

Experimental Evaluation of the Risk of Distal Embolization during Endovascular Clot Retrieval Using Various Techniques

Abstract

Background: This study was conducted to evaluate various devices and techniques for endovascular thrombectomy that can reduce the risk of intraprocedural distal embolism in a preliminary *in vitro* setting with different types of thrombi. **Materials and Methods:** Endovascular clot retrieval was performed in a vascular model with collateral circulation. White and red thrombi were prepared using whole blood collected from a pig. A Direct Aspiration First Pass Technique (ADAPT), simple stentretreiving with and without proximal flow arrest by a guiding balloon (SR [B+] and SR [B±]), the AspirationRetriever Technique for Stroke (ARTS), and A stentretreiving into an Aspiration catheter with Proximal balloon (ASAP) were performed three times, respectively. The saline samples that were collected at the distal side during each procedure were examined using a particle counter. The particles were counted and categorized into three groups based on size (100 µm). **Results:** SR (B-) and SR (B+) could not achieve complete retrieval of the clot, especially using the white thrombus. ASAP was the only method that was able to retrieve the clots in all attempts. In both clot types, SR (B-), SR (B+), and ARTS, which involved a temporary flow restoration through stent deployment, demonstrated the migration of a greater number of particles measuring >100 µm in size than that shown by ADAPT and ASAP. **Conclusions:** ASAP was the safest method in terms of intraprocedural clot migration among the five methods evaluated in this study. Temporary flow restoration through stent deployment may affect the dangerous distal clot migration.

Keywords: Acute ischemic stroke, aspiration, distal embolization, stent clot retriever

Introduction

For patients with acute ischemic stroke, various endovascular approaches have been attempted with high recanalization rates and good clinical outcomes. A meta-analysis of five trials confirmed the benefit of mechanical thrombectomy in patients with acute ischemic stroke caused by occlusion of the proximal anterior circulation, irrespective of the use of tissue plasminogen activator.^[1] However, mechanical thrombectomy has a few limitations. Ischemic complications such as distal embolization and embolization to a new territory may require repeat procedures, and further thrombus migration to a distal small vessel may not be accessible through a microcatheter. To avoid these complications, several novel approaches have been reported with good outcomes; however, there is no consensus on the best system in the first attempt.

This is an open access journal, and articles are distributed under the terms of the Creative Commons Attribution-NonCommercial-ShareAlike 4.0 License, which allows others to remix, tweak, and build upon the work non-commercially, as long as appropriate credit is given and the new creations are licensed under the identical terms.

For reprints contact: WKHLRPMedknow_reprints@wolterskluwer.com

We hypothesized that distal release of embolic particles during endovascular procedures is related to the device and the treatment strategy, and lesser with the Aspiration catheter with Proximal (ASAP) technique^[2] than with any other techniques such as captive^[3] and aspiration-retriever technique for stroke (ARTS).^[4] Therefore, the aim of this study was to evaluate various devices and techniques for endovascular thrombectomy that can reduce the risk of intraprocedural distal embolism using a preliminary *in vitro* middle cerebral artery (MCA) occlusion model with different types of thrombi.

Materials and Methods

In vitro settings

A simple silicone vascular model with a fluid circulator was used as an MCA occlusion model [Figure 1]. Saline was maintained at 37°C using a heater. It was continuously served through the vascular

Tomotaka Ohshima¹,
Shigeru Miyachi^{1,2}

¹Neuroendovascular Therapy Center, Aichi Medical University, ²Department of Neurosurgery, Aichi Medical University, Nagakute, Aichi, Japan

Address for correspondence:

Dr. Tomotaka Ohshima,
1-1 Yazakokarimata, Nagakute,
Aichi 480-1195, Japan.
E-mail: tmtkoh@gmail.com

Access this article online

Website: www.asianjns.org

DOI: 10.4103/ajns.AJNS_237_20

Quick Response Code:



How to cite this article: Ohshima T, Miyachi S. Experimental evaluation of the risk of distal embolization during endovascular clot retrieval using various techniques. *Asian J Neurosurg* 2021;16:84-8.

Submitted: 18-May-2020

Revised: 14-Jun-2020

Accepted: 12-Jul-2020

Published: 23-Feb-2021

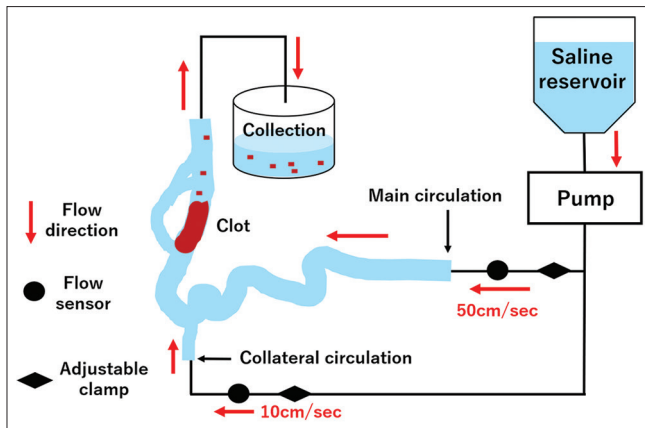


Figure 1: Schematic drawing of the vascular model. Saline in the reservoir was maintained at 37°C. It was continuously served through the vascular model at a rate of 50 cm/s into the main route and at 10 cm/s into the collateral route. The draining saline with the particles was collected at the distal end

model at a rate of 50 cm/s into the main route and at 10 cm/s into the collateral route. The particles collected in 20ml saline at the distal side were counted using a particle counter (Z2 9914558; Beckman Coulter, Brea, CA, USA). The particles were counted and categorized into three groups based on size (<20, 20 – 100, and >100 μm). We defined the risk of infarction to the distal territories as low for <20 μm particles, moderate for 20 –100 μm particles, and high for >100 μm particles.

Clot preparation

We collected a whole blood sample from pig and created a white hard clot from its serum part and red soft clot from the rest of the sample [Figure 2]. Three–4 days before our experiment, we took arterial blood from the nonheparinized laboratory animal into two 40cc test tubes. After leaving it at room temperature for a half-day, we retained it in the refrigerating chamber at 4°C until the day before the experiment. We visually confirmed the whole blood was spontaneously separated into blood serum and a blood clot on the right before the day of the experiment. We did not use any anticoagulant nor centrifugal separator for this separation. We collected 3cc of the blood serum part with a syringe, added 0.15 ml of thrombin, which is commercially available Thrombin Liquid Mochida Soft Bottle 5000 (Mochida Pharmaceutical, Tokyo) containing 5000 units of thrombin per 5 cc, and kept it in a dish at 4°C to congeal over the night. On the experiment day, we moved the created white clot into a new clean dish as the white clot sample. We kept the rest part of the whole blood after serum collection in the refrigerator and used it as the red soft clot sample without adding any material or procedure. The white clot was prepared using plasma of whole blood by centrifuging it and added thrombin until coagulation. The red clot was prepared from precipitated blood cells and added thrombin until coagulation. Each piece of the clot setting in the vascular model was measured as 2.0 g using an accurate scale.

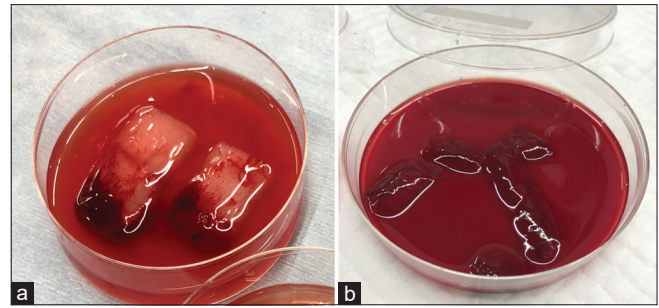


Figure 2: Photograph of clots. (a) Lumps of white clots. (b) Lumps of red clots

Endovascular procedures

We performed the following methods using the white and red clots three times in each group and have evaluated the successful retrieval of clot and calculation of particles;

A direct aspiration first pass technique

A SOFIA Flow Plus (Terumo, Tokyo, Japan) aspirator was navigated up to the proximal end of the clot using a coaxial Headway 21 microcatheter (Terumo). After beginning aspiration through a pump (Penumbra MAX pump; Penumbra, Alameda, CA, USA), the guiding balloon was inflated (modified A direct aspiration first pass technique [ADAPT]).^[5] The SOFIA Flow Plus aspirator was withdrawn and retrieved into the guiding catheter. Then, the guiding balloon was deflated.

Stent-retrieving without proximal flow arrest by a guiding balloon (SR [B-])

A Solitaire Platinum 4 × 40 (Medtronic, Irvine, CA, USA) stent retriever was used through a Headway 21 microcatheter. The guiding balloon was not inflated during the procedure.

Stent-Retrieving with proximal flow arrest by a guiding balloon (SR [B+])

The above-mentioned Solitaire and Headway 21 microcatheter were used here, but the guiding balloon was inflated before the stent was withdrawn. After retrieving the stent, the guiding balloon was deflated.

Aspiration-retriever technique for stroke

The SOFIA Flow Plus was coaxially used for navigating the Headway 21 microcatheter and the Solitaire 4 × 40. After deployment of the stent, the aspirator was advanced until the backflow of fluid from the proximal end of the system into the penumbra pump was stopped. Then, the guiding balloon was inflated. The Solitaire and SOFIA were withdrawn and retrieved together into the guiding catheter while maintaining the distance from the tip of the Solitaire to the tip of the SOFIA. After retrieving the stent and the aspirator, the guiding balloon was deflated.

A stent-retrieving into an Aspiration catheter with proximal balloon^[2]

The same devices used for ARTS were used. Before the deployment of the stent, the proximal guiding balloon was inflated. Then, after stent deployment, the aspirator was advanced up to the approximate proximal end of the clot with aspiration through the pump. Next, the stent was retrieved into the aspirator at the local site. Then, the aspirator was withdrawn into the guiding catheter, after which the proximal balloon was deflated. The ASAP technique which involves a secured contact aspiration after the stent retriever failed due to escaping clot, which has an advantage over the Solumbra technique. Moreover, the vessel shift phenomenon looks lesser than simultaneous withdrawal both the stent and aspirator, such as simple stent-retrieving and ARTS.

Endpoints

The primary endpoints were assessed based on the risk of distal embolism according to the number of clot fragments in each procedure. The secondary endpoints were successful recanalization with each procedure using the different types of clot.

Statistical analysis

Data were analyzed using Microsoft Excel (Microsoft Corporation, Redmond, WA, USA) and SPSS version 21.0 for Windows (SPSS Inc., Chicago, IL, USA) to evaluate equal variances of each procedure. All statistical tests were two-sided, and $P < 0.05$ was considered for statistical significance.

Results

The result obtained in each procedure using the white clot is presented in Table 1, and the result obtained using the red clot is shown in Table 2. Both SR (B-) and SR (B+) could not achieve complete retrieval of the clot, especially using the white clot. ASAP was the only method that could retrieve the clots in all attempts. The results of each procedure obtained using the white clot are depicted as a graph in Figure 3, and that obtained using the red clot is presented in Figure 4. Using the red thrombus, groups of SR (B-) and SR (B+) demonstrated the migration of a greater number of particles measuring $<20 \mu\text{m}$ in size than that in other groups ($P < 0.05$). ASAP showed the migration of the least number of particles measuring $<20 \mu\text{m}$ ($P < 0.01$). In both clot types, SR (B-), SR (B+), and ARTS, which involved a temporary flow restoration through stent deployment, revealed the migration of a greater number of particles measuring $>100 \mu\text{m}$ in size than that shown by ADAPT and ASAP [Figure 5].

Discussion

The risk of embolization into new territories is of particular concern in mechanical thrombectomy, as embolization can

Table. 1 Results of white clots

Retrieval	10-20 μm	20-100 μm	$>100 \mu\text{m}$	
○ or ×				
ADAPT	○	5,360	600	0
	○	2,800	250	1
	×	16,600	2,700	0
SR (B-)	×	6,160	560	2
	×	77,710	780	2
	×	3,500	1,190	1
SR (B+)	×	14,140	700	0
	×	22,240	1,520	2
	○	16,640	4,340	1
ARTS	×	8,800	2,560	1
	○	980	420	0
	○	1,495	345	1
ASAP	○	2,240	400	0
	○	3,760	240	0
	○	5,775	595	0

○; success, ×; failure, SR (B-); Stent Retrieving without proximal flow arrest by a guiding Balloon, SR (B+); Stent Retrieving with proximal flow arrest by a guiding Balloon

Table. 2 Results of red clots

Retrieval	10-20 μm	20-100 μm	$>100 \mu\text{m}$	
○ or ×				
ADAPT	○	143,000	600	3
	○	5,206,045	650	3
	○	2,432,115	135	0
SR (B-)	×	6,886,360	2,340	10
	×	10,440,625	1,625	3
	○	9,183,510	1,120	1
SR (B+)	○	701,190	3,510	4
	×	176,94,360	1,150	1
	○	100,64,460	1,820	0
ARTS	○	37,52,250	1,050	2
	○	34,79,040	1,350	2
	○	32,21,760	1,760	0
ASAP	○	11,150	250	0
	○	23,580	260	0
	○	59,220	390	0

○; success, ×; failure, SR (B-); Stent Retrieving without proximal flow arrest by a guiding Balloon, SR (B+); Stent Retrieving with proximal flow arrest by a guiding Balloon

impair collateral blood supply to the affected territory, accelerate penumbral tissue loss, and cause additional ischemic lesions.^[6] In previous studies, researchers have investigated embolic fragments in both clinical and *in vitro* experiments.^[7-9] We hypothesized that the distal release of embolic particles during endovascular procedures is lesser with the ASAP^[2] technique than with any other techniques such as CAPTIVE^[3] and ARTS.^[4] Furthermore, we predicted that the ASAP technique could achieve the highest rate of recanalization against any clot mechanics

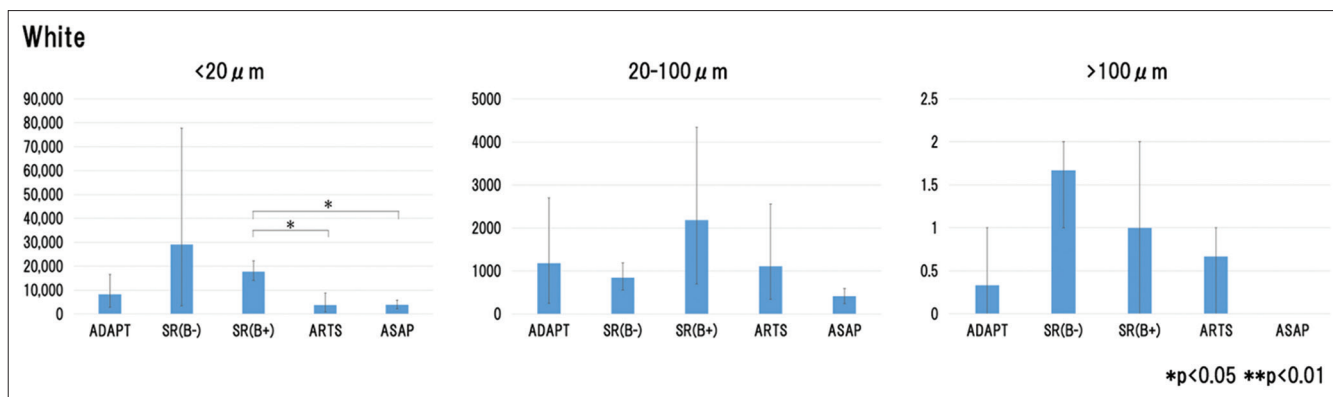


Figure 3: Number of counted particles in each procedure using the white clot. SR (B-): Stent-Retrieving without proximal flow arrest by a guiding balloon, SR (B+): Stent-Retrieving with proximal flow arrest by a guiding balloon

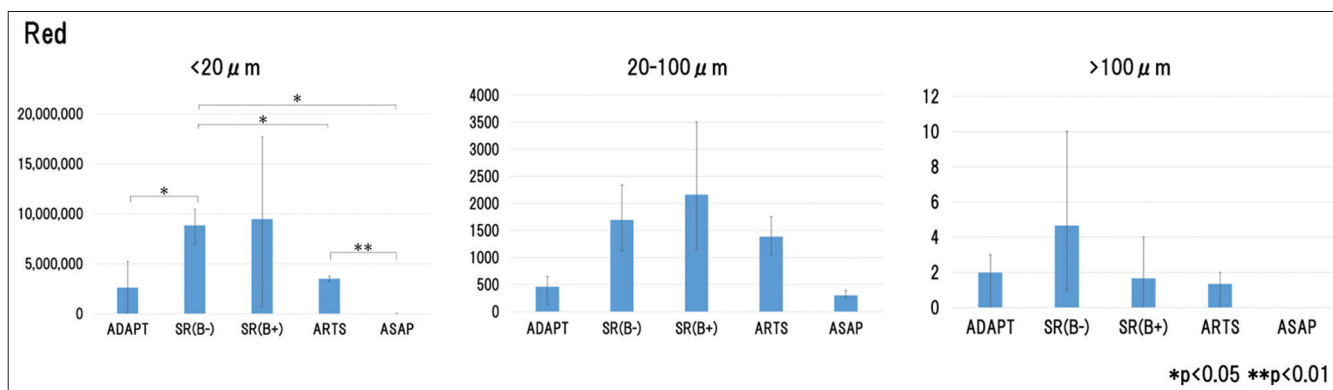


Figure 4: Number of counted particles in each procedure using the red clot. SR (B-): Stent-Retrieving without proximal flow arrest by a guiding balloon, SR (B+): Stent-Retrieving with proximal flow arrest by a guiding balloon

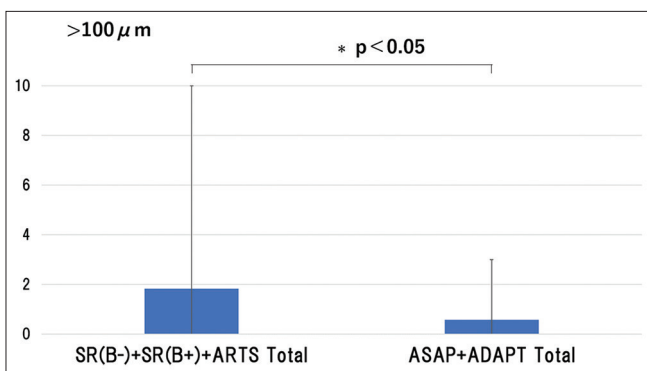


Figure 5: Number of particles with or without a temporary flow restoration through stent deployment. SR (B-): Stent-Retrieving without proximal flow arrest by a guiding balloon, SR (B+): Stent-Retrieving with proximal flow arrest by a guiding balloon

compared with other techniques, including the ADAPT.^[5] Therefore, we evaluated various devices and techniques for endovascular thrombectomy that can reduce the risk of intraprocedural distal embolism and rapid recanalization using a preliminary *in vitro* vascular model with different types of thrombi.

In this study, we found that ASAP was the only method that could retrieve the clots in all attempts as we expected. The red clots could be retrieved in all sessions using

ADAPT, ARTS, and ASAP. Moreover, the red clots were easier to remove than the white clots. In general, both the white and red clots were difficult to retrieve using the method of simple stent-retrieving with or without proximal balloon occlusion. Only the stent retriever without a combined aspirator was used since the white clot appeared to be rolling between the stent and the vessel wall, the clot remained at the occluded site. This was because the white clots exhibit more friction against both the stent and the vessel wall than the red clots.

We categorized the migrated fragments into three groups according to their size. Particles measuring <20 μm were defined to be of low risk in causing distal embolism because this size appeared similar to that of blood cells. Particles measuring 20 –100 μm were defined to be of moderate risk, whereas those measuring >100 μm were defined to be of high risk in causing infarction to the distal territories.^[10] In this study, we were not able to demonstrate the superiority of ASAP over the other techniques in the group of >100 μm particles with statistical significance because no fragment was detected using the ASAP technique. We believe that the fact that the results are not statistically significant is simply related to the sample size. In both clot types, SR (B-), SR (B+), and ARTS revealed the migration of a greater number of particles measuring >100 μm in size than that

shown by ADAPT and ASAP. Therefore, the techniques that involved a temporary flow restoration through stent deployment before the proximal flow arrest demonstrated a risk of distal embolism. In case a continuous aspiration was induced after the proximal flow arrest as in ASAP, the collateral circulation could be ignored to promote distal embolism during stent deployment. We also had thought that the ASAP techniques were more likely to occur the distal embolism by the collateral flow than the CAPTIVE or ARTS. However, in this study, when the deployed stent was withdrawn into the aspirator, there was no major clot migration. During the stent withdrawal, as the deployed stent was worked to keep the aspiration lumen, the broken thrombi were fully aspirated into the large-caliber aspiration catheter. Moreover, the CAPTIVE or ARTS were often released the broken clot at the tip of the guiding catheter.

Chueh *et al.*^[9] reported that ADAPT and the use of balloon guiding catheter during stent retrieval were associated with lower rates of distal embolization in their *in vitro* experiment. They recommended the combined technique or direct aspiration in addition to the balloon guiding catheter when encountering hard clots. These results were in complete agreement with our findings.

This study has several limitations. First, the silicone vascular model does not completely mimic the actual vessels. It has only a limited collateral pathway. Second, in actual circumstances, there are more than two types of clots. Finally, this study was performed under direct vision to navigate and deploy the devices, and the efficacy of all techniques is likely to be overestimated compared to the actual clinical settings.

The risk of distal embolization is affected by the device, the technique, and the clot mechanics. ASAP was the safest method in terms of intraprocedural distal embolism among the five methods evaluated in this study. Temporary flow restoration through stent deployment may affect the dangerous distal embolism.

Financial support and sponsorship

Nil.

Conflicts of interest

There are no conflicts of interest.

References

1. Goyal M, Menon BK, van Zwam WH, Dippel DW, Mitchell PJ, Demchuk AM, *et al.* Endovascular thrombectomy after large-vessel ischaemic stroke: A meta-analysis of individual patient data from five randomised trials. *Lancet* 2016;387:1723-31.
2. Goto S, Ohshima T, Ishikawa K, Yamamoto T, Shimato S, Nishizawa T, *et al.* A stent-retrieving into an aspiration catheter with proximal balloon (ASAP) technique: A technique of mechanical thrombectomy. *World Neurosurg* 2018;109:e468-75.
3. McTaggart RA, Tung EL, Yaghi S, Cutting SM, Hemendinger M, Gale HI, *et al.* Continuous aspiration prior to intracranial vascular embolectomy (CAPTIVE): A technique which improves outcome. *NeuroIntervent Surg* 2016;0:1-6
4. Massari F, Henninger N, Lozano JD, Patel A, Kuhn AL, Howk M, *et al.* ARTS (Aspiration-retriever technique for stroke): Initial clinical experience. *Interv Neuroradiol* 2016;22:325-32.
5. Turk AS, Frei D, Fiorella D, Mocco J, Baxter B, Siddiqui A, *et al.* ADAPT FAST study: A direct aspiration first pass technique for acute stroke thrombectomy. *NeuroIntervent Surg* 2014;6:260-4.
6. Jung S, Gilgen M, Slotboom J, El-Koussy M, Zubler C, Kiefer C, *et al.* Factors that determine penumbral tissue loss in acute ischaemic stroke. *Brain* 2013;136:3554-60.
7. Kurre W, Vorlaender K, Aguilar-Pérez M, Schmid E, Bätzner H, Henkes H. Frequency and relevance of anterior cerebral artery embolism caused by mechanical thrombectomy of middle cerebral artery occlusion. *AJNR Am J Neuroradiol* 2013;34:1606-11.
8. Todo A, Minaeian A, Sahni R, Chao KH. Incidence and outcome of procedural distal emboli using the penumbra thrombectomy for acute stroke. *J Neurointerv Surg* 2013;5:135-8.
9. Chueh JY, Puri AS, Wakhloo AK, Gounis MJ. Risk of distal embolization with stent retriever thrombectomy and ADAPT. *J Neurointerv Surg* 2016;8:197-202.
10. Rapp JH, Pan XM, Yu B, Swanson RA, Higashida RT, Simpson P, *et al.* Cerebral ischemia and infarction from atheroemboli <100 micron in size. *Stroke* 2003;34:1976-80.