

The periumbilical incision for anterior lumbar interbody fusions

Sherwin Abdoli, MD,^a Jin Sui, MD,^a Kenneth Ziegler, MD,^b Steven Katz, MD,^{a,b} Walter Burnham, MD,^a and Christian Ochoa, MD,^b Pasadena and Los Angeles, Calif

ABSTRACT

The traditional retroperitoneal approach for the anterior lumbar interbody fusion (ALIF) uses a longitudinal paramedian incision. In this study, we use a discrete periumbilical incision. A 270-degree semicircular incision is made around the umbilicus and the subcutaneous tissue is dissected radially at a 45-degree angle, creating a mound around the umbilical stalk. Once the anterior sheath is encountered, the steps of the operation converge with those of the traditional approach. In this study, 30 patients underwent a periumbilical ALIF with an average of 2.1 levels fused. Perioperative outcomes were comparable to those described in the ALIF literature. No patients experienced complications attributable to the periumbilical incision. (*J Vasc Surg Cases and Innovative Techniques* 2020;6:384-7.)

Keywords: Spinal surgery; Exposure; Minimally invasive surgery

The first reported spinal fusion was during the start of the 20th century, when orthopedic surgeons manipulated and fused the spinous processes with wires and rods.¹ By the 1930s, spinal fusions began to be performed using an anterior approach, and in 1963, the first anterior retroperitoneal approach to the lumbar spine was reported. Since then, several other spinal access techniques, including the transforaminal, extreme lateral, and oblique lateral approaches, have been described. Unfortunately, these new approaches require the surgeon to operate endoscopically because of their obtuse angles and small working space. In 2018, Italian surgeon Roberto Bassani described his experience obtaining retroperitoneal anterior exposure using a 270-degree periumbilical incision.² In this report, we describe our observations using the 270-degree periumbilical incision among multiple access surgeons at our institution to provide anterior access for anterior lumbar

interbody fusion (ALIF). Patients signed written consent agreeing to be photographed or video taped for publication.

METHODS

Institutional Review Board approval was obtained. Patients undergoing ALIF through a periumbilical incision between 2015 and 2018 were identified. The surgeon's and anesthesiologist's preoperative history and physical examination findings were reviewed to collect demographics, comorbidities, past surgical history, and indication for surgery. The operative report, intraoperative nursing report, and anesthesia run sheet were examined to obtain operative time, blood loss, levels fused, and deviations from the normal operation (including extension of the initial incision; repositioning of the implant; and injury to peritoneum, visceral organs, dura, or vascular structures). Inpatient progress notes were reviewed to determine hospital length of stay, complications as defined by Clavien-Dindo classification, postoperative pain requiring escalation of narcotic regimen, readmission within 30 days, and emergency department visits within 30 days.³

Technique. A 270-degree semicircular incision, with the opening facing the patient's head, is made with a diameter of approximately 6 cm (*Fig. A and B; Video*). Once the subcutaneous fat is encountered, the surgeon begins to angle the dissection radially at 45 degrees, thus creating a large mound of subcutaneous fat around the umbilicus (*Fig. C and D*). The result is that once the anterior rectus sheath is reached, the 270-degree circular dissection has a much larger diameter than the original skin incision (*Fig. E*). Once the anterior rectus sheath has been encountered, the steps of the operation are the same as those of the standard paramedian incision: the

From the Department of Surgery, Huntington Memorial Hospital, Pasadena^a; and the Division of Vascular Surgery and Endovascular Therapy, University of Southern California, Los Angeles.^b

Author conflict of interest: W.B. is a paid consultant for NuVasive, Inc.

Presented at the Thirty-fourth Annual Meeting of the Western Vascular Society, Maui, Hawaii, September 28-October 1, 2019.

Correspondence: Christian J. Ochoa, MD, Assistant Professor of Surgery, Division of Vascular Surgery and Endovascular Therapy, Department of Surgery, Keck School of Medicine of USC, 1520 San Pablo St, Ste 4300, Los Angeles, CA 90033 (e-mail: christian.ochoa@med.usc.edu).

The editors and reviewers of this article have no relevant financial relationships to disclose per the Journal policy that requires reviewers to decline review of any manuscript for which they may have a conflict of interest.

2468-4287

© 2020 The Author(s). Published by Elsevier Inc. on behalf of Society for Vascular Surgery. This is an open access article under the CC BY-NC-ND license (<http://creativecommons.org/licenses/by-nc-nd/4.0/>).

<https://doi.org/10.1016/j.jvscit.2020.06.011>

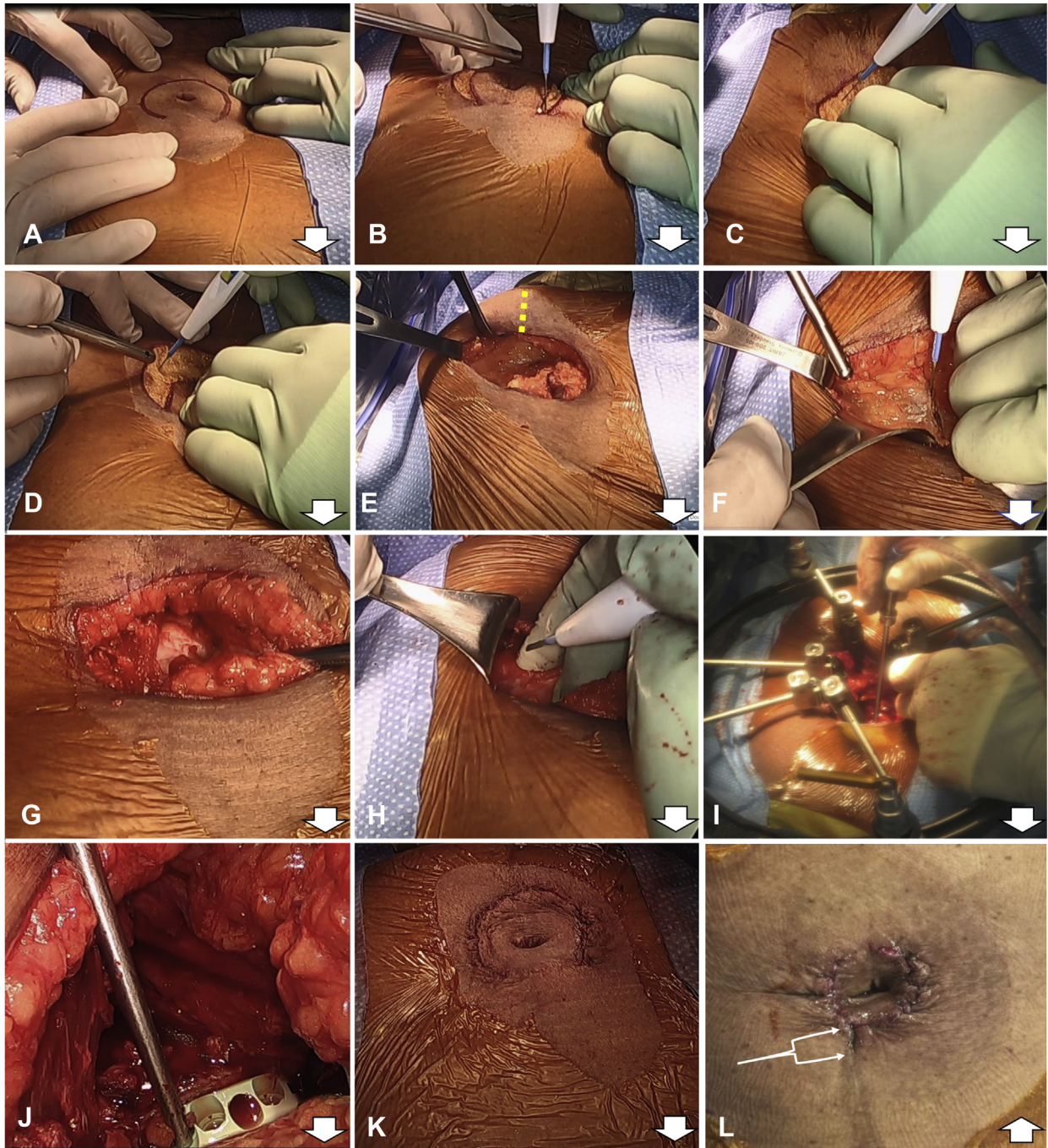


Fig. The steps of the periumbilical incision for anterior lumbar interbody fusion (ALIF). The *thick white arrows* point cephalad. **A**, A 270-degree semicircle is drawn centered on the umbilicus with a diameter of about 6 cm. **B**, The skin of the 270-degree semicircle is cut. **C-E**, Once the skin has been transected and thus subcutaneous fat is encountered, the dissection continues radially at a 45-degree angle until the anterior sheath is encountered. A *yellow dotted line* demonstrates where a counterincision can be made partway through the case to expand the field of view if the initial incision is made with too small of a diameter. **F**, The anterior sheath is cut at its medial attachment to the linea alba. **G**, The rectus abdominis is retracted laterally, revealing the posterior sheath. **H**, The posterior sheath is incised laterally at the arcuate line. **I** and **J**, Retractors are placed such that a single spinal level is exposed, then repositioned without modifying the original incision to expose other levels. **K**, The dermis is closed with buried interrupted polyglactin stitches, and the epidermis is closed with buried interrupted polyglactone stitches. Dermabond is applied on top of the closure. **L**, This photograph shows a different patient 3 weeks after the original procedure. In the case pictured here, a small counterincision had been made during the operation to increase the size of the exposure as highlighted by the *bident*. Only one patient (3%) had to have such a counterincision made.

Table I. Demographics

Patients	(N = 30)
Female	16 (53)
BMI, kg/m ²	28 (6)
Age, years	57 (12)
ASA class	
1	3 (10)
2	15 (50)
3	12 (40)
Indication	
Spinal stenosis	10 (33)
Spondylolisthesis	8 (26)
Neuromuscular pain condition	11 (36)
Scoliosis	1 (3)
Posterior fusion during admission	29 (97)
Same day	8 (27)
Following day	21 (70)

ASA, American Society of Anesthesiologists; BMI, body mass index. Categorical variables are presented as number (%). Continuous variables are presented as mean (standard deviation).

anterior rectus sheath is incised at its medial attachment to the linea alba, the left rectus abdominis is retracted laterally, the posterior sheath is incised at the lateral aspect of the arcuate line, and the peritoneum is medialized to expose the lumbar spine (Fig, F-H). Retractors are placed such that a single spinal level is exposed (Fig, I and J). We use the Phantom AL (TeDan Surgical Innovations, Sugar Land, Tex) or the MaXcess supine ALIF access retractor (NuVasive, San Diego, Calif). These are ring retractors designed for supine ALIF access and feature two redundant articulating table-mounted arms. The described exposure creates a lax dissection that allows the retractors to easily be repositioned to expose any level between S1 and L3. When encountered, the iliolumbar vein near L4-L5, the segmental vessels of L3-L4, and the middle sacral vessels overlying L5-S1 are tied off proximally and distally with 3-0 silk ties, redundantly clipped, and then divided with Metzenbaum scissors. At the conclusion of the case, the dermis and epidermis are closed using buried interrupted stitches with skin adhesive applied on top (Fig, K). We do not place subcutaneous drains. Although we found our incision to be adequate to operate on any level from L3 to S1, the diameter of the initial incision can be expanded if a wider field of view is desired, such as to expose two levels simultaneously, or contracted if the surgeon is comfortable restricting the field of view. If a wider field of view is needed partway through the operation, a small counterincision that starts at the bottom curve of the 270-degree semicircular incision and extends out inferiorly can be made (Fig, L).

Table II. Outcomes

Outcome	(N = 30)
Levels fused	
L4-L5	6 (20)
L4-L5, L5-S1	14 (47)
L3-L4, L4-L5, L5-S1	10 (33)
Operative time, minutes	
L4-L5	134
L4-L5, L5-S1	160
L3-L4, L4-L5, L5-S1	172
Blood loss, mL	176 (166)
Intraoperative complications	
Bleeding >500 mL	2 (7)
Iliac vein injury	1 (3)
Counterincision	1 (3)
Postoperative complications	
Hypotension	3 (10)
Urinary retention	2 (7)
Incisional pain	2 (7)
Blood transfusion	2 (7)
Seroma	1 (3)
Length of stay, days	
Single operative day	3 (2-4)
Two operative days	4 (3-6)
Readmission within 30 days	1 (3)

Categorical variables are presented as number (%). Continuous variables are presented as mean (standard deviation) or median (interquartile range).

RESULTS

Thirty patients underwent a periumbilical ALIF by one of four access surgeons (Table I). Fifty-three percent were female, the average age was 57 years, the average body mass index (BMI) was 29 kg/m² (range, 21-40 kg/m²), and the average American Society of Anesthesiologists class was 2.3. Twenty percent received single-level (L4-L5) fusions, 47% received two-level fusions (L4-S1), and 33% received triple-level fusions (L3-S1); the mean operative times for these procedures were 134 minutes, 160 minutes, and 172 minutes, respectively (Table II). No periumbilical L5-S1 fusions were observed as the surgeons performed these exclusively using a Pfannenstiel incision. Intraoperatively, two patients experienced blood loss in excess of 500 mL as a result of aggressive blunt dissection on top of the spine. One of these patients suffered a partial venotomy of the left iliac vein requiring primary repair with a figure-of-eight polypropylene stitch; the other had bleeding from small, unnamed veins that resolved with manual pressure and topical hemostatic agents. One patient required an additional counterincision. There were 29 patients (97%) who had a posterior fusion performed during the hospital stay;

8 patients (27%) had this performed immediately on completion of the ALIF, whereas 21 patients (70%) had it performed on a subsequent day of the hospitalization.

Postoperatively, five patients complained of neurologic pain or weakness that resolved before discharge. The two patients who experienced significant intraoperative bleeding resulting in postoperative hypotension were treated with postoperative blood transfusions. One patient, whose operative course was unremarkable, experienced postoperative hypotension that resolved after an intravenous fluid bolus. Two patients complained of incisional pain that required an escalation of the originally ordered narcotic regimen. Two patients suffered urinary retention requiring temporary Foley placement. There were no infectious complications, wound breakdowns, or complications unique to the periumbilical incision, such as umbilical necrosis. Of the patients who underwent an ALIF only or an ALIF and a posterior fusion on the same day, the median length of stay was 3 days; for those who underwent an ALIF and a posterior fusion on separate days, the median length of stay was 4 days. During the 30 days after the index operation, one patient presented to the emergency department with intractable pain and was admitted for intravenous analgesics; another presented to the emergency department with a sterile seroma, which was managed nonoperatively on an outpatient basis.

DISCUSSION

We continue to perform L5-S1 fusions exclusively through a Pfannenstiel incision as we think its discrete location in the pubic hairline is aesthetically superior and the approach is more direct for the L5-S1 disk space, although there are no technical restrictions preventing the use of the periumbilical incision. We did not decline any patients for this approach because of BMI; our study included six patients with BMIs >35 kg/m². Although we did not observe any skin necrosis, our thinnest patient had a BMI of 21 kg/m², and it is possible that if we had operated on patients with very little subcutaneous fat, the undermining of skin could have resulted in necrosis.

Several systematic reviews and meta-analyses have compared newer exposure techniques to the standard

ALIF, and these outcomes can be used as qualitative benchmarks. In 2015, Phan et al⁴ performed a review and meta-analysis of studies comparing ALIF with transforaminal lumbar interbody fusion. Of the 12 studies they reviewed, 8 reported mean ALIF operative times, and the median was 281.5 minutes; 8 reported blood loss, with a median of 814 mL; and 8 reported length of stay, with a median of 6.65 days. Five studies reported vascular injury, with an overall incidence of 2.5%; five studies reported neurologic deficit, with an overall incidence of 6.7%; and seven studies reported infections, with an overall incidence of 4.9%.

CONCLUSIONS

This study validates the periumbilical incision in a different setting from the original Bassani study. The Bassani study was a single-surgeon study performed at a European institute without an access surgeon and with the assistance of an endoscope. The patients were on average 9 years younger, had a mean American Society of Anesthesiologists class of 1.51 vs 2.51 in this study, and had an average of 1.7 levels fused as opposed to 2.3 levels. With the addition of this study, we conclude that the periumbilical exposure is a safe alternative to the traditional paramedian incision for ALIF.

REFERENCES

1. Tarpada SP, Morris MT, Burton DA. Spinal fusion surgery: a historical perspective. *J Orthop* 2017;14:134-6.
2. Bassani R, Querenghi AM, Cecchinato R, Morselli C, Casero G, Gavino D, et al. A new "keyhole" approach for multilevel anterior lumbar interbody fusion: the perinavel approach—technical note and literature review. *Eur Spine J* 2018;27:1956-63.
3. Clavien PA, Barkun J, De Oliveira ML, Vauthey JN, Dindo D, Schulick RD, et al. The Clavien-Dindo classification of surgical complications: five-year experience. *Ann Surg* 2009;250:187-96.
4. Phan K, Thayaparan GK, Mobbs RJ. Anterior lumbar interbody fusion versus transforaminal lumbar interbody fusion—systematic review and meta-analysis. *Br J Neurosurg* 2015;29:705-11.

Submitted Apr 27, 2020; accepted Jun 9, 2020.