




ELSEVIER

Contents lists available at ScienceDirect

JPRAS Open

journal homepage: [www.elsevier.com/locate/jpra](http://www.elsevier.com/locate/jpra)



## Review Article

# The management of deep sternal wound infection: Literature review and reconstructive algorithm

Pennylouise Hever, Prateush Singh\*, Inez Eiben, Paola Eiben, Dariush Nikkhah

*Department of Plastic Surgery, Royal Free London NHS Foundation Trust, Pond Street, London, United Kingdom*

## ARTICLE INFO

### Article history:

Received 1 February 2021

Accepted 26 February 2021

Available online 6 March 2021

## ABSTRACT

Deep sternal wound infection (DSWI) is an important complication of open thoracic surgery, with a reported incidence of 0.5–6%. Given its association with increased morbidity, mortality, inpatient duration, financial burden, and re-operation rates, an aggressive approach to treatment is mandated. Flap reconstruction has become the standard of care, with studies demonstrating improved outcomes with reduced mortality and resource usage in patients undergoing early versus delayed flap reconstruction. Despite this, no evidence-based standard for the management of DSWI exists.

We performed a thorough review of the literature to identify principles in management, using a PRISMA compliant methodology. Ovid-Embase, Medline and PubMed databases were searched for relevant papers using the search terms “deep sternal wound infection,” and “post-sternotomy mediastinitis” to December 2019. Duplicates were removed, and the search narrowed to look at specific areas of interest i.e. negative pressure wound therapy, flap reconstruction, and rigid fixation. The reference list of included articles underwent full text review. No randomized controlled trials were identified.

\* Corresponding author.

E-mail addresses: [phever@nhs.net](mailto:phever@nhs.net) (P. Hever), [rmhkpsi@ucl.ac.uk](mailto:rmhkpsi@ucl.ac.uk) (P. Singh).

We review the current management techniques for patients with DSWI, and raise awareness for the need for further high quality studies, and a standardized national cardiothoracic-plastic surgery guideline to guide management. Based on our findings and the authors' own experience in this area, we provide evidence-based recommendations. We also propose a reconstructive algorithm.

© 2021 The Authors. Published by Elsevier Ltd on behalf of British Association of Plastic, Reconstructive and Aesthetic Surgeons. This is an open access article under the CC BY-NC-ND license (<http://creativecommons.org/licenses/by-nc-nd/4.0/>)

## Introduction

Deep sternal wound infection (DSWI) is a significant complication of thoracic surgery performed by a median sternotomy approach, with reported incidence 0.5–6%.<sup>2–7</sup> The Centers for Disease Control and Prevention (CDC) defines DSWI as having one of the following criteria: (1) an organism isolated from culture of mediastinal tissue/ fluid; (2) evidence of mediastinitis seen intraoperatively; (3) presence of chest pain, sternal instability, or fever ( $> 38\text{ }^{\circ}\text{C}$ ), and purulent drainage from the mediastinum or isolation of organism present in a blood culture or from the mediastinal area.<sup>1</sup> The consequences of DSWI can be catastrophic with increased morbidity and mortality, and decreased life expectancy, so one must have a low threshold for diagnosis and a clear management algorithm.<sup>8,9</sup>

Currently, the literature consists of only limited, low-quality evidence, and no clear management algorithm. The consensus, however, remains that early plastic surgery input with definitive operative management improves outcomes and reduces mortality. We therefore analyse and outline evidence from the current literature to provide recommendations and construct a robust reconstructive algorithm.

## Methods

A PRISMA compliant review of the literature was performed using Ovid-Embase, Medline and PubMed databases up to December 2019 using the search terms “deep sternal wound infection,” and “post-sternotomy mediastinitis”. 1883 number of texts were identified on initial screen. Duplicates were removed, and the search narrowed to look at specific areas of interest i.e. negative pressure wound therapy, flap reconstruction, and rigid fixation, excluding texts not relevant to post-surgical sternal complications. Case reports and foreign language papers were also excluded. The reference list of included articles underwent full text review. No randomized controlled trials were identified.

## Classification

Many classification systems have been proposed to classify DSWI (Table 1),<sup>10–13,15</sup> In our unit, we adopt the Pairolero and Arnold classification, which classifies DSWI according to timing of presentation.<sup>14</sup> The fault with this classifications is that it fails to immediately direct reconstructive options. Greig et al. tried to address this by proposing an anatomical classification to guide flap choice based on site of infection,<sup>15</sup> classifying wounds into types A, B or C (see Table 1).

## Risk factors

Prevention is key to minimising risk of DSWI following open thoracic surgery, with appropriate patient selection and perioperative care. Risk factors can be divided into patient factors, perioperative factors, and procedural factors (Table 2). Patient risk factors are cumulative, making the early identification of high-risk patients with multiple risk factors imperative.<sup>6,16–18</sup> Gatti et al. performed

**Table 1**  
Classification systems for DSWI.

El-Oakley & Wright (1996) <sup>10</sup>	Rupprecht & Schmid (2013) <sup>13</sup>	Pairolero & Arnold (1984) <sup>14</sup>	Greig (2007) <sup>15</sup>
<b>Type I:</b> Presentation within 2 weeks of operation, in the absence of risk factors	Sternal instability without infection	<b>Type I:</b> First few days post-op	<b>Type A:</b> Wounds involving the upper half of the sternum
<b>Type II:</b> Presentation within 2–6 weeks of operation, in the absence of risk factors	DSWI without sternal instability	<b>Type II:</b> First few weeks	<b>Type B:</b> Wounds involving the lower half of the sternum
<b>Type IIIa:</b> Type I + 1 or 2 risk factors	DSWI with sternal instability	<b>Type III:</b> Months to years	<b>Type C:</b> Wounds involving the whole of the sternum
<b>Type IIIb:</b> Type II + 1 or 2 risk factors			
<b>Type IVa:</b> Type I/III/III after 1 failed therapeutic event			
<b>Type IVb:</b> Type I/II/III after >1 failed therapeutic attempt			
<b>Type V:</b> DSWI presenting for the first time >6wks post-op			

**Table 2**  
Risk factors for the development of DSWI.

Patient factors <sup>6,16–21</sup>	Perioperative factors <sup>17,19,20</sup>	Procedural factors <sup>3,21</sup>	Post-operative factors <sup>6,19,20</sup>
Age	Insufficient skin preparation	Concomitant coronary artery bypass graft	Early operation for re-bleeding
BMI > 30	Prolonged operative time	Non-skeletonised IMA pedicle	Blood transfusion
Smoking	Perioperative blood transfusion	Use of electrocautery	Chest infection
Steroid use	Late admission of prophylactic antibiotics		Prolonged ITU stay
Comorbid disease: Diabetes Osteoporosis Coronary artery disease End stage renal failure Chronic lung disease Chronic infection			

a retrospective analysis of over 3000 patients undergoing bilateral internal mammary artery ( IMA) grafts for myocardial revascularisation, developing a score to predict risk of developing DSWI.<sup>19</sup> This score has been validated, and can be used to aid pre-operative planning in high-risk patients.<sup>19,22</sup> Bilateral use of IMAs is no longer considered to be an independent risk factor, except in patients with poorly controlled diabetes.<sup>23</sup>

### Management principles

General principles of surgical debridement and intravenous antibiotic therapy are widely accepted for the acute phase management of DSWI. Though there has been a movement towards early plastic surgery involvement for flap-based reconstruction, there is no treatment algorithm for managing the multidisciplinary therapy of DSWI, such as is accepted practice for open lower limb fractures with the BOAST 4 criteria from BOA/BAPRAS.<sup>24</sup>

### Acute management

Surgical debridement with deep tissue culture is the first step in the management of DSWI, and should be undertaken as soon as possible following diagnosis. All non-viable tissue should be removed

along with any exposed or infected foreign material. Deep tissue cultures should be obtained to target antibiotic therapy.

The literature generally reports coagulase-negative staphylococci and staphylococcus aureus to be the most common pathogens isolated in DSWI.<sup>25–27</sup> Gram-negative rods are more common in infections which persist following timely debridement and implementation of intravenous antibiotic therapy, and are associated with worse prognosis.<sup>28</sup> Once the diagnosis is suspected, empirical broad-spectrum intravenous antibiotics should be initiated. Once culture results are available, antibiotics should be targeted following microbiology advice.

### **Definitive closure – is there an optimum timing for flap coverage?**

There is little evidence detailing the specific timing of flap reconstruction for DSWI. Many studies advocate the use of negative pressure wound therapy (NPWT) to bridge definitive primary closure or flap reconstruction. New evidence is coming to light, however, suggesting that early or immediate flap reconstruction may improve outcomes. Brandt challenged the cardiothoracic dogma of wound debridement, sternal re-wiring, and antibiotic therapy for managing DSWI; reporting unsatisfactory outcomes with this approach.<sup>29</sup> Brandt undertook a radical change in management by adopting a “plastic surgery approach” with a predetermined plan for immediate sternal debridement plus bilateral pectoralis major advancement flaps. He demonstrated this approach provided rapid, reliable, and effective eradication of deep infection, and advocated the immediate involvement of plastic surgeons.

- Recommendation: Patients benefit from plastic surgery consultation and reconstruction as early as possible. A plastic surgeon should be present at the time of initial debridement following diagnosis of DSWI.

### **NPWT**

In DSWI, use of NPWT has been shown to increase parasternal blood flow and decrease bacterial load, thereby accelerating wound healing and the development of granulation tissue.

Many studies have been reported which provide level 3 evidence for the role of NPWT in the management of DSWI.<sup>30–32</sup> In a 12-year review, Lonie et al. demonstrated NPWT to be associated with a reduced need for flap reconstruction and fewer post-operative complications requiring re-operation after definitive closure.<sup>33</sup> None of the patients in their study treated with NPWT required re-wiring of the sternum, suggesting stabilization of the sternum as an additional benefit.

Studies using NPWT are limited by their retrospective nature; small sample sizes; failure to describe an optimum period for NPWT use; and failure to compare NPWT as a bridge to flap closure with patients treated by primary flap closure. Variations in clinical practice include from early closure within 48 h to multiple re-dressings until microbiology cultures are clear. Furthermore, major complications have been reported with the use of NPWT for post-sternotomy mediastinitis. In one retrospective analysis of 69 patients, 7.2% sustained a major complication during NPWT.<sup>34</sup> All complications were picked up during routine dressing changes; 4 involving bleeding from the CABG, and 1 from an infected homograft of the ascending aorta. The most common cause of major bleeding is right ventricle rupture, with rates of 5.4–14.6%.<sup>35</sup> Sartipy et al. reported 5 cases with a 60% mortality rate.<sup>36</sup> In all cases, pressure was maintained at 125 mmHg, with paraffin gauze beneath polyurethane foam. The authors identified an insufficient number of layers of paraffin gauze or failure to cover the whole right ventricle as potential causative factors, emphasizing the importance of using abundant interface.

- Recommendation: NPWT dressing changes should be performed in theatre every 3–4 days, and flap coverage performed as soon as the patient is suitably stable.

### **Early flap closure**

Novel evidence seems to suggest that early versus delayed flap coverage has better outcomes. A study of 5329 midline sternotomies looking at modifiable factors associated with flap reconstruction

in DSWI found only 2 significant variables; time taken for referral to plastic surgery (median 21-days vs 8-days in infection free group,  $p = 0.02$ ), and time taken to primary flap coverage from time of initial DSWI diagnosis (median 29.5-days vs 12-days in infection free group,  $p = 0.011$ ).<sup>37</sup> No other factors were shown to be associated with DSWI. This provides evidence for early flap cover in DSWI, with each day of delay to flap coverage significantly increasing the risk of chronic infection: an important mortality factor in DSWI.

These findings are supported by a study of single-stage procedures with debridement and immediate bilateral pectoralis major myocutaneous advancement flaps, which demonstrated one of the lowest overall infection rates reported in the literature: 2%.<sup>38</sup> In this series of 114 patients, 107 underwent single-stage treatment with debridement and simultaneous pectoralis major advancement flap closure, with delayed closure reserved only for 7 patients with severe haemodynamic instability or large purulent collection. The authors reported excellent functional and aesthetic outcomes in their patients, alongside low morbidity and mortality (overall 30-day mortality rate of 7.9%, with death unrelated to infection in most cases).

A study using a multivariable logistic regression model to evaluate the relationship between mortality and flap timing found that patients undergoing delayed flap reconstruction had greater odds of mortality compared to patients having earlier flap closure.<sup>39</sup> Controlling for independent variables including patient demographics, treatment characteristics, and risk factors, patients having flap closure 4–7 days and >7 days after DSWI diagnosis had double the predicted probability of death compared to patients having same day, or 1–3 days later closure. Delayed flap timing > 4 days after DSWI diagnosis was associated with an increased number of procedures, and longer hospital stay. The timing of initial debridement and type of flap used did not significantly impact mortality. This study, though limited by retrospective design and loss of some clinical information such as wound size and number of debridements prior to flap closure, highlights the relationship between early flap coverage and lower mortality rate, hospital days, and costs compared to patients with prolonged time between DSWI diagnosis and flap coverage. Cabbabe et al. demonstrated similar findings, with early debridement and bilateral pectoralis muscle flap reconstruction associated with a significantly reduced hospital stay, morbidity and mortality compared to patients with delayed reconstruction.<sup>40</sup>

These studies provide level 3 evidence in support of the role of early flap closure in the management of DSWI.

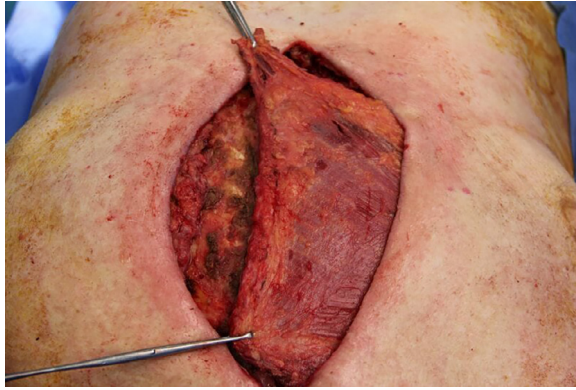
- Recommendation: The aim in management of DSWI should be for early flap closure. If flap coverage is not possible at initial debridement due to instability of the patient, then – and only then – should NPWT be used alongside aggressive IV antibiotic therapy for interval wound therapy, with plan for delayed closure.

## Flap choice

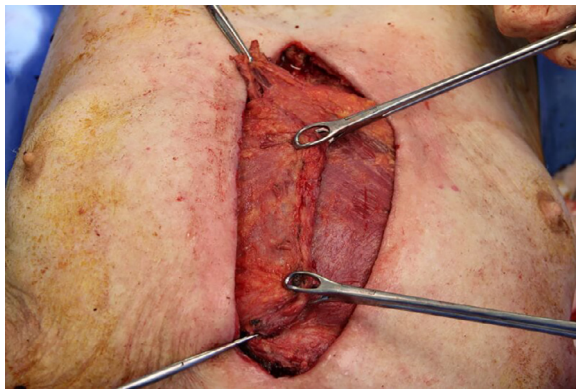
There are a variety of flap options for reconstructing sternal wounds following debridement in DSWI. Depending on the size of the sternal defect, single flaps often do not have the capacity to resurface entirely, or obliterate dead space in the chest after debridement. Flaps are therefore often used in tandem. The pectoralis major (PM) flap is the workhorse flap for sternal reconstruction, with several authors today considering this flap as the primary choice for wound closure.<sup>42,43</sup> Besides the PM flap, the rectus abdominis, latissimus dorsi, and greater omentum have also been described in the reconstruction of sternal wounds.

## Pectoralis major flap

The PM flap was first described for use in the setting of DSWI by Jurkiewics in the 80's,<sup>41</sup> It can be used as either a unilateral or bilateral flap depending on the defect size, and has the benefit of avoiding a second surgical incision. Though traditionally described for proximal sternal defects, the rectus fascia can be incorporated with the lower part of the PM to reconstruct defects involving the lower third (Figure 1), and to facilitate further advancement one can detach it from its humeral origin via an incision in the deltopectoral groove. Double-breasting the flaps can improve sternal stability, further obliterating dead-space (Figure 2).



**Figure 1.** Incorporating the rectus fascia with bilateral PM flaps to reconstruct a large sternal defect extending into the lower third. (PM, pectoralis major).



**Figure 2.** Double-breasting of the flaps to improve sternal integrity.

The PM flap has also been described as a turnover flap based on perforators of the IMA. (IMAP flap) to reconstruct larger defects, using a muscle-splitting approach to increase its versatility, and decreasing the likelihood of needing additional flaps to achieve sternal coverage.<sup>44</sup> This is only possible if the IMAs have not been harvested as bypass grafts. With the muscle-splitting approach one can better cover the lower 1/3 of the sternal wound, which is often an issue with the use of the standard PM flap. Zahiri et al. demonstrated the turnover flap to be associated with less postoperative complications when compared to the standard PM flap – predominantly attributed to its superior ability to fill the sternal defect.<sup>45</sup> Kannan reported a series of 7 patients undergoing sternal reconstruction with an IMAP flap, describing its ability to reconstruct the entire length of the sternotomy wound with relatively minimal dissection and morbidity compared to the traditional PM advancement flap.<sup>46</sup>

- Recommendation: The PM flap is a reliable flap for superior 2/3 sternal defects. It can be used in the absence of the IMA as an advancement flap, or as a perforator flap where the IMA is present to increase its excursion for the reconstruction of larger defects.

### **Rectus abdominis flap**

Rectus abdominis (RA) muscle flaps are ideal for use in reconstructing the lower third of the sternum. This flap is based on the superior inferior epigastric artery (SIEA), requires simple dissection, and has a wide arc of rotation. It can be raised as a muscle only or myocutaneous flap with either a

vertical or transverse skin paddle. Donor site hernia is a possibility, though this risk can be reduced by leaving the rectus fascia in place and performing a two-layered closure.<sup>47</sup> Donor site breakdown can occur owing to the major disruption of the blood supply to the abdominal skin.

Bilateral harvesting of the IMA has been reported to be a concern with the use of the RA flap, however Netscher et al. suggested that the viability of the RA flap can be reliably maintained in the face of ipsilateral IMA harvest if elevation of the flap and division of the lateral segmental perforators is performed only to the costal margin.<sup>48</sup> The use of the RA flap based on an intercostal artery pedicle has also been described for cases where there is no IMA inflow. In a retrospective study of 15 cases over a span of 15 years, the authors reported optimal flap survival, with the avoidance of donor site wound complications due to preservation of the IEA.<sup>49</sup> Fernando et al also reported that a musculocutaneous flap can be raised solely on the eight intercostal perforator.<sup>50</sup> Anastomosing the IEA to the intercostal artery or IMA perforator to create an RA flap with a dual blood supply in cases where either a single or both IMAs have been used for the bypass graft has also been described, with no reported complications of distal flap necrosis, and all flaps healing without recurrence of infection.<sup>51</sup> This study is limited however by the very small sample size, and therefore it is not possible to draw any strong conclusions from this data.

The RA flap can also be incorporated with the PM flap. In a study of 130 patients in which outcomes with both flaps were directly compared, a high rate of success (85% in the modified PM flap integrated with rectus fascia group; 86% in the stand-alone RA flap) was found with both flaps.<sup>52</sup> There was, however, a significantly higher rate of complications in the modified PM flap group as compared to the stand-alone RA flap group. The authors therefore suggested the stand-alone RA flap to be a superior choice for DSWI in the region of the lower third of the sternum.

- Recommendation: The RA flap is the best choice for reconstruction of defects of the lower third of the sternum.

### **Latissimus dorsi flap**

The latissimus dorsi (LD) flap remains an option in the case of bilateral IMA harvest with poor perforators. This flap has the added advantage of simple dissection, and not disrupting the blood supply to the sternal and parasternal tissues.<sup>53</sup> It can be used to close large sternal defects, and can be performed simultaneously for reconstruction at initial debridement. In a recent study by Spindler et al. of 106 cases of LD reconstruction post DSWI, the flap was shown to be reliable with only small adverse effects in shoulder function and strength, and pulmonary function.<sup>54</sup> It is a less favoured option however owing to the need to reposition the patient during the procedure.

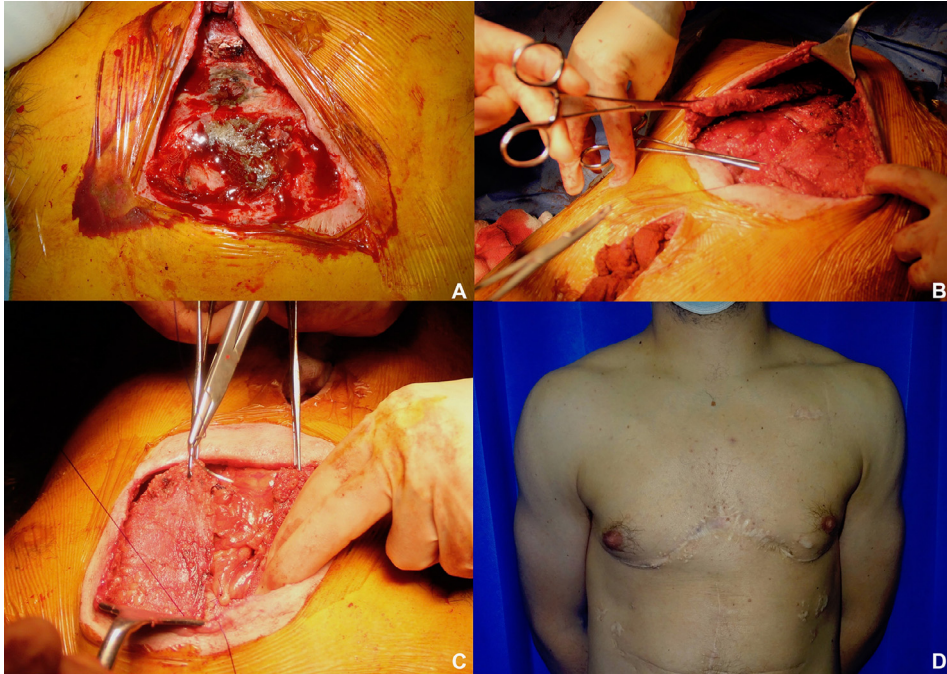
- Recommendation: The LD flap is a reliable back-up option for superior sternal defects. It is less favourable due to donor site morbidity and the need to reposition the patient intra-operatively.

### **Greater omentum flap**

The greater omentum flap is often chosen as a secondary reconstructive option where PM or RA flaps are not an option, or for salvage and in cases where significant dead space needs obliteration. Harvested on the gastroepiploic artery, the omentum flap has a rich vascular supply with long pedicle, and contours well to irregular defects. In contrast to muscle flaps, it exhibits noteworthy immunologic properties, with the direct contact and excellent perfusion of the omentum allowing for improved local nutrition and penetration of antibiotics to surrounding tissue. The omental flap readily accepts a skin graft without needing to wait for granulation tissue. Though it requires an additional surgical site with a diaphragmatic incision, the minimally invasive laparoscopic approach reduces risks (Figure 3).

When comparing omental flap use with the PM flap, several studies seem to suggest its superiority, providing level 3 evidence.<sup>55–57</sup> It has also been described to supplement bilateral PM advancement flaps to reconstruct the inferior parts of infected sternal wounds, with low mortality rates.<sup>58</sup> It is a reliable flap for managing recurrent DSWI after alternative treatments have failed.<sup>59</sup>

- Recommendation: The omentum flap is a good option for salvage, or in combination with other flaps to obliterate deadspace.



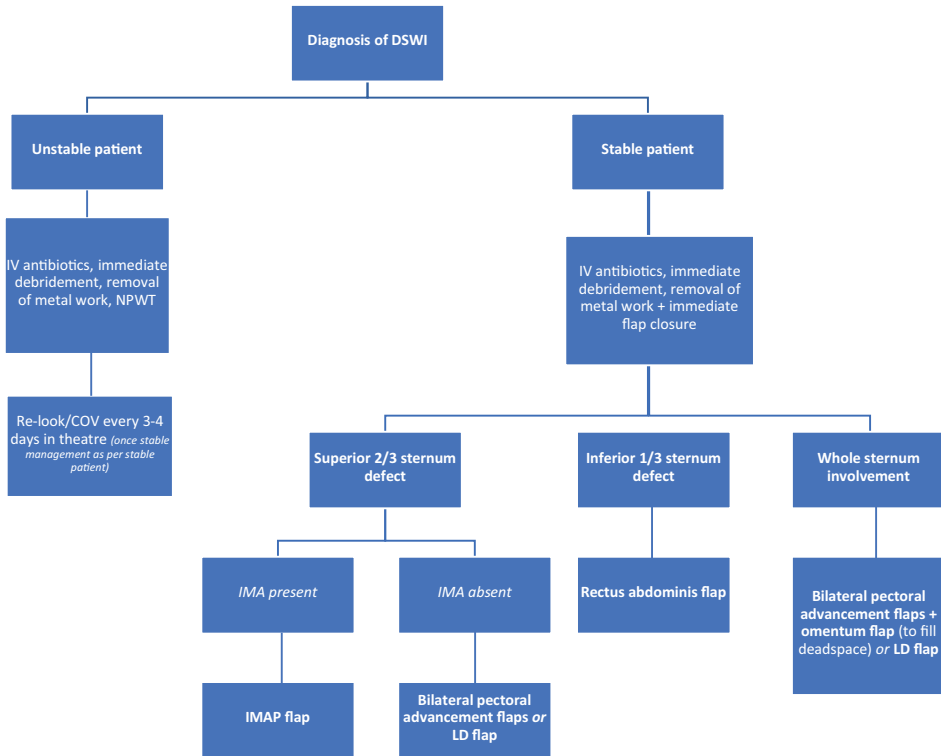
**Figure 3.** A, sternal defect following the development of DSWI in a cystic fibrosis patient post bilateral sequential lung transplant. B, abdominal incision for the raising of pedicled omentum flap to fill the deadspace. C, double breasting of PM flaps to cover the omentum. D, appearance of wound 6 months post-operatively. (DSWI, deep sternal wound infection. PM, pectoralis major).

### Flap closure vs rigid fixation

While flap closure of the sternum is regarded as the gold standard in DSWI where there is inadequate bone following debridement or uncertainty whether the infectious process has been controlled, primary rigid fixation where bone quality is adequate is an option. Gottlieb et al. found that often after debridement for DSWI, the remaining bone is viable and vascularized; suggesting that rigid fixation could be part of the primary reconstructive process.<sup>60</sup> In a series of 40 consecutive patients, Fawzy et al. demonstrated sternal plating to be an effective option for treating of DSWI associated with sternal instability.<sup>61</sup> Douville et al. suggested that preservation of the sternum with sternal rewiring and leaving the wound to heal by secondary-intention, or with delayed flap closure, leads to lower mean infection time, less primary re-operation, and lower risk of morbidity/mortality if future cardiac re-operation is required.<sup>62</sup> They favoured this approach as it made latter cardiac re-operation safer, particularly in cardiac bypass graft procedures, by maintaining a plane between the sternum and heart. They argued the sternum should only be left open in patients with a necrotic, irradiated chests, or multi-fractured sternums, while all other patients should primarily be treated with sternal re-wiring and delayed primary closure.

In another study comparing different strategies for DSWI, the authors found use of the titanium sternal plating system (TSFS) to be associated with a statistically significant shorter hospitalisation period and lower mortality rate with less re-interventions when compared to the musculocutaneous flap closure (MFC) group.<sup>63</sup> Patient reported quality of life was also significantly elevated. The authors therefore concluded the TSFS to be a feasible and safe alternative in DSWI. This study is limited however by its retrospective nature and small sample size, and failure to match patients according to severity of DSWI. Though both patient groups were similar in terms of demographics before cardiac surgery, they developed differently in the period between cardiac surgery and final sternal stabiliza-





**Figure 4.** DSWI reconstructive algorithm. Algorithm for the acute management and surgical reconstruction in DSWI based on an analysis of the literature and consideration of the anatomical defect. (DSWI, deep sternal wound infection. COV, change of vac dressing.).

tion, in favour of the TSFS group. There was a statistically significant difference in the number of VAC changes between debridement and closure in the MFC group as compared to the TSFS group, and therefore one could argue worse infection in this group. There was also a prolonged time between initial cardiac surgery and final reconstruction in the MFC group as compared to the TSFS group. Arguably this study therefore merely demonstrates TSFS to be a potential safe option in DSWI, which can be considered in select patients, with MFC remaining the gold standard treatment choice for complicated cases with severe infection.

- Recommendation: Where bone quality post-debridement is adequate, sternal fixation with re-wiring or plating may result in improved sternal stability compared to flap closure alone, and should be considered as an option, though flap closure remains the gold standard option.

**The ‘fix and flap’ approach**

Other studies have demonstrated success in using a primary ‘fix and flap’ approach. Pancholy & Raman performed a retrospective analysis of 14 patients who underwent sternal reconstruction with plate fixation and use of bone morphogenetic protein and demineralized bone matrix for remaining sternal defects, followed by pectoral myocutaneous flap closure.<sup>64</sup> At 6-months post-op they reported all patients to have stable chest walls with no further sternal instability, and no recurrence of dehiscence or wound infection. Several other authors have similarly described good outcomes with the use of a simultaneous sternal plating and PM advancement flap approach, suggesting this method to be associated with earlier extubation, low incidence of recurrence, and high sternal integrity.<sup>65,66</sup> In

**Table 3**  
Summary of key evidence-based recommendations.

Evidence-based recommendations:
<ul style="list-style-type: none"> <li>• Patients benefit from plastic surgery consultation and reconstruction as early as possible. We suggest that a plastic surgeon should be present at the time of initial debridement following diagnosis of DSWI, as with best practice guidelines for management of open lower limb fractures.</li> <li>• The aim in management of DSWI should be for early flap closure. If flap coverage is not possible at initial debridement due to instability of the patient, then – and only then – should NPWT be used alongside aggressive IV antibiotic therapy for interval wound therapy, with plan for delayed closure.</li> <li>• NPWT dressing changes should be performed in theatre every 3–4 days, and flap coverage performed as soon as the patient is suitably stable.</li> <li>• Many options for flap reconstruction exist. Careful pre-operative planning should consider anatomical location of dehiscence and the presence/absence of uni/bilateral IMA graft to guide reconstructive options, as the transferred tissue must have optimal blood supply in order to overcome the infection.</li> <li>• The best flap option immediately available should be used, avoiding any unnecessary additional surgical incisions.</li> <li>• The PM flap is a reliable flap for superior 2/3 sternal defects. It can be used in the absence of the IMA as an advancement flap, or as a perforator flap where the IMA is present to increase its excursion for the reconstruction of larger defects.</li> <li>• The RA flap is the best choice for reconstruction of defects of the lower third of the sternum.</li> <li>• The LD flap is a reliable back-up option for superior sternal defects. It is less favourable due to donor site morbidity and the need to reposition the patient intra-operatively.</li> <li>• The omentum flap is a good option for salvage, or in combination with other flaps to obliterate deadspace.</li> <li>• Where bone quality post-debridement is adequate, sternal fixation with re-wiring or plating may result in improved sternal stability compared to flap closure alone, and should be considered as an option, though flap closure remains the gold standard option.</li> </ul>

a large 15-year review of 92 patients, Baillot et al. reported decreased perioperative mortality in patients treated with VAC followed by TSFS and pectoralis major flaps compared with isolated muscle flaps.<sup>67</sup> It is unclear, however, whether these findings are related to VAC use or the use of TSFS, as significantly, the isolated muscle flap group were not treated with VAC therapy. Further studies need performing in this area.

## Discussion

Several approaches to the treatment of DSWI have been described, with no real consensus as to the single best specific treatment methodology. Early identification with initiation of broad spectrum IV antibiotic therapy and urgent surgical debridement is key, and a common theme in clinical practice. Timing for definitive closure, however, is a subject of contention. Some authors advocate interval NPWT with delayed closure, particularly in patients in whom early closure of the chest may not be possible due to patient instability with poor pulmonary or cardiac reserve, or need for serial debridement. There is no consensus regarding the interval to wound closure with the use of NPWT.

With recent literature demonstrating the success of early flap coverage with low incidence of recurrent infection or flap failure when used in combination with aggressive antibiotic therapy, delayed closure may not be necessary in most patients. Large variations have been demonstrated, however, in regard to method of definitive closure. This may be due in part to the fact that none of the early classification systems described for DSWI directly guide reconstructive options. Greig et al. tried to address this issue by proposing an anatomical classification to help guide flap choice based on site of infection.<sup>15</sup> We utilize this classification, with slight modification based on our review of the literature and the author's own experience in this area, to create a robust reconstructive algorithm (Figure 4). With this algorithm, we recognize that the optimum flap strategy is not standardized, but varies according to the expertise of the surgeon, the location of the defect, and the local vascular supply.

A 'fix and flap' approach has recently been described in the literature. Such studies suggest that a combination of rigid sternal plate fixation with flap reconstruction when compared to isolated flap reconstruction may produce greater results in terms of sternal stability and quality of life in patients who are assessed to have adequate bone quality at the time of debridement, though evidence here

is limited. Further large-scale, ideally randomized controlled studies are therefore necessary to determine whether this option is the most effective way to achieve sternal stability and long-term soft tissue when compared to flap reconstruction alone.

Considering the findings of our literature review and the authors' own experience in this area, we provide evidence-based recommendations (Table 3).

## Conclusion

DSWI is a potentially life-threatening complication of cardiac surgery. Despite the low incidence, DSWI-related morbidity, mortality, and costs are extremely high; and an aggressive approach is therefore necessary. Early identification of high-risk patients along with instigation of preventative measures is paramount. Treatment involves a combination of early antibiotic therapy and early consultant plastic and cardiothoracic surgeon input; with the multidisciplinary approach key to delivery of the best results. Discussion with the plastic surgery team should take place as soon as diagnosis is made to enable surgical planning with consideration for early flap closure, with or without sternal plating. Where NPWT is used, this should be used for as short a period as possible, and plastic surgery coverage performed as early as possible.

Future research efforts should focus on establishing a joint BAPRAS-Cardiothoracic Society guideline for DSWI to parallel the BOA-BAPRAS approach to open lower limb trauma, with the main points of focus being multidisciplinary care, planning, and appropriate treatment of DSWI. Large scale RCTs will aid in the development of a validated standard of care.

## Declaration of Competing Interest

None.

## Funding

None.

## Ethical approval

Not required.

## References

- Horan TC, Andrus M, Dudeck MA. CDC/NHSN surveillance definition of healthcare-associated infection and criteria for specific types of infections in the acute care setting. *Am J Infect Control*. 2008;36(5):309–332.
- Eklund AM, Lyytikäinen O, Klemets P, et al. Mediastinitis after more than 10,000 cardiac surgical procedures. *Ann Thorac Surg*. 2006;82:1784–1789.
- Kubota H, Miyata H, Motomura N, et al. Deep sternal wound infection after cardiac surgery. *J Cardiothorac Surg*. 2013;8(1):132.
- Salehi Omran A, Karimi A, Ahmadi SH, et al. Superficial and deep sternal wound infection after more than 9000 coronary artery bypass graft (CABG): incidence, risk factors and mortality. *BMC Infect Dis*. 2007;7(1):112.
- Force SD, Miller DL, Petersen R, et al. Incidence of deep sternal wound infections after tracheostomy in cardiac surgery patients. *Ann Thorac Surg*. 2005;80(2):618–622.
- Ridderstolpe L, Gill H, Granfeldt H, Ahlfeldt H, Rutberg H. Superficial and deep sternal wound complications: Incidence, risk factors and mortality. *Eur J Cardiothorac Surg*. 2001;20(6):1168–1175.
- Tang AT, Ohri SK, Haw MP. Novel application of vacuum assisted closure technique to the treatment of sternotomy wound infection. *Eur J Cardiothorac Surg*. 2000;17:482–484.
- Lazar HL, Vander Salm T, Engelman R, Orgill D, Gordon S. Prevention and management of sternal wound infection. *J Thorac Cardiovasc Surg*. 2016;152:962–972.
- Sears ED, Wu L, Waljee JF, Momoh AO, Zhong L, Chung KC. The impact of deep sternal wound infection on mortality and resource utilization: a population-based study. *World J Surg*. 2016;40(11):2673–2680.
- El Oakley RM, Wright JE. Postoperative mediastinitis: Classification and management. *Ann Thorac Surg*. 1996;61:1030–1036.
- Horan TC, Gaynes RP, Martone WJ, Jarvis WR, Emori TG. CDC definitions of nosocomial surgical site infections, 1992: A modification of CDC definitions of surgical wound infections. *Infect Control Hosp Epidemiol*. 1992;13(10):606–608.
- van Wingerden JJ, de Mol BA, van der Horst CM. Defining post-sternotomy mediastinitis for clinical evidence-based studies. *Asian Cardiovasc Thorac Ann*. 2016;24:355–363.

13. Rupperecht L, Schmid C. Deep sternal wound complications: An overview of old and new therapeutic options. *Open J Cardiovasc Surg.* 2013;6:9–19.
14. Pairolero PC, Arnold PG. Management of recalcitrant median sternotomy wounds. *J Thorac Cardiovasc Surg.* 1984;88:357–364.
15. Greig AV, Geh JL, Khanduja V, et al. Choice of flap for the management of deep sternal wound infection: an anatomical classification. *J Plast Reconstr Aesthet Surg.* 2007;60:372–378.
16. Ariyaratnam P, Bland M, Loubani M. Risk factors and mortality associated with deep sternal wound infections following coronary bypass surgery with or without concomitant procedures in a UK population: A basis for a new risk model? *Interact Cardiovasc Thorac Surg.* 2010;11(5):543–546.
17. Floros P, Sawhney R, Vrtik M, et al. Risk factors and management approach for deep sternal wound infection after cardiac surgery at a tertiary medical centre. *Heart Lung Circ.* 2011;20(11):712–717.
18. Cutrell JB, Barros N, McBroom M, et al. Risk factors for deep sternal wound infection after cardiac surgery: Influence of red blood cell transfusions and chronic infection. *Am J Infect Control.* 2016;44(11):1302–1309.
19. Gatti G, Dell'Angela L, Barbatì G, Benussi B, Forti G, Gabrielli M, et al. A predictive scoring system for deep sternal wound infection after bilateral internal thoracic artery grafting. *Eur J Cardiothorac Surg.* 2016;49:910–917.
20. Centofanti P, Savia F, La Torre M, et al. A prospective study of prevalence of 60-days postoperative wound infections after cardiac surgery: An updated risk factor analysis. *J Cardiovasc Surg (Torino).* 2007;48:641–646.
21. Oliviera Sa M, Ferraz P, Soares A, et al. Development and validation of a stratification tool for predicting risk of deep sternal wound infection after coronary artery bypass grafting at a Brazilian hospital. *Braz J Cardiovasc Surg.* 2017;32(1):1–7.
22. Gatti G, Perrotti A, Santarpino G, Biancari F. *Recent Clinical Techniques, Results, and Research in Wounds.* The Gatti score and the risk of deep sternal wound infection after bilateral internal thoracic artery grafting. Cham: Springer; 2018.
23. Itagaki S, Cavallaro P, Adams DH, Chikwe J. Bilateral internal mammary artery grafts, mortality and morbidity: an analysis of 1 526 360 coronary bypass operations. *Heart.* 2013;99:849–853.
24. British orthopaedic association & British association of plastic, reconstructive & aesthetic surgeons audit standards for trauma – open fractures. Dec 2017. Accessed via: <https://www.boa.ac.uk/resources/boast-4-pdf.html>.
25. Gärdlund B, Bitkover CY, Vaage J. Postoperative mediastinitis in cardiac surgery – microbiology and pathogenesis. *Eur J Cardiothorac Surg.* 2002;21(5):825–830.
26. Chen LF, Arduino JM, Sheng S, et al. Epidemiology and outcome of major postoperative infections following cardiac surgery: Risk factors and impact of pathogen type. *Am J Infect Control.* 2012;40(10):963–968.
27. Chan M, Yusuf E, Giulieri S, et al. A retrospective study of deep sternal wound infections: clinical and microbiological characteristics, treatment, and risk factors for complications. *Diagn Microbiol Infect Dis.* 2016;84(3):261–265.
28. Charbonneau H, Maillet JM, Faron M, et al. Mediastinitis due to Gram negative bacteria is associated with increased mortality. *Clin Microbiol Infect.* 2014;20(3):197–202.
29. Brandt C, Alvarez J. First-line treatment of deep sternal wound infection with a plastic surgery approach: Superior results compared with a conventional cardiac surgery orthodoxy. *PRS.* 2002;109(7):2231–2237.
30. Raja SG, Berg GA. Should vacuum-assisted closure therapy be routinely used for management of deep sternal wound infection after cardiac surgery? *Interact Cardiovasc Thorac Surg.* 2007;6:523–526.
31. Steingrimsson S, Gottfredsson M, Gudmundsdottir I, et al. Negative-pressure wound therapy for deep sternal wound infections reduces the rate of surgical interventions for ear re-infections. *Int Cardiovasc Thor Surg.* 2012;15:406–410.
32. Fuchs V, Zittermann A, Stuetgen B, et al. Clinical outcome of patients with deep sternal wound infection managed by vacuum-assisted closure compared to conventional therapy with open packing: A retrospective analysis. *Ann Thorac Surg.* 2005;79:516–521.
33. Lonie S, Hallam J, Yui M, et al. Changes in the management of deep sternal wound infections: A 12-year review. *ANZ J Surg.* 2015;85:878.
34. Petzina R, Malmsjo M, Stamm C, Hetzer R. Major complications of negative pressure wound therapy in poststernotomy mediastinitis after cardiac surgery. *J Thor Cardiovasc Surg.* 2010;140(5):1133–1136.
35. Thorsteinsson DT, Valsson F, Geirsson A, Gudbjartsson T. Major cardiac rupture following surgical treatment for deep sternal wound infection. *Interact Cardiovasc Thorac Surg.* 2013;16:708–709.
36. Sartipy U, Lockowandt U, Gabel J, Jideus L, Dellgren G. Cardiac rupture during vacuum-assisted closure therapy. *Ann Thorac Surg.* 2006;82:1110–1111.
37. Lo S, Hutson K, Hallam MJ, et al. The importance of early flap coverage in deep sternal wounds. *Ann Plast Surg.* 2014;73(5):588–590.
38. Ascherman JA, Patel BA, Malhotra SM, et al. Management of sternal wounds with bilateral pectoralis major myocutaneous advancement flaps in 114 consecutively treated patients: refinements in technique and outcomes analysis. *Plast Reconstr Surg.* 2004;114:676Y683.
39. Sears E, Momoh A, Chung K, Lu Y, Zhong L, Waljee J. A national study of the impact of delayed flap timing for the treatment of patients with deep sternal wound infection. *Plast Reconstr Surg.* 2017;140(2):390–400.
40. Cabbabe EB, Cabbabe SW. Immediate versus delayed one-stage sternal debridement and pectoralis muscle flap reconstruction of deep sternal wound infections. *Plast Reconstr Surg.* 2009;123:1490–1494.
41. Jurkiewicz MJ, Bostwick J, Hester TR, Bishop JB, Craver J. Infected median sternotomy wound successful treatment by muscle flaps. *Ann Surg.* 1980;191:738–744.
42. Cabbabe EB, Cabbabe SW. Surgical management of the symptomatic unstable sternum with pectoralis major muscle flaps. *Plast Reconstr Surg.* 2009;123:1495.
43. Ascherman JA, Patel SM, Malhotra SM, Smith CR. Management of sternal wounds with bilateral pectoralis major myocutaneous flaps in 114 consecutively treated patients: refinements in technique and outcome analysis. *Plast Reconstr Surg.* 2004;114:676–683.
44. Li EN, Goldberg NH, Slezak S, Silverman RP. Split pectoralis major flaps for mediastinal wound coverage: A 12-year experience. *Ann Plast Surg.* 2004;53(4):334–337.
45. Zahiri HR, Lumpkins K, Kelishadi S, Stromberg JA, Silverman RP, Slezak S, et al. Pectoralis major turnover versus advancement technique for sternal wound reconstruction. *Ann Plast Surg.* 2013;70(2):211–215 2013.

46. Kannan R. The IMA perforator flap and its subtypes in the reconstruction of median sternotomy wounds. *J Thorac Cardiovasc Surg.* 2016;192(1):264–268.
47. Davison SP, Clemens MW, Armstrong D, et al. Sternotomy wounds: Rectus flap versus modified pectoral reconstruction. *Plast Reconstr Surg.* 2007;120:929–934.
48. Netscher DT, Eladoumikdachi F, Goodman CM. Rectus abdominis muscle flaps used successfully for median sternotomy wounds after ipsilateral internal mammary artery ligation. *Ann Plast Surg.* 2001;47:223–228.
49. Jacobs B, Gherzi M. Intercostal artery-based rectus abdominis transposition flap for sternal wound reconstruction. *Ann Plast Surg.* 2008;60(4):410–415.
50. Fernando B, Myszyński C, Mustoe T. Closure of a sternal defect with the rectus abdominis muscle after sacrifice of both internal mammary arteries. *Ann Plast Surg.* 1988;21:468–471.
51. Li Y, Zheng Z, Yang J, Su L, Liu Y, Han F, et al. Management of the extensive thoracic defects after deep sternal wound infection with the rectus abdominis myocutaneous flap. A retrospective case series. *Medicine.* 2017;96(16):1–5.
52. Davison S, Clemens MW, Armstrong D, Newton ED, Swartz W. Sternotomy wounds: Rectus flap vs. modified pectoral reconstruction. *PRS.* 2007;120(4):929–934.
53. Dejesus RA, Paletta JD, Dabb RW. Reconstruction of the median sternotomy wound dehiscence using the latissimus dorsi myocutaneous flap. *J Cardiovasc Surg.* 2001;42:359–364.
54. Spindler N, Kade S, Siegl U, et al. Deep sternal wound infection – latissimus dorsi reconstruction is a reliable option for reconstruction of the thoracic wall. *BMC Surg.* 2019;19:173.
55. Yasuura K, Okamoto H, Morita S, et al. Results of omental flap transposition for deep sternal wound infection after cardiovascular surgery. *Ann Surg.* 1998;227:455–459.
56. Milano CA, Georgiade G, Muhlbaier LH, Smith PK, Wolfe WG. Comparison of omental and pectoralis flaps for poststernotomy mediastinitis. *Ann Thorac Surg.* 1999;67:377.
57. Van Wingerden J, Lapid O, Boonstra PW, et al. Muscle flaps or omentum flaps in the management of deep sternal wound infection. *Interact Cardiovasc Vasc Surg.* 2011;13:179–188.
58. Spartalis E, Markakis C, Moris D, Lachanas E, Agathos E. Results of the modified bipectoral muscle flap procedure for post-sternotomy deep wound infection. *Surg Today.* 2016;46:460–465.
59. Spindler N, Etz CD, Misfield M, et al. Omentum flap as a salvage procedure in deep sternal wound infection. *Ther Clin Risk Manag.* 2017(13):1077–1083.
60. Gottlieb L J, Pielet R W, Karp R B, Krieger L M, Smith D J, Jr Deeb G M. Rigid internal fixation of the sternum in postoperative mediastinitis. *Arch Surg.* 1994;129:489–493.
61. Fawzy H, Osei-Tutu K, Erret L, et al. Sternal plate fixation for sternal wound reconstruction: Initial experience (Retrospective study). *J Cardiothorac Surg.* 2011;6(63).
62. Douville EC, Asaph JW, Dworkin RJ, Handy JR, Canepa CS, Grunkemeier GL, et al. Sternal preservation: A better way to treat most sternal wound complications after cardiac surgery. *Ann Thorac Surg.* 2004;78:1659–1664.
63. Grapow M, Haug M, Tschung C, Winkler B, Banerjee P, Heinisch PP, et al. Therapy options in deep sternal wound infection: Sternal plating versus muscle flap. *PLOS ONE.* 2017;12(6):e0180024. doi:10.1371/journal.pone.0180024.
64. Pancholy B, Raman J. Chest wall reconstruction using sternal plating in patients with complex sternal dehiscence. *Ann Thorac Surg.* 2015;99:2228–3.
65. Proffitt R, Boone A, St John J. Comparison of the treatment of sternal infections by flap reconstruction versus rigid transverse titanium plate fixation by one surgeon in one hundred forty nine consecutive cases over thirteen years. *PRS.* 2004;134:139–140.
66. Cicilioni OJ, Stieg FH, Papanicolaou G. Sternal wound reconstruction with transverse plate fixation. *Plast Reconstr Surg.* 2005;115:1297.
67. Baillot R, Cloutier C, Montalin L, Cote L, Lellouche F, Houde C, et al. Impact of deep sternal wound infection management with vacuum-assisted closure therapy followed by sternal osteosynthesis: A 15-year review of 23,499 sternotomies. *Eur J Cardiothorac Surg.* 2010;37:880–887.