



Received: 2016.03.21  
Accepted: 2016.05.05  
Published: 2016.12.01

Authors' Contribution:

- A** Study Design
- B** Data Collection
- C** Statistical Analysis
- D** Data Interpretation
- E** Manuscript Preparation
- F** Literature Search
- G** Funds Collection

## Primary Hydatid Cyst of the Brain in a Child: A Case Report

Alessia Imperato\*<sup>1</sup> Alessandro Consales\*<sup>2</sup>, Marcello Ravegnani<sup>2</sup>,  
Elio Castagnola<sup>3</sup>, Roberto Bandettini<sup>4</sup>, Andrea Rossi<sup>5</sup>

<sup>1</sup> Department of Neurosciences and Reproductive and Odontostomatological Sciences, Division of Neurosurgery, Università Degli Studi Federico II, Naples, Italy

<sup>2</sup> Neurosurgery Unit, Istituto Giannina Gaslini, Genoa, Italy

<sup>3</sup> Infectious Diseases Unit, Istituto Giannina Gaslini, Genoa, Italy

<sup>4</sup> Laboratory Analysis Unit, Istituto Giannina Gaslini, Genoa, Italy

<sup>5</sup> Neuroradiology Unit, Istituto Giannina Gaslini, Genoa, Italy

\* Equally contributing authors

**Author's address:** Alessia Imperato, Department of Neurosciences and Reproductive and Odontostomatological Sciences, Division of Neurosurgery, Università degli studi Federico II, Via Pansini 5, 80131, Naples, Italy,  
e-mail: alessia.imperato@gmail.com

### Summary

**Background:**

Primary intracranial hydatid cyst is a rare location of human echinococcosis whose spontaneous, traumatic or even iatrogenic rupture, as in case of misdiagnosis, may cause anaphylactic reactions and dissemination.

**Case Report:**

We discuss the management of a 9-year-old boy who was admitted to our Emergency Department with an intracranial hypertension syndrome. Head CT scan and brain MRI showed a huge intra-axial right temporo-parieto-occipital cyst with a marginal calcification, associated with left ventricular uncompensated hydrocephalus. DTI showed displacement of the ipsilateral corticospinal tract, whereas MR spectroscopy showed absence of normal brain metabolites and presence of succinate and lactate within the cyst. A diagnosis of hydatid cyst was then presumed on the basis of the neuroradiological findings. Empiric chemotherapy with albendazole was instituted and surgical en bloc removal of the cyst was obtained, allowing the patient to recover without complications. Diagnosis of brain echinococcosis was confirmed by laboratory tests.

**Conclusions:**

HE is still an endemic manifestation in some rural areas of the world, and it should be included in the differential diagnosis of children living in or coming from an endemic country who present with an intracerebral cyst. Early diagnosis and complete surgical removal of the intact cyst are the main factors that determine a favourable outcome.

**MeSH Keywords:**

Brain Diseases • Child • Echinococcosis

**Abbreviations:**

HE – human echinococcosis; CT – computed tomography; MRI – magnetic resonance imaging; CSF – cerebrospinal fluid; DTI – diffusion-tensor imaging

**PDF file:**

<http://www.polradiol.com/abstract/index/idArt/898619>

### Background

Primary intracranial hydatid cyst is a rare location of human echinococcosis (HE), a parasitic disease caused by

metacestodes (larval forms) of *Echinococcus granulosus* [1]. HE usually affects the liver asymptotically; when present, symptoms are nonspecific and correlate with cyst growth and compression of adjacent structures [2].

Spontaneous or traumatic (including surgical) cyst rupture may cause anaphylactic reactions and dissemination [3,4]. We present the case of a giant primary intracerebral hydatid cyst in a child, discussing its surgical management and analyzing the recent literature on the topic.

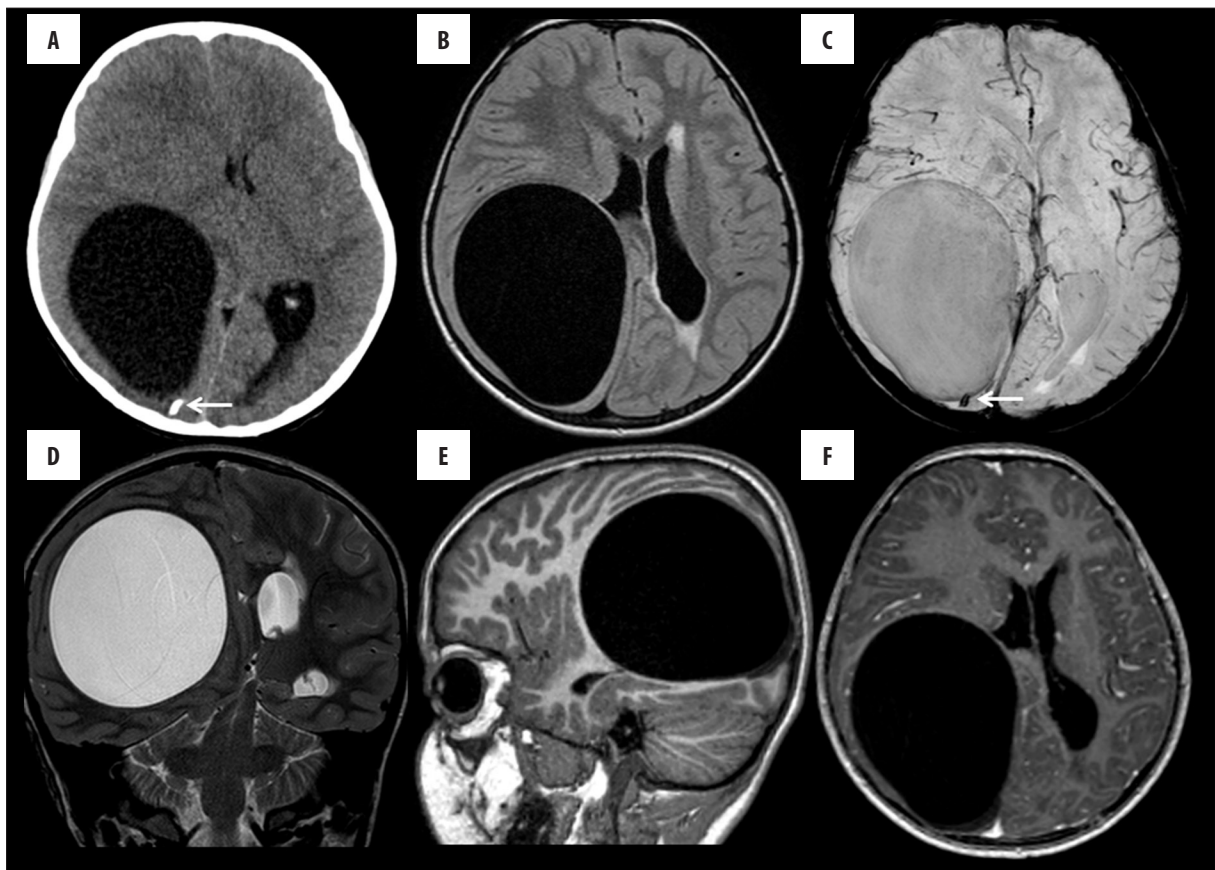
### Case Report

We examined a 9-year-old boy who recently immigrated from a rural area of Albania, who complained of severe long-standing headache and diplopia. He was alert and conscious but asthenic, without sensorimotor deficits. Fundoscopy revealed left papilledema, while routine blood tests, chest X-rays, and abdominal ultrasound were unremarkable. Cardiac ultrasound revealed a patent Botallo duct with left-to-right shunt. Head computed tomography (CT) scan showed a huge intra-axial right temporo-parieto-occipital hypodense cyst with marginal calcification. Brain magnetic resonance imaging (MRI) confirmed the cyst to be isointense with cerebrospinal fluid (CSF) and causing marked mass effect, contralateral displacement of the midline structures, and left ventricular uncompensated hydrocephalus (Figure 1). Diffusion-tensor imaging (DTI) showed displacement of the ipsilateral corticospinal tract, whereas MR spectroscopy showed absence of normal brain

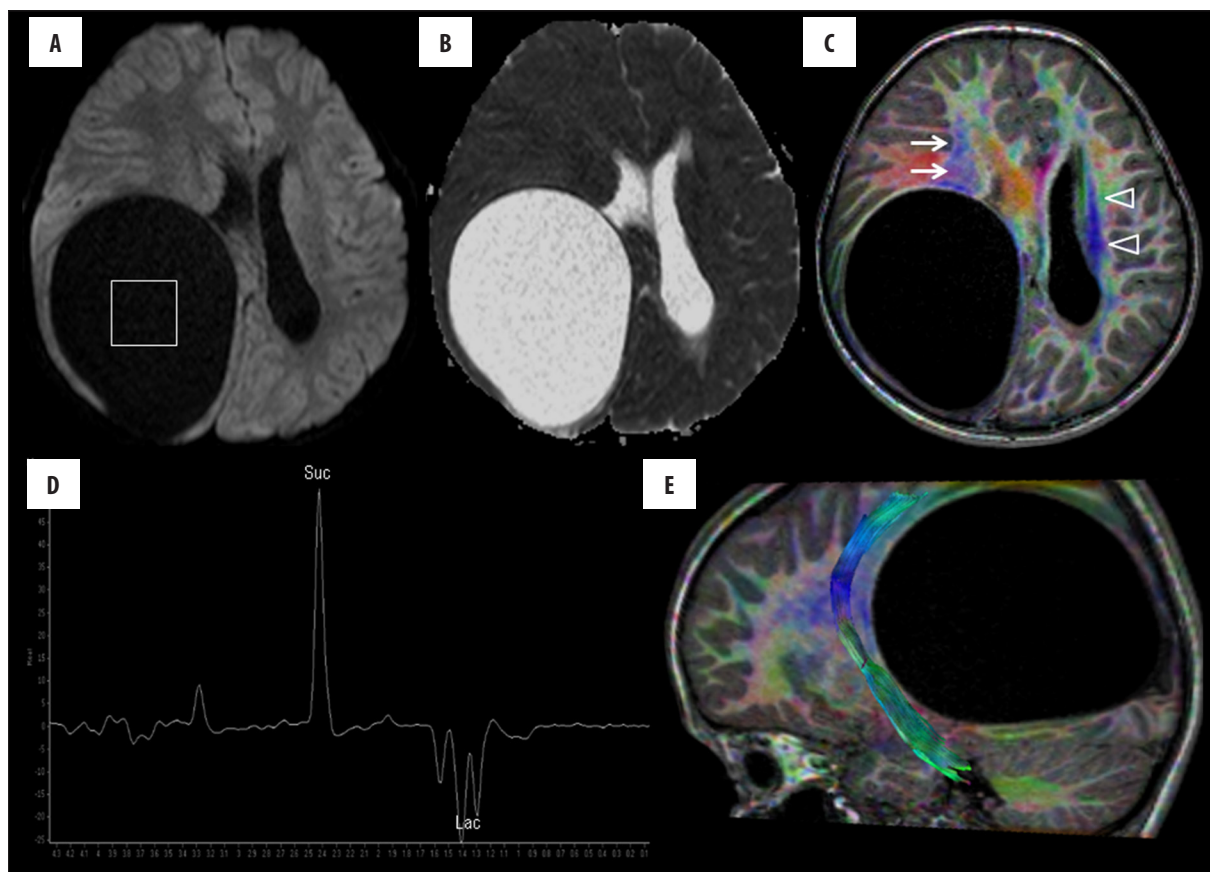
metabolites and presence of succinate and lactate within the cyst (Figure 2). A diagnostic hypothesis of hydatid cyst was made on the basis of the neuroradiological findings and empiric chemotherapy with albendazole was instituted. Further history taking revealed that he routinely used to drink raw non-pasteurised milk. The patient underwent surgery via a large occipital craniotomy; a thin cortical layer covered the cyst. Gross total removal was obtained via Dowling's technique [5,6], without rupture of the wall and/or ventricular opening. The patient recovered without complications and post-operative CT and MRI confirmed complete removal of the lesion. The patient was discharged home after suture removal. Cystic fluid was analyzed and protoscolices were stained (Figure 3). Two months after the operation, persistent Botallo duct was successfully corrected through an endovascular approach and therapy with albendazole was discontinued eight months later.

### Discussion

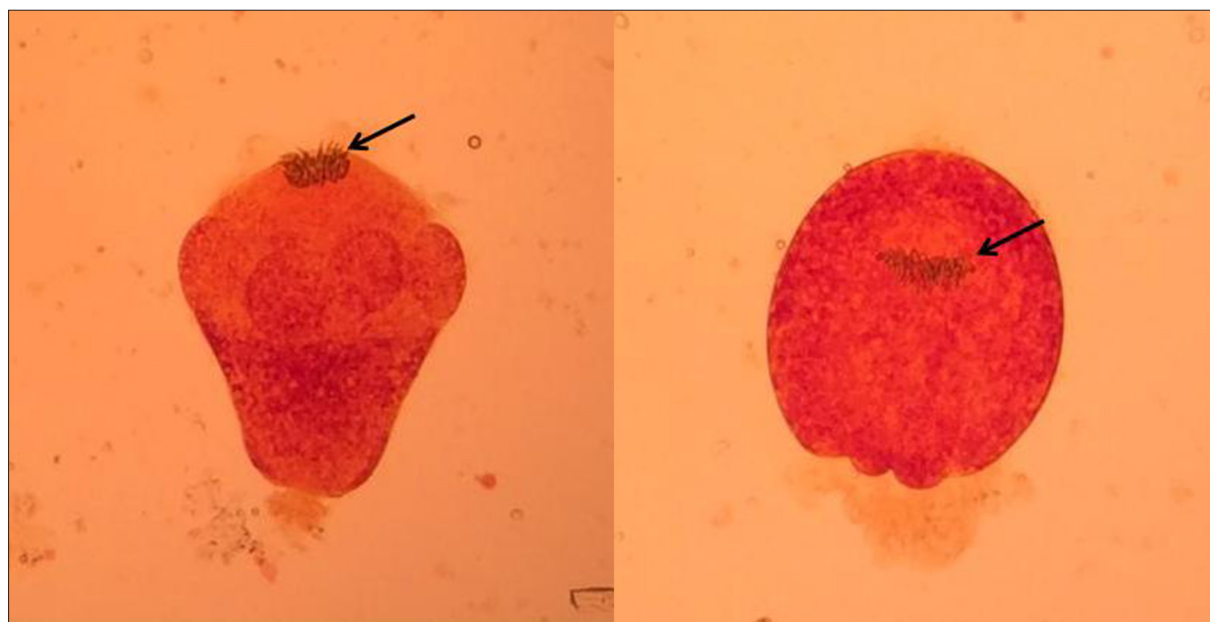
*Echinococcus granulosus* and *Echinococcus multilocularis* are small tapeworms that live in the bowel of canines (definitive host); their eggs are shed in the feces of dogs and can be ingested by cattle, sheep, and sometimes humans (intermediate host) [1]. After digestion of the capsule,



**Figure 1.** (A) Axial noncontrast CT shows huge intraaxial hypodense cyst with marginal calcification (arrow). (B) Axial FLAIR image shows the cyst to be isointense with CSF. There is marked mass effect with contralateral displacement of midline structures and left ventricular uncompensated hydrocephalus. (C) Axial susceptibility-weighted image confirms the marginal calcification (arrow) and also reveals a very thin, hypointense marginal cystic membrane. (D) Coronal T2-weighted image and (E) sagittal T1-weighted image show smoothly marginated cyst causing internal transtentorial herniation as well as displacement of adjacent convolutions. (F) Axial postcontrast T1-weighted image shows lack of contrast enhancement.



**Figure 2.** (A) Axial diffusion-weighted image and (B), corresponding apparent diffusion coefficient (ADC) map reveal water-like diffusion within the cyst. Placement of an MR spectroscopy voxel is also shown on A. (C) Color-coded fractional anisotropy image derived from a diffusion-tensor imaging (DTI) study at 16 directions shows that the corticospinal tract (CST) is severely distorted and displaced anteriorly (arrows; compare with normal contralateral CST, arrowheads). Fiber tractography image (E), however, confirms that the CST is only displaced, but not infiltrated, by the adjacent mass. (D) MR spectroscopy obtained with a single-voxel point-resolved (PRESS) technique at 144 ms echo-time shows absence of normal brain metabolites within the cyst; a huge peak at 2.4 ppm is consistent with succinate, whereas an inverted double peak at 1.3–1.4 ppm is consistent with lactate.



**Figure 3.** Protoscolices from the hydatid cyst fluid, stained with Dobell (40× magnification). Note the hooklets (black arrow).

embryos penetrate the intestinal mucosa and spread through the portal circulation: most are trapped in the liver and lung, developing hydatid cysts in those locations. The brain is a rare location, accounting for only 1–2% of all intracranial space-occupying lesions even in endemic areas [2]. Associated extracranial cysts are common, thus requiring a thorough radiological evaluation of the patient (including chest X-rays, abdominal ultrasound and, especially in children, cardiac ultrasound).

Primary cerebral HE is exceedingly rare; only few reports from endemic areas such as Turkey and India are available [7,8]. To date, only one case report and one clinical series have been described by Lunardi et al. and Sardi et al. of Italian patients operated on for hydatid brain lesions [9,10]. Brain location requires peculiar anatomic conditions that allow the germ to shunt the hepatic and pulmonary filters; the present patient had a persistent Botallo duct [11]. Most reported cases have described solitary, intraparenchymal cysts mainly located along the terminal branches of the middle cerebral artery [12]. Especially in children, cerebral hydatid cysts can grow to an enormous size because of the elastic structure of bone and the relatively higher compressibility of the neural tissue [13]. Multiple cysts can be due either to embolization of multiple larvae or to traumatic, iatrogenic, or even spontaneous cyst rupture [14,15]. Clinical features are not specific, depending on size and location: headache and signs of raised intracranial pressure are mostly reported, while focal neurological deficits and seizures are less frequent. Ersahin et al. reported a growth rate of about 1 cm per month over a 6-month period [16]. Serologic tests are of little clinical value in primary cerebral disease [13,17].

MRI and CT scans are helpful in suggesting the diagnosis and planning a proper treatment, although no pathognomonic sign can be detected [18]. The cyst characteristically presents as a solitary, homogeneous, spherical lesion with well-defined borders, no contrast enhancement, and no perilesional edema, filled with CSF-isodense fluid. Other supratentorial cystic lesions such as arachnoid cysts, cystic tumors, abscess, and porencephalic cysts should always be considered in the differential diagnosis [19]. Advanced imaging techniques, such as DTI or MR spectroscopy, can be helpful but not conclusive.

Surgery is the elective treatment, the goal being removal of the entire cyst without rupture, thereby preventing parasitic spread with further neurological deficits and the rare but existing anaphylactic reaction [3,20]. This can be achieved following some simple, clear steps: (i) positioning the patient's head so that the cyst is in a dependent position; (ii) large craniotomy; (iii) adequate corticotomy with accurate cortical dissection; (iv) careful Valsalva manoeuvre; and (v) use of continuous warm saline irrigation between the cyst and the surrounding brain parenchyma to help delivery (Dowling's technique) [5,6]. Other techniques have been proposed, such as fluid aspiration, but they appear to be dangerous with a high probability of cyst rupture and associated anaphylaxis and/or parasite spread to distant sites [4]. Intraoperative cyst rupture is a possible event associated with a potentially fatal anaphylactic reaction and a high rate of cyst recurrence [21, 22]. On the other hand, seizures, subdural effusion, porencephalic cyst, hemorrhage, pneumocephalus, hydrocephalus, and focal neurological deficits are the main reported postoperative complications that sometimes need further intervention [23]. Medical therapy is also important. Albendazole is currently the elective medication; it is effective in sterilizing the cyst, decreasing the risk of anaphylaxis, and reducing the recurrence rate [24,25]. Corticosteroids may help control perilesional edema, while anticonvulsants are used prophylactically [26].

## Conclusions

HE is still an endemic manifestation in some rural areas of the world, and it should be included in the differential diagnosis of children living in or coming from an endemic country who present with an intracerebral cyst. Early diagnosis and complete surgical removal of the intact cyst are the main factors that determine a favourable outcome. When a primary intracranial hydatid cyst is strongly suspected, the treatment of choice is surgery. The best surgical technique is en bloc removal of the cyst. Cyst puncture should be avoided for the risk of anaphylactic reaction and parasite spread to distant sites.

## Acknowledgements

We are very grateful to Aldo Naselli, MD PhD student, Infectious Diseases Unit, Istituto Giannina Gaslini, Genoa, Italy, for his help and assistance at the outpatient clinic in the follow-up of the patient reported in this paper.

## References:

- Ozdemir NG, Kurt A, Binici DN, Ozsoy KM: *Echinococcus alveolaris*: Presenting as a cerebral metastasis. *Turk Neurosurg*, 2012; 22(4): 448–51
- Kizilca O, Altas M, Senol U, Oztek MA: Hydatid disease located in the cerebellomedullary cistern. *Case Rep Med*, 2014; 2014: 271365
- Richter J, Profis E, Holtfreter MC et al: Anaphylactic shock ensuing therapeutic puncture of an echinococcal cyst. *Parasitol Res*, 2015; 114(2): 763–66
- Turgut M: Hydatidosis of central nervous system and its coverings in the pediatric and adolescent age groups in Turkey during the last century: A critical review of 137 cases. *Childs Nerv Syst*, 2002; 18(12): 670–83
- Carrea R, Dowling E, Jr., Guevara JA: Surgical treatment of hydatid cysts of the central nervous system in the pediatric age (Dowling's technique). *Childs Brain*, 1975; 1(1): 4–21
- Dowling EO: Hydatid cyst of the right frontal lobe. *Revta Asoc Méd Argent*, 1929; 1929(4): 209–17 [in Spanish]
- Altinors N, Bavbek M, Caner HH, Erdogan B: Central nervous system hydatidosis in Turkey: A cooperative study and literature survey analysis of 458 cases. *J Neurosurg*, 2000; 93(1): 1–8
- Rumana M, Mahadevan A, Nayil Khurshid M et al: Cestode parasitic infestation: intracranial and spinal hydatid disease – a clinicopathological study of 29 cases from South India. *Clin Neuropathol*, 2006; 25(2): 98–104



9. Sardi I, Sanzo M, Buccoliero AM et al: Intracerebral atypical presentation of echinococcosis in a child. *Pediatr Neurosurg*, 2008; 44(4): 350-52
10. Lunardi P, Missori P, Di Lorenzo N, Fortuna A: Cerebral hydatidosis in childhood: A retrospective survey with emphasis on long-term follow-up. *Neurosurgery*. 1991; 29(4): 515-17; discussion 517-18
11. Ciurea AV, Fountas KN, Coman TC et al: Long-term surgical outcome in patients with intracranial hydatid cyst. *Acta Neurochir (Wien)*, 2006; 148(4): 421-26
12. Luo K, Luo DH, Zhang TR, Wen H: Primary intracranial and spinal hydatidosis: A retrospective study of 21 cases. *Pathog Glob Health*, 2013; 107(2): 47-51
13. Tuzun Y, Kadioglu HH, Izci Y et al: The clinical, radiological and surgical aspects of cerebral hydatid cysts in children. *Pediatr Neurosurg*, 2004; 40(4): 155-60
14. Amin OS: Multiple cerebral hydatid cysts: Have the previous operations contributed to their formation? *BMJ Case Rep*, 2012; 2012: pii: bcr2012007240
15. Yuceer N, Guven MB, Yilmaz H: Multiple hydatid cysts of the brain: A case report and review of the literature. *Neurosurg Rev*, 1998; 21(2-3): 181-84
16. Ersahin Y, Mutluer S, Guzelbag E: Intracranial hydatid cysts in children. *Neurosurgery*, 1993; 33(2): 219-24; discussion 224-25
17. Debourgogne A, Goehringer F, Umhang G et al: Primary cerebral alveolar echinococcosis: Mycology to the rescue. *J Clin Microbiol*, 2014; 52(2): 692-94
18. Okur A, Ogul H, Sengul G et al: Magnetic resonance spectroscopy and magnetic resonance imaging findings of the intracerebral alveolar echinococcosis. *J Craniofac Surg*, 2014; 25(4): 1352-53
19. Guzel A, Tatli M, Maciaczyk J, Altinors N: Primary cerebral intraventricular hydatid cyst: A case report and review of the literature. *J Child Neurol*, 2008; 23(5): 585-88
20. Diaz de Durana MD, Lopez A, Fraj J: Anaphylaxis and cerebral hydatidic disease. *Ann Intern Med*, 1997; 126(9): 745
21. Umerani MS, Abbas A, Sharif S: Intra cranial hydatid cyst: A case report of total cyst extirpation and review of surgical technique. *J Neurosci Rural Pract*, 2013; 4(Suppl. 1): S125-28
22. Onal C, Unal F, Barlas O et al: Long-term follow-up and results of thirty pediatric intracranial hydatid cysts: half a century of experience in the Department of Neurosurgery of the School of Medicine at the University of Istanbul (1952-2001). *Pediatr Neurosurg*, 2001; 35(2): 72-81
23. Tuzun Y, Solmaz I, Sengul G, Izci Y: The complications of cerebral hydatid cyst surgery in children. *Childs Nerv Syst*, 2010; 26(1): 47-51
24. Horton RJ: Albendazole in treatment of human cystic echinococcosis: 12 years of experience. *Acta Trop*, 1997; 64(1-2): 79-93
25. Junghanss T, da Silva AM, Horton J et al: Clinical management of cystic echinococcosis: State of the art, problems, and perspectives. *Am J Trop Med Hyg*, 2008; 79(3): 301-11
26. Duishanbai S, Jiafu D, Guo H et al: Intracranial hydatid cyst in children: Report of 30 cases. *Childs Nerv Syst*, 2010; 26(6): 821-27