

Recurrence in a Laparoscopically Repaired Traumatic Diaphragmatic Hernia: Case Report and Literature Review

Nikita R. Bhatt,^{1,*} and Morgan McMonagle¹

¹Department of Surgery, Waterford University Hospital, Waterford, Ireland

*Corresponding author: Nikita Bhatt, Department of Surgery, Waterford University Hospital, Waterford, Ireland. Tel: +353-860609430, E-mail: nikitarb89@gmail.com

Received 2014 May 21; Revised 2014 July 20; Accepted 2014 July 29.

Abstract

Introduction: Traumatic diaphragmatic hernia (TDH) develops infrequently following a traumatic diaphragmatic rupture (TDR). As TDR is frequently missed due to lack of sensitive and specific imaging modalities, a high index of suspicion for such injuries is essential, whether immediately posttraumatic, or even decades after the trauma. We describe a rare case of recurrence in a laparoscopically repaired TDH and review the current literature on the same.

Case Presentation: A 23-year-old male with a history of primary laparoscopic repair of left-sided TDR two years ago presented with symptoms of acute large bowel obstruction. His chest X-ray showed a left-sided pleural effusion and a loop of the bowel in the left hemithorax, but no signs of free gas. An abdominal X-ray (AXR) demonstrated massively dilated large bowel with distension of the small bowel. At laparotomy, the obstructing lesion consisted of the large bowel with omentum herniated through the left hemidiaphragm, consistent with a left recurrent/chronic diaphragmatic hernia. The diaphragmatic defect was repaired with interrupted nylon. The patient made an uneventful recovery.

Conclusions: Recurrence after repair of TDH is a less reported condition (with only two published articles) and little is known regarding the factors responsible for this. Laparoscopy is an excellent diagnostic tool, but currently management is probably best performed via an open technique using heavy non-absorbable suture material to prevent recurrence. Long term follow up of these patients should also be considered.

Keywords: Diaphragmatic Hernia, Trauma, Recurrence, Laparoscopy, Open Repair

1. Introduction

Traumatic diaphragmatic rupture (TDR) reportedly affects 1% - 7% and 10% - 15% of major (ISS > 15) blunt and penetrating injuries respectively (1). Traumatic diaphragmatic hernia (TDH) is a relatively rare but potentially lethal complication following TDR which poses both diagnostic and therapeutic challenges for surgeons, due in part to the lack of awareness amongst healthcare providers in addition to the low sensitivity and specificity of commonly available diagnostic tests, making it one of the most frequently missed injuries (2). TDR typically occurs concomitantly with other severe injuries, especially after blunt trauma, which contributes to its associated higher mortality and morbidity, reflecting the seriousness of the diagnosis when discovered (3). The treating team must remain vigilant with a high index of suspicion for any patient presenting with a history suggestive of TDR or a mechanism associated with the risk (both acutely or even many years later). We describe a case of a delayed presentation of recurrent chronic diaphragmatic hernia that presented to our institution with acute complications. A review of literature on TDH and its recurrence along with possible causative factors are also described.

2. Case Presentation

A twenty-three year old male patient presented to our emergency department (ED) on two separate occasions in the same week complaining of a 5-day history of increasing central and lower abdominal pain with distension and three episodes of feculent vomiting. Although he also reported constipation, he maintained the passage of flatus. At first presentation he reported abdominal pain only without distension or vomiting and was admitted for a 24-hour period of observation after which his symptoms settled and he was discharged home relatively well. On the second attendance, he presented with recurrent abdominal pain with distension, nausea and vomiting. On examination he had generalized abdominal tenderness (without peritonitis), but remained hemodynamically well. Blood investigations showed a leukocytosis ($16.5 \times 10^3/\mu\text{L}$) and elevated C-reactive protein (235 mg/L), consistent with an acute inflammatory response, but all other standard blood tests (hemoglobin, platelets, liver function tests, urea, creatinine, and electrolytes) were within normal range.

His past medical history included a multi-trauma two years previously, managed at a different institution. Injuries included: closed head injury (admission GCS 6/15),

pelvic fracture, a grade 2 splenic injury (all successfully managed non-operatively) and left sided TDR (diagnosed on CT scanning). He remained hemodynamically well at that time and underwent a laparoscopic repair of the TDR using continuous 2/0 nylon suture. After a protracted ICU stay managing raised intracranial pressure he was eventually discharged home after 3 months with mild to moderate left sided weakness, which continued in the intervening period. On this admission, his chest X-ray (CXR) demonstrated a left sided pleural effusion with a loop of bowel within the left hemithorax, but with no free gas visible (Figure 1). Abdominal X-ray (AXR) demonstrated gross large and small bowel dilatation, consistent with large bowel obstruction with ileo-caecal valve incompetence (which may explain the intermittent nature of his symptoms and presentation).

Acute management included fluid resuscitation (intravenous crystalloid) and gastrointestinal decompression with a nasogastric tube (NG). The NG tube drained a large volume of feculent fluid (> 3L) over a 6hr period, but with little improvement in abdominal pain or distension. Due to the lack of progress during this time, the surgical team proceeded to laparotomy for the management of acute large bowel obstruction.

Findings at laparotomy included large bowel obstruction, dilated from the cecum to the splenic flexure with distal collapse. There was also a large visceral hernia containing large bowel (with omentum) through a defect in the left hemidiaphragm consistent with a recurrent yet chronic TDR. The hernia sac was thickened with evidence of long-standing incarceration and multiple chest adhesions, consistent with the chronic nature of the condition, necessitating careful dissection from the surrounding diaphragmatic muscle and left pleura. After successful mobilization the bowel and omentum were inspected (fully viable and without perforation) and were reduced back into the abdominal cavity. There was a 3cm x 2cm defect in the left hemidiaphragm (Figure 2).

The diaphragmatic defect was subsequently repaired with interrupted No. 1 nylon and the abdomen was lavaged with warm saline, drained and closed as standard. The patient went on to make an uneventful recovery and follow up CXR only showed a small left sided pleural effusion with no evidence of the diaphragmatic hernia (Figure 3).

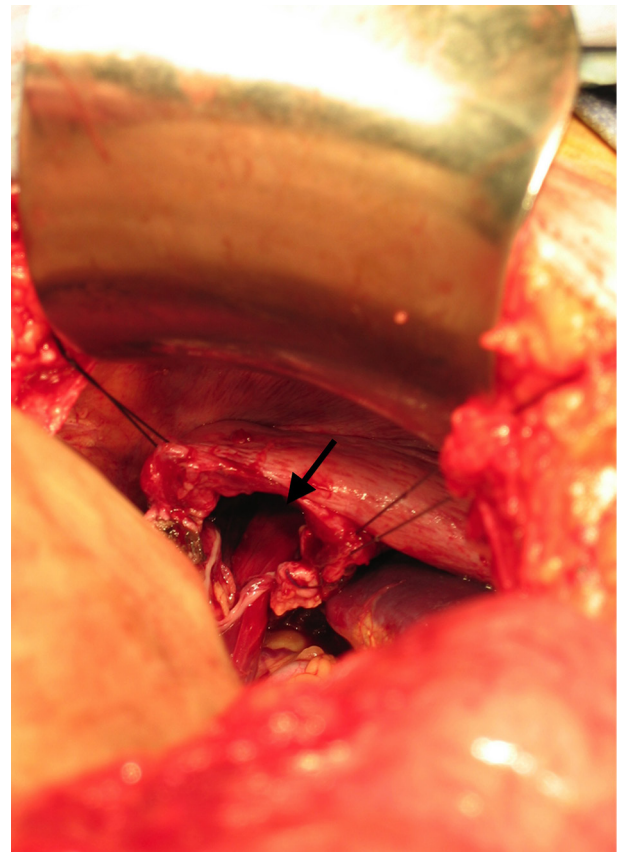


Figure 2. The Defect in the Left Hemi-Diaphragm

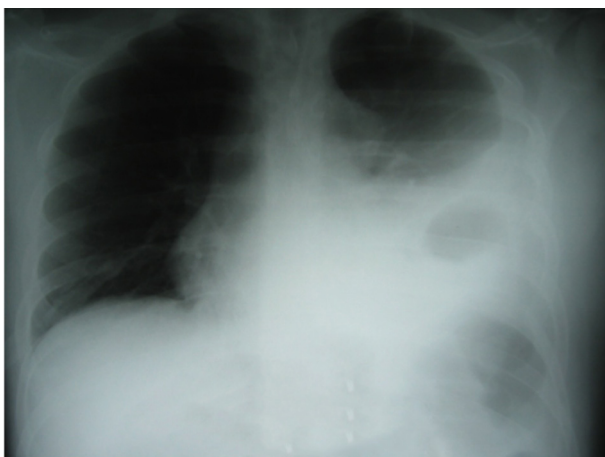


Figure 1. Pre-Operative Chest X-Ray (CXR) Demonstrating a Left Sided Pleural Effusion With a Loop of Bowel Within the Left Hemithorax

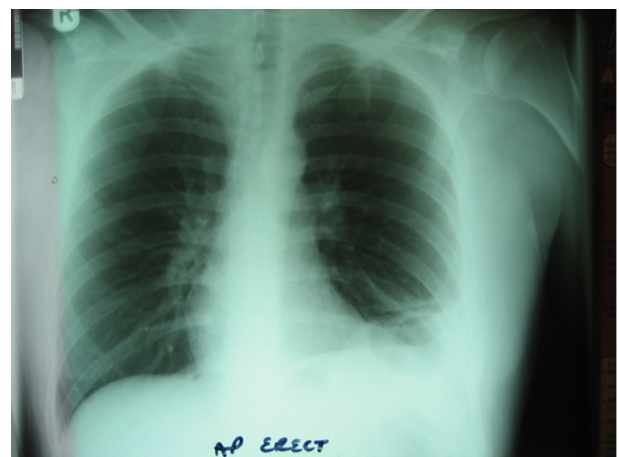

Figure 3. Post-Operative Chest X-Ray Showing Resolution of Diaphragmatic Hernia

3. Discussion

The hypothesis of Grimes (1974) explains the delay in TDR presentation, which may be due to either a delay in the actual physical rupture of the diaphragm or may simply be due to a delay in accurate diagnosis (4). The delayed rupture probably results from the continual, intermittent mandatory motion of the diaphragm over time. Despite the underlying muscular injury, the anatomical boundary is maintained for some time. Repeated diaphragmatic excursion during respiration, results in recurrent muscular stress and repetitive micro-trauma to the muscle fibers, with eventual rupture some time later (days to months). This underlying mechanism of delayed rupture may be further exacerbated or even hastened into rupture by any other hazards associated with barometric fluctuations such as flying and scuba diving (5, 6).

Published evidence suggests that the interval between injury and diagnosis can vary from weeks to years (with the longest being 50 years!) (7). Complications include; herniation of abdominal contents into the chest cavity as a result of the thoraco-abdominal pressure gradient, leading to a progressively enlarging diaphragmatic defect. Slow, progressive herniation may present with chronic, intermittent abdominal and / or chest pain and constipation, eventually leading to dyspnea due to lung compression on the affected side, bowel obstruction, strangulation, perforation, septicemia with hemodynamic collapse (2).

A high level of clinical vigilance and suspicion is needed so that these injuries do not go undiagnosed, either immediately post-trauma or even in cases presenting months to years later (as the hernia may recur as in this case). It is possible to miss these injuries even during exploratory laparotomy, unless specifically explored for, by palpating and visualizing both hemi-diaphragm directly. As the size and position of the liver on the right gives support and protection to the right hemidiaphragm, these injuries occur almost exclusively (88% - 95%) on the left (8). However, a right-sided hernia should still be ruled-out at laparotomy, as the hemodynamic consequences of a hepatic-diaphragmatic hernia can be devastating (9).

Delayed TDH can also lead to bowel obstruction which should also be diagnosed early and managed operatively before complications occur, which carry a high mortality (10) In our case, the TDR was detected early after the index trauma, and underwent laparoscopic repair, but which recurred sometime later, re-presenting two years after the initial injury.

Investigations include; plain X-ray films and CT scanning (chest and abdomen) as long as patient's hemodynamics allow. Chest X-ray (CXR) is a standard investigation after trauma with reports of 23% - 73% of left sided TDRs being detected with this alone with an additional 25% found on serial subsequent films in-hospital. Signs of a diaphragmatic rupture on chest X-ray (11):

- Abdominal contents in the hemi-thorax; With or without signs of focal constriction ("collar sign")
- Nasogastric tube seen in the thorax
- Elevated hemidiaphragm (> 4 cm higher on left vs right)
- Distortion of diaphragmatic margin

Conventional CT scanning has reported sensitivity and specificity of 14%-82% and 87% respectively with helical CT increased the sensitivity to 71% - 100% (esp. left side) (11). Signs of a diaphragmatic rupture on a CT-scan:

- Direct visualization of injury
- Segmental diaphragm non-visualization
- Intrathoracic herniation of viscera, "collar sign"
- Peridiaphragmatic active contrast extravasation

Surgical management of a TDR with or without herniation (acute or chronic) includes reduction of incarcerated sac contents, dissection and excision of the hernia sac, pleural drainage and repair of the diaphragmatic defect. We recommend closing the defect with interrupted or continuous, non-absorbable heavy suture (e.g.: nylon, prolene), reinforced with pledgets if there is any evidence of further diaphragmatic muscular injury or tearing during repair (to reinforce and minimize tearing of the thin diaphragmatic musculature when tightened). Larger defects may require a mesh repair, over the defect to achieve a tension free closure on the continually contracting-relaxing diaphragmatic complex (12).

Repair is typically performed via the abdomen (laparotomy), although access via the chest (thoracotomy) is also acceptable and often depends on the presenting injuries mandating surgical exploration. Both laparoscopic and thoracoscopic approaches have been described (13, 14). However, we would urge caution with this approach, which requires advanced laparoscopic skills and has a higher missed injury rate. Neugebauer et al. (15) have cautioned that advanced laparoscopic procedures have only achieved grade B or C recommendation in the management of TDR in comparison with laparoscopic interventions for other non-traumatic conditions such as acute cholecystitis or appendicitis (Grade A). Currently, the long-term data results after laparoscopic repair of TDR is lacking. However, best published evidence suggests that the laparoscopic management of TDR is currently deficient (15). The main concern with laparoscopic management include difficulty with adequate exposure of this anatomical recess in addition to the high incidence of concomitant injuries that also require full open surgical exposure. In addition, a more justified and confident repair is more easily achieved through the open approach.

Rashid et al. (12) reported 27 cases of left sided rupture and 13 cases of right-sided rupture. Rare sites of rupture included central herniation (n = 1), bilateral rupture (n = 2) and trans-diaphragmatic intercostal herniation (n = 1). Postoperative complications described included; pneumothorax, atelectasis, recurrence (of the hernia), ileus,

and intraabdominal adhesions (12).

Published descriptions of recurrent TDR after successful repair are limited. Hanna et al. (13) reported recurrences in only two cases after primary repair during follow-up (n = 76) but only 13 (17.1%) of the 76 patients alive at discharge could be followed up successfully after the primary repair. Although the true incidence of recurrence is unclear, the present literature suggests that it may be more common than previously thought. Currently, there is a lack of published data exploring the factors responsible for recurrence. One such factor could be the type of suture material used for repair (16). Both cases of recurrence in the study by Hanna et al. (13) had undergone initial repair with absorbable sutures, whereas the remaining 11 cases without recurrence underwent repair with non-absorbable material. In a similar case by Kitada et al. (16), the primary repair was also performed with absorbable suture. Although in our case, the initial repair was performed with nylon (non-absorbable), the recurrence could be due to a continuous repair of the hernia defect. The primary repair in our case was done using 2-0 nylon, but No. 1 nylon was used post-recurrence. It may be proposed that the size and the strength of the suture material used may play a role. Despite the fact that long-term data on follow-up after trauma is difficult to obtain, further studies are needed before the true clinical courses of these injuries is fully understood.

Delayed TDH following a TDR is an important cause of bowel obstruction. Owing to the rarity of this condition and the diagnostic challenges it poses, a high index of suspicion is imperative for timely diagnosis and repair. A history of high velocity trauma, left chest penetrating injury, injuries at the thoracoabdominal junction and other associate concomitant injuries (e.g. splenic, gastric) should all lead to the high index of suspicion for these potentially lethal diaphragmatic injuries. This case presented to us with a delayed traumatic diaphragmatic hernia 2 years after primary laparoscopic repair of a left sided traumatic diaphragmatic rupture. Early diagnosis is very important for appropriate surgical management, reducing the risks of visceral strangulation and its complications. Surgical repair can be done either primarily with non-absorbable suture or patch closure with a mesh in larger defects. Though some centers advocate laparoscopy for managing these injuries, the literature suggests that the laparoscopic repair may be deficient in the long term. A laparotomy would allow thorough exploration of the diaphragm and leave less chance for the development of a recurrence like the one that occurred in this

case; and is thus the option advocated by us. We also recommend long-term follow up in patients following a primary repair of the diaphragm to detect possible recurrence and prevent life threatening complications of the resulting diaphragmatic hernia.

References

1. Meyers BF, McCabe CJ. Traumatic diaphragmatic hernia. Occult marker of serious injury. *Ann Surg.* 1993;**218**(6):783-90. [PubMed: 8257229]
2. Alimoglu O, Eryilmaz R, Sahin M, Ozsoy MS. Delayed traumatic diaphragmatic hernias presenting with strangulation. *Hernia.* 2004;**8**(4):393-6. doi: 10.1007/s10029-004-0225-6. [PubMed: 15098101]
3. Nursal TZ, Ugurlu M, Kologlu M, Hamaloglu E. Traumatic diaphragmatic hernias: a report of 26 cases. *Hernia.* 2001;**5**(1):25-9. [PubMed: 11387719]
4. Grimes OF. Traumatic injuries of the diaphragm. *Diaphragmatic hernia. Am J Surg.* 1974;**128**(2):175-81. [PubMed: 4843862]
5. Chanson C, Hahnloser D, Nassiopoulou K, Petropoulos P. Gastric and omental incarceration through an occult traumatic diaphragmatic hernia in a scuba diver. *J Trauma.* 2002;**52**(1):146-8. [PubMed: 11791065]
6. Maningas PA, DiJulio MA, Dronen SC. Diaphragmatic rupture during G-manuevers in a T33 jet trainer. *Aviat Space Environ Med.* 1983;**54**(11):1037-8. [PubMed: 6651731]
7. Singh S, Kalan MM, Moreyra CE, Buckman Jr RF. Diaphragmatic rupture presenting 50 years after the traumatic event. *J Trauma.* 2000;**49**(1):156-9. [PubMed: 10912874]
8. Goh BK, Wong AS, Tay KH, Hoe MN. Delayed presentation of a patient with a ruptured diaphragm complicated by gastric incarceration and perforation after apparently minor blunt trauma. *CJEM.* 2004;**6**(4):277-80. [PubMed: 17382006]
9. Hopkins J, Gash K, Armstrong C. Small bowel ischaemia resulting from delayed presentation of an incarcerated right-sided diaphragmatic hernia. *J Surg Case Rep.* 2011;**2011**(10):3. doi: 10.1093/jscr/2011.10.3. [PubMed: 24950548]
10. Demuro JP. A delayed traumatic diaphragmatic hernia presenting with a bowel obstruction 20 years postinjury. *J Clin Diagn Res.* 2013;**7**(4):736-8. doi: 10.7860/JCDR/2013/4755.2898. [PubMed: 23730663]
11. Sliker CW. Imaging of diaphragm injuries. *Radiol Clin North Am.* 2006;**44**(2):199-211. doi: 10.1016/j.rcl.2005.10.003. [PubMed: 16500203]
12. Rashid F, Chakrabarty MM, Singh R, Iftikhar SY. A review on delayed presentation of diaphragmatic rupture. *World J Emerg Surg.* 2009;**4**:32. doi: 10.1186/1749-7922-4-32. [PubMed: 19698091]
13. Hanna WC, Ferri LE. Acute traumatic diaphragmatic injury. *Thorac Surg Clin.* 2009;**19**(4):485-9. doi: 10.1016/j.thorsurg.2009.07.008. [PubMed: 20112631]
14. Matsevych OY. Blunt diaphragmatic rupture: four year's experience. *Hernia.* 2008;**12**(1):73-8. doi: 10.1007/s10029-007-0283-7. [PubMed: 17891332]
15. Neugebauer EA, Sauerland S. Guidelines for emergency laparoscopy. *World J Emerg Surg.* 2006;**1**(1):31. doi: 10.1186/1749-7922-1-31. [PubMed: 17052332]
16. Kitada M, Ozawa K, Satoh K, Hayashi S, Sasajima T. Recurrent diaphragmatic hernia 3 years after initial repair for traumatic diaphragmatic rupture: a case report. *Ann Thorac Cardiovasc Surg.* 2010;**16**(4):273-5. [PubMed: 21057446]