

Effectiveness of Endoscopic Surgery for Comatose Patients with Large Supratentorial Intracerebral Hemorrhages

Shigeo YAMASHIRO,¹ Yasuyuki HITOSHI,¹ Akimasa YOSHIDA,¹
and Jun-ichi KURATSU²

¹*Department of Neurosurgery, Kumamoto Rosai Hospital, Yatsushiro, Kumamoto;*

²*Department of Neurosurgery, Graduate School of Life Sciences, Kumamoto University, Kumamoto, Kumamoto*

Abstract

To evaluate the effectiveness of endoscopic surgery for life-threatening large brain hemorrhage, we reviewed our empirical cases of comatose patients with large supratentorial intracerebral hemorrhage. Among 35 patients with putaminal or subcortical hemorrhage that was evacuated endoscopically, 14 cases (40%) presented both findings of neurological grade IV for severity and hematoma volume exceeding 70 mL in the recent 3 years (endoscope group), whereas 8 cases with the same conditions were treated by conventional craniotomy for the preceding 3-year period (craniotomy group). Between these two groups, mean age was higher and duration of surgery was shorter in the endoscope group, but no significant differences in hematoma size or evacuation rate were recognized. In the 10 cases that presented with signs of cerebral herniation (neurological grade IVb) and required emergent decompression, the preparation time for surgery tended to be shorter in the endoscope group, although the difference was not significant. Additional ventricular drainage was performed in 7 cases and showed a supplemental effect of reducing intracranial pressure (ICP). Consequently, all patients in the endoscope group were rescued without decompressive large craniectomy, even with symptoms of cerebral herniation. In conclusion, endoscopic surgery has the potential to offer an effective therapeutic option for comatose patients with large supratentorial intracerebral hemorrhages, matching conventional craniotomy for emergent treatment in terms of mortality and management of ICP.

Key words: endoscopic surgery, intracerebral hemorrhage, comatose patient, intracranial pressure, decompressive craniectomy

Introduction

Endoscopic surgery has gradually become acknowledged as an effective method for treating intracerebral hemorrhage, thanks to the efforts of early adopters^{1,2)} and the continuous and vigorous refinement of technical procedures and hardware. In terms of the proper selection of patients, conventional wisdom is that this type of surgery is best suited for cases involving moderate-sized hematoma rather than larger, life-threatening hemorrhage with imminent danger of cerebral herniation, for which open-skull surgery with or without decompressive craniectomy has generally been employed. In our institution, endoscopic surgery has been applied not only for modestly sized hematoma, but also for massive

hematoma. We review those cases and discuss the effect and some advantages of this surgery for expanded applications.

Materials and Methods

From May 2007, we have typically applied endoscopic surgery for any spontaneous basal ganglia or subcortical hemorrhage if the calculated hematoma volume exceeds 31 mL, in accordance with the 2009 Japanese clinical guidelines for stroke.³⁾ From May 2011, endoscopic surgery has also been employed for comatose patients with neurological grade IV severity of intracerebral hematoma, or with hematoma volume more than 70 mL. Since that time, the surgical indications for conventional craniotomy for intracerebral hemorrhage have been limited to cases with hematoma associated with aneurysm or

vascular malformation. In endoscopic surgery, acute-phase intervention is always preferred to promptly reduce intracranial pressure (ICP), in the hope of preserving surrounding brain cells. Depending on the age or degree of urgency, local anesthesia is utilized as an alternative to general anesthesia. Procedural and technical details of endoscopic surgery were based on the method originally devised by Nishihara et al.,²⁾ in which dedicated suction tubes with diameters of 2.5 mm and 4 mm were used for hematoma aspiration under a 2.7-mm rigid endoscope (Olympus Corp., Shinjuku-ku, Tokyo) through a transparent sheath (Neuroport; Hakko Medicals, Chikuma, Nagano) following creation of a burr hole or small craniotomy.

This study reviewed 35 cases in which endoscopic surgery was employed for supratentorial intracerebral hemorrhage (31 cases in the putamen, 4 cases in subcortical regions) treated between May 2011 and October 2014. Among these, 14 patients (40%) with putaminal hematoma presented in a comatose state, judged as neurological grade IV (grade IVa, 4 cases; grade IVb with anisocoria, 10 cases). Before this period, 8 cases showing comparable conditions were subjected to open-skull surgery between May 2008 and April 2011. We compared endoscopic and open surgeries, taking into account differences in age, hematoma volume, evacuation rates, duration of surgery, and duration from computed tomography (CT) to start of surgery, and outcomes according to the modified Rankin Scale (mRS). Duration from

CT to start of surgery represents the time required to prepare surgical instruments and materials after making the decision to perform an emergency operation. We excluded patients with tumor bleeding or aneurysmal or arteriovenous hemorrhage. We also excluded patients with a pathological diagnosis of cerebral amyloid angiopathy because of differences in nature of the hematoma compared to hypertensive cases.

We analyzed the data of male/female ratio and mRS severity of outcomes using the χ^2 test. Other values are presented as mean \pm standard deviations and analyzed by a nonparametric Mann–Whitney test. Significant differences were defined as values of $p < 0.05$.

Results

All 14 comatose patients with large supratentorial hemorrhages originating from the putamen, so-called neurological grade IV, and who underwent endoscopic surgery, were reviewed (Table 1). Hematoma volume ranged from 76 mL to 232 mL. Evacuation rates of hematomas were $> 70\%$ in all except 2 cases. Continuous ICP monitoring was performed for 9 cases (64.2%). Additional ventricular drainage was performed in 7 cases (30%) with the aim of achieving the supplemental effect of reducing ICP. Local anesthesia was chosen due to the urgent need for rapid intervention in 2 cases with neurological grade IVb. All patients

Table 1 Endoscopic surgery for comatose patients with supratentorial intracerebral hemorrhage

Age	Sex	Neurol. grade	Hematoma vol. (mL)	Evacuation rate (%)	ICP monitoring	Ventricular drainage	mRS grade
55	M	IV-a	117	97	yes		4
77	F	IV-a	78	94			5
86	M	IV-a	80	94			4
87	M	IV-a	76	100			5
70	F	IV-b	115	90			5
68	M	IV-b	120	95			4
66	M	IV-b	127	79	yes		5
60	M	IV-b	142	98	yes	yes	4
*61	M	IV-b	165	70	yes	yes	4
*85	M	IV-b	232	97	yes	yes	5
79	M	IV-b	88	66	yes	yes	5
69	F	IV-b	192	43	yes	yes	5
69	F	IV-b	82	98	yes	yes	5
53	M	IV-b	230	98	yes	yes	5

*Operation was performed under local anesthesia. F: female, ICP: intracranial pressure, M: male, Neurol.: neurological, vol.: volume.

survived endoscopic surgery, with estimated outcomes of mRS grade 4 in 5 cases and grade 5 in 9 cases. One patient treated with conventional craniotomy with decompressive craniectomy died because of expansive cerebral infarction on the hematoma side.

A summary of comparisons between the endoscope and craniotomy groups is provided in Table 2. Mean age was significantly higher and duration of surgery was significantly shorter for endoscopic surgery than for craniotomy. No significant differences were recognized for hematoma volume, evacuation rate, or outcome by mRS score.

Among the selected cases with neurological grade IVb, mean hematoma volume was higher, but duration of surgery was significantly shorter in the endoscope group than in the craniotomy group. The duration from CT to surgery tended to be shorter for endoscopy than for craniotomy, although no significant difference was observed (Table 2).

Representative Case

A 61-year-old man with a history of hypertension collapsed at home. He was comatose with marked

anisocoria and left hemiplegia at the time of initial contact by emergency services. Airborne transfer to our emergency room was made within about an hour, at which time he was still in the devastating status of Glasgow Coma Scale 4, with fully dilated right pupil, left complete hemiparesis, and decerebrated posture. Head CT showed right putaminal hematoma with a volume of 165 mL and intraventricular perforation, severe midline shift, and signs of tentorial herniation (Fig. 1).

He was rushed to the operation room for immediate endoscopic surgery under local anesthesia, resulting in the evacuation of more than 70% of the initial volume. This was less than expected, due to technical difficulties including sudden collapse of the hematoma cavity. After managing arterial bleeding on the hematoma cavity, ventricular drainage was added to the right anterior horn of the lateral ventricle along with insertion of an ICP probe. During early-phase postoperative management, ICP never reached harmful levels. After proper management of aspiration pneumonia, his level of consciousness gradually improved following lumboperitoneal shunt for secondary hydrocephalus, allowing basic activities of daily living.

Table 2 Comparison between endoscopic surgery and open craniotomy for comatose patients with large supratentorial intracerebral hemorrhage

	All cases		Neurological grade IV-b	
	Endoscope (n = 14)	Craniotomy (n = 8)	Endoscope (n = 10)	Craniotomy (n = 7)
Mean age	70.4 ± 10.7	58.2 ± 24.0*	68.0 ± 8.7	61.3 ± 24.2*
Male: Female	10 : 4	4 : 4	7 : 3	3 : 4
Mean hematoma volume	131.7 ± 52.2	99.2 ± 16.5	149.2 ± 51.3	98.2 ± 17.4*
Mean evacuation rate (%)	87.0 ± 16.1	86.7 ± 12.4	83.3 ± 17.6	86.1 ± 13.2
Mean duration of surgery (min)	124.9 ± 38.0	176.0 ± 40.6*	120.5 ± 33.4	174.0 ± 43.0*
Mean duration from CT to surgery	165.0 ± 64.2	155.5 ± 45.7	137.0 ± 36.1	161.0 ± 46.4
mRS ≤ Grade 4 (%)	5 (35.7 %)	4 (50 %)	3 (30.0 %)	3 (42.9 %)

*Statistically significant difference between two groups. CT: computed tomography, mRS: modified Rankin Scale.

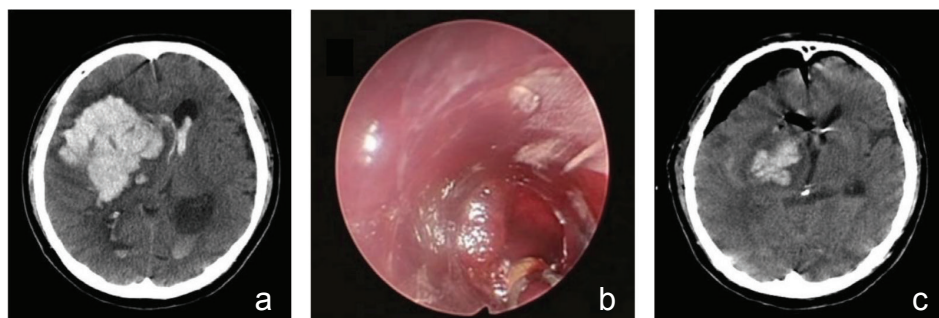


Fig. 1 a: Preoperative computed tomography (CT) image revealing approximately 165 mL of putaminal hematoma with intraventricular hemorrhage and severe midline shift. b: Endoscopic view through a transparent sheath inserting to the hematoma cavity. c: Postoperative CT scan showing a part of residual hematoma inside of the putamen.

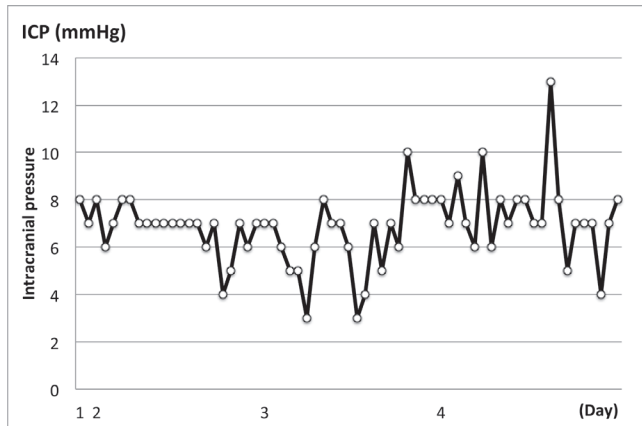


Fig. 2 Line chart showing change of intracranial pressure (ICP), from immediately after surgery to 4 days.

Discussion

All 14 comatose patients with poor neurological grade IV were treated by endoscopic surgery, and survived. Monitoring in 9 cases showed that postoperative ICP consistently remained within normal range. In fact, endoscopic surgery was able to manage life-threatening high ICP accompanying cerebral herniation in neurological grade IVb cases, even if the surgery resulted in only partial evacuation of the hematoma.

In the initial 3-year period of the study before the introduction of endoscopic surgery, open-skull surgery was preferred for treating large intracerebral hematomas in severe cases. However, in the last 3 years of the study, we applied endoscopic surgery to all but a handful of cases in which the presence of arteriovenous malformation was suspected. The treatment results for this study period underscore the effectiveness of endoscopic surgery even for very large hematomas, even though the original intent underlying the development of endoscopic surgery was to lower the invasiveness of surgery for moderate-size hematomas.^{4,5)}

Historically, the effect of surgical intervention for cerebral hemorrhage has been controversial, best represented in the randomized trial, International Surgical Trial in Intracerebral Hemorrhage (STICH), which found no statistical advantage to surgical intervention.⁶⁾ The newer STICH II trial finally reported some advantage in terms of functional outcome at 6 months and mortality rate, if patients showed a good level of consciousness and the hematoma was located within 1 cm from the brain surface.⁷⁾ In Japan, surgical intervention for cerebral hemorrhage has been popular among neurosurgeons and its effectiveness has been reported.⁸⁾ In this environment, endoscopic surgery has been gaining

popularity as a method for surgical intervention in selected situations.

As for severe cases such as those showing neurological grade IVb or with hematoma volume exceeding 70 mL, neither treatment had any impact on functional outcome, so the only purpose of surgical intervention would be to achieve patient survival, despite the fact that some authors have even cast doubt on the reduction in mortality rate supposedly achieved by lowering ICP via surgical methods.^{5,9)} Nonetheless, situations could arise in which the patient's family may have a last hope of survival and depend on surgical intervention, despite negative indications. In fact, our study included some patients who survived after surgical intervention and showed outcomes of mRS grade 4 despite an apparently hopeless status on initial assessment. Indeed, institutions with the option to use endoscopic surgery may consider application of this approach even for severe-grade cases, given the simplicity and speed of the procedure. Both duration of surgery and preparation time for surgery were shorter for endoscopy than for craniotomy in neurological grade IVb cases. Because atrophy of the brain with aging might provide some kind of intrinsic buffer zone against high ICP, elderly individuals might show a better chance of recovery bolstered by the reduced invasiveness of this surgery. Besides such potential advantages, one issue has been of major concern: how coagulation of a bleeding point is achieved under endoscopic view. Addressing this issue requires some practice, since the whole procedure and many surgical components are indeed alien to standard neurosurgery.

Decompressive craniotomy has frequently been believed to be an appropriate management of ICP for severe cases, but its application is still controversial in terms of outcomes. Although some reports have described favorable outcomes with a reduced mortality rate,^{10,11)} negative aspects have consistently been reported and the procedure has been considered unnecessary due to a lack of meaningful improvements in outcome.¹²⁾ One retrospective study reinforced this negative view by comparing two groups of 25 craniotomy cases with or without decompressive craniectomy, finding no significant difference in terms of functional outcomes, despite modest improvements in midline shift with decompression.¹³⁾ Our experience, at least, partially reinforced this result, given the successful management of ICP without craniectomy by reduced hematoma volume and elimination of cerebrospinal fluid augmented by placement of ventricular drainage according to circumstances.

This study is limited by the small number of patients. Furthermore, no significant differences were observed in waiting time for surgery and clinical outcomes between endoscope and craniotomy groups. To establish the effectiveness of endoscopic surgery for large supratentorial intracerebral hemorrhages, well-designed studies equivalent to randomized controlled trials with a larger numbers of cases are required.

Conclusion

Endoscopic surgery has the potential to offer an effective therapeutic option for comatose patients with severe supratentorial intracerebral hemorrhages, matching the traditional open-skull surgery including decompressive craniectomy. This less-invasive approach could especially be advantageous to the elderly or patients with considerable risk factors.

Conflicts of Interest Disclosure

The authors have no personal, financial, or institutional interest in any of the drugs, materials, or devices described in this article.

References

- 1) Auer LM, Deinsberger W, Niederkorn K, Gell G, Kleinert R, Schneider G, Holzer P, Bone G, Mokry M, Körner E: Endoscopic surgery versus medical treatment for spontaneous intracerebral hematoma: a randomized study. *J Neurosurg* 70: 530–535, 1989
- 2) Nishihara T, Teraoka A, Morita A, Ueki K, Takai K, Kirino T: A transparent sheath for endoscopic surgery and its application in surgical evacuation of spontaneous intracerebral hematomas. Technical note. *J Neurosurg* 92: 1053–1055, 2000
- 3) Yasui N: Operative indication for hypertensive intracerebral hemorrhage, in Shinohara Y, Ogawa A, Suzuki N, Katayama Y, Kimura A (eds): *Japanese Guidelines for the Management of Stroke 2009*. Tokyo, 2009, pp 152–168
- 4) Yamamoto T, Ezaki T, Nakao Y, Mori K: Endoscopic hematoma evacuation for the hypertensive putaminal hemorrhage. *Jpn J Stroke* 32: 595–601, 2010 (Japanese)
- 5) Yamamoto T, Ezaki T, Nakao Y, Mori K: Endoscopic hematoma evacuation to improve the functional outcome. *Jpn J Neurosurg (Tokyo)* 20: 734–740, 2011 (Japanese)
- 6) Mendelow AD, Gregson BA, Fernandes HM, Murray GD, Teasdale GM, Hope DT, Karimi A, Shaw MD, Barer DH; STICH investigators: Early surgery versus initial conservative treatment in patients with spontaneous supratentorial intracerebral haematomas in the International Surgical Trial in Intracerebral Haemorrhage (STICH): a randomised trial. *Lancet* 365: 387–397, 2005
- 7) Mendelow AD, Gregson BA, Rowan EN, Murray GD, Gholkar A, Mitchell PM; STICH II Investigators: Early surgery versus initial conservative treatment in patients with spontaneous supratentorial lobar intracerebral haematomas (STICH II): a randomised trial. *Lancet* 382: 397–408, 2013
- 8) Kanaya H, Kuroda K: Intracerebral hematomas, in Kaufman HH (ed): *Development in Neurosurgical Approach to Hypertensive Intracerebral Hemorrhage in Japan*. New York, Raven Press, 1992, pp 179–209
- 9) Pantazis G, Tsitsopoulos P, Mihas C, Katsiva V, Stavrianos V, Zymaris S: Early surgical treatment vs conservative management for spontaneous supratentorial intracerebral hematomas: A prospective randomized study. *Surg Neurol* 66: 492–501; discussion 501–502, 2006
- 10) Takeuchi S, Takasato Y, Masaoka H, Hayakawa T, Yatsushige H, Shigeta K, Nagatani K, Otani N, Nawashiro H, Shima K: Decompressive craniectomy with hematoma evacuation for large hemispheric hypertensive intracerebral hemorrhage. *Acta Neurochir Suppl* 118: 277–279, 2013
- 11) Fung C, Murek M, Z'Graggen WJ, Krähenbühl AK, Gautschi OP, Schucht P, Gralla J, Schaller K, Arnold M, Fischer U, Mattle HP, Raabe A, Beck J: Decompressive hemicraniectomy in patients with supratentorial intracerebral hemorrhage. *Stroke* 43: 3207–3211, 2012
- 12) Li Q, Yang CH, Xu JG, Li H, You C: Surgical treatment for large spontaneous basal ganglia hemorrhage: retrospective analysis of 253 cases. *Br J Neurosurg* 27: 617–621, 2013
- 13) Shimamura N, Munakata A, Naraoka M, Nakano T, Ohkuma H: Decompressive hemi-craniectomy is not necessary to rescue supratentorial hypertensive intracerebral hemorrhage patients: consecutive single-center experience. *Acta Neurochir Suppl* 111: 415–419, 2011

Address reprint requests to: Shigeo Yamashiro, Department of Neurosurgery, Kumamoto Rosai Hospital, 1670 Takehara-machi, Yatsushiro, Kumamoto 866-8533, Japan.