

Characterization of *Eimeria brunetti* Isolated from a Poultry Farm in Japan

Fumiya KAWAHARA^{1)*}, Guohong ZHANG¹⁾, Takayuki SUZUKI¹⁾, Akira IWATA¹⁾, Kisaburo NAGAMUNE^{2,3)} and Tetsuo NUNOYA¹⁾

¹⁾Nippon Institute for Biological Science, 9-2221-1 Shin-machi, Ome, Tokyo 198-0024, Japan

²⁾National Institute of Infectious Diseases, 1-23-1 Toyama, Shinjuku-ku, Tokyo 162-8640, Japan

³⁾Graduate School of Life and Environmental Sciences, University of Tsukuba, 1-1-1 Tennodai, Tsukuba, Ibaraki 305-8572, Japan

(Received 12 May 2013/Accepted 7 August 2013/Published online in J-STAGE 21 August 2013)

ABSTRACT. None of anticoccidial vaccines (Trivalent TAMTM, monovalent NecaTM and imported pentavalent Paracox[®]-5) contain *Eimeria brunetti* in Japan, which has not been regarded as a cause of coccidiosis, because of its low prevalence. However, we have recently reported the evidence of a high nationwide prevalence of this species. In this report, we describe the characteristics of *E. brunetti* which have never been clearly defined in Japan. Mortality rates and other disease characteristics caused by our strain (Nb strain) were similar to those reported previously in other studies. Despite great reduction of body weight gains among groups infected with over 1×10^3 oocysts, the intestinal lesions in the infected chickens were rather mild compared to previous studies. Sulfà drugs and lasalocid were so effective that the *E. brunetti* infection was almost completely blocked. Consequently, it is suggested that the characteristics of *E. brunetti* are various among the strains, but the pathogenicity of the Japanese Nb strain is enough strong to cause clinical coccidiosis.

KEY WORDS: anti-drug sensitivity, *Eimeria brunetti*, Japan, live vaccine, pathogenicity.

doi: 10.1292/jvms.13-0239; *J. Vet. Med. Sci.* 76(1): 25–29, 2014

Chicken coccidiosis induced by *Eimeria* parasites causes huge economic losses to intensive poultry industries worldwide [12]. Seven species of *Eimeria* have been reported to infect chickens so far. Among these species, *E. acervulina*, *E. brunetti*, *E. maxima*, *E. necatrix* and *E. tenella* are highly pathogenic, causing production losses in industry due to clinical or subclinical coccidiosis.

Generally, the poultry industry uses specific anticoccidial drugs or live anticoccidial vaccines as prophylactic therapies to prevent and control the disease. There are concerns about drug residues in poultry products and a strong consumer desire to ban drugs from animal feeds. As a result, the demand for products derived from organic chickens, without feeding of chemicals or antibiotics, tends to increase in Japan as European countries. It is estimated that live anticoccidial vaccines in Japan are applied to one hundred million chickens per year [13].

Three live coccidiosis vaccines have been registered and sold in Japan. Trivalent TAMTM (Nisseiken Co., Ltd., Tokyo, Japan) contains precocious attenuated strains of *E. acervulina*, *E. maxima* and *E. tenella*. Monovalent NecaTM (Nisseiken Co., Ltd.) contains a precocious attenuated strain of *E. necatrix*. Pentavalent Paracox[®]-5 (MSD Animal Health, Milton Keynes, U.K.) which contains precocious attenuated strains of *E. acervulina*, *E. maxima*, *E. mitis* and

E. tenella has been imported from the UK. However, none of these products contain *E. brunetti*, because its occurrence in chicken flocks has been regarded to be less intensive in Japan to date. No oocysts of *E. brunetti* were detected on several national surveys of broiler flocks in 1970's [8–10]. In 1990, two strains of *E. brunetti* were first isolated from poultry farms in Hokkaido and Kumamoto. This suggested a greater prevalence of *E. brunetti*, as these are the northernmost and southernmost parts of Japan, respectively [7]. No further surveys or cases have been reported since 1991.

E. brunetti infections have been recently diagnosed in many cases from samples submitted to our laboratory from commercial chicken farms [3]. This has forced us to review our concept of *E. brunetti* as a species capable of causing coccidiosis in Japan also. Characteristics of the Japanese isolate of *E. brunetti* haven't been evaluated still yet. For the verification, we describe a Japanese strain of *E. brunetti*, focusing on its pathogenicity and sensitivity to drugs in this paper.

MATERIALS AND METHODS

Parasite: The isolates of *E. brunetti*, as Nb strain, was derived from a single oocyst isolated from feces of breeder chickens in Miyazaki prefecture and has been maintained in our laboratory using specific-pathogen-free (SPF) layer chickens. The correct species identification and purity of the strain were confirmed by PCR employing an assay directed towards the ITS-1 [3].

Experimental design: *E. brunetti* infection was induced in a group of ten 35-day-old SPF chickens by oral inoculation with 1×10^2 , 1×10^3 , 1×10^4 or 1×10^5 sporulated oocysts/bird. The birds were raised in wire-floored cages for 7 days and then necropsied. Experimental infections were evaluated

*CORRESPONDENCE TO: KAWAHARA, F., Nippon Institute for Biological Science, 9-2221-1 Shin-machi, Ome, Tokyo 198-0024, Japan. e-mail: funuwo@gmail.com

©2014 The Japanese Society of Veterinary Science

This is an open-access article distributed under the terms of the Creative Commons Attribution Non-Commercial No Derivatives (by-nc-nd) License <<http://creativecommons.org/licenses/by-nc-nd/3.0/>>.

Table 1. The pathogenicity of the Japanese Nb strain of *E. brunetti*

Number of oocysts inoculated per bird	Mortality rate	Mean growth ratio ^{a)} (relative growth ratio)	Mean lesion score ^{b)}	
			Jejunum, ileum	Rectum
1×10^2	0/10	38.7 ± 8.3 (0.89)	1.7 ^{c)}	0.8 ^{c)}
1×10^3	0/10	$22.2 \pm 8.7^c)$ (0.51)	1.3 ^{c)}	0.6 ^{c)}
1×10^4	0/10	$9.3 \pm 8.2^c)$ (0.21)	1.3 ^{c)}	1.1 ^{c)}
1×10^5	3/10	$-4.2 \pm 4.9^c)$ (-0.1)	1.9 ^{c)}	1.4 ^{c)}
None	0/10	43.7 ± 7.4 (1.0)	0	0

a) (body weight at termination – body weight at initiation)/ body weight at initiation $\times 100$. b) Johnson and Reid [2]. c) Values with superscripts indicate significant difference ($P < 0.05$) from uninfected control group.

Table 2. Oocyst output of the Japanese Nb strain of *E. brunetti*

Number of oocysts inoculated per bird	Days after inoculation							
	4	5	6	7	8	9	10	11
1×10^2	-	4.7 ^{a)}	7.4	7.4	7.2	6.1	5.3	-
1×10^3	-	-	7.6	7.6	7.2	5.1	-	-
1×10^4	-	4.2	7.7	8.1	7.2	6.1	5.8	-
1×10^5	-	4.1	7.2	7.7	7.3	5.3	-	-
None	-	-	-	-	-	-	-	-

a) Oocysts/g feces (OPG) is shown by log. Detection limit is log2.0.

Table 3. Developing stages of the Japanese Nb strain of *E. brunetti* present in intestinal tissue

Day after inoculation	Mean scores of organism density ^{a)} (Types of emerging organisms ^{b)})				
	Duodenum	Jejunum	Ileum	Cecum	Rectum
1	0	0.5 (F)	0	0	0
2	0	1 (F)	0	0	0
3	0.5 (F)	1.5 (F)	0	0	0
4	0.5 (F>S)	2 (S)	2 (S)	1.5 (S)	1 (S)
5	2 (S)	2 (S>G)	2 (S>G)	2 (S>G)	2 (S>G)
6	0.5 (G)	1 (G>S)	1 (G>S)	1.5 (G)	1.5 (G)
7	0.5 (G)	1 (G)	1.5 (G)	1.5 (G)	1 (G)
8	0	0	0.5 (G)	1 (G)	0.5 (G)

Two birds were sampled daily after inoculation with 1×10^5 oocysts per bird.

a) 0=no organisms; 1=less than 10% of host cells are infected; 2=more than 10% of host cells are infected. b) F=first generation schizonts; S=other generation schizonts or immature gametocytes; G=mature gametocytes.

using growth ratio, mortality and intestinal lesion scores. The growth ratio was obtained individually with the following formula: (body weight at termination – body weight at initiation)/ body weight at initiation $\times 100$. Intestinal lesion scores were graded according to Johnson's method [2]. The oocysts excreted in feces were counted daily from 4 to 11 days post-inoculation (DPI). To observe the developing stages of infection with *E. brunetti*, 35-day-old SPF chickens were given 1×10^5 oocysts/bird, and then intestinal tissues were taken daily from two of these chickens from 1 to 8 days. The tissues were paraffin embedded, and sections were stained with hematoxylin and eosin. The density of the population of parasites was ranked at the observation site as 0 (no organisms), +1 (less than 10% of host cells are infected) and +2 (more than 10% of host cells are infected).

Evaluation of drug resistance: To evaluate the drug sensitivity, a group of ten 14-day-old SPF chickens were orally inoculated with 1×10^5 sporulated oocysts/bird, kept in wire-floored cages for 7 days and then necropsied. Four medicated infected, one unmedicated infected and one unmedicated uninfected (control) groups were included in this study. As sulfa anticoccidial drugs, diaveridine (19.2 ppm)/sulfaquinoxaline (76.8 ppm) obtained from Sumika Environment Science Co., Ltd. (Nishinomiya, Japan) and ormetoprim (75 ppm)/sulfamonomethoxine (225 ppm) obtained from Meiji Seika Pharma Co., Ltd. (Tokyo, Japan) were used in the drinking water on days 0 to 3 after infection. As ionophorous polyether anticoccidial drugs, salinomycin (50 ppm) obtained from Nichiku Yakuhin Kogyo Corporation (Ayase, Japan) and lasalocid (75 ppm) obtained from Scientific Feed

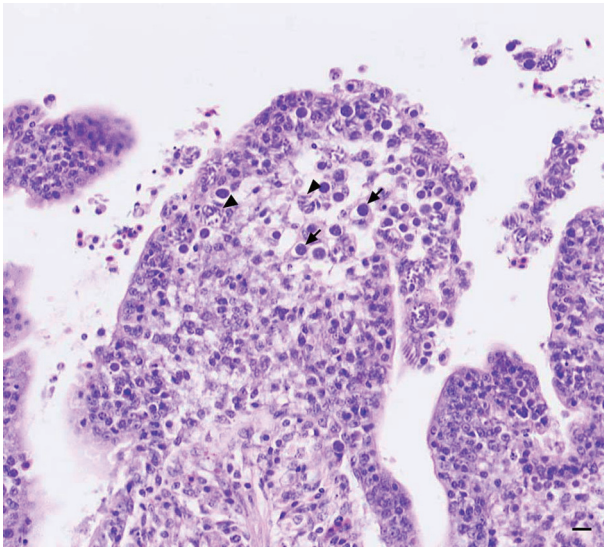


Fig. 1. Microscopic findings of the jejunum. 4DPI. Mature (arrowheads) and immature (arrows) schizonts are observed in the mucosal cells and subepithelial zone of the disrupted villi. HE stain. Bar=10 μ m.

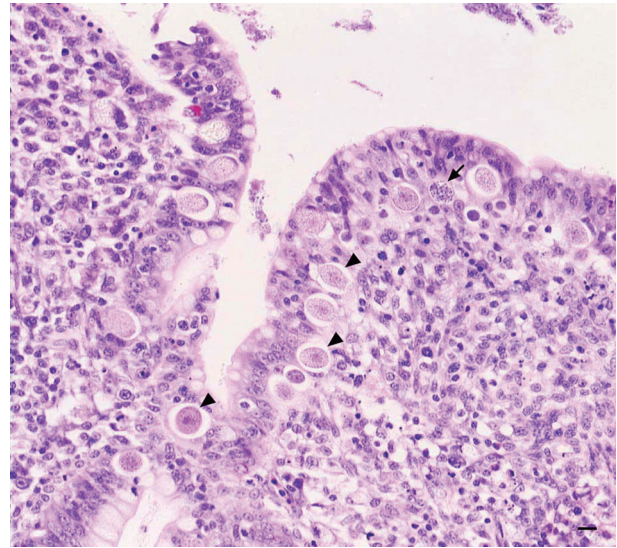


Fig. 2. Microscopic findings of the rectum. 6DPI. Mature female gametocytes (arrowheads) and mature male gametocytes (arrow) are observed in the mucosal cells and subepithelial zone of the villi. The number of female gametocytes is much larger than that of male gametocytes. HE stain. Bar=10 μ m.

Laboratory Co., Ltd. (Tokyo, Japan) were used in the feed continuously. The sensitivity against anticoccidial drugs is represented by calculating the anticoccidial index (ACI) according to the method of Merck Sharp & Dohme Co., Ltd. [5] as follows: $ACI = (\text{relative growth ratio} + \text{survival ratio}) - (\text{lesion index} + \text{oocyst index})$. The strain was considered sensitive if the ACI was >161 , partially resistant if the ACI was 121 to 160 and resistant if the ACI was <120 .

Animal care and use: The experiments presented here were carried out according to protocols pre-approved by the Animal Care and Use Committee of Nippon Institute for Biological Science (Tokyo, Japan) in accordance with Regulation of Animal Experimentation of Nippon Institute for Biological Science.

RESULTS

Experimentally infected chickens showed a great reduction in their body weight gain which correlated with the dose of oocysts (Table 1). There were 3 mortalities in the group that was infected with 1×10^5 oocysts. Despite showing the great reduction of body weight gains, the intestinal lesions in the infected chickens were rather mild. Typical lesions were found in the rectum, including slight swelling, a color change into whitish-orange and formation of a bellows-like-shape with folded circular rings along the tube. In the other intestinal compartment, the only abnormality observed was a slight paling of the serosal surface. There was no correlation between the output patterns and the number of inoculated oocysts. Oocysts were seen in droppings from 5 to 10 DPI among almost groups (Table 2). It indicates that prepatent and patent periods of the strain were about 5 and 6 days, respectively.

Histological observation of the developing stages of the parasite is summarized in Table 3, showing the infection rate of host cells and stage transition of parasites on each day after inoculation. Mature (arrowheads) and immature (arrows) schizonts were observed in the mucosal cells and subepithelial zone of the disrupted villi of the jejunum at 4 days after infection (Fig. 1). Mature female gametocytes (arrowheads) and mature male gametocytes (arrow) were observed in the mucosal cells and subepithelial zone of the villi of the rectum at 6 days after infection (Fig. 2). The number of female gametocytes was much larger than that of male gametocytes. The onset of parasite development occurred in the upper portion of the small intestine, and subsequently parasites were found in the lower tract. The parasite density in the jejunum of *E. brunetti*-infected SPF chickens was the highest among the locations examined, although the gross lesions were mild (Table 2). The ACIs of medicated and unmedicated infected groups are presented in Table 4. Of the 4 medicated infected groups, only the ACI of the salinomycin group was in the partial resistant. Other drugs were so effective that the *E. brunetti* infection was almost completely blocked.

DISCUSSION

Severe lesions were often observed in the field chickens infected with *E. brunetti* (data not shown). However, such lesions did not develop in the intestines of SPF chickens under experimental conditions in this study. This may be due to differences between commercial field chickens and SPF chickens to *E. brunetti* infection in the susceptibility. Otherwise, this may associate with *Clostridium perfringens* infection. Because necrotic enteritis and coccidiosis often

Table 4. Sensitivity of the Japanese Nb strain of *E. brunetti* against anticoccidial drugs^{a)}

Drug	Relative growth ratio	Survival ratio	Lesion index ^{b)}	Oocyst index ^{c)}	Anticoccidial index ^{d)} (ACI)
Diaveridine/ sulfaquinoxaline (in water)	94.10	100	0	0	194
Ormetoprim/ sulfamonomethoxine (in water)	96.51	100	0	0	197
Salinomycin (in feed)	49.18	100	1	5	143
Lasalocid (in feed)	96.88	100	0	0	197
None	-4.3	100	16	40	40

a) Each group contains ten birds which were inoculated with 1×10^5 oocysts per bird. b) Lesion index: the total amount of lesion score of ten birds based on Johnson and Reid [2]. c) Oocyst index: based on the ratio (%) of OPG to the none-drug group. 0–1%=0; 1–25%=5; 26–50%=10; 51–75%=20; and 76–100%=40. d) Anticoccidial index=(relative growth ratio + survival ratio) – (lesion index + oocyst index). ACI: 200–161 =sensitive; 121–160 =partially resistant; and <120 =resistant.

occur concurrently in a field flock [11]. Gross lesions resulting from co-infection become much severe. Actually, *C. perfringens* was also isolated from field chickens infected with *E. brunetti* in almost cases (data not shown). According to our observations in SPF chickens, the organisms first colonized the upper intestine and moved down to the lower portion. The accumulation of parasites was higher in the jejunum than in the other compartments examined. However, the major parasitic site has been generally considered to be the lower small intestine [1, 4].

Contrary to previous reports [8–10], our recent study revealed that *E. brunetti* is very prevalent in Japan [3]. In this study, we showed that *E. brunetti* infections with a Japanese isolate cause similar mortalities and suppression of body weight gain as other tested isolates [1, 4]. So, the Japanese Nb strain has similar high pathogenicity to oversea strains. Furthermore, the involvement of *E. brunetti* in field coccidiosis cases must be evaluated. The drug sensitivity was also found to be normal, although our strain was slightly resistant to salinomycin. This coccidiostatic drug is generally thought to be slightly ineffective against *E. brunetti* [6].

The reasons for the recent increase in the diagnosis of *E. brunetti* infections in Japan remain unclear. Improvements of the techniques for the detection of *E. brunetti* in field samples based on PCR, rather than morphological diagnosis, could account for this, at least in part. Traditional classification techniques use criteria, such as oocyst size, parasitic site in the intestine, gross lesion figures and variations in prepatent time. It has been well documented that several species overlap in their measured values or patterns using these criteria, leading to confusion in the species-determination process, especially when mixed infections are present. We suspect that the clinical signs attributed to *E. brunetti* infections in breeder pullet flocks have been misdiagnosed as those of *E. necatrix*. Actually, we experienced that only *E. brunetti* was detected by PCR in considerable samples which the field veterinarians had diagnosed as *E. necatrix* infection (data not shown).

Opinions on the prevalence of *E. brunetti* were basically derived from information supplied from field surveys [8–10]. These were performed mainly on broiler flocks, while recent data for detection came from breeder pullet and layer chicken flocks [3]. *E. brunetti* was commonly thought to infect both younger and older chicken flocks [4]. Therefore, the epidemiology of *E. brunetti* should be evaluated using surveys from not only broiler flocks, but also breeder pullet and layer chicken flocks.

From the recent and present findings, the broad distribution and pathogenicity of *E. brunetti* in Japan has emerged. This indicates that an appropriate plan to confront the risk associated with outbreaks of this species is required. The fact that *E. brunetti* outbreaks are usually found in older chicken flocks means that using coccidiostatic drugs that are normally applied extensively to broilers would not be suitable for this species. Vaccination would be the best method to mitigate this risk, but appropriate vaccines effective against this species are not available in Japan. Therefore, development of an effective *E. brunetti* vaccine that is safe for use in the poultry industry in Japan is urgently required.

ACKNOWLEDGMENTS. The authors thank Eri Tomeno, Fumio Koyama and Hitomi Tomioka for their technical assistance.

REFERENCES

1. Davies, S. F. M. 1963. *Eimeria brunetti*, an additional cause of intestinal coccidiosis in the domestic fowl in Britain. *Vet. Rec.* **75**: 1–4.
2. Johnson, J. and Reid, W. M. 1970. Anticoccidial drugs: lesion scoring techniques in battery and floor-pen experiments with chickens. *Exp. Parasitol.* **28**: 30–36. [Medline] [CrossRef]
3. Kawahara, F., Taira, K., Nagai, S., Onaga, H., Onuma, M. and Nunoya, T. 2008. Detection of five avian *Eimeria* species by species-specific real-time polymerase chain reaction assay. *Avian Dis.* **52**: 652–656. [Medline] [CrossRef]
4. McDougald, L. R. and Fitz-Coy, S. H. 2008. Coccidiosis. pp.

- 1068–1080. *In*: Diseases of Poultry, 12th ed. (Saif, Y. M., Fadly, A. M., Glisson, J. R., McDougald, L. R., Nolan, L. K. and Swayne, D. E. eds.), Blackwell Publishing, Ames.
5. Merck Sharp & Dohme Company Ltd. 1998. The control of coccidiosis. pp. 2–4. *In*: MSD Technical Booklet.
6. Migaki, T. T., Chappel, L. R. and Babcock, W. E. 1979. Anti-coccidial efficacy of a new polyether antibiotic, salinomycin, in comparison to monensin and lasalocid in battery trials. *Poult. Sci.* **58**: 1192–1196. [[Medline](#)] [[CrossRef](#)]
7. Nakamura, T., Kawaguchi, H. and Imose, J. 1990. Identification of *Eimeria brunetti* using glucose isomerase and lactate dehydrogenase. *Nihon Juigaku Zasshi* **52**: 859–860. [[Medline](#)] [[CrossRef](#)]
8. Oikawa, H., Kawaguchi, H., Nakamoto, K. and Tunoda, K. 1974. Field surveys on coccidial infection in broiler in Japan—results obtained in spring and summer in 1973. *Nihon Juigaku Zasshi* **36**: 321–328. [[Medline](#)] [[CrossRef](#)]
9. Oikawa, H., Kawaguchi, H., Nakamoto, K. and Tunoda, K. 1975. Field surveys on coccidial infection in broiler in Japan—results obtained in autumn and winter and summarized in 1973. *Nihon Juigaku Zasshi* **37**: 271–279. [[Medline](#)] [[CrossRef](#)]
10. Oikawa, H., Kawaguchi, H., Nakamoto, K. and Tunoda, K. 1977. Field surveys on coccidial infection in broiler in Japan in 1974 and 1975. *Nihon Juigaku Zasshi* **39**: 127–134. [[Medline](#)] [[CrossRef](#)]
11. Opengart, K. 2008. Necrotic enteritis. pp. 872–879. *In*: Diseases of Poultry, 12th ed. (Saif, Y. M., Fadly, A. M., Glisson, J. R., McDougald, L. R., Nolan, L. K., Swayne, D. E. eds.), Blackwell Publishing, Ames.
12. Shirley, M. W., Smith, A. L. and Tomley, F. M. 2005. The biology of avian *Eimeria* with an emphasis on their control by vaccination. *Adv. Parasitol.* **60**: 285–330. [[Medline](#)] [[CrossRef](#)]
13. The National Veterinary Assay Laboratory 2011. p. 61. *In*: Annual Report of the National Veterinary Assay Laboratory.