

Case Report

---

# Identification of Metastatic Conjunctival Squamous Cell Carcinoma through Neck Palpation

Thamanna Nishath<sup>a</sup> Minh T. Nguyen<sup>a</sup> Michael Wu<sup>b</sup>  
Desiree A. Marshall<sup>c</sup> Andrew W. Stacey<sup>a</sup>

<sup>a</sup>Department of Ophthalmology, University of Washington, Seattle, WA, USA; <sup>b</sup>Department of Ophthalmology, Kaiser Permanente, Seattle, WA, USA; <sup>c</sup>Department of Pathology, University of Washington, Seattle, WA, USA

## Keywords

Neck palpation · Nodal metastasis · Conjunctival squamous cell carcinoma

## Abstract

An 80-year-old male with a distant 10 pack-years smoking history and squamous cell carcinoma (SCCA) of the scalp diagnosed 15 years ago presented with a new right nasal bulbar conjunctival lesion found to be invasive SCCA. The patient was started on interferon alfa-2b for 5 months until there was no evidence of residual disease. During a follow-up visit 10 months after diagnosis and during routine ophthalmic follow-up, an enlarged right submandibular lymph node was found through neck palpation and revealed to be SCCA without extranodal extension. The lesion was likely to have metastasized from his right conjunctival squamous cell carcinoma (CSCCA). Regional lymph nodes are a commonplace of metastasis for CSCCA making neck palpation a reasonable and recommended part of clinical examination to monitor for metastasis. This is the first known case of identifying regional metastasis of CSCCA through neck palpation.

© 2022 The Author(s).  
Published by S. Karger AG, Basel

## Introduction

Conjunctival squamous cell carcinoma (CSCCA) is rare, with an incidence ranging from 0.02 to 3.5 per 100,000 worldwide [1]. Metastasis from CSCCA is rarer ranging from ~0.02 to 4% of all CSCCA cases. Of this very small subset reported in the literature, metastasis has been

found distally or regionally – specifically, in the submandibular, preauricular, cervical, and parotid lymph nodes, usually identified through soft tissue imaging and confirmed with biopsy [2–8]. None have been found through neck palpation. Some authors recommend neck-lymph node palpations as part of an ophthalmologic exam in evaluating for regional spread; this is already common for conjunctival melanoma where nodal metastasis is more common [6, 8–11]. However, to the best of our knowledge, there are no clear guidelines on this practice and there has been no report of CSCCA lymph node metastases diagnosed through neck palpation during a routine ophthalmic follow-up exam. This report describes a case of metastatic CSCCA identified through lymph node palpation during the ophthalmic exam. The study adhered to the tenets of the Declaration of Helsinki and was HIPAA compliant.

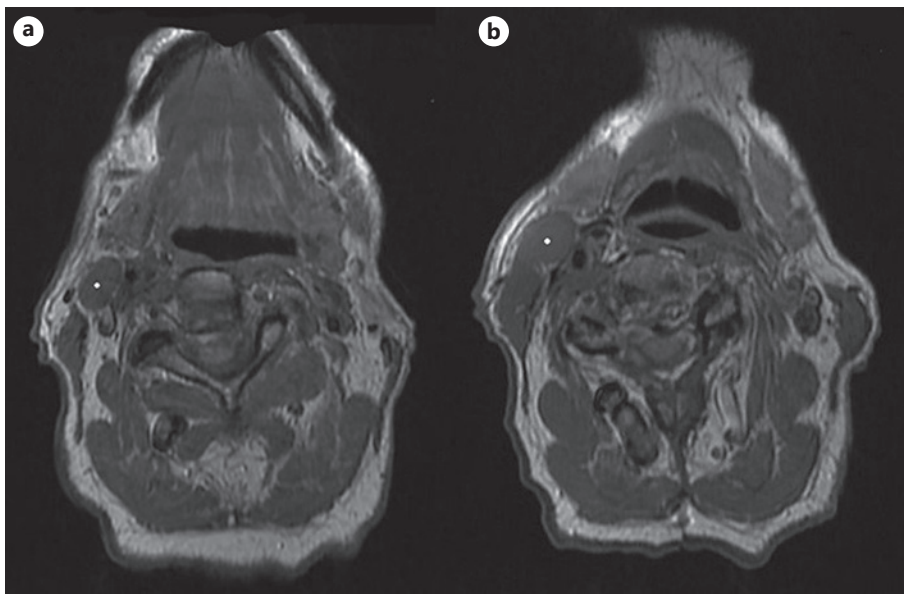
## Case Presentation

An 80-year-old male patient with light skin complexion presented with a new lesion in the nasal bulbar conjunctiva of the right eye. The patient had a 20-year history of UV exposure while living in a sunny climate in the Western USA, a distant 10 pack-years smoking history, and was not immunosuppressed. The patient had a history of squamous cell carcinoma (SCCA) of the scalp 15 years prior and history of excisional biopsy of a temporal pinguecula with pathology showing mild basilar nuclear atypia of the epithelium consistent with actinic changes in the right eye 4 years prior. Since there was no evidence of conjunctival intraepithelial neoplasia in the temporal pinguecula, no adjuvant therapy was given except for cryotherapy. The new nasal bulbar conjunctival lesion appeared thick, gelatinous, with overlying leukoplakia and corneal involvement. An excisional biopsy of the nasal lesion revealed invasive SCCA with involvement of the peripheral margin. Given previous findings, the patient likely had multiple areas of solar damage. The new lesion was not a late recurrence of the temporal pterygium. He was treated with adjuvant interferon alfa-2b (IFN-a2b) eyedrops, 1 million units/mL in the right eye four times daily and referred to the ocular oncology service. The IFN-a2b was continued for 5 months and discontinued when there was no evidence of conjunctival abnormality. At each visit, the patient was examined both at the slit lamp and with neck palpation.

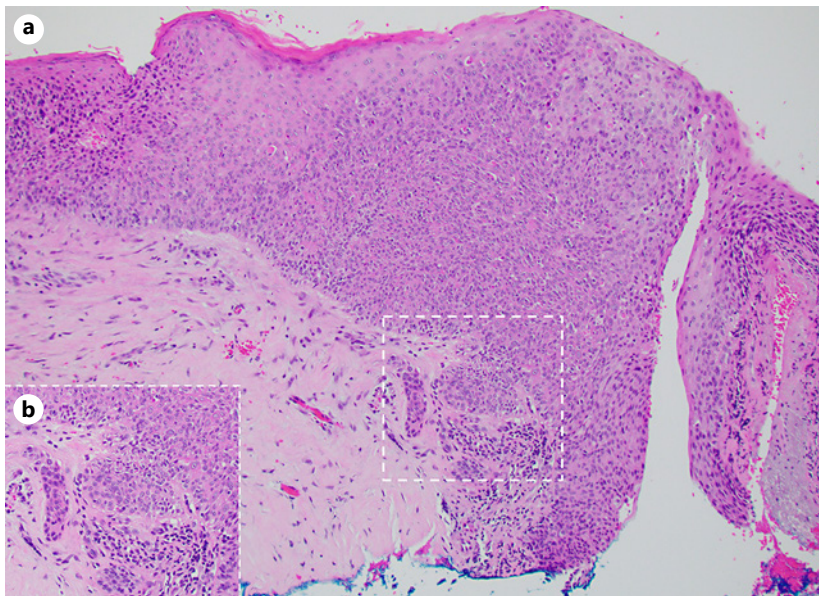
Ten months after diagnosis, he was found to have an enlarged right submandibular lymph node which was not visible and was unknown to the patient. The node was detected only after neck palpation during an ophthalmology follow-up visit. He underwent a neck MRI, which identified enlarged level 3 lymph nodes on the right side measuring 14 mm × 19 mm (Fig. 1a) and 19 mm × 11 mm (Fig. 1b) in dimensions. The patient underwent an ultrasound-guided fine needle biopsy, which showed metastatic SCCA. Thorough examination and workup with otolaryngology did not reveal any other primary site. He was subsequently treated with modified radical neck dissection. Only one node (1 of 6 level III nodes) was found to contain SCCA without extranodal extension (Fig. 2). He underwent a full staging workup, including PET scan, which failed to reveal any additional disease. Adjuvant radiotherapy to the neck was recommended, but the patient declined. He has been monitored since neck dissection and he has had no local recurrence in the conjunctiva nor distant recurrence in 4 years.

## Discussion

CSCCA is rare, despite being the most common neoplasia in the conjunctiva. CSCCA is generally considered a low-grade malignancy and metastasis is also rare [4, 7]. Due to its rarity, there are no formal guidelines for evaluation, monitoring, and treatment of metastatic CSCCA.



**Fig. 1.** Axial T1 magnetic resonance image of the neck showing two right-sided level 3 enlarged nodes measuring 19 mm × 11 mm (**a**, white mark) and 14 mm × 19 mm (**b**, white mark) in dimensions.



**Fig. 2. a** H&E, ×100. Conjunctival incisional biopsy: full-thickness epithelial atypia with infiltration of microscopic squamous nests into the substantia propria (i.e., microinvasive SCCA). **b Inset.** H&E, ×200. Higher power view of microinvasion.

However, most authors recommend neuroimaging of the head and neck region for surveillance because regional drainage patterns of the conjunctiva lead to neck lymph nodes [4, 7]. The majority of reported metastases from conjunctival carcinomas have been found in regional lymph nodes. This is also the case for CSCCA. Yousef and Finger [8] reported 1 metastasis (regional lymph node) in a cohort of  $n = 101$  patients with CSCCA. Cervantes et al. [5] reported 2 cases ( $n = 287$ ) in the submandibular and preauricular lymph nodes, Bhattacharyya et al. [4]

reported 1 case ( $n = 33$ ) in the parotid gland, McKelvie et al. [1] with 1 case ( $n = 26$ ) in the cervical lymph node, and Iliff et al. [2] with 1 case ( $n = 27$ ) in the parotid gland. Tabbara et al. [3] reported that out of 10 metastatic cases evaluated, 9 cases were found to metastasize to regional lymph nodes (submandibular and submaxillary glands) [3, 12]. These have been found incidentally or due to other modes of surveillance but never through neck palpation.

Unlike head and neck malignancies where ample literature has established lymph node metastasis as a prognostic factor, there has not been any definitive correlation for CSCCA [12]. El-Hadad et al. [12] were unable to assess prognosis of neck metastases of CSCCA due to a small sample size of 4 nodal metastasis cases ( $n = 44$ ); 1 case was found at presentation while 3 cases were found at follow-up with a median time of 36.5 months from diagnosis to nodal metastasis. However, based on their finding of 9% nodal metastasis, they emphasized the importance of palpation and imaging during both presentation and follow-up as this could be a mechanism to catch it earlier [12]. Historically, identification of metastasis has been reported through CT or MRI and confirmed with biopsy.

The patient had a remote history of cutaneous SCCA of the scalp. The patient has had multiple scalp lesions removed and it is unknown where the location of the remote cutaneous SCCA was located. Theoretically, the lymph node metastasis might be from a remote cutaneous SCCA, but given the location and time correlation to the conjunctival SCCA, this seems like a more reasonable etiology.

Neck palpation is simple, fast, and effective. In cases of conjunctival metastatic melanoma, it has been widely recommended to conduct nodal palpation as part of a careful clinical exam since regional lymph nodes are typically the first site of metastasis and metastasis is far more common in conjunctival melanoma compared to CSCCA [9]. This has not been the case for CSCCA, most likely due to its rarity. During our patient's routine follow-up examination, neck palpation was completed in approximately 1 min and led to the critical identification of confirmed metastasis decreasing the lag time in diagnosis and leading to many years of local and regional tumor control. Based on the literature reviewed and to our best knowledge, there has been no other reported case of CSCCA metastasis identified through the neck palpation technique.

While formal recommendations for complete surveillance are still unclear, based on this case of CSCCA metastasis identified through neck lymph node palpation, we recommend that at minimum, neck palpation should be included in any ophthalmic exam as a standard of screening for patients with any epithelial or melanocytic tumor of the conjunctiva. The exam is simple, fast, no-risk, and can potentially detect CSCCA metastases in their most likely location. The potential benefits of routine neck palpation in patients with CSCCA, including earlier diagnosis of metastases, far outweigh the associated, albeit negligible, examination completion time.

## Statement of Ethics

This study protocol was approved by the Institutional Review Board of the University of Washington (STUDY00010261). Written informed consent was obtained from the patient for publication of this case report and any accompanying images.

## Conflict of Interest Statement

The authors have no conflicts of interest to declare.

## Funding Sources

The authors have no funding sources to declare for this study.

## Author Contributions

Thamanna Nishath wrote the first draft. Minh T. Nguyen, Michael Wu, Desiree A. Marshall, and Andrew W. Stacey contributed to the write up, figures, and critical revisions.

## Data Availability Statement

In this case report of 1 patient, all data and supporting findings are included in this article. Further inquiries can be directed to the corresponding author.

## References

- 1 McKelvie PA, Daniell M, McNab A, Loughnan M, Santamaria JD. Squamous cell carcinoma of the conjunctiva: a series of 26 cases. *Br J Ophthalmol*. 2002;86(2):168–73.
- 2 Iliff WJ, Marback R, Green WR. Invasive squamous cell carcinoma of the conjunctiva. *Arch Ophthalmol*. 1975; 93(2):119–22.
- 3 Tabbara KF, Kersten R, Daouk N, Blodi FC. Metastatic squamous cell carcinoma of the conjunctiva. *Ophthalmology*. 1988;95(3):318–21.
- 4 Bhattacharyya N, Wenokur RK, Rubin PA. Metastasis of squamous cell carcinoma of the conjunctiva: case report and review of the literature. *Am J Otolaryngol*. 1997 May 1;18(3):217–9.
- 5 Cervantes G, Rodríguez AA Jr, Leal AG. Squamous cell carcinoma of the conjunctiva: clinicopathological features in 287 cases. *Can J Ophthalmol*. 2002 Feb;37(1):14–20; discussion 19–20
- 6 Faustina M, Diba R, Ahmadi MA, Gutstein BF, Esmaeli B. Patterns of regional and distant metastasis in patients with eyelid and periocular squamous cell carcinoma. *Ophthalmology*. 2004 Oct 1;111(10):1930–2.
- 7 Kim SK, Gombos DS, Esmaeli B. Management of conjunctival neoplasms. *Ophthalmic oncology*. Springer; 2010. p. 127–38.
- 8 Yousef YA, Finger PT. Squamous carcinoma and dysplasia of the conjunctiva and cornea: an analysis of 101 cases. *Ophthalmology*. 2012 Feb;119(2):233–40.
- 9 Wong JR, Nanji AA, Galor A, Karp CL. Management of conjunctival malignant melanoma: a review and update. *Expert Rev Ophthalmol*. 2014 Jun;9(3):185–204.
- 10 Bellerive C, Berry JL, Polski A, Singh AD. Conjunctival squamous neoplasia: staging and initial treatment. *Cornea*. 2018;37(10):1287–91.
- 11 Pe'er J, Frenkel S. Conjunctival and corneal tumors: examination techniques. *Clinical ophthalmic oncology*. Springer; 2019. p. 131–5.
- 12 El-Hadad C, Rubin ML, Nagarajan P, Ford JR, Xu S, Ning J, et al. Prognostic factors for orbital exenteration, local recurrence, metastasis, and death from disease in conjunctival squamous cell carcinoma. *Ophthalmic Plast Reconstr Surg*. 2020;37(3):262–8.