

Clinical Report

Renal-limited thrombotic microangiopathy and acute interstitial nephritis with a single dose of quinine

Jobert Anjelo^{1,2}, Nitesh Rao¹, Vinoi G. David¹, Sophia Otto³ and Graeme Russ¹

¹Central Northern Adelaide Renal Transplantation Services, Royal Adelaide Hospital, Adelaide, Australia, ²Division of Nephrology, Royal Adelaide Hospital, Adelaide, SA, Australia and ³Department of surgical pathology, Royal Adelaide Hospital, SA Pathology, Adelaide, SA, Australia

Correspondence and offprint requests to: Jobert Anjelo; E-mail: chetacut@yahoo.com

Abstract

Quinine has been reported to cause acute kidney injury by various mechanisms. The response to quinine can result in a spectrum of problems ranging from isolated thrombocytopenia to thrombotic microangiopathy (TMA) to disseminated intravascular coagulation. Quinine has also been reported to cause acute interstitial nephritis (AIN). We report an unusual presentation where both of these entities of renal-limited TMA and AIN were precipitated by a single dose of quinine.

Keywords: acute renal failure; interstitial nephritis; quinine; thrombotic microangiopathy

Background

Quinine has been reported to cause acute kidney injury by various mechanisms. The response to quinine can result in a spectrum of diseases ranging from isolated thrombocytopenia to thrombotic microangiopathy (TMA) to disseminated intravascular coagulation (DIC) [1]. Quinine has also been reported to cause acute interstitial nephritis (AIN) [2]. We report an unusual presentation where both of these entities of renal-limited TMA and AIN were precipitated by a single dose of quinine.

Case

A 66-year-old woman presented with 8 days of diarrhoea, vomiting, epistaxis, muscle cramps, bilateral leg swelling, oliguria and lower abdominal and bilateral flank pain. She had acute renal failure with serum creatinine rising to 1295 $\mu\text{mol/L}$ (normal range: 50–120 $\mu\text{mol/L}$) from a baseline of 86 $\mu\text{mol/L}$ 2 weeks before. She reported taking one tablet (300 mg) of quinine 8 days prior, for lower limb muscle cramps. There was a history of chronic use of tonic water to relieve muscle cramps in the distant past.

She had a past medical history of rheumatoid arthritis but had not been on disease-modifying rheumatoid arthritis drugs or NSAIDs for the past 5 years. Physical examination on presentation revealed signs of volume overload and her blood pressure was 140/90 mmHg. Investigations revealed anaemia but no thrombocytopenia (Hb 80 g/L, platelets $173 \times 10^9/\text{L}$), raised serum LDH 1014 (110–230 U/L), low serum haptoglobin 0.46 g/L (0.50–2.50 g/L), eosinophilia $0.86 \times 10^9/\text{L}$ (5.6%) with peripheral smear showing mild polychromasia, but no schistocytes on two occasions were

detected by the haematologist; coagulation studies were unremarkable. Renal functions revealed a raised creatinine of 1295 $\mu\text{mol/L}$ and urea of 51 mmol/L.

Urine microscopy revealed haematuria and eosinophils, but no dysmorphic red blood cells or casts. Serum complements were normal, and quinine-dependent platelet antibodies were negative. ANCA and dsDNA were negative with a positive ANA (1/80 titre). The rheumatoid factor and anti-CCP were positive. Her hepatitis serology, serum electrophoresis and direct Coombs tests were negative. Stool microscopy and culture were negative for leucocytes and bacteria. Kidney biopsy revealed fibrinoid material with obliteration of capillary lumina and other changes consistent with TMA, along with evidence of AIN with a prominence of eosinophils (Figures 1 and 2). Immunofluorescence staining was negative for immunoglobulin. Electron microscopy showed a reduction in capillary lumina by swollen endothelial cells and presence of granulocytes, but no electron-dense deposits (Figure 3).

She was managed with five sessions of haemodialysis. She was initiated on steroids (prednisolone 60 mg daily for 14 days and tapered over 6 weeks). Two weeks following treatment, her urine output improved and she became dialysis independent. Plasma exchange was not offered as her renal function and haematological parameters improved with the above management. Her serum creatinine stabilized at 300 $\mu\text{mol/L}$ prior to discharge from hospital. She was reviewed after 3 weeks in the outpatient clinic. She was asymptomatic and her investigations showed a normal LDH (161 U/L), haemoglobin (120 g/L) and creatinine (143 mmol/L).

Discussion

This case demonstrates the presence of two distinct pathologies related to quinine toxicity, interstitial nephritis and

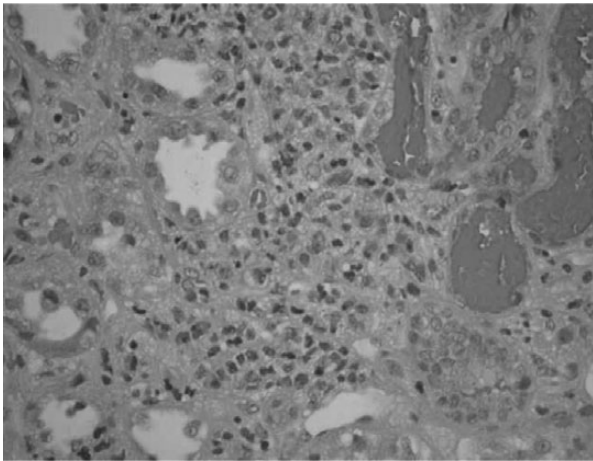


Fig. 1. Eosinophils in the interstitial space and fibrinoid material in the capillary lumina demonstrating a combination of TMA and AIN.

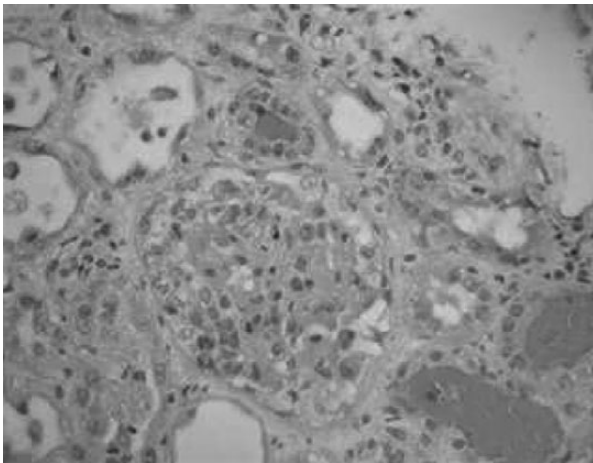


Fig. 2. Eosinophils in the interstitial space and fibrinoid material in the capillary lumina demonstrating a combination of TMA and AIN.

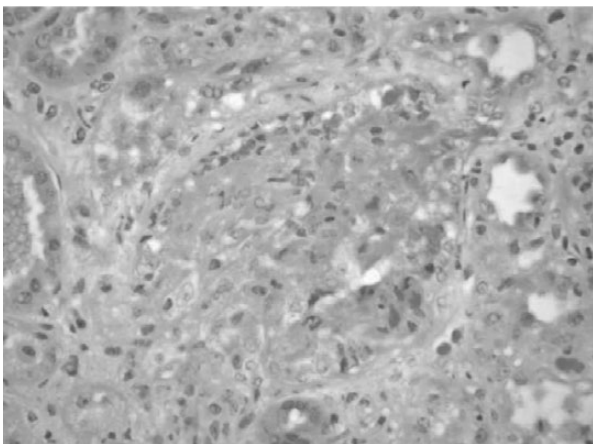


Fig. 3. High power view of glomerulus showing narrowing of capillary lumina and fibrin thrombi.

TMA. Quinine is commonly present in beverages such as tonic water and lemon, lime and bitters. It is also used in over-the-counter preparations to treat muscle cramps.

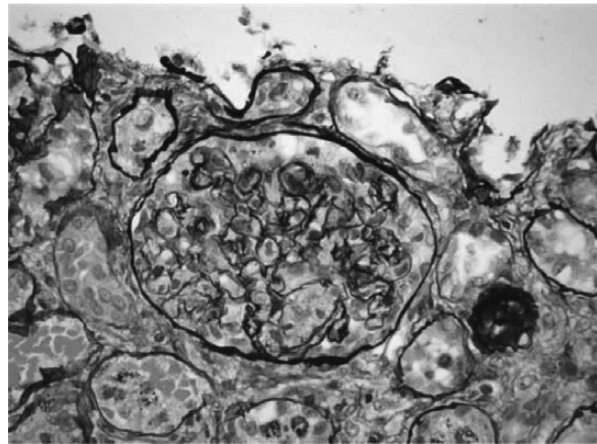


Fig. 4. Jones silver stain showing capillary lumina narrowing and fibrin thrombi.

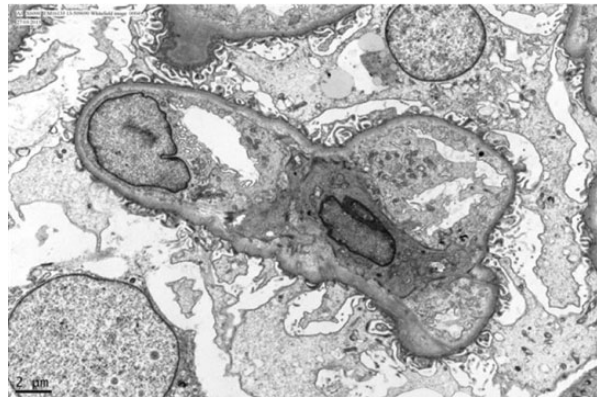


Fig. 5. Electron microscopic view demonstrating endothelial swelling and granulocyte.

The patient described in our report may have been previously sensitized to quinine from the tonic water which she regularly consumed in the past [3]. She had not consumed tonic water for 6 months (Figure 4).

Quinine can result in a spectrum of diseases ranging from isolated thrombocytopenia to TMA or DIC depending on the degree of the coagulopathy. TMA is characterized by microangiopathic haemolytic anaemia and thrombocytopenia [4]. In drug-induced TMA, thrombocytopenia and anaemia may be less severe and renal insufficiency more prominent [5]. Thrombocytopenia with or without microangiopathy following quinine is often referred to as quinine 'hypersensitivity'. When schistocytes are present, it is frequently termed 'quinine-associated TTP/HUS'. Our patient had renal failure requiring dialysis, anaemia, raised LDH and low haptoglobin, but no schistocytes or thrombocytopenia (Figure 5).

Patients with quinine-associated thrombocytopenia have been shown to have antibodies directed against platelets, leukocytes, erythrocytes and endothelial cells [6]. Why some individuals are more susceptible than others is not clear. The mechanisms of antibody formation are thought to be by two processes: (i) the formation of new or altered antigenic sites secondary to the binding of quinine (drug dependent) and (ii) the stimulation of true

autoantibody formation without the need for the drug (drug independent). It has been shown that endothelial cells share the glycoprotein IIIa quinine-dependent epitope found on platelets. It is presumed that the antibody damage to endothelial cells leads to the formation of the TMA and haemolytic anaemia. The epitopes recognized by antibodies from patients who have quinine-induced thrombocytopenia have been characterized for selected target molecules. Precise localization, however, has been achieved only for a limited number of quinine-dependent antibodies as this is a rare phenomenon. Antibodies to GP IIb/IIIa and GP Ib/IX have been described when platelets are the target and GP IIIa, when it is the endothelial cell. In our case, the antibodies were undetectable for possibly two reasons: (i) the antibodies may have been directed against erythrocytes, eosinophils, neutrophils or lymphocytes and (ii) it has been shown in the past that these antibodies are consumed early in the course of illness resulting in low or theoretically undetectable levels. It has also been shown in several case series that ADAMTS13 activity is not severely deficient in these patients. This was not tested in the patient described above [6].

The use of plasma exchange in quinine-induced TMA is questionable when compared with idiopathic TMA and it has also been argued if patients are subjected unnecessarily to this intervention, given the risks of anaphylaxis, allergies and infection. It has been previously shown that both dialysis and particularly plasma exchange are relatively ineffective in the removal of quinine, and that allowing for renal excretion of the drug with supportive care may be a more reasonable approach, as demonstrated in our case too [7, 8].

Quinine-induced AIN has been reported in two case reports previously, but without evidence of TMA in those cases [2, 9]. Drug hypersensitivity reactions are a common cause of AIN. The clinical presentation of drug-induced AIN can be quite variable, with only 30% of the patients having the classic extra renal symptoms and signs of hypersensitivity, which was absent in our patient [10]. Quinine-induced AIN responds well to steroids along with withdrawal of the drug. Diarrhoea in our patient was possibly a side effect of quinine and there was no evidence of infection. In our case, the patient did have eosinophils in the urine without other peripheral manifestations. To our knowledge, this is the first case reported to have both entities (TMA and AIN) present simultaneously and causing renal failure after ingestion of a single dose of quinine.

Quinine is metabolized in the liver. Quinine is not cleared by dialysis. Quinine is bound to a protein called

α_1 -acid glycoprotein and is metabolized to 3-hydroxyquinine and 10,11-dihydroxydihydroquinine [11]. In chronic renal failure patients, α_1 -acid glycoprotein levels are high and free quinine levels are low.

Conclusion

This is an instructive case report of an unusual presentation of quinine ingestion. As quinine can cause a wide variety of clinical manifestations, there must be a high index of suspicion in patients with a similar presentation. Failure to do so can otherwise result in a serious yet preventable recurrence.

Conflict of interest statement. None declared.

References

1. Gottschall J, Elliot W, Lianos E *et al.* Quinine-induced immune thrombocytopenia associated with hemolytic uremic syndrome: a new clinical entity. *Blood* 1991; 77: 306–310
2. Pawar R, Jacobs GH, Smith MC. Quinine-associated acute interstitial nephritis. *Am J Kidney Dis* 1994; 24: 211–214
3. Belkin GA. Cocktail purpura: an unusual case of quinine sensitivity. *Ann Intern Med* 1967; 66: 583
4. Allford SL, Hunt BJ, Rose P *et al.* Guidelines on the diagnosis and management of the thrombotic microangiopathic haemolytic anaemias. *Br J Haematol* 2003; 120: 556
5. Visentin GP, Liu CY. Drug-induced thrombocytopenia. *Hematol Oncol Clin North Am* 2007; 21: 685–696
6. Park Y, Hay S, Brecher M. Is it quinine TTP/HUS or quinine TMA? ADAMTS13 levels and implications for therapy. *J Clin Apher* 2009; 24: 115–119
7. Rabetoyan G, Hansen M, Brosnahan G *et al.* The lady who had muscle cramps and developed thrombotic microangiopathy. *Nephrol Dial Transplant* 2000; 15: 1464–1467
8. Pisoni R, Ruggenenti P, Remuzzi G. Drug induced thrombotic microangiopathy: incidence, prevention and management. *Drug Saf* 2001; 24: 491–501
9. McDonald SP, Shanahan EM, Thomas AC *et al.* Quinine-induced hemolytic uremic syndrome. *Clin Nephrol* 1997; 47: 397–400
10. Delve P, Lau M, Yun K *et al.* Omeprazole-induced acute interstitial nephritis. *N Z Med J* 2003; 116: U332
11. Roy L, Leblanc M, Bannon P *et al.* Pharmacokinetics of single-dose primaquine in patients with chronic kidney dysfunction. *Br J Clin Pharmacol* 2002; 54: 604–609

Received for publication: 10.1.14; Accepted in revised form: 25.3.14