



Implantation of cardiac defibrillator in an infant with hypertrophic cardiomyopathy and newly identified *MYBP3* mutation

Hipertrofik kardiyomiyopati tanılı süt çocuğunda yeni tanımlanan *MYBP3* mutasyonu ve implantable defibrilatör uygulaması

Osman Güvenç¹, Kadri Karaer², Sertaç Haydin³, Alper Güzeltaş¹, Yakup Ergül⁴

¹Department of Pediatric Cardiology, İstanbul Sağlık Bilimleri University, Mehmet Akif Ersoy Thoracic and Cardiovascular Surgery Training and Research Hospital, İstanbul, Turkey

²Department of Clinical Genetics, Dr. Ersin Arslan Hospital, Gaziantep, Turkey

³Department of Cardiovascular Surgery, İstanbul Sağlık Bilimleri University, Mehmet Akif Ersoy Thoracic and Cardiovascular Surgery Training and Research Hospital, İstanbul, Turkey

⁴Department of Pediatric Cardiology and Electrophysiology, İstanbul Sağlık Bilimleri University, Mehmet Akif Ersoy Thoracic and Cardiovascular Surgery Training and Research Hospital, İstanbul, Turkey

The known about this topic

Hypertrophic cardiomyopathy has the highest incidence rate among congenital heart diseases and significant variations in its clinical, morphologic, and hemodynamic characteristics. It is characterized by ventricular hypertrophy. It develops as a result of mutations in genes that code the sarcomere protein structures in cardiac muscle. If there is a risk of sudden death, it is recommended to implant cardioverter-defibrillators.

Contribution of the study

In this article, we present a case of an infant with severe hypertrophic cardiomyopathy who underwent epicardial cardioverter-defibrillator implantation due to surgical septal myectomy and the risk of sudden death, with a previously unspecified mutation in the *MYBP3* gene.

Abstract

Hypertrophic cardiomyopathy has the highest incidence rate among genetically inherited cardiac diseases. It develops as a result of mutations in genes related to the sarcomere protein in cardiac muscle. Generally, this results in asymmetrical hypertrophy. Patients who are symptomatic and have a significantly narrow left ventricular outflow tract should receive surgical treatment, whereas patients with a sudden cardiac death risk should receive treatment with an implantable cardiac defibrillator. This paper presents an infant with hypertrophic cardiomyopathy who was recently identified as having a mutation that resulted in a deletion-insertion type framework shift in the gene *MYBP3*, who had family history of sudden death at a young age, and received myectomy and treatment with an implantable cardiac defibrillator in the same session due to a severely narrowed left ventricular outflow tract.

Anahtar sözcükler: Hypertrophic cardiomyopathy; implantable cardiac defibrillator; *MYBP3* gene; new mutation; septal myectomy

Öz

Hipertrofik kardiyomiyopati, en sık görülen genetik geçişli kalp hastalığıdır. Kalp kasındaki sarkomerin proteini ile ilgili genlerdeki mutasyonlar sonucu ortaya çıkar. Genelde asimetric olan hipertrofi meydana gelir. Semptomatik olan, önemli sol ventrikül çıkım yolu darlığı olan hastalarda cerrahi tedavi, ani kardiyak ölüm riski olan hastalarda ise kardiyak defibrilatör implante edilmelidir. Bu yazıda, ailesinde genç yaşta ani ölüm öyküsü olan ve ciddi sol ventrikül çıkım yolu darlığı nedeni ile aynı seansta septal miyektomi ve implantable kardiyak defibrilatör uygulaması yapılan, *MYBP3* geninde delesyon-insersiyon tarzında çerçeve kaymasına neden olan yeni mutasyon saptanan hipertrofik kardiyomiyopati süt çocuğu olgu sunuldu.

Anahtar sözcükler: Hipertrofik kardiyomiyopati, implantable kardiyak defibrilatör, *MYBP3* geni, septal miyektomi, yeni mutasyon

Cite this article as: Güvenç O, Karaer K, Haydin S, Güzeltaş A, Ergül Y. Implantation of cardiac defibrillator in an infant with hypertrophic cardiomyopathy and newly identified *MYBP3* mutation. Turk Pediatri Ars 2020; 55(3): 304-8.

Corresponding Author/Sorumlu Yazar: Osman Güvenç E-mail/E-posta: osmanguvenc1977@gmail.com

Received/Geliş Tarihi: 23.07.2018 **Accepted/Kabul Tarihi:** 17.10.2018

©Copyright 2020 by Turkish Pediatric Association - Available online at www.turkpediatriarsivi.com

©Telif Hakkı 2020 Türk Pediatri Kurumu Derneği - Makale metnine www.turkpediatriarsivi.com web adresinden ulaşılabilir.

DOI: 10.14744/TurkPediatriArs.2018.35556

OPEN ACCESS This work is licensed under a Creative Commons Attribution-NonCommercial 4.0 International License.



Introduction

Hypertrophic cardiomyopathy (HCMP) has the highest incidence rate among congenital heart diseases, and significant variations in its clinical, morphologic, and hemodynamic characteristics. It is characterized by ventricular hypertrophy. Its incidence rate in the general population is approximately 1 in 500 (1, 2). Almost all patients have an autosomal dominant inheritance. It develops as a result of mutations in genes that code the sarcomere protein structures in cardiac muscle. To date, 25 genes associated with hypertrophic cardiomyopathy have been reported. The hypertrophy is generally asymmetrical and is most frequently seen in the anteroseptal region. The left ventricular compliance is decreased and a filling defect develops. As diastolic functions are disturbed, atrial distention, pulmonary hypertension, and cardiac failure may develop, and nearly one-quarter of patients may develop dynamic sub-aortic stenosis (1, 3).

The rate of sudden cardiac death in this disease is in the range of 1–8%. All patients diagnosed as having hypertrophic cardiomyopathy should be evaluated in terms of sudden cardiac death and treatment should be identified accordingly. Surgical treatment is recommended for patients who are symptomatic and have a significantly narrowed left ventricular outflow, and treatment with an implantable cardiac defibrillator (ICD) (4) is recommended for patients at risk for sudden cardiac death risk. This article presents a patient with severe HCMP with an unidentified mutation in the *MYBPC3* gene, a family history of sudden death, and significant stenosis in his left ventricular outflow tract (LVOT). The patient was identified as having QRS widening and T-wave alternance during 24-hour Holter monitoring and underwent septal myectomy and epicardial ICD implantation.

Case

A 1.5-year-old male patient was diagnosed as having HCMP at the pediatric cardiology center upon presentation due to murmur at the age of two months, and he was started on propranolol treatment. His metabolic study results were considered normal. The patient's parents were not related and it was identified in his anamnesis that he experienced episodes of convulsions. It was learned that the patient's aunt died suddenly without reason at the age of 27 years, and his grandmother's uncle died in the same way at the age of 30 years.

His physical examination showed that his overall condition was good with a heart rate of 109 beats/min, blood pressure 100/65 mm Hg, respiratory count 28/min, oxygen saturation 98%, and body temperature 36.6°C. The

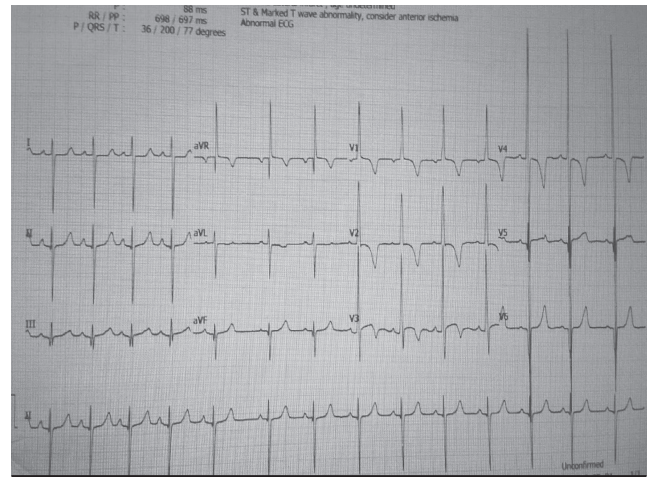


Figure 1. Electrocardiographic examination shows left ventricular hypertrophy and T wave inversion

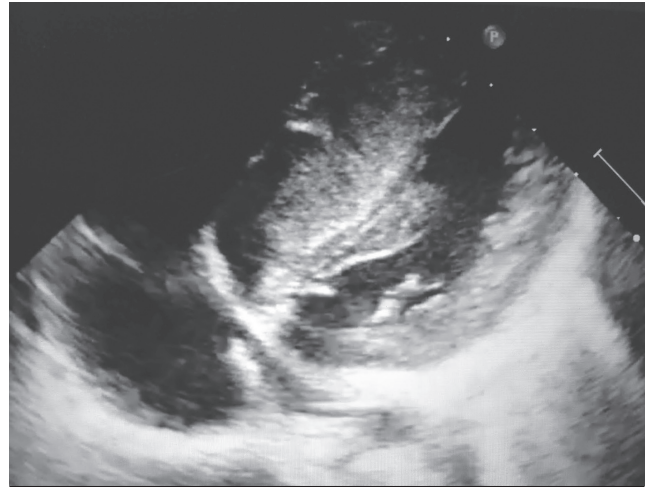


Figure 2. Echocardiographic examination shows that the left ventricle cavity is smaller than normal and there is a significant hypertrophy in the septum

patient had systolic ejection murmur at a severity of 3/6 that was best auscultated in the second right intercostal space. The examination results of his other systems were normal. An electrocardiographic examination (ECG) showed a normal sinus rhythm of 86 beats/min, generalized QRS widening, and left ventricular hypertrophy (Fig. 1). The cardiothoracic ratio was 0.6 according to a telecardiographic evaluation and the patient's hematologic and biochemical results were within normal limits.

According to an echocardiographic examination (ECHO), the left ventricle cavity was smaller than normal and the septum was significantly hypertrophic (Fig. 2). The left ventricular end-diastolic dimension z score was -3, end-systolic thickness of the interventricular septum was 25.8 mm, and the z score was +7.9. On ECHO, significant left ventricular outflow tract (LVOT) obstruction (systolic gradient

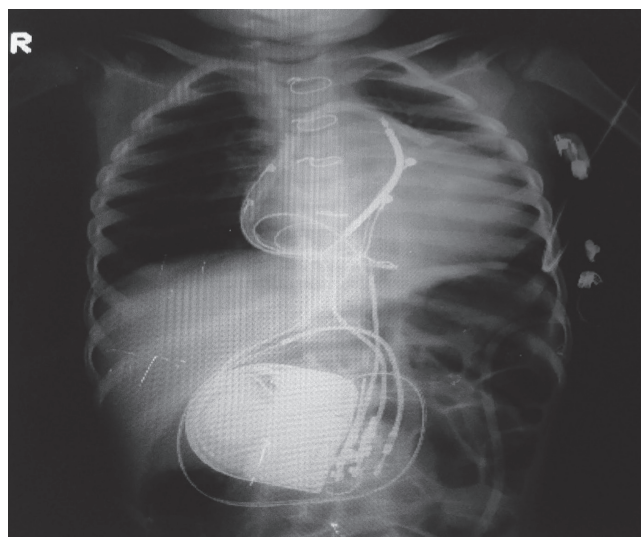


Figure 3. Telecardiography shows epicardial ICD implantation

of maximum 87 mm Hg at rest and 32 mm Hg on average in the mid-cavitary region was observed) and a systolic anterior movement (SAM) of the posterior leaflet of the mitral valve was observed. Furthermore, the patient had mild subvalvular pulmonary valve stenosis and mild mitral valve failure; his left ventricular systolic functions were normal (shortening fraction of 40%). The patient was evaluated with 24-hour Holter monitoring and he was identified as having widened QRS complexes, increased voltage, and T-wave alternance. In the same session, the patient received sternotomy and septal myectomy (1 cm thickness and 8 cm length) under cardiopulmonary bypass, thinning of the anterior papillary muscle, which was identified to have become thicker and adhered to the septum at the apical part, and epicardial ICD implantation because he was in the high-risk group for sudden cardiac death (Fig. 3).

During the patient's genetic examination, a next-generation sequence device (Illumina Miseq) was used to identify that he had a p.P102Lfs*12 (c.305delCinsTGAGG) mutation of the *MYBPC3* gene. It was understood that this change had not previously been identified; however, the mutation had transformed into the amino acid (aa) leucine in place of prolin aa, which had to be present in the normal sequence at position 102 aa, and that it had formed a stop codon after 12 aa in light of the *in silico* and literature-based assessments performed. This change was considered to be the most probable reason for the disease because the gene had ended its expression prematurely. In a screening performed on the first-degree relatives of the patient, it was identified that the mother, father, and sibling had normal electrocardiographic examination results. The patient's treatment was continued with propranolol at a dosage of 3.5 mg/kg/day, and he was discharged under outpatient clinic follow-up.

The patient has been under follow-up for two years and no arrhythmia or shocks have been observed in his ICD records. Also, no recurrence in the left ventricular outflow tract has been seen in his ECG follow-up. Written informed consent was obtained from the patient's parents.

Discussion

Hypertrophic cardiomyopathy is characterized by myocardial hypertrophy resulting in the narrowing of the LVOT, decreased left ventricular cavity, reduced compliance, and diastolic dysfunction. Approximately one-quarter of patients have significant and hemodynamically significant narrowing of the LVOT (5). Beta blockers and calcium channel blockers used in medical treatment may reduce the narrowing of the LVOT and diastolic dysfunction, thereby ensuring improvement of symptoms. Patients who do not benefit from maximum treatment, are symptomatic and have significant narrowing LVOT, undergo myectomy and myotomy surgeries called the Morrow procedure as a surgical method of treatment. A U-shaped muscle mass is excised and removed from the anterior septum. It is known that the LVOT diameter is increased and narrowing is decreased with the resection of the sub-aortic portion of septum. If surgery is successful, the residual gradient is very low or absent; SAM is not observed in the posterior leaflet of the mitral valve (6).

Regarding postoperative complications, iatrogenic ventricular septal defects, aortic or mitral valve failure, left ventricular dysfunction or aneurysm, left bundle branch block or complete AV block requiring the implantation of a permanent pacemaker may develop and LVOT obstruction may re-occur. There are approximately 20-year follow-up data for the procedure and the long-term results are promising (6). No complications developed in the two-year follow-up period of our patient after surgery. The mitral gradient of a maximum 87 mm Hg, which was present in the left ventricular outflow tract, was measured at 20 mm Hg and no SAM signs were identified in the mitral valve. The interventricular septum thickness in systole was 23 mm.

After the diagnosis of HCMP is made, it is necessary to evaluate patients in terms of sudden cardiac death. Previous syncope, history of cardiac arrest, serious hypertrophy with a ventricular wall thickness above 30 mm, family history of sudden cardiac death due to HCMP or an unknown reason, ventricular tachycardia attacks, and abnormal blood pressure response to exercise were considered to be major risk factors for sudden cardiac death. Potential risk factors include atrial fibrillation, myocardial ischemia, LVOT obstruction, high-risk genetic mutations, and competitive sports (5). Beta blockers and calcium channel

blockers are used to reduce the narrowing of the left ventricular outflow tract and to slow down the development of hypertrophy; however, they have a limited effect on long-term prognosis or sudden death risk. The presence of even one major risk factor in patients would create an indication for ICD implementation due to the risk of sudden cardiac death. ICD implantation in these patients is an effective and safe treatment option (4, 7, 8). ICD implantation during Morrow procedure was performed in our patient because the presence of sudden death in the family history, significant septal hypertrophy, significant narrowing of the LVOT, wide QRS complexes, and T-wave alternance indicated that he was in the risk group for sudden cardiac death. No shock therapies following ICD implantation were encountered during follow-up.

There are 25 genes associated with HCMP. The *MYH7* and *MYBPC3* genes account for approximately 80% of the patient population. Van Driest et al. (9) conducted a study in 2004 in which they identified mutations of the *MYBPC3* gene in 71 (18%) of 389 patients with HCMP. It was specified that there were no significant differences between the mutations in other genes associated with degree of hypertrophy, age at diagnosis, family history, sudden death, and *MYBPC3* gene mutations (9). However, Calore et al. (10) conducted a different study in Italy where they examined 97 patients with HCMP and identified the same mutation (p.F305Pfs*27) containing a two-base pair deletion in 19 patients. When this mutation was compared with mutations in other genes and other mutations in the *MYBPC3* gene, it was concluded that the rate of non-continuous tachycardia and ICD implantation rate was much higher. Furthermore, it was also stated that the risk of sudden cardiac death was 2% higher than in the previously described *MYBPC3* mutations and mutations in other genes (10). In light of this information, it was considered that the disease of our patient could have severe progress because the mutation (p.P102Lfs*12) had resulted in the development of a stop codon and the expression part of the gene had become much shorter.

In conclusion, successful results can be obtained with the Morrow procedure if there is a significant narrowing of the LVOT in patients with HCMP. It is necessary to evaluate patients in terms of sudden cardiac death at every follow-up visit. ICD implantation is an effective method if the patient is at risk for sudden cardiac death.

Informed Consent: Written informed consent was given by the patient's parents.

Peer-review: Externally peer-reviewed.

Author Contributions: Concept - O.G., Y.E.; Design - O.G., Y.E.; Supervision - A.G, S.H.; Funding - K.K., S.H., A.G.; Materials - O.G., K.K.; Data Collection and/or Processing - O.G., Y.E.; Analysis and/or Interpretation - A.G., Y.E.; Literature Review - O.G., Y.E.; Writing - O.G., K.K., Y.E.; Critical Review - A.G., S.H., Y.E.

Conflict of Interest: No conflict of interest was declared by the authors.

Financial Disclosure: The authors declared that this study has received no financial support.

Hasta Onamı: Yazılı hasta onamı hastanın ebeveynleri tarafından verildi.

Hakem Değerlendirmesi: Dış bağımsız.

Yazar Katkıları: Fikir - O.G., Y.E.; Tasarım - O.G., Y.E.; Denetleme - A.G, S.H.; Kaynaklar - K.K., S.H., A.G.; Malzemeler - O.G., K.K.; Veri Toplanması ve/veya İşlenmesi - O.G., Y.E.; Analiz ve/veya Yorum - A.G., Y.E.; Literatür Taraması - O.G., Y.E.; Yazıyı Yazan - O.G., K.K., Y.E.; Eleştirel İnceleme - A.G., S.H., Y.E.

Çıkar Çatışması: Yazarlar çıkar çatışması bildirmemişlerdir.

Mali Destek: Yazarlar bu çalışma için mali destek almadıklarını beyan etmişlerdir.

References

1. Maron BJ, McKenna WJ, Danielson GK, et al. American College of Cardiology/European Society of Cardiology clinical expert consensus document on hypertrophic cardiomyopathy. A report of the American College of Cardiology Foundation Task Force on Clinical Expert Consensus Documents and the European Society of Cardiology Committee for Practice Guidelines. *J Am Coll Cardiol* 2003; 42: 1687–713.
2. Feingold B, Webber SA. Cardiomyopathies and acute myocarditis. In: Da Cruz EM, Ivy D, Jaggars J, editors. *Pediatric and congenital cardiology, cardiac surgery and intensive care*. London: Springer-Verlag; 2014.p.2063–78.
3. El-Saiedi SA, Seliem ZS, Esmail RI. Hypertrophic cardiomyopathy: prognostic factors and survival analysis in 128 Egyptian patients. *Cardiol Young* 2014; 24: 702–8.
4. Maron BJ, Spirito P, Ackerman MJ, et al. Prevention of sudden cardiac death with implantable cardioverter-defibrillators in children and adolescents with hypertrophic cardiomyopathy. *J Am Coll Cardiol* 2013; 61: 1527–153.
5. Mataraci I, Polat A, Songur CM, et al. The results of the surgical treatment of hypertrophic cardiomyopathy. *Turkish J Thorac Cardiovasc Surg* 2009; 17: 243–8.
6. Biçer M. Surgical treatment in hypertrophic cardiomyopathy. *Türkiye Klinikleri J Cardiol-Special Topics* 2011; 4: 103–6.
7. Berul CI, Van Hare GF, Kertesz NJ, et al. Results of a mul-

- ticenter retrospective implantable cardioverter-defibrillator registry of pediatric and congenital heart disease patients. *J Am Coll Cardiol* 2008; 51: 1685–91.
8. Elliott PM, Poloniecki J, Dickie S, et al. Sudden death in hypertrophic cardiomyopathy: identification of high risk patients. *J Am Coll Cardiol* 2000; 36: 2212–8.
 9. Van Driest SL, Vasile VC, Ommen SR, et al. Myosin binding protein C mutations and compound heterozygosity in hypertrophic cardiomyopathy. *J Am Coll Cardiol* 2004; 44: 1903–10.
 10. Calore C, De Bortoli M, Romualdi C, et al. A founder *MYBPC3* mutation results in HCM with a high risk of sudden death after the fourth decade of life. *J Med Genet* 2015; 52: 338–47.