

Received: 2015.10.12
Accepted: 2015.12.14
Published: 2016.01.10

Musculoskeletal Ultrasound: A Novel Approach for Luschka's Joint and Vertebral Artery

Authors' Contribution:
Study Design A
Data Collection B
Statistical Analysis C
Data Interpretation D
Manuscript Preparation E
Literature Search F
Funds Collection G

BE 1 **Ying Yin**
CD 1 **Xiaoxia Qin**
CE 1 **Rongzhong Huang**
EF 1,2 **Jing Xu**
CF 1,3 **Yamei Li**
AG 1 **Lehua Yu**

1 Department of Rehabilitation Medicine, The Second Affiliated Hospital of Chongqing Medical University, Chongqing, P.R. China
2 Department of Rehabilitation Medicine, Hubei Combinational Hospital of Chinese and Western Medicine, Wuhan, Hubei, P.R. China
3 Sichuan Academy of Medical Sciences, Sichuan Provincial People's Hospital, Sichuan, P.R. China

Corresponding Author: Lehua Yu, e-mail: yulehuadoc@aliyun.com

Source of support: This study was supported by the National Natural Science Foundation of China (Grant No. 81171859) and Chongqing Municipal Health Bureau (2010-1-20)

Background: Cervical vertigo has been a controversial diagnosis for several years, and the lack of a diagnostic test is a critical problem. Musculoskeletal ultrasound (MSUS) is a real-time dynamic approach that is used to investigate the musculoskeletal and vascular systems.


Material/Methods: In this study, MSUS was used to examine whether there is a relationship among vertigo, the vertebral artery (VA), and Luschka's joint proliferation in patients with cervical vertigo.

Results: MSUS clearly revealed the size, shape, and characteristics of the Luschka's joint, the VA, and the surrounding structures. The Luschka's joint proliferation was not distributed uniformly, but the predilection sites were C4/5 (50.5%) and C5/6 (32.3%). The proliferation from C4/5 and C5/6 Luschka's joints was the major cause of the grade 2/3 VA tortuosity. Moreover, there was a significant correlation between VA compression from Luschka's joint proliferation and the symptoms of cervical vertigo.

Conclusions: MSUS is a real-time and noninvasive technique that can be used to locate and observe Luschka's joint and the VA during research and clinical applications. In future practice MSUS could be used as a diagnostic approach for patients with suspected cervical vertigo.

MeSH Keywords: **Musculoskeletal Abnormalities • Sound • Vertebral Artery**

Full-text PDF: <http://www.medscimonit.com/abstract/index/idArt/896242>

 2793

 8

 2

 26



Background

Vertigo and dizziness are common symptoms reported by patients, and 80% of these cases require medical intervention. Among the various causes of vertigo, the most controversial is so-called cervical vertigo, which is vertigo that is caused by neck disorders [1]. Although the term "cervical vertigo" seems out of fashion, the lack of a diagnostic test remains a critical problem that must be solved [2]. However, there is no criterion standard diagnostic method to establish whether a patient's vertigo is caused by an underlying neck condition [1].

The presence of a joint with synovial lining between the opposing superior and inferior margins of the adjoining cervical vertebrae was first described by Dr. Luschka, and was later named Luschka's joint [3]. Luschka's joint is also known as an uncovertebral joint or a neurocentral joint because it develops from the uncinat process. Luschka's joint consists of a uncinat process situated on the upper surface from the lateral edge to the posterior side of the cervical vertebral body from C3 to C7 and its corresponding recess located on the inferolateral surface of the upper vertebral body [4]. In addition, uncinat processes are variably absent on C7 and have been described to extend to T1 and T2 on occasion [5]. The uncinat process might become larger and flatter as individuals age, losing its sharp and bony characteristics [6]. Cervical spine decompression has been performed for the proliferation of Luschka's joint during anterior or posterior cervical spine surgery, which successfully relieves the symptoms (such as vertigo) of patients with vertebrobasilar insufficiency [7,8]. The compression or stimulation of the second segment of the VA (V2) by the degeneration or instability of cervical vertebrae might contribute to the insufficiency. V2 is transmitted by the grossly oval transverse foramina of the C6–C2 levels, and resides near the medial margin of the foramina [9,10] and so is very close to the Luschka's joint. Therefore, this suggests that the proliferation of the uncinat process causes compression of the VA to contribute to cervical vertigo.

Musculoskeletal ultrasound (MSUS) is a real-time dynamic approach for investigating the musculoskeletal and vascular systems. A previous Doppler ultrasound study revealed that cervical spondylosis patients with vertigo had significantly lower blood flow parameters with contralateral head rotation in the left and right VA compared to patients without vertigo [11]. However, that study focused on head rotation and did not observe Luschka's joint proliferation and VA simultaneously. In this study we focused on the use of MSUS to demonstrate the relationship between Luschka's joint proliferation and vertigo in patients with suspected cervical vertigo related to VA compression for the first time.

Material and Methods

Patient selection

We used MSUS to examine consecutive patients from the PM&R, Neurology, Geriatrics Department and the Physical Examination Center of the Second Affiliated Hospital of Chongqing Medical University between March 2011 and March 2013. A total of 160 patients who met the inclusion criteria were enrolled in this study. All subjects signed written informed consent before entering the study, and the Chongqing Medical University Ethics Committee approved the study protocol. All patients underwent an MSUS examination and were divided into 2 groups based on the MSUS images. Group A contained 76 patients with Luschka's joint proliferations, of whom 45 patients suffered from cervical vertigo (Group A1: 18 males and 27 females aged 32–87 years; mean age 60.56 ± 13.49 years) and 31 did not (Group A2: 13 males and 18 females aged 32–91 years; mean age 58.23 ± 14.09 years). Group B contained 84 patients without Luschka's joint proliferations. Of the 84 patients without proliferations, 15 patients suffered from cervical vertigo (Group B1: 7 males and 8 females aged 36–78 years; mean age 55.40 ± 13.26 years) and 69 did not (Group B2: 28 males and 41 females aged 32–87 years, mean age 59.33 ± 11.25 years). There were no significant differences between Group A and B in terms of age or sex ($P=0.55$).

The inclusion criteria were: patients whose chief complaint was vertigo, who were willing to provide written informed consent, and vertigo that was dependent upon correlating symptoms of imbalance and dizziness with neck pain. Exclusion criteria were other vestibular disorders based on history, examination, and vestibular function tests [12]. The exclusion criteria were: 1) patients with cervical spondylosis myelopathy (CSM); 2) patients with stenosis or insufficiency of the first, third, or fourth segment of the VA (V1, V3, V4); and 3) patients with any critical condition.

MSUS examination

A Philips iU22 xMATRIX (Koninklijke Philips NV, USA) with a high-frequency linear array transducer ranging from 5 to 12 MHz was used in the current study. A qualified ultrasonographer who was blinded to the patient details and was specialized in musculoskeletal ultrasound (US) imaging and examining both sides of the extra-cranial vasculature performed all scans.

We previously reported a method for observing Luschka's joint in patients using MSUS [13]. Briefly, patients were placed in the supine position with the neck elevated by 15 cm using a pillow and rotated by 45 degrees to the contralateral side. The ultrasonic probe was placed at the medial border of the sternocleidomastoid muscle. When the longitudinal section of the

Table 1. The proliferation of left and right Luschka's joint.

Vertebrae	Luschka's joint proliferation		Total
	+	-	
Left	44	596	640
Right	55	585	640
Total	99	1181	1280

Table 2. The proportion of Luschka's joint proliferation from C2/3 to C5/6.

Vertebrae	Luschka's joint proliferation		Total
	+	-	
C2/3	2	318	320
C3/4	19	301	320
C4/5	46	274	320
C5/6	32	288	320
Total	99	1181	1280

common carotid artery was shown, the probe was moved slowly laterally until the VA first appeared, and was then moved up along the VA. Once the VA entered the transverse foramen, the probe was moved slightly to allow the Luschka's joint behind the VA to be observed between 2 transverse processes. Thus, the Luschka's joint lay between 2 transverse processes: the lateral margins of 2 vertebral bodies and outside the intervertebral disc. The echo of the lateral border of the uncinat process was on a straight line with the echo of the lateral margin of the vertebral body, with the VA in front of the line. The image of an uncinat process with a lateral osteophyte crossed the line and reached closer to the VA. The distance between the tip and bottom of the uncinat process was denoted by T (mm) to quantify the degree of osteophyte. Luschka's joints were measured 3 times each on the left and right side and we took the average of the 3 readings.

Next, the Luschka's joint and its relationship with the adjacent tissues, particularly the VA, were observed to assess whether there was a spur from the lateral part of the uncinat process and also to measure the osteophyte.

Peak systolic velocity (PSV, cm/s), end-diastolic velocity (EDV, cm/s), and resistance index (RI) were measured at the level of the C2-3 intertransverse process when the VA was a normal shape, and was measured at the proximal and distal part of the tortuosity in other cases. The VA tortuosity was evaluated according to the following scale [14]: Grade 1, the VA is straight; Grade 2, the VA is tortuous, but without stenosis; Grade 3, the VA is tortuous and stenosis is present.

Evaluation and statistical analysis

The data are presented as arithmetic means \pm standard deviations (SDs), and were analyzed using SPSS Statistics 17.0 (IBM, NY, USA). The difference between sides and spinal levels were analyzed using chi square tests. Chi square tests were also used to evaluate the correlation between 2 variables and to calculate odds ratios (ORs). Potential confounders, including age (related degenerative changes), sex, smoking, and handedness, were used to adjust the P value using multivariate logistic regression analysis. Descriptive statistics were calculated for measurement data, including mean values, and the standard, minimum, and maximum values. Significance levels were set at $P < 0.05$ for all statistical analyses.

Results

Assessing Luschka's joint proliferations in patients by using MSUS

Luschka's joint proliferation was identified using MSUS in 76 patients in Group A. First, Luschka's joint proliferations on the right side (55) and the left side (44) of the cervical vertebrae were compared (Table 1), and there were no significant differences between the 2 sides. Second, the presence of Luschka's joint proliferation at different sections of the cervical spine was assessed (Table 2). There was no significant difference among the C2/3 and C5/6 vertebrae. Next, the proliferation between any 2 cervical vertebrae was compared. Although there was no significant difference between C3/4

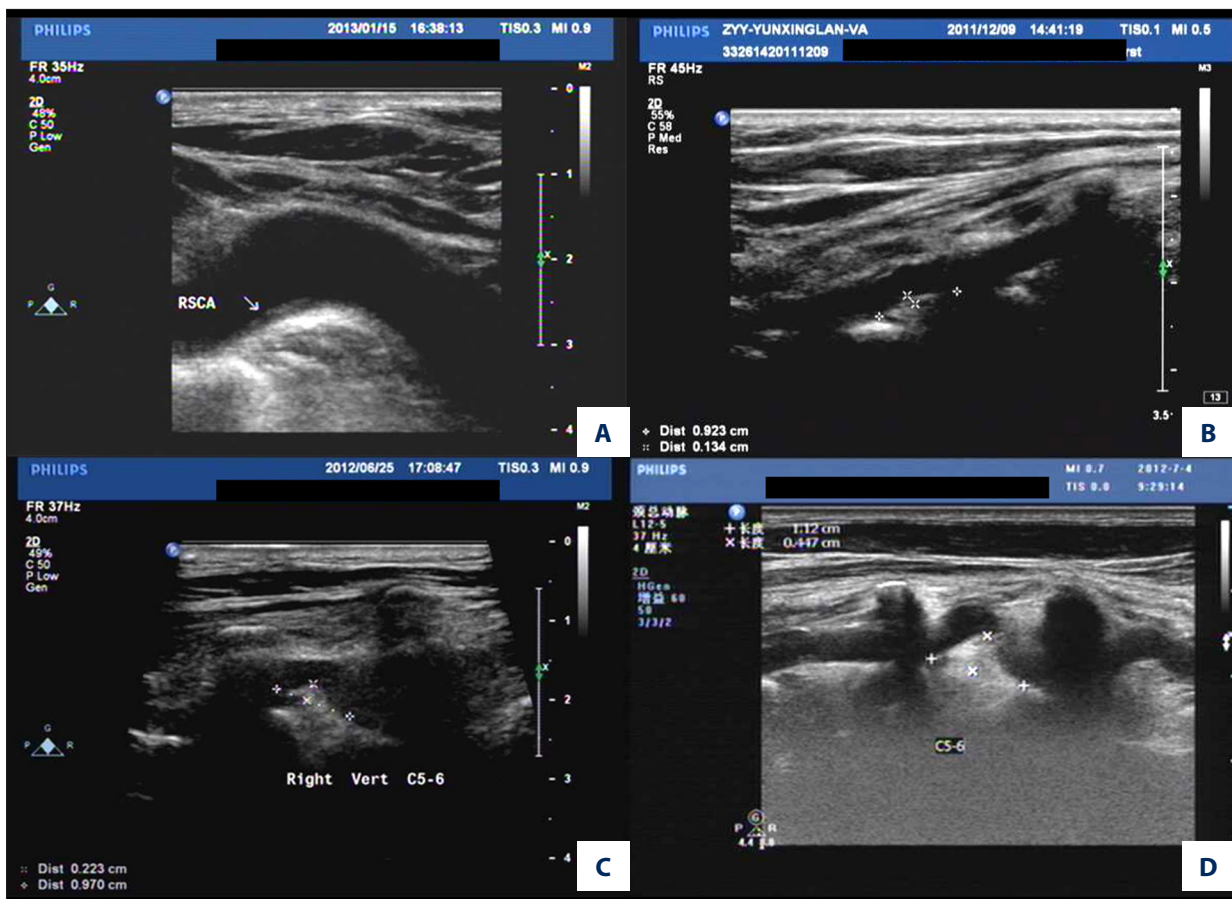


Figure 1. Luschka's joint and its proliferation on MSUS imaging. (A) Luschka's joint (arrow) without proliferation; (B) Luschka's joint with proliferation (T=1.34) and Grade 1 VA tortuosity; (C) Luschka's joint with proliferation (T=2.23) and Grade 2 VA tortuosity; (D) Luschka's joint with proliferation (T=4.47) and Grade 3 VA tortuosity. VA – vertebral artery; T (mm) – the distance between the tip and bottom of the uncinate process.

Table 3. The proportion 99 Luschka's joints with different lateral proliferation sizes.

Luschka's joint proliferation (T)				
T <2 mm	T 2–3 mm	T <3–4 mm	T 4–5 mm	Total
37	43	13	6	99

and C5/6, significant differences were observed between other pairs ($P < 0.05$; Figure 1); the T values were calculated and are shown in Table 3.

Detecting the dynamic impact of Luschka's joints on the VA in real time

A total of 69 Luschka's joints exhibited slight proliferation (T < 3 mm), which cause Grade 1 VA tortuosity (Figure 1B), whereas more proliferation (T > 3 mm) at the Luschka's joints potentially caused Grade 2/3 VA tortuosity (Table 4; Figure 1C, 1D). Interestingly, proliferation at C4/5 and C5/6 Luschka's joints caused most of the Grade 2/3 VA tortuosity (83%, 25/30) (Table 5).

The hemodynamics of different parts of tortuous VA

The PSV, EDV, and RI were increased significantly at the site of VA tortuosity compared with sites proximal to VA tortuosity ($P < 0.001$; Figure 2A, 2B). In contrast, there was no statistically significant difference between the pre- and post-VA tortuosity regions ($P > 0.05$; Table 6).

The relationship between Luschka's joint proliferation and vertigo

The incidence of cervical vertigo in Group A was 59.21%, which was significantly higher than in Group B (17.86%; $P < 0.01$;

Table 4. The effect of Luschka's joint proliferation on VA tortuosity.

VA tortuosity	Luschka's joint proliferation (T)				Total
	T <2 mm	T 2-3 mm	T <3-4 mm	T 4-5 mm	
Grade 1	36	33	0	0	69
Grade 2	1	10	13	5	29
Grade 3	0	0	0	1	1
	37	43	13	6	99

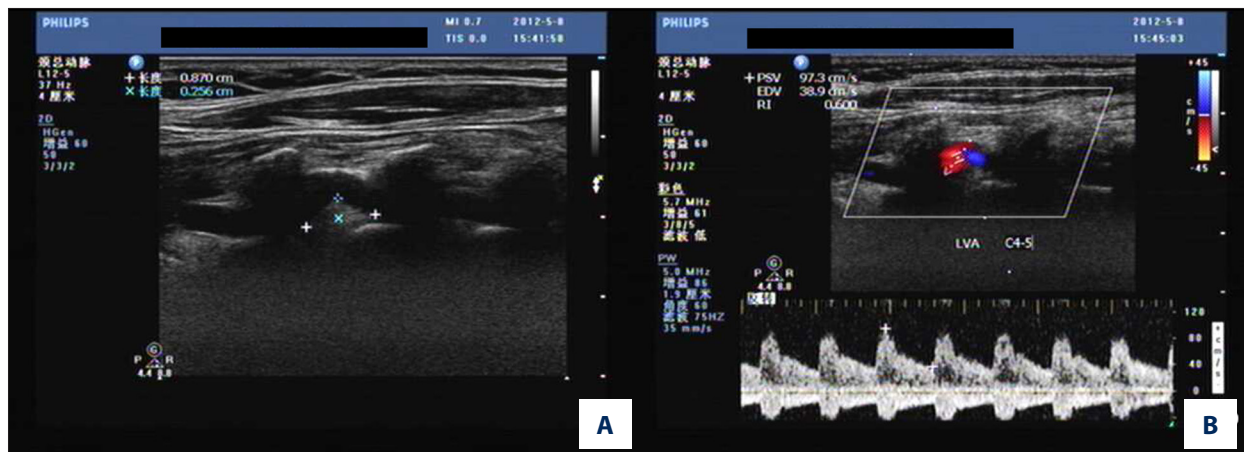


Figure 2. Hemodynamics of tortuous VA. (A) Two-dimensional image showing a Luschka's joint lateral osteophyte and tortuous VA. (B) Spectral Doppler image showing PSV, EDV, and RI at the same tortuous region. PSV – peak systolic velocity (cm/s); EDV – end-diastolic velocity (cm/s); RI – resistance index; VA – vertebral artery.

Table 5. The effect of different levels of Luschka's joint proliferation on VA tortuosity.

VA tortuosity	Level of Luschka's joint proliferation				Total
	C2/3	C3/4	C4/5	C5/6	
Grade 1	2	14	31	22	69
Grade 2	0	5	15	9	29
Grade 3	0	0	0	1	1
	2	19	46	32	99

Table 7). There was a statistically significant association between the compression of the VA caused by Luschka's joint proliferation and the symptoms of cervical vertigo (Table 8). Specifically, after removing potential confounding factors, patients with VA compression caused by Luschka's joint proliferation had a 2.94-fold higher risk of experiencing cervical vertigo (OR=2.94; $\chi^2=6.562$; 95% CI=1.29-6.72; $P=0.01$; $\alpha=0.05$).

Discussion

Luschka's joint contributes to the mobility and stability of spinal motion segments, and also functions to protect the

intervertebral foramen contents. Luschka's joints are common sites of osteoarthritic changes, which manifest as pitting and eburnation of the articular surfaces and distortion of the uncinat process as it develops osteophytic spurring. We previously studied the reliability and validity of MSUS for observing Luschka's joint [15]. In this study, patients with cervicogenic vertigo were examined using both MSUS and 3-dimensional computer tomography angiography (3D-CTA) to assess whether there was a lateral proliferation in the Luschka's joint. Taking 3D-CTA as the criterion standard, we found that there was no significant difference between MSUS and 3D-CTA for assessing proliferation, and a good correlation and consistency were found between the 2 methods. The sensitivity,

Table 6. PSV, EDV, and RI in different parts of the VA.

Paired data	Mean	SD	P	95% CI	
				Lower	Upper
PSV Δ(Pre – Tor)	-35.759	12.426	0.000*	-40.485	-31.032
PSV Δ(Pre – Post)	1.862	5.310	0.069	-0.158	3.882
EDV Δ(Pre – Tor)	-8.793	5.473	0.000*	-10.875	-6.711
EDV Δ(Pre – Post)	-0.103	3.405	0.871	-1.399	1.192
RI Δ(Pre – Tor)	-0.04276	0.04854	0.000*	-0.06122	-0.02429
RI Δ(Pre – Post)	0.00276	0.02103	0.486	-0.00524	0.01076

PSV – peak systolic velocity (cm/s); EDV – end diastolic velocity (cm/s); RI – resistance index; VA – vertebral artery; Pre – pre-tortuosity; Post – post-tortuosity; Tor – VA tortuosity. * P<0.001.

Table 7. The relationship between Luschka's joint proliferation and cervical vertigo.

Luschka's joint proliferation	Cervical vertigo		Total	%
	+a	-b		
+	45	31	Group A (n=76)	59.21
-	15	69	Group B (n=84)	17.86
	Group A1+B1 (n=60)	Group A2+B2 (n=100)	160	37.50

a, "+" means T ≥ 3 mm; b, "-" means T < 3 mm or no proliferation on Luschka's joint.

Table 8. The proportion of patients with or without cervical vertigo according to VA tortuosity.

Cervical vertigo	VA tortuosity (Grade 2/3)		Total
	+a	-b	
+	16	44	60
-	11	89	100
	27	133	160

a, "+" means the VA tortuosity caused by Luschka's joint proliferation was Grade 2 or 3; b, "-" means the VA tortuosity was Grade 1 (no proliferation on Luschka's joint or proliferation with VA Grade 1). VA – vertebral artery.

specificity, positive predictive value, negative predictive value, and accuracy rate of MSUS were 84.44%, 96.80%, 3.20%, 13.56%, 92.73%, 93.80%, and 93.48%, respectively. As a rapid, inexpensive, noninvasive, nonradiative, repeatable, and real-time examination, MSUS is a superior diagnostic tool for assessing Luschka's joints proliferation, which might contribute to cervical vertigo.

Previous studies demonstrated that the Luschka's joint preferentially exhibited proliferation in the lower cervical spine secondary to the relatively higher loads and stress experienced at these levels [16,17]. Ebraheim et al. also reported that the uncinat processes were significantly higher at the C4 to C6

level compared with the C3 or C7 levels [18]. An anatomical study also revealed that the taller uncinat processes tended to be located below the C3 vertebral level, with an 8-mm mean anteroposterior length¹⁹. The findings of current study are consistent with these previous observations; since 76 patients with Luschka's joint proliferation according to MSUS had a higher mean age older, the Luschka's joint proliferations were not uniformly distributed, and the predilection sites were C4/5 (50.5%) and C5/6 (32.3%). These sites take the major range of motion and stress in the cervical spine.

In the current study the size of Luschka's joint proliferations were observed using MSUS. Slight lateral proliferation (T < 3

mm) accounted for 80% (80/99) of cases, and moderate and severe proliferation ($T > 3$ mm) accounted for the remaining 20%. Since proliferation might impinge on anatomical structures in the vicinity, we investigated the relationship between the size of Luschka's joint proliferation and VA tortuosity using MSUS for the first time. The results demonstrated that moderate and severe proliferation might be related to Grade 2/3 VA tortuosity. A recent study revealed that the vertebral artery was more likely to be compressed by proliferation from the uncinat process than from the zygapophysial joints [20]. However, we found that proliferation from C4/5 and C5/6 Luschka's joints accounted for most of the Grade 2/3 VA tortuosity (83%, 25/30).

Doppler US has become the first choice for evaluating the extracranial part of the vertebral artery because the degree of the stenosis can be identified with high accuracy, particularly when experienced physicians perform the examinations [21]. In the current study we used MSUS Doppler sonography to measure blood flow of the VA and Luschka's joint proliferation in real time. We found that PSV, EDV, and RI were increased significantly at the site of VA tortuosity compared with pre-VA tortuosity sites, consistent with a report by Jargiello et al. [22]; however, there was no statistically significant difference between pre- and post-VA tortuosity regions. A previous study reported that blood flow parameters with the head in a neutral position were similar in cervical spondylosis patients with or without vertigo. However, cervical spondylosis patients with vertigo had statistically significantly lower blood flow parameters in the left and right vertebral arteries with contralateral head rotation compared with cervical spondylosis patients without vertigo and control subjects [11]. Zhang et al. reported that the VA diameter, PSV, and variance index (VI) of the tortuous vertebral artery were increased. Compared with pre-tortuosity, the post-tortuous VI was also increased [23]. The increased VI represented the decrease in mean VA blood flow velocity, which caused hypoperfusion; however, PSV was increased at the site of VA tortuosity. In addition, the authors suggested that vertigo might be caused by hypoperfusion of the VA [23]. In the current study, to ensure patient safety, head rotation was not permitted, and VI was not measured as part of a routine US examination. Nevertheless, we performed a study in rhesus macaques to observe the atlanto-axial artery hemodynamics during cervical spine manipulation using Doppler US, and the results are ready to publish.

VA compression due to Luschka's joint proliferation can lead to clinical symptoms of vertebrobasilar insufficiency [24]. In most cases, VA compression that is significant to cause symptoms occurs dynamically with various head positions [20,25]. Luschka's joint proliferation is the main cause of V2 mechanical compression, which ultimately leads to the onset and increasing severity of VBI; vertigo might occur as part of this pathological process [26]. A case report revealed that a cerebellar

infarction originating from VA stenosis was caused by a right hypertrophied C5–C6 uncovertebral joint [25]. In the current study, patients with VA compression that was caused by Luschka's joint proliferation had a 2.94-fold increased risk of experiencing cervical vertigo. Specifically, 59.21% of patients with Luschka's joint proliferations detected using MSUS complained of cervical vertigo, and this proportion was much higher than in patients who did not have cervical vertigo. Eleven patients (11/27) with obvious VA compression had no symptoms of vertigo, which might be caused by a sufficient collateral compensative capacity.

Limitations

There are a number of limitations to the current study that must be acknowledged. Firstly, the medical history did not include details about working at a desk, the amount of exercise, and smoking, which might be risk factors for Luschka's joint proliferation, and these parameters were not included in the analysis. In addition, the apparatus software measured only PSV, EDV, and RI automatically; however, other hemodynamic parameters, such as mean velocity (VM), VI, and pulsatility index (PI), were not calculated. In addition, to ensure patient safety the subject's head was deliberately not turned to either side, which might have contributed to the negative effect of Luschka's joint proliferation on the VA. Moreover, multivariate logistic regression analysis was not used in this case-control study, which might decrease the strength of the results.

Conclusions

In summary, for the first, we used MSUS to assess the relationship between Luschka's joint and the VA. The contribution of VA compression caused by Luschka's joint proliferation to cervical vertigo in patients was investigated for the first time. Patients with VA compression caused by Luschka's joint proliferation had a higher risk of experiencing cervical vertigo. The current study diagnosed and measured Luschka's joint proliferation, and the data revealed that it might contribute to VA compression and cervical vertigo. MSUS is a real-time and noninvasive technique that can be used to locate and observe Luschka's joint and VA during research and clinical applications. In future practice MSUS could be used as a diagnostic tool in patients with suspected cervical vertigo.

Acknowledgements

The human skeletal specimens and cadavers were provided by the Department of Anatomy, Chongqing Medical University. Philips iU22 was provided by the Ultrasound Department of the Second Affiliated Hospital, Chongqing Medical University. The support of all of these institutions is gratefully acknowledged.

Conflicts of interest

None of the authors have any conflicts of interest to disclose.

References:

1. Yacovino DA, Hain TC: Clinical characteristics of cervicogenic-related dizziness and vertigo. *Semin Neurol*, 2013; 33: 244–55
2. Hain TC: Cervicogenic causes of vertigo. *Curr Opin Neurol*, 2015; 28: 69–73
3. Orofino C, Sherman MS, Schechter D: Luschka's joint – a degenerative phenomenon. *J Bone Joint Surg Am*, 1960; 42-A: 853–58
4. Tubbs RS, Vahedi P, Loukas M, Shoja MM, Cohen-Gadol AA: Hubert von Luschka (1820–1875): His life, discoveries, and contributions to our understanding of the nervous system. *J Neurosurg*, 2011; 114: 268–72
5. Tulsı RS, Perrett LV: The anatomy and radiology of the cervical vertebrae and the tortuous vertebral artery. *Aust Radiol*, 1975; 19: 258–64
6. Ugur HC, Uz A, Attar A et al: Anatomical projection of the cervical uncinate process in ventral, ventrolateral, and posterior decompressive surgery. *J Neurosurg*, 2000; 93: 248–51
7. Ohsaka M, Takgami M, Koyanagi I et al: [Cerebral ischemia originating from rotational vertebral artery occlusion caused by C5/6 spondylotic changes: a case report]. *No Shinkei Geka*, 2009; 37: 797–802 [in Japanese]
8. Miele VJ, France JC, Rosen CL: Subaxial positional vertebral artery occlusion corrected by decompression and fusion. *Spine*, 2008; 33: E366–70
9. Guvencer M, Men S, Naderi S et al: The V2 segment of the vertebral artery in anterior and anterolateral cervical spinal surgery: A cadaver angiographic study. *Clin Neurol Neurosurg*, 2006; 108: 440–45
10. Bruneau M, Cornelius JF, Marneffe V et al: Anatomical variations of the V2 segment of the vertebral artery. *Neurosurgery*, 2006; 59: ONS20–24; discussion ONS-24
11. Machaly SA, Senna MK, Sadek AG: Vertigo is associated with advanced degenerative changes in patients with cervical spondylosis. *Clin Rheumatol*, 2011; 30: 1527–34
12. Wrisley DM, Sparto PJ, Whitney SL, Furman JM: Cervicogenic dizziness: a review of diagnosis and treatment. *J Orthop Sports Phys Ther*, 2000; 30(12): 755–66
13. Li Y, Zheng Y, Yu Q, Yu L: Using ultrasound for assessing cervical Luschka's joint problems. *Chin J Phys Med Rehabil*, 2014; 36: 95–99 [in Chinese]
14. Jian-Ping G, Zhi-An L, Ming-Hui Q et al: The effect of osseous hypertrophy of cervical Luschka's joints on vertebral artery. *Journal of Clinical Radiology*, 1998; 17: 354–56 [in Chinese]
15. Li Y, Yu L, Zheng Y, Yu Q: The validity of musculoskeletal ultrasound for assessing cervical Luschka's joint with lateral osteophyte formation. *Practical Journal of Clinical Medicine*, 2014; 11 [in Chinese]
16. Pesch HJ, Bischoff W, Becker T, Seibold H: On the pathogenesis of spondylosis deformans and arthrosis uncovertebralis: Comparative form-analytical radiological and statistical studies on lumbar and cervical vertebral bodies. *Arch Orthop Trauma Surg*, 1984; 103: 201–11
17. Prescher A: Anatomy and pathology of the aging spine. *Eur J Radiol*, 1998; 27: 181–95
18. Ebraheim NA, Lu J, Biyani A et al: Anatomic considerations for uncovertebral involvement in cervical spondylosis. *Clin Orthop Relat Res*, 1997; (334): 200–6
19. Tubbs RS, Rompala OJ, Verma K et al: Analysis of the uncinate processes of the cervical spine: an anatomical study. *J Neurosurg Spine*, 2012; 16(4): 402–7
20. Klaassen Z, Tubbs RS, Apaydin N et al: Vertebral spinal osteophytes. *Anat Sci Int*, 2011; 86: 1–9
21. Landwehr P, Schulte O, Voshage G: Ultrasound examination of carotid and vertebral arteries. *Eur Radiol*, 2001; 11: 1521–34
22. Jargiello T, Pietura R, Rakowski P et al: Power Doppler imaging in the evaluation of extracranial vertebral artery compression in patients with vertebralbasilar insufficiency. *Eur J Ultrasound*, 1998; 8: 149–56
23. Huabin Z, Jinrui W: Ultrasonographic appearance of the tortuosity of extracranial vertebral artery. *Chinese J Ultrasound Med*, 2003; 19: 300–33 [in Chinese]
24. Brismee JM, Sizer PS Jr, Dedrick GS et al: Immunohistochemical and histological study of human uncovertebral joints: A preliminary investigation. *Spine*, 2009; 34: 1257–63
25. Choi JM, Hong HJ, Chang SK, Oh SH: Cerebellar infarction originating from vertebral artery stenosis caused by a hypertrophied uncovertebral joint. *J Stroke Cerebrovasc Dis*, 2012; 21: 908.e7–9
26. Cagnie B, Barbaix E, Vinck E et al: Extrinsic risk factors for compromised blood flow in the vertebral artery: anatomical observations of the transverse foramina from C3 to C7. *Surg Radiol Anat*, 2005; 27: 312–16