

Concurrent apatinib and local radiation therapy for advanced gastric cancer

A case report and review of the literature

Ming Zhang, MD^{a,*}, Weiye Deng, MD^{b,c}, Xiaoci Cao, MD^a, Xiaoming Shi, MD^d, Huanfen Zhao, MD^e, Zheping Duan, MD^a, Bonan Lv, MD^d, Bin Liu, MD^{a,*}

Abstract

Rationale: Apatinib is a novel anti-angiogenic agent targeting vascular endothelial growth factor receptor-2, which is effective in patients with chemotherapy-refractory gastric cancer. There are no reports of concurrent apatinib with local radiation therapy in elderly patients with advanced gastric cancer.

Patient concerns and Diagnoses: we present the first published report of a 70-year-old male patient with advanced gastric cancer who received concurrent apatinib and local radiation therapy after failure of oxaliplatin and S-1 chemotherapy.

Interventions and Outcomes: The patient received concurrent apatinib and local radiation therapy and was followed up 7 months after therapy without disease progress, 14 months later indicated extensive metastasis and this patient died of pulmonary infection.

Lessons: Elderly patients with advanced gastric cancer may benefit from concurrent apatinib with local radiation therapy when chemotherapy is not tolerated or successful. Further studies are needed to investigate the clinical outcomes and toxicities associated with concurrent apatinib and radiation therapy in gastric cancer.

Abbreviation: BMI = body mass index, ECOG = Eastern Cooperative Oncology Group, FISH = fluorescence in situ hybridization, GST- π = glutathione S-transferase π , HER-2 = human epidermal growth factor receptor 2, IMRT = intensity modulated radiation therapy, OS = overall survival, PET-CT = positron-emission tomography computed tomography, PFS = progression-free survival, RECIST = Response Evaluation Criteria in Solid Tumors, SUV = standardized uptake value, TOPOII α = topoisomerase enzyme II α , VEGF = vascular endothelial growth factor.

Keywords: antiangiogenic therapy, apatinib, gastric cancer, radiation therapy

1. Introduction

The gastric cancer is the fifth leading cause of cancer in the world and China accounts for approximately 40% of global gastric cancer incidence annually.^[1] Patients diagnosed with advanced gastric cancer usually have a poor prognosis, with a median overall survival (OS) of 1 year when treated with chemothera-

py.^[2,3] Gastric cancer frequently occurs in elder individuals, and conventional cancer therapies are difficult to administer due to challenges associated with age, comorbidities, and cancer-related debilitation. In order to avoid the toxicity associated with conventional therapies and improve outcomes in this patient population, many research studies have focused on the application of novel molecular targeted agents.

In the 1970s, angiogenesis was reported to play a key role in tumor growth.^[4] Since this initial research, multiple antiangiogenic agents have been developed and studied in clinical trials. Although these agents show promising antitumor effects, their efficacy when used as monotherapy is limited. Therefore, these agents have been integrated with conventional cancer therapies, including chemotherapy and radiotherapy, in order to enhance antitumor activity.

Apatinib is a novel oral antiangiogenic agent that shows efficacy in the inhibition of tumor angiogenesis.^[5] Phase II and III clinical trials suggest apatinib can improve OS and progression-free survival (PFS) in advanced gastric cancer patients who have experienced treatment failure on 2 or more prior chemotherapy regimens. Apatinib was approved and launched in the People's Republic of China in 2014 as a second-line treatment for gastric cancer patients.

Here, we report the case of a 70-year-old male patient with advanced gastric cancer, who received concurrent apatinib and local radiation therapy.

2. Case report

On December 28, 2014, a 70-year-old man complaining of abdominal pain, dizziness, and nausea was referred to the Hebei

Editor: Simona Gurzu.

MZ and WD contributed equally to this work.

Funding: This work was supported by The fund of HeBei Food and Drug Administration (ZD2015035).

The authors have no conflicts of interest to disclose.

^a Department of Radiation Oncology, Hebei General Hospital, Shijiazhuang, China, ^b Department of Radiation Oncology, The University of Texas MD Anderson Cancer Center, ^c Division of Epidemiology, Human Genetics and Environmental Sciences, The University of Texas School of Public Health at Houston, Houston, TX, ^d Department of Gastrointestinal Surgery, ^e Department of Pathology, Hebei General Hospital, Shijiazhuang, China.

* Correspondence: Ming Zhang and Bin Liu, Department of Radiation Oncology, Hebei General Hospital, Shijiazhuang, China (e-mails: Zhangming096@163.com [MZ]; 13111582843@163.com [BL]); Bin Liu, MD, Department of Radiation Oncology, Hebei General Hospital, Shijiazhuang, 050051, China (e-mail: 13111582843@163.com).

Copyright © 2017 the Author(s). Published by Wolters Kluwer Health, Inc. This is an open access article distributed under the Creative Commons Attribution-No Derivatives License 4.0, which allows for redistribution, commercial and non-commercial, as long as it is passed along unchanged and in whole, with credit to the author.

Medicine (2017) 96:9(e6241)

Received: 11 October 2016 / Received in final form: 5 February 2017 /

Accepted: 6 February 2017

<http://dx.doi.org/10.1097/MD.0000000000006241>

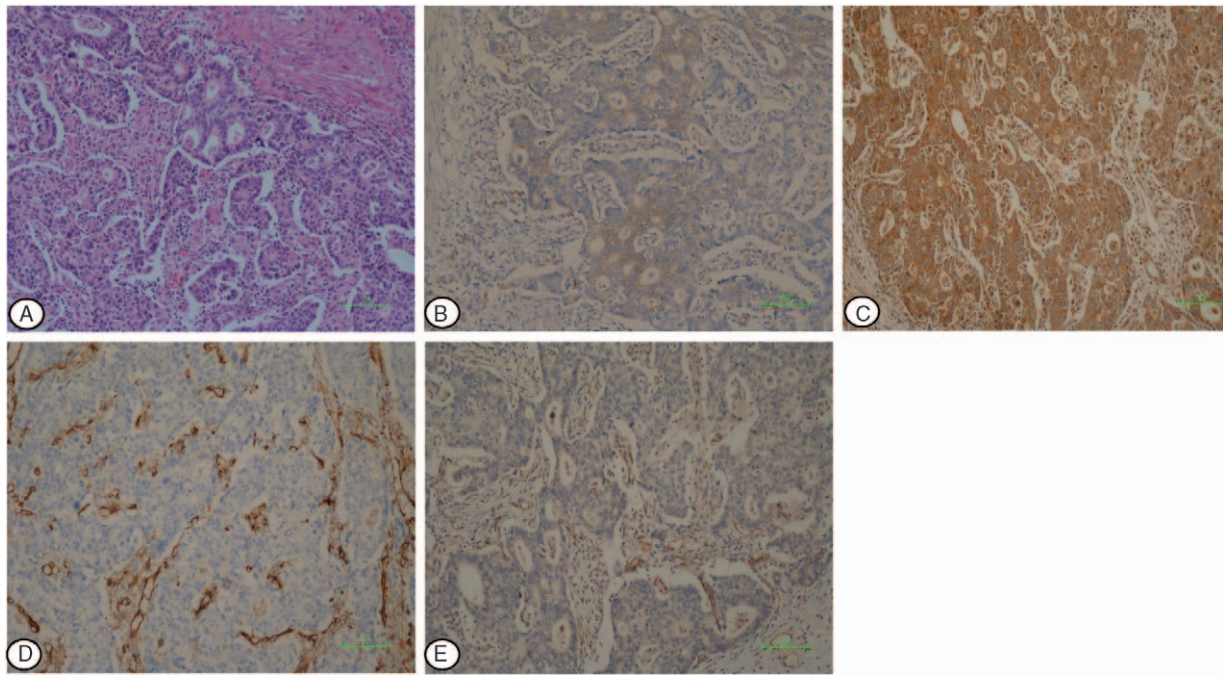


Figure 1. Postoperative pathology: (A) hematoxylin and eosin staining indicating moderately differentiated gastric adenocarcinoma (100 \times). (B) Immunohistochemistry showing the expression of HER2 (+) (100 \times). (C) Immunohistochemistry showing the expression of VEGF (+) (100 \times). (D) Immunohistochemistry showing the expression of CD31 (+) (100 \times). (E) Immunohistochemistry showing the expression of CD105 (+) (100 \times). HER-2 = human epidermal growth factor receptor 2, VEGF = vascular endothelial growth factor.

General Hospital, Hebei, China. Gastroscopy showed irregular hemorrhagic ulcerative lesions extending from the gastric body to the lesser curvature and pyloric stenosis of the stomach. Gastric biopsy revealed adenocarcinoma. On January 7, 2015, palliative gastrectomy plus Roux-en-Y near esophagojejunostomy were performed. Diffuse enlarged para-aortic and anterior superior pancreatic lymph nodes, as well as lymph nodes around the common hepatic artery, could not be resected. Postoperative pathology demonstrated moderately differentiated gastric adenocarcinoma (Fig. 1A). Immunohistochemistry showed the following: human epidermal growth factor receptor 2 (HER-2) (+), vascular endothelial growth factor (VEGF) (+), CD31 (+), CD105 (+) (Fig. 1B–E), triple positive (TP) (+), glutathione S-transferase π (GST- π) (+++), topoisomerase enzyme II α (TOPOII α), P53 (–), and Ki-67 (70%). The diagnosis was stage IV gastric adenocarcinoma with multiple lymph nodes metastases (T4N2M1).

The patient was administered 1 cycle of chemotherapy with oxaliplatin and S-1; however, the treatment was terminated, as the patient could not tolerate the associated gastrointestinal disturbances. On February 2, 2015, adjuvant radiotherapy was administered. Before radiotherapy, positron-emission tomography computed tomography (PET-CT) showed extensive distant metastasis (left supraclavicular and mediastinal lymph nodes, and lymph nodes throughout the abdominal cavity). The patient's Eastern Cooperative Oncology Group (ECOG) performance status was 2, and his body mass index (BMI) was 19; therefore, he was considered to be at risk of malnutrition. Oral apatinib 850 mg once a day combined with and following radiotherapy was prescribed. Informed consent was obtained from the patient prior to treatment. In an attempt to improve tolerance to treatment, palliative intensity modulated radiation therapy (IMRT) was used. The patient received a dose of 64 Gy in 30 fractions to the

mediastinum and doses of 52 Gy in 26 fractions to the other abdominal metastatic lesions (n=5). The left supraclavicular lymph node was treated with apatinib alone (Figs. 2 and 3A–C).

A PET-CT scan performed 2 weeks after radiotherapy showed an 80% reduction in the maximum standardized uptake value (SUV_{max}) of 2-deoxy-2-[¹⁸F]fluoro-D-glucose (FDG). FDG uptake was higher in the left supraclavicular lymph node compared to the metastatic regions treated with concurrent apatinib and radiation therapy. According to Response Evaluation Criteria in Solid Tumors (RECIST), the clinical effect was partial response (Fig. 2). The patient received further radiotherapy (66 Gy in 28 fractions) to the left supraclavicular lymph node due to residual metastasis.

Tumor markers and biochemical analyses were evaluated every 2 months. Two months after therapy, chest, and abdominal CT scans indicated stable disease; anemia and gastrointestinal symptoms had improved, ECOG performance status was 0, and BMI was 22. Hematologic toxicity, hypertension, renal dysfunction, proteinuria, and hand-foot syndrome were not observed during apatinib therapy.

In September 2015, a follow-up examination showed increased carbohydrate antigen (CA) 125 and ferritin; however, gastroscopy and abdominal CT revealed no abnormalities. In November 2015, the patient had difficulty swallowing and experienced intermittent hematochezia. Apatinib was terminated due to gastrointestinal bleeding. Gastroscopy revealed anastomotic stenosis due to gastric cancer and intragastric hemorrhage (Fig. 3D–F). The patient and his family refused chemoradiotherapy. Symptomatic treatment with a hemostatic drug and best supportive care were prescribed. After 1 week of therapy, hemorrhaging was resolved. One month later, the patient again experienced intermittent hematochezia. On December 20, 2015, PET-CT demonstrated extensive metastasis. The patient and his

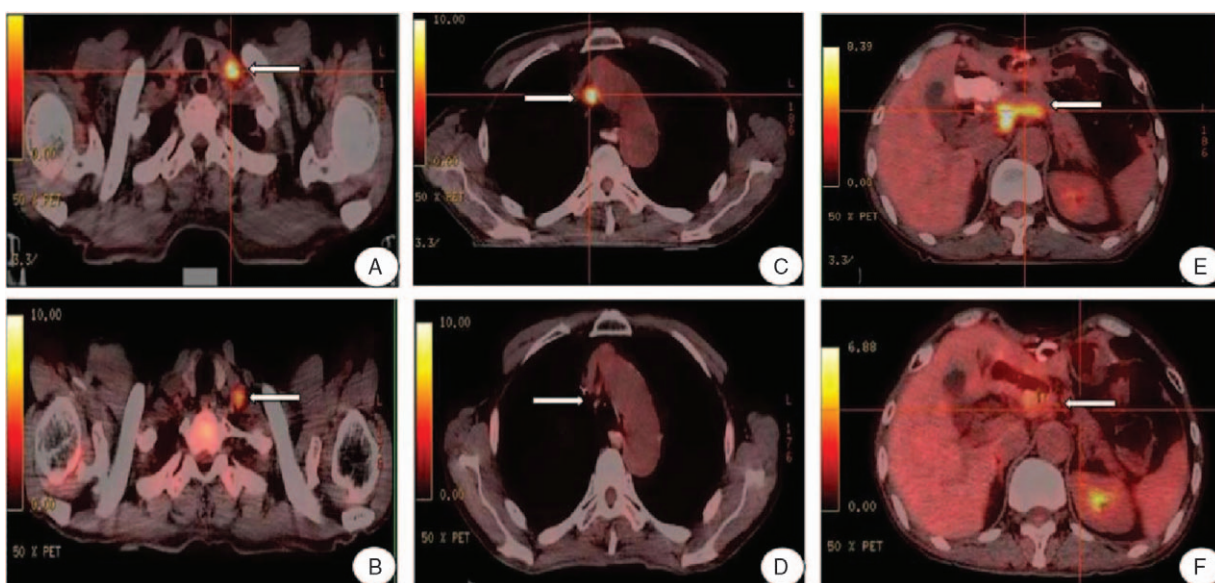


Figure 2. PET-CT scans: (A) left supraclavicular metastasis (arrow) before apatinib treatment; (B) left supraclavicular metastasis (arrow) after apatinib treatment; (C) mediastinum metastasis (arrow) before concurrent apatinib and radiotherapy; (D) mediastinum metastasis (arrow) after concurrent apatinib and radiotherapy; (E) abdominal metastasis (arrow) before concurrent apatinib and radiotherapy; (F) abdominal metastasis (arrow) after concurrent apatinib and radiotherapy. PET-CT = positron-emission tomography computed tomography.

family requested best supportive care. On April 16, 2016, the patient died due to pulmonary infection.

3. Discussion

This study reports the case of a 70-year-old male patient with advanced gastric cancer who received concurrent apatinib and

local radiation therapy after failure of oxaliplatin and S-1 chemotherapy. Chemotherapy, radiation therapy, and chemo-radiotherapy are recommended for metastatic gastric cancer; however, relapses are frequent and prognosis is poor.

Molecular targeted therapies have the potential to improve oncological outcomes. The recently published multinational Phase III randomized TOGA trial of trastuzumab, a monoclonal

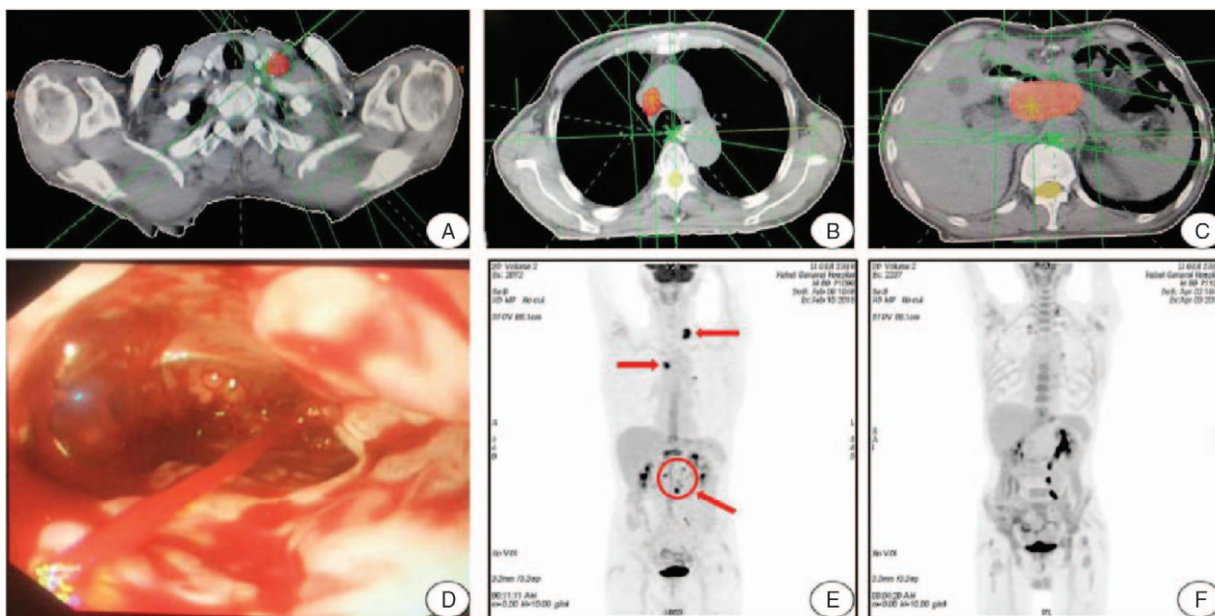


Figure 3. Pre- and postoperative imaging: (A) clinical target volume (red) of the left supraclavicular region; (B) clinical target volume (red) of the mediastinum; (C) clinical target volume (red) of the abdominal cavity (A–C) gross tumor volume and planning target volume contours omitted for clarity); (D) gastric endoscopy showing anastomotic stenosis due to gastric cancer with intragastric hemorrhage; (E) PET-CT showing extensive distant metastasis in supraclavicular lymph nodes (arrow), the mediastinum (arrow), and multiple parts of the abdominal cavity (circle and arrow) before concurrent apatinib and radiotherapy; (F) PET-CT showing a partial response in the supraclavicular lymph nodes, mediastinum, and multiple parts of the abdominal cavity after concurrent apatinib and radiotherapy. PET-CT = positron-emission tomography computed tomography.

antibody that targets HER2,^[6] is the first to show benefit of a targeted agent in gastric cancer. The addition of trastuzumab to a standard cisplatin/fluoropyrimidine chemotherapy doublet resulted in significant improvements in the overall response rate, PFS and OS, compared to chemotherapy alone. However, the survival benefit of trastuzumab is limited to the few patients whose esophagogastric cancers are HER2 (+++) or fluorescence in situ hybridization (FISH) positive. The gastric cancer of the patient in the current study was HER2 (+); therefore, he was not eligible for trastuzumab therapy.

New blood vessel formation or neovascularization is crucial for tumor growth and metastasis. VEGF is the most potent mediator of this process. VEGF binds to high-affinity receptors (VEGFR type 1 and 2) and leads to endothelial cell migration and proliferation.^[7] Antiangiogenesis strategies using monoclonal antibodies and tyrosine kinase inhibitors have improved OS in colon, renal, non-small-cell lung cancer and hepatocellular carcinoma,^[8] and have been extensively assessed in gastric cancer. Interesting, antiangiogenesis strategies seem to be more effective in intestinal-type than diffuse-type gastric cancer.^[9]

Apatinib targets the intracellular ATP-binding site of VEGFR-2.^[10] It was the first agent to show a clear survival benefit compared with placebo in a phase III trial in patients with advanced gastric cancer refractory to 2 or more lines of prior chemotherapy. OS was 6.5 months in the apatinib group and 4.7 months in the placebo group. PFS was 2.6 months in the apatinib group and 1.8 months in the placebo.^[11] To our knowledge, the current study is the first to show that apatinib combined with radiotherapy may achieve a better clinical outcome than apatinib alone in metastatic gastric cancer.

Although several trials have shown that the addition of conventionally fractionated radiation therapy to antiangiogenic agents is well tolerated,^[12,13] some reports suggest increased luminal gastrointestinal toxicity in combination therapy, especially when stereotactic body radiation therapy is combined with antiangiogenic agents.^[14,15] Gastrointestinal organs are regenerative organs. However, acute radiation toxicity may selectively kill stem cells, resulting in an insufficient supply to replace sloughed villi.^[16,17] Chronic radiation toxicity can cause fibrosis and endothelial abnormalities.^[18] Furthermore, radiation therapy is associated with a decrease in vascular density, leading to ischemia, telangiectasia, and a predisposition for bleeding. VEGF plays an important role in the gastrointestinal mucosa and ulcer healing, and it may be protective against small bowel injury after irradiation. Infusion of VEGF inhibitors delays healing of gastric erosions.^[19] Additionally, excessive VEGF inhibition can cause regression of normal blood vessels and reduced vascular density in the small intestinal villi, affecting recovery of damaged tissue.^[20]

The schedule of radiotherapy and the timing, duration, dosage and selection of VEGF inhibitor may determine the extent of treatment-related toxicity. In the current study, we used fractionated radiation therapy. Our patient presented with intermittent gastrointestinal hemorrhage 7 months after radiation therapy; however, gastroscopy confirmed that the hemorrhagic lesions were not radiation-associated.

Postoperative adjuvant radiotherapy or chemoradiotherapy is beneficial for gastric cancer patients. However, some elderly patients with resected gastric adenocarcinoma may not gain a survival benefit from administration of adjuvant chemo-radiotherapy.^[21] The patient in the current study refused chemoradiotherapy after termination of apatinib. The PFS of

this patient reached 7 months and he experienced good quality of life. After disease progression, best supportive care was prescribed.

Future studies investigating treatment regimens for advanced gastric cancer should focus on target validation, the development of biomarkers of gastrointestinal toxicity, and stratify patients by age in order to better understand the impact of treatment regimens on older patients. There is a need for more data to create treatment guidelines that can be refined to maximize treatment benefit and minimize toxicity.

4. Conclusion

Elderly patients with advanced gastric cancer may benefit from concurrent apatinib and local radiation therapy when chemotherapy is not tolerated or successful. Further studies are needed to investigate the clinical outcomes and toxicities associated with concurrent apatinib and radiation therapy in gastric cancer.

References

- Lu S, Zhu Z. Clinical and prognostic features of surgical treatment in gastric cancer in aged patients. *Zhonghua Wei Chang Wai Ke Za Zhi* 2016;19:596–600.
- Cunningham D, Okines AF, Ashley S. Capecitabine and oxaliplatin for advanced esophagogastric cancer. *N Engl J Med* 2010;362:858–9.
- Ajani JA, Buyse M, Lichinitser M, et al. Combination of cisplatin/S-1 in the treatment of patients with advanced gastric or gastroesophageal adenocarcinoma: results of noninferiority and safety analyses compared with cisplatin/5-fluorouracil in the First-Line Advanced Gastric Cancer Study. *Eur J Cancer* 2013;49:3616–24.
- Folkman J. Tumor angiogenesis: therapeutic implications. *N Engl J Med* 1971;285:1182–6.
- Geng R, Li J. Apatinib for the treatment of gastric cancer. *Expert Opin Pharmacother* 2015;16:117–22.
- Bang YJ, Van Cutsem E, Feyereislova A, et al. Trastuzumab in combination with chemotherapy versus chemotherapy alone for treatment of HER2-positive advanced gastric or gastro-oesophageal junction cancer (ToGA): a phase 3, open-label, randomised controlled trial. *Lancet* 2010;376:687–97.
- Ferrara N, Kerbel RS. Angiogenesis as a therapeutic target. *Nature* 2005;438:967–74.
- Cheng AL, Kang YK, Chen Z, et al. Efficacy and safety of sorafenib in patients in the Asia-Pacific region with advanced hepatocellular carcinoma: a phase III randomised, double-blind, placebo-controlled trial. *Lancet Oncol* 2009;10:25–34.
- Gurzu S, Kadar Z, Sugimura H, et al. Gastric cancer in young vs old Romanian patients: immunoprofile with emphasis on maspin and mena protein reactivity. *APMIS* 2015;123:223–33.
- Zhang H. Apatinib for molecular targeted therapy in tumor. *Drug Des Devel Ther* 2015;9:6075–81.
- Li J, Qin S, Xu J, et al. Randomized, double-blind, placebo-controlled phase III trial of apatinib in patients with chemotherapy-refractory advanced or metastatic adenocarcinoma of the stomach or gastroesophageal junction. *J Clin Oncol* 2016;34:1448–54.
- Small WJr, Mulcahy MF, Rademaker A, et al. Phase II trial of full-dose gemcitabine and bevacizumab in combination with attenuated three-dimensional conformal radiotherapy in patients with localized pancreatic cancer. *Int J Radiat Oncol Biol Phys* 2011;80:476–82.
- Spigel DR, Hainsworth JD, Yardley DA, et al. Tracheoesophageal fistula formation in patients with lung cancer treated with chemoradiation and bevacizumab. *J Clin Oncol* 2010;28:43–8.
- Lordick F, Geinitz H, Theisen J, et al. Increased risk of ischemic bowel complications during treatment with bevacizumab after pelvic irradiation: report of three cases. *Int J Radiat Oncol Biol Phys* 2006;64:1295–8.
- Barney BM, Markovic SN, Laack NN, et al. Increased bowel toxicity in patients treated with a vascular endothelial growth factor inhibitor (VEGFI) after stereotactic body radiation therapy (SBRT). *Int J Radiat Oncol Biol Phys* 2013;87:73–80.
- Potten CS. Extreme sensitivity of some intestinal crypt cells to X and gamma irradiation. *Nature* 1977;269:518–21.

- [17] Brown M. What causes the radiation gastrointestinal syndrome?: overview. *Int J Radiat Oncol Biol Phys* 2008;70:799–800.
- [18] Brush J, Lipnick SL, Phillips T, et al. Molecular mechanisms of late normal tissue injury. *Semin Radiat Oncol* 2007;17:121–30.
- [19] Yoshida M, Wakabayashi G, Ishikawa H, et al. A possible defensive mechanism in the basal region of gastric mucosa and the healing of erosions. *Clin Hemorheol Microcirc* 2003;29:301–12.
- [20] Pollom EL, Deng L, Pai RK, et al. Gastrointestinal toxicities with combined antiangiogenic and stereotactic body radiation therapy. *Int J Radiat Oncol Biol Phys* 2015;92:568–76.
- [21] Hoffman KE, Neville BA, Mamon HJ, et al. Adjuvant therapy for elderly patients with resected gastric adenocarcinoma: population-based practices and treatment effectiveness. *Cancer* 2012;118:248–57.