

## Case Report

# Spontaneous bilateral subdural hematoma in a patient with a prosthetic valve and association with plasmodium vivax malaria: A rare case report

Ishak Ahmed Abdi<sup>a,\*</sup>, Nor Osman Sidow<sup>b</sup>, Mohamed Sheikh Hassan<sup>b</sup>,  
Mohamed Farah Yusuf Mohamud<sup>c</sup>, Mesut Karataş<sup>a</sup>

<sup>a</sup> Department of Cardiology, Mogadishu Somali Turkish Training and Research Hospital, Mogadishu, Somalia

<sup>b</sup> Department of Neurology, Mogadishu Somali Turkish Training and Research Hospital, Mogadishu, Somalia

<sup>c</sup> Mogadishu Somali Turkish Training and Research Hospital, Mogadishu, Somalia



## ARTICLE INFO

## Keywords:

Spontaneous subdural hematoma  
Warfarin  
Prosthetic valve  
Plasmodium vivax malaria

## ABSTRACT

**Introduction and importance:** Bilateral subdural hematoma (SDH) is a very rare condition which can occur without any apparent etiology. It's characterized by a lower frequency of focal neurological impairments, which could delay the diagnosis and postpone treatment. The reported incidence of an acute spontaneous subdural hematoma (SSH) varies between 2% and 6.7% of all acute SDH. SDH following Plasmodium vivax (P. vivax) infection are uncommon to our knowledge, only two cases of SDH linked with P. vivax infection have been documented in the literature.

**Case presentation:** We describe a case of a 31-year-old male with a history of mitral mechanical valve replacement on anti-coagulant presented with spontaneous bilateral subdural hematoma in the presence of malaria. The patient had a limited vague symptom, which delayed a prompt diagnosis of his disease.

**Clinical discussion:** Spontaneous subdural hematoma has only a few documented cases. Hypertension, infections, vascular malformations, ruptured aneurysms, thrombocytopenia caused by hematological and oncological illnesses, acquired or inherited types of coagulopathies, and drug abuse are all risk factors. Also, SDH has been documented in the literature as a consequence of Plasmodium infection. In addition to that this patient was on anti-epileptic medicines which might potentiate vitamin K antagonists. Numerous factors were thought to have contributed to this significant bleeding.

**Conclusion:** Patients on anticoagulants who exhibit nebulous symptoms, including a mild headache, should be subjected to a thorough history and examination. And any factor delaying an accurate diagnosis should be eliminated. This will complement the patient's plan and management.

## 1. Introduction

Spontaneous subdural hematoma (SSHs) are uncommon, with only a few case reports in the medical literature. The reported incidence of an acute SSH varies between 2% and 6.7% of all acute subdural hematoma [1]. In patients with mechanical heart valves, subdural hematoma (SDH) was responsible for 50% of anticoagulant-related intracranial hemorrhages [2]. Several cases have been reported in the literature of spontaneous subdural hematomas in association with Plasmodium falciparum malaria [3,4]. However, incidence of SDH following Plasmodium vivax (P. vivax) infection is rare, as per our knowledge only two cases with isolated plasmodium vivax infection has been reported [5,6].

We present here a case of a 31-year-old male with a history of mitral mechanical valve replacement who presented with spontaneous bilateral subdural hematoma in the setting of Malaria.

## 2. Case presentation

A 31-year-old male presented to the outpatient department of cardiology complaining of a mild headache and tiredness associated with a mild temperature in five days. Three years prior he had prosthetic mitral valve replacement for rheumatic mitral valve stenosis. He has no significant family history. His history also revealed hypertension and epilepsy. Two days prior to presentation, the patient received a

\* Corresponding author. Department of Cardiology, Mogadishu Somali-Turkish Training and Research Hospital, Second Street, Black Sea, Hodan district, Mogadishu, Somalia.

E-mail address: [isakabdi70@gmail.com](mailto:isakabdi70@gmail.com) (I.A. Abdi).

<https://doi.org/10.1016/j.amsu.2022.104191>

Received 18 June 2022; Received in revised form 10 July 2022; Accepted 10 July 2022

Available online 13 July 2022

2049-0801/© 2022 The Authors. Published by Elsevier Ltd on behalf of IJS Publishing Group Ltd. This is an open access article under the CC BY-NC-ND license (<http://creativecommons.org/licenses/by-nc-nd/4.0/>).

*Plasmodium vivax* (*P. vivax*) diagnosis in another healthcare facility. There was no history of projectile vomiting or convulsions, no blurred or double vision, no weight loss or weakness, and no other neurological abnormalities. The patient had not reported any trauma or falling history recently. There has been no history of any symptoms that may indicate a bleeding issue, such as easy bruising, significant bleeding from minor wounds, or inexplicable nosebleeds. His current medical treatments included warfarin 2 mg once every 4 days, lamotrigine 100 mg, phenytoin 100 mg, valsartan plus hydrochlorothiazide 160/12.5, and arthemeter lumefantrine 20/120 mg. He was vitally stable and oriented to time, place, and person; memory was intact; pupils responded equally to light; all limbs were powered five out of five; intact cranial nerves examination; and normal gait. The sound of prosthetic valves was heard clearly. An international normalized ratio (INR) of 2.08 (the target range for patients with MVR is 2.5–3.5), and a prothrombin time (PT) of 27 (11–16 sec). Other laboratories were normal. His symptoms were assumed to be related to the recent diagnosis of uncomplicated malaria, and at that time, a CT scan was not done and he was consulted to complete the anti-malaria treatment.

After the headache persisted for four days, the patient came to the emergency department complaining of a throbbing severe headache, which he scored 8 out of 10. The following were his initial vital signs: blood pressure was 125/85, heart rate was 82 minutes, temperature 38 °C, respiratory rate was 16 breaths per minute, and SaO<sub>2</sub> was 98% on ambient air. The results of the full blood count were within normal limits. The platelet function tests were normal. Coagulation tests revealed INR of 5.9, PT of 79, and partial thromboplastin time of 165 (23–35 sec). All other routine investigations were normal. His Glasgow Coma Scale was 15, with no neurological deficit. Due to a history of severe headaches, a history of warfarin use, and an abnormal coagulation profile, a head CT scan was ordered, which showed acute subdural hematoma in both cerebral hemispheres, the deepest area measured 3 cm (Fig. 1). He was transferred to a high dependency ward in our hospital under close follow up of his neurological assessment and coagulation profile. On trans-thoracic echocardiography, the mechanical prosthetic valve was found in the mitral position with proper opening and closing. The forward flow gradient was 10 mmHg on average.

Because the INR was above the intended therapeutic range (2.5–3.5) for MVR and a second bleed was anticipated, warfarin was discontinued. Vitamin K injections and 4 units of fresh blood were used to try to reverse bleeding diathesis. Also, the patient was anticoagulated with unfractionated heparin with APTT monitoring.

A multidisciplinary discussion involving cardiologists, neurologists,

and neurosurgeons took place. Due to patient's little neurological deficit, abnormal coagulation parameters surgical intervention was considered both high risk and undesirable and they suggested to be treated conservatively. His INR was reduced to 2.9, PT of 38.6 sec, and partial thromboplastin time of 109 sec.

After one day of follow-up in the intensive care unit, the patient's condition deteriorated and he had a drop in sensorium, GCS 8, necessitating mechanical intubation. A repeat CT brain revealed a crescent-shaped homogeneously hypertense subdural collection in bilateral cerebral hemispheres and along the right tentorial leaflet, as well as re-expansion of the subdural hematoma with bilateral bi-convex extradural hematoma (Fig. 2A&B). The patient's clinical state deteriorated, with no evidence of neurologic improvement, and he passed away three days later. The case has been reported in line with the SCARE criteria [18].

### 3. Discussion

Subdural hematoma is attributed by a collection of blood between the dura mater and the arachnoid membrane. The most prevalent cause is trauma, which causes traction of the bridging veins as a result of fast acceleration or deceleration of the head [7].

Spontaneous subdural hematoma have only a few documented cases. Hypertension, infections, vascular malformations, ruptured aneurysms, thrombocytopenia caused by hematological and oncological illnesses, acquired or inherited types of coagulopathy, and drug abuse are all risk factors [1,8]. Anticoagulation is linked to an increased risk of bleeding. With an international normalized ration (INR) > 4.8, the risk of hemorrhagic problems increases in patients who have a mechanical valve and are on anticoagulation [9]. SDH has been documented in the literature as a consequence of *Plasmodium falciparum* infection [3,4]; however, SDH after *Plasmodium vivax* infection is uncommon; to our knowledge, only two cases of isolated plasmodium vivax infection have been reported [5,6]. Interactions between warfarin and other drugs mainly induce a change in the international normalized ratio (INR), but they can also cause bleeding and/or thromboembolic events [10,11]. The interaction of warfarin and phenytoin isn't completely understood [12]. Anticoagulation decisions in persons with epilepsy are complicated, because each of these patients has unique risk profiles for thrombotic/bleeding events [13].

Our patient was on a vitamin K antagonist with an INR target of 2.5–3.5, and numerous factors were suspected to have played a part in this major bleeding, including *Plasmodium Vivax* and anti-epileptic drugs.

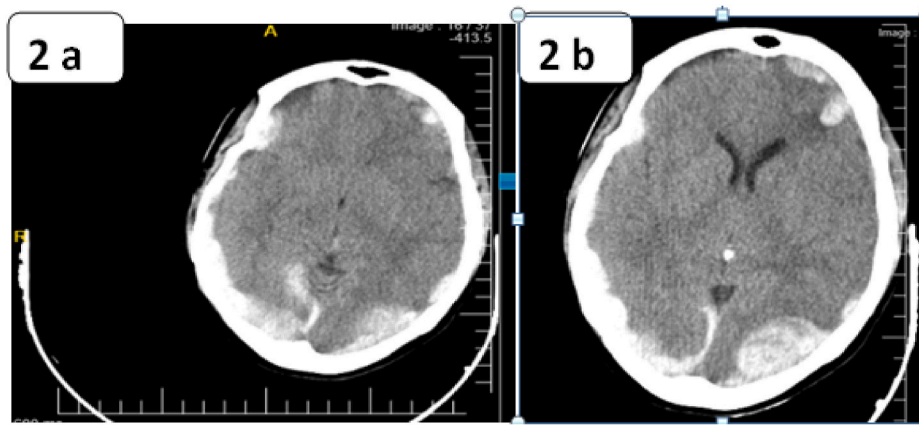
Surgical evacuation of chronic SDH is linked to a positive outcome [2]. However, the result in patients with acute SDH is not always favorable. Failure to reverse anticoagulation before to surgery may be linked to a bad outcome [14]. An INR of at least 1.4 or less is recommended as the ideal coagulation parameter for neurosurgical operations [15,16]. Our case was treated conservatively because he had an acute subdural hematoma with few symptoms and the anticoagulants had not been reversed in a timely manner.

The therapeutic management of hemorrhagic patients on anticoagulant medication in patients with mechanical heart valve prostheses was extremely problematic; restarting treatment could result in bleeding recurrence, but suspending or halting treatment could result in prosthesis thrombosis [17]. Despite all efforts to reverse the anticoagulation using FFP and vitamin K injections, the goal range was not reached in our reported case, which could be related to many factors leading to bleeding diathesis, which were present in this instance.

In conclusion for patients using anticoagulants, any misinterpretation of variables affecting drug pharmacodynamics and pharmacokinetics should be explored. This will contribute in the patient's plan and pave the way for the other management strategy.

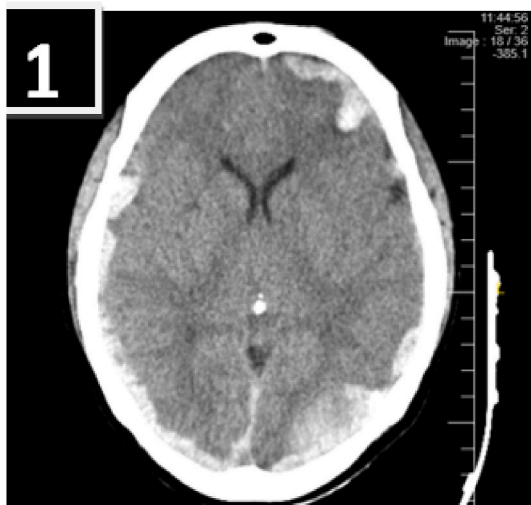

Fig. 1. Acute subdural hematoma in both cerebral hemispheres the deepest area measures 3cm.



**Fig. 2.** A&B Crescent-shaped homogeneously hyperdense subdural hematoma bilateral cerebral hemispheres (2a) and along with Bi-convex hyperdense collection under the skull (extradural) in bilateral occipital, right side measures  $3 \times 1.5$  cm and left side measures  $4 \times 2.5$  cm (2b).

### Funding resources

We declared that we have not received any financial support.

### Registration of research studies

1. Name of the registry: **Not Applicable**
2. Unique Identifying number or registration ID: **Not Applicable**
3. Hyperlink to your specific registration (must be publicly accessible and will be checked): **Not Applicable**

### Ethics approval

Based on the regulations of the review board of the Mogadishu Somali Turkish Training and Research Hospital, institutional review board approval is not required for case reports.

### Consent for publication

Written informed consent was obtained from the patient's brother for publication of this case report and accompanying images. A copy of the written consent is available for review by the Editor-in-Chief of this journal on request.

### Author contributions

All authors performed substantial contributions to the case sections. Took part in drafting the case or revising it critically for important intellectual content and gave final approval of the version to be published.

### Guarantor

Ishak Ahmed Abdi.

### Provenance and peer review

Not commissioned, externally peer-reviewed.

### Declaration of competing interest

The authors declare that there is no competing interest related to the study, authors, other individuals, or organizations.

### References

- [1] D. Garbossa, R. Altieri, F.C. Specchia, A. Agnoletti, G. Pilloni, M. Lanotte, R. Spaziante, A. Ducati, Are acute subdural hematomas possible without head trauma? *Asian J. Neurosurg.* 9 (4) (2014 Oct) 218.
- [2] E.F. Wijidicks, W.I. Schievink, R.D. Brown, C.J. Mullany, The dilemma of discontinuation of anticoagulation therapy for patients with intracranial hemorrhage and mechanical heart valves, *Neurosurgery* 42 (4) (1998 Apr 1) 769–772.
- [3] S.C. Chaudhary, S.K. Sonkar, V. Kumar, A. Gupta, Falciparum malaria presenting as subdural hematoma, *J. Assoc. Phys. India* 59 (2011 May 1) 325–326.
- [4] M.F. Huda, N.I. Kamali, V.K. Srivastava, M. Kaif, Spontaneous acute subdural hematoma in malaria: a case report, *J. Vector Borne Dis.* 48 (2011) 247–248.
- [5] Y. Thirumal, R. Alugolu, Spontaneous chronic subdural hematoma following Plasmodium vivax malaria: a rare association, *J. Vector Borne Dis.* 51 (1) (2014 Mar 1) 73.
- [6] A.R. Mallela, S. Hariprasad, R. Koya, V. Acharya, S.B. Krishna, Spontaneous subdural haemorrhage: a rare association with plasmodium vivax malaria, *J. Clin. Diagn. Res.: J. Clin. Diagn. Res.* 10 (1) (2016 Jan) OD05.
- [7] S. Moledina, M. Shanmuganathan, S. Pathak, A. Simon, Spontaneous subdural haematoma in a patient with a total artificial heart on warfarin, *BMJ Case Rep. CP* 12 (9) (2019 Sep 1), e230519.
- [8] Syncardia, How does the syncardia total artificial heart work?, 6th Mar 2019, <https://syncardia.com/patients/patient-resources/how-does-the-total-artificial-heart-work/>, 2019.
- [9] P.D. Stein, D. Grandison, T.A. Hua, P.M. Slettehaugh, J.W. Henry, P. Turlapaty, R. Kerwin, Therapeutic level of oral anticoagulation with warfarin in patients with mechanical prosthetic heart valves: review of literature and recommendations based on international normalized ratio, *Postgrad. Med.* 70 (1994) S72–S83.
- [10] W. Ageno, A.S. Gallus, A. Wittkowsky, M. Crowther, E.M. Hylek, G. Palareti, American college of chest physicians. Oral anticoagulant therapy: antithrombotic therapy and prevention of thrombosis, 9th ed: American college of chest physicians evidence-based clinical practice guidelines, *Chest* 141 (suppl 2) (2012) e44S–e88S.
- [11] A.M. Holbrook, J.A. Pereira, R. Labiris, Systematic overview of warfarin and its drug and food interactions, *Arch. Intern. Med.* 165 (10) (2005) 1095–1106.
- [12] N.P. Clark, K. Hoang, T. Delate, J.R. Horn, D.M. Witt, Warfarin interaction with hepatic cytochrome P-450 enzyme-inducing anticonvulsants, *Clin. Appl. Thrombosis/Hemostasis.* 24 (1) (2018 Jan) 172–178.
- [13] M.R. Keezer, S.M. Sisodiya, J.W. Sander, Comorbidities of epilepsy: current concepts and future perspectives, *Lancet Neurol.* 15 (1) (2016 Jan 1) 106–115.
- [14] T. Kawamata, M. Takeshita, O. Kubo, M. Izawa, M. Kagawa, K. Takakura, Management of intracranial hemorrhage associated with anticoagulant therapy, *Surg. Neurol.* 44 (5) (1995 Nov 1), 438–2.
- [15] N.M. Boulis, M.P. Bobek, A. Schmaier, J.T. Hoff, Use of factor IX complex in warfarin-related intracranial hemorrhage, *Neurosurgery* 45 (5) (1999 Nov 1) 1113–1119.
- [16] T. Mathiesen, K. Benediktsdottir, H. Johnsson, M. Lindqvist, H. Von Hoist, Intracranial traumatic and non-traumatic haemorrhagic complications of warfarin treatment, *Acta Neurol. Scand.* 91 (3) (1995 Mar) 208–214.
- [17] Y.C. Chan, J.P. Morales, J.F. Reidy, P.R. Taylor, Management of spontaneous and iatrogenic retroperitoneal haemorrhage: conservative management, endovascular intervention or open surgery? *Int. J. Clin. Pract.* 62 (10) (2008 Oct) 1604–1613.
- [18] R.A. Agha, T. Franchi, C. Sohrabi, G. Mathew, for the SCARE Group, The SCARE 2020 guideline: updating consensus surgical Case REport (SCARE) guidelines, *Int. J. Surg.* 84 (2020) 226–230.