


Elsberg Syndrome, Lumbosacral Radiculopathy, and Myelitis Due to Herpes Zoster in a Patient With Smoldering Myeloma

Journal of Investigative Medicine High Impact Case Reports
Volume 10: 1–5
© 2022 American Federation for Medical Research
DOI: 10.1177/23247096211063348
journals.sagepub.com/home/hic


Rohan Desai, MS4¹ , Cynthia T. Welsh, MD¹,
and Samuel O. Schumann III, MD, MSCR¹ 

Abstract

Herpes zoster (HZ) is a common illness caused by the reactivation of latent varicella zoster virus (VZV) due to waning immunity, often secondary to old age or an underlying immunocompromised state. Its complications can manifest in variety of ways, including persistent neuralgias, vasculopathies, and stroke. Here, we describe a case of a 45-year-old man with a history of cryptogenic stroke and smoldering myeloma who was admitted with sacral HZ complicated by right lumbosacral radiculopathy and myelitis, otherwise known as Elsberg syndrome (ES). He was found to have an enhancing lesion in the peripheral conus medullaris on magnetic resonance imaging (MRI) with nonspecific inflammation and necrosis on biopsy pathology and cerebrospinal fluid (CSF) polymerase chain reaction (PCR) positive for VZV. The patient was initially treated with intravenous acyclovir and dexamethasone and discharged with a steroid taper and indefinite valacyclovir therapy. Twelve months postdischarge, the patient's right lumbosacral radiculopathy and myelitis had almost completely resolved; however, he continued to require bladder self-catheterization. We believe that the patient's underlying smoldering myeloma lead to an immunocompromised state, allowing for reactivation of latent VZV, resulting in both the patient's cryptogenic stroke years earlier and recent ES.

Keywords

herpes zoster, Elsberg syndrome, cauda equina, smoldering myeloma

Case Report / Case Presentation

A 45-year-old man with a history of cryptogenic stroke presented to our institution's outpatient clinic with acute urinary retention, incontinence of stool, right lumbosacral vesicular rash, and paresthesias in his right leg.

Approximately 2.5 years prior to this presentation, the patient was admitted to the neurology stroke service with encephalopathy found to have an acute ischemic stroke. He experienced symptoms of an upper respiratory tract infection 3 days prior to his stroke and treated these symptoms with over-the-counter cough and cold medication. At home, he became acutely confused, was brought to the emergency department (ED) via emergency medical services (EMS), and was found to have aphasia and dysarthria concerning for stroke. Initial ED evaluation, including computed tomography (CT) of the head and CT angiogram of the head and neck, was unremarkable for acute hemorrhage, arterial stenosis, or aneurysm. Subsequent lumbar puncture was notable for red blood cell count of 604/mm³, absolute white blood cell count of 0/mm³, protein of 103.6 mg/dL, and a glucose

of 80 mg/dL (with a plasma glucose of 138 mg/dL) on cerebrospinal fluid (CSF) analysis. Cerebrospinal fluid Gram stain, cultures, enterovirus polymerase chain reaction (PCR), and herpes simplex virus (HSV) 1 & 2 PCR were negative. The CSF varicella zoster virus (VZV) PCR was not ordered. Magnetic resonance imaging (MRI) of the brain without contrast showed an acute infarct in the left periventricular white matter with punctate areas of diffusion abnormality within the right frontal lobe, right thalamus, and left basal ganglia. He was admitted to the neurology stroke service;

¹Medical University of South Carolina, Charleston, USA

Received September 13, 2021. Revised November 2, 2021. Accepted November 10, 2021.

Corresponding Author:

Samuel O. Schumann III, MD, MSCR, Assistant Professor of Medicine, Division of General Internal Medicine, Medical University of South Carolina, 135 Rutledge Ave, MSC 591, Suite 1240, Charleston, SC 29425, USA.

Email: schuman@musc.edu



was started on empiric treatment for infectious meningitis with acyclovir, ceftriaxone, and vancomycin; and underwent further evaluation to determine the source of his encephalopathy and ischemic strokes. Electroencephalogram showed diffuse background slowing but was otherwise unremarkable. Blood and urine cultures returned without growth and respiratory viral PCR was negative. Cardiac telemetry did not find an arrhythmia and transthoracic echocardiogram and transesophageal echocardiogram did not reveal intracardiac thrombus, shunt, or other a possible stroke source. During this hospitalization, he was incidentally found to have monoclonal IgG (immunoglobulin G) lambda gammopathy at 0.83 g/dL. Encephalopathy resolved by day 4 of hospitalization and he was discharged to acute rehabilitation to complete gait re-training where he made a full recovery. On outpatient follow-up, 30-day mobile cardiac telemetry did not identify arrhythmia and it was recommended that aspirin 81 mg and high-dose statin be continued indefinitely.

Sixteen months prior to the current presentation, his monoclonal IgG lambda gammopathy increased to 2.01 g/dL and he was referred to malignant hematology. Bone marrow biopsy revealed plasma cell neoplasm with 15% cellularity, but he did not exhibit end-organ damage related to his myeloma. He was diagnosed with smoldering myeloma and monitored under active surveillance.

Four days prior to the current presentation, he was evaluated in our institution's ED for acute urinary retention with severe lower abdominal pain. Urinalysis at the time was unremarkable for an infectious etiology and the patient had resolution of symptoms following bladder drainage with a urinary catheter. He was discharged with a foley catheter in place, prescribed tamsulosin, and referred to the outpatient urology clinic. However, the following day, he noticed a nontender, nonpruritic rash on his right buttocks that subsequently spread to his right groin, penis, and scrotum (Figure 1). Over the next 3 days, he experienced associated paresthesia of the right lower extremity, weakness of the right lower extremities, and incontinence of stool with coughing and sneezing. On the third day after rash development, he presented to his primary care provider's office with a chief complaint of a progressive rash, right lower extremity weakness and numbness, urinary retention with foley catheter in place, and fecal incontinence. On examination, his blood pressure was 131/87 mmHg and pulse was 81 bpm. Nontender, nonpruritic cropped vesicular lesions on erythematous bases were present in an S2-S3 distribution extending from the right buttocks and wrapped anteriorly across the right side of the groin, scrotum, and shaft of penis. Saddle anesthesia was present and strength in the bilateral lower extremities was 5/5 proximally and distally, deep tendon reflexes were normal, and rectal tone was diminished with stool incontinence. He was immediately transferred to our institution's ED with concern for cauda equina syndrome in the setting of acute herpes zoster (HZ). In the ED, MRI of the lumbar spine with and without contrast showed a

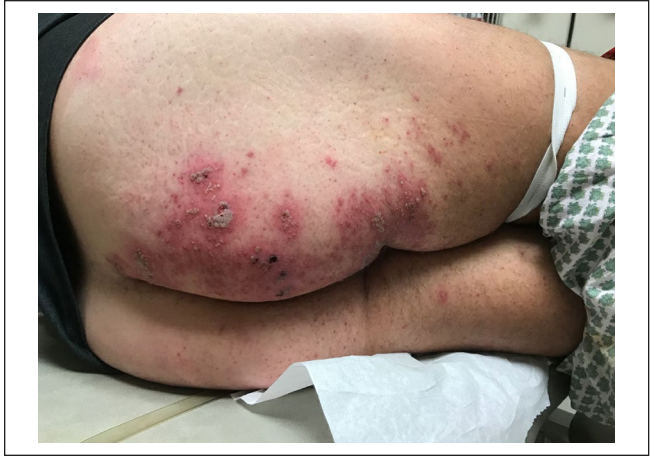

Figure 1. Cropped vesicular and pustular rash along right buttocks.

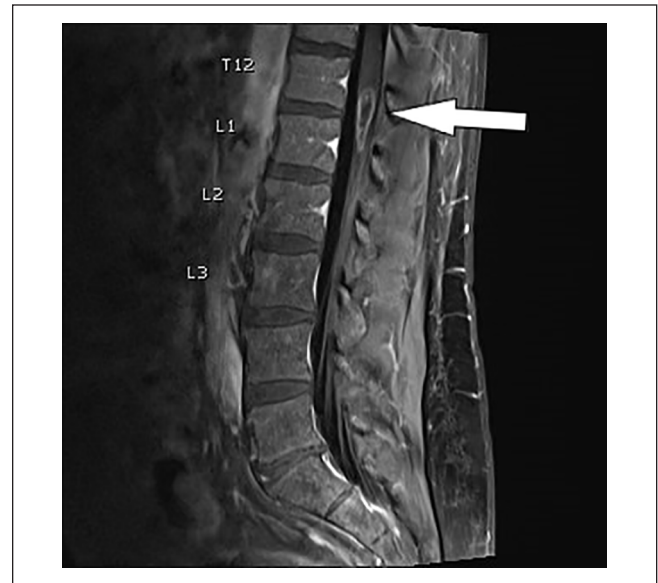

Figure 2. Peripherally enhancing region in the conus medullaris (white arrow).

peripherally enhancing region in the conus medullaris (Figure 2). Other diagnostic studies in the ED included a urinalysis that was notable for elevated protein of 100 mg/dL and elevated red blood cell count of >182 , complete blood count and complete metabolic panel which were unremarkable, and HIV-1, HIV-2, and hepatitis C virus (HCV) antibodies which were nonreactive. He was started immediately on intravenous (IV) acyclovir and was not initially treated with dexamethasone to prevent disruption of surgical pathology. He was admitted under airborne and contact isolation precautions to the neurosurgery service with infectious diseases, neurology, dermatology, hematology, and urology consultation. The CSF analysis from lumbar puncture was notable for absolute white blood cell count of $59/\text{mm}^3$,

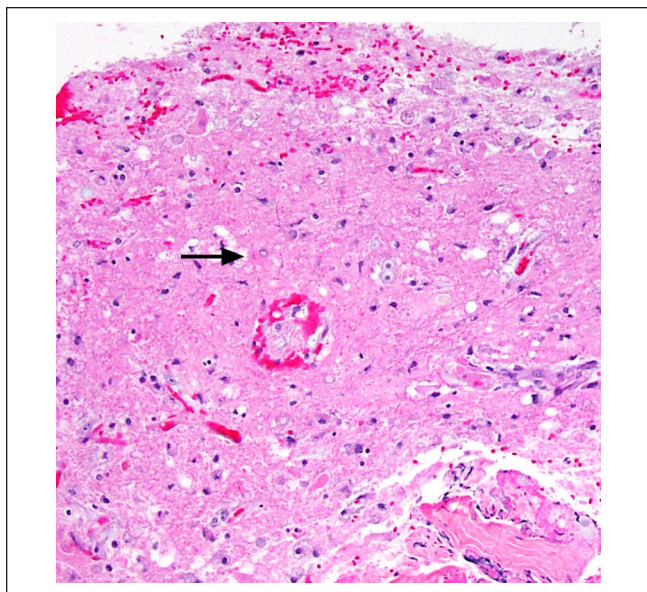


Figure 3. Surgical biopsy from conus medullaris lesion showing gliosis (black arrow).

elevated protein of 193 mg/dL, and elevated IgG monoclonal immune globulin of 3770 mg/dL. The PCR CSF analysis later returned negative for HSV 1&2 PCR and positive for VZV PCR. Additional MRI of the brain, cervical spine, and thoracic spine with and without contrast showed a T2 hyperintense lesions in the posterior cervicomedullary junction and symmetrical enhancement of cranial nerves V and VII. Due to concern for neoplastic process, he also underwent contrasted CT of the chest, abdomen, and pelvis that revealed several indeterminate nodules in the lungs bilaterally. Given the patient's diagnosis of smoldering myeloma and new finding of lung nodules, there was concern for progression of smoldering myeloma versus a new malignancy. He underwent repeat bone marrow biopsy.

On day 2 of his hospitalization, the patient underwent lumbar decompression with resection of the conus medullaris lesion. Surgical pathology (Figure 3) was nonspecific—showing gliosis with necrosis, no clear evidence for vasculitis, no neoplasm, and no virus seen. These findings could represent infarct, inflammatory, infectious, or demyelinating processes. With a neoplastic process being unlikely, dexamethasone therapy was initiated. Infectious disease consultation recommended switching from acyclovir to IV valacyclovir given the burden of the patient's immunosuppression. On day 3 of his hospitalization, the patient underwent bone marrow biopsy with hematology that did not show evidence of progression of the patient's smoldering myeloma to active myeloma. The patient continued valacyclovir and dexamethasone therapy throughout his hospitalization and experienced improvement of his dermatologic lesions, sensation in his lower extremities, and bowel and bladder control. He was discharged to home on hospital day 8 with diagnosis of HZ

complicated by cauda equina syndrome, also known as Elsberg syndrome. He was prescribed a steroid taper and continued oral valacyclovir therapy indefinitely on discharge with close follow-up in neurosurgery, infectious disease, urology, and primary care clinics.

Six months after discharge, repeat MRI of central nervous system (CNS) showed resolution of cerebral enhancing lesions with improvement of the linear enhancement of the conus. There were no new CNS lesions. The pulmonary nodules found on CT chest had resolved. Functionally, strength and sensation of the right leg had improved but not returned to normal and continence of stool had recovered. However, the patient continued to require self-bladder catheterization due to urinary retention and experienced erectile dysfunction with neuropathic pain along the penis. At 12 months after discharge, strength of right leg had nearly completely recovered and the patient had returned to prior exercises at the gym. He continued to experience paresthesia of the right distal leg and had developed some atrophy of the lateral gastrocnemius muscle. His urinary retention had not improved and he continued to require self-catheterization. His erectile dysfunction had resolved and sensation along the penis nearly returned to baseline. Considering his smoldering myeloma, he was continued on valacyclovir prophylactic therapy.

Discussion and Conclusion

Herpes zoster infection is a common illness in the United States with an incidence of approximately 1 million cases per year, caused by reactivation of latent varicella zoster infection.¹ Risk increases with age, with an incidence of approximately 5 cases per 1000 persons in those 50 to 59 years old and increasing to 11 cases per 1000 persons in those above 80 years old.¹ Risk increasing with age is a likely consequence of waning varicella-virus-specific T-cell immune response.² Other risk factors for HZ include immunocompromised state, including, but not limited to, patients receiving an organ transplant, patients with malignant neoplasm, and patients with HIV.³⁻⁶ Classically, HZ presents as a cropped, unilateral, vesicular, and painful rash confined to 1 to 3 contiguous dermatomes.⁷ The vesicles progress to pustules, crust, and heal over the course of 7 to 10 days.^{7,8} A prodromal phase of pain and paresthesia in affected dermatomes often occurs. Due to the pathognomonic characteristics of the rash, a clinical diagnosis is typically made; however, this can be confirmed with viral PCR testing from skin lesions.

The most commonly associated complication of HZ is postherpetic neuralgia (PHN), described as localized pain persisting for at least 90 days after the resolution of the rash, thought to affect around 20% of those with HZ.⁹ However, other complications have been reported. The above case provides an example of CNS VZV infection complicated by Elsberg syndrome, a rarely recognized cause of infectious lumbosacral radiculitis and myelitis.^{10,11} Findings supporting

this diagnosis include a rash consistent with HZ, neuropathy along the S2-S3 distribution, features of cauda equina syndrome (acute urinary retention, fecal incontinence, and saddle anesthesia), T2 peripherally enhancing lesion in the conus medullaris on MRI, a positive finding of CSF VZV PCR, and surgical pathology negative for neoplasm or other specific infectious or inflammatory process. One study estimated that Elsberg syndrome accounted for 10% of patients presenting with cauda equina syndrome and myelitis.¹⁰ Classically, HSV 2 is recognized as the most common cause of Elsberg syndrome, with VZV as a known and likely underrecognized cause of Elsberg syndrome. Other viruses implicated in the pathogenesis of Elsberg syndrome include cytomegalovirus, Epstein-Barr virus, and recently, severe acute respiratory syndrome coronavirus 2 (SARS-CoV-2).^{12,13}

Herpes zoster is known to cause vasculopathy with a wide range of central nervous system manifestations, including, but not limited to, transient ischemic attacks, aneurysm, hemorrhage, and stroke.¹⁴⁻¹⁶ The proposed mechanism for this involves trans-axonal spread of VZV to arteries and subsequent inflammation with arterial intimal thickening.¹⁷ The thickened arterial intima can eventually lead to occlusion and infarct presenting as ischemic stroke. The surgical pathology from the conus medullaris primarily shows gliosis and necrosis without virus or vasculopathy; however, that does not indicate that the patient did not have VZV vasculopathy at the time of the stroke. We hypothesize this could have been the cause of our patient's cryptogenic stroke years prior as all other causes were ruled out or highly unlikely. Notably, vasculopathy due to VZV reactivation can occur without rash.¹⁵

Our patient's underlying diagnosis of smoldering myeloma should be considered a contributing factor to his development of HZ and Elsberg syndrome. Patients with monoclonal gammopathy of unknown significance and multiple myeloma are known to have increased risk of infections, including viral infections and specifically HZ.¹⁸⁻²⁰ As smoldering myeloma fits in this spectrum of disease, it is believed that it leads to both a decreased cellular immunity and decreased humoral immunity.^{18,19} We believe that our patient's underlying smoldering myeloma contributed to an immunocompromised state leading to his presentation with HZ.

Ultimately, our immunocompromised patient was diagnosed with disseminated HZ complicated by Elsberg syndrome. Prompt identification of disseminated HZ and initiation of isolation precautions are important for the protection of care team members while the patient is contagious. Rapid initiation of treatment with antiviral therapy within 72 hours of development of the rash has been shown to improve outcomes while limiting progression of severe complications in the acute setting.²¹ Oral valacyclovir in particular is the preferred agent due to ease of dosing in those with uncomplicated disease, but IV acyclovir is preferred in those who are

immunocompromised or those with disseminated disease (including those with CNS involvement).⁸ Current guidelines recommend treatment for 7 to 10 days in cases of uncomplicated zoster.^{8,21} Our patient received IV acyclovir on initial presentation and was transitioned to valacyclovir, eventually being discharged on oral valacyclovir continued indefinitely due to concern over his underlying smoldering myeloma. It is unclear whether zoster vaccination can prevent severe complications from HZ infection such as vasculitis and myelitis; however, it is reasonable to assume so. Currently, the use of zoster vaccination for patients with immunocompromising condition is under review by the Advisory Committee on Immunization Practices. Further studies are needed to determine whether patients younger than 50 years old and facing an immunocompromised state, such as the patient in this case report, would benefit from zoster vaccination.

Declaration of Conflicting Interests

The author(s) declared no potential conflicts of interest with respect to the research, authorship, and/or publication of this article.

Funding

The author(s) received no financial support for the research, authorship, and/or publication of this article.

Ethics Approval


Our institution does not require ethical approval for reporting individual cases.

Informed Consent

Verbal informed consent was obtained from the patient for their anonymized information to be published in this article.

ORCID iDs

Rohan Desai  <https://orcid.org/0000-0003-4667-0651>

Samuel O. Schumann  <https://orcid.org/0000-0001-5989-9290>

References

1. Insinga RP, Itzler RF, Pellissier JM, Saddier P, Nikas AA. The incidence of herpes zoster in a United States administrative database. *J Gen Intern Med.* 2005;20:748-753. doi:10.1111/j.1525-1497.2005.0150.x.
2. Hayward AR, Herberger M. Lymphocyte responses to varicella zoster virus in the elderly. *J Clin Immunol.* 1987;7:174-178. doi:10.1007/bf00916011.
3. Yawn BP, Saddier P, Wollan PC, St. Sauver JL, Kurland MJ, Sy LS. A population-based study of the incidence and complication rates of herpes zoster before zoster vaccine introduction. *Mayo Clin Proc.* 2007;82:1341-1349. doi:10.4065/82.11.1341.
4. Chen SY, Suaya JA, Li Q, et al. Incidence of herpes zoster in patients with altered immune function. *Infection.* 2014;42:325-334. doi: 10.1007/s15010-013-0550-8.
5. Arvin AM. Varicella-zoster virus. *Clin Microbiol Rev.* 1996;9:361-381. doi:10.1128/CMR.9.3.361-381.1996.

6. Buchbinder SP, Katz MH, Hessel NA, et al. Herpes zoster and human immunodeficiency virus infection. *J Infect Dis.* 1992;166:1153-1156. doi:10.1093/infdis/166.5.1153.
7. Weinberg JM. Herpes zoster: epidemiology, natural history, and common complications. *J Am Acad Dermatol.* 2007;57(6 Suppl):S130-S135. doi:10.1016/j.jaad.2007.08.046.
8. Cohen JI. Clinical practice: herpes zoster. *N Engl J Med.* 2013;369:255-263. doi:10.1056/NEJMcp1302674.
9. Johnson RW, Rice ASC. Postherpetic neuralgia. *N Engl J Med.* 2014;371:1526-1533. doi:10.1056/NEJMcp1403062.
10. Savoldi F, Kaufmann TJ, Flanagan EP, Toledano M, Weinshenker BG. Elsberg syndrome: a rarely recognized cause of cauda equina syndrome and lower thoracic myelitis. *Neurol Neuroimmunol Neuroinflamm.* 2017;4(4):e355. doi:10.1212/NXI.0000000000000355.
11. Steinberg CJ, Moody AD, Yenior AL, Bertasi RAO, Kieneker L, Pujalte GGA. Disseminated herpes zoster with cauda equina symptoms. *IDCases.* 2020;21:e00902. doi:10.1016/j.idcr.2020.e00902.
12. Eberhardt O, Küker W, Dichgans J, et al. HSV-2 sacral radiculitis (Elsberg syndrome). *Neurology.* 2004;63:758-759. doi:10.1212/01.wnl.0000134652.51657.10.
13. Abrams RMC, Desland F, Lehrer H, et al. A case of Elsberg syndrome in the setting of asymptomatic SARS-CoV-2 infection. *J Clin Neuromuscul Dis.* 2021;22:228-231. doi:10.1097/cnd.0000000000000369.
14. Amlie-Lefond C, Gilden D. Varicella zoster virus: a common cause of stroke in children and adults. *J Stroke Cerebrovasc Dis.* 2016;25:1561-1569. doi:10.1016/j.jstrokecerebrovasdis.2016.03.052.
15. Gilden D, Cohrs RJ, Mahalingam R, Nagel MA. Varicella zoster virus vasculopathies: diverse clinical manifestations, laboratory features, pathogenesis, and treatment. *Lancet Neurol.* 2009;8:731-740. doi:10.1016/S1474-4422(09)70134-6.
16. Nagel MA, Bubak AN. Varicella zoster virus vasculopathy. *J Infect Dis.* 2018;218:S107-S112. doi:10.1093/infdis/jiy425.
17. Nagel MA, Traktinskiy I, Azarkh Y, et al. Varicella zoster virus vasculopathy: analysis of virus-infected arteries. *Neurology.* 2011;77:364-370. doi:10.1212/WNL.0b013e3182267bfa.
18. Karlsson J, Andreasson B, Kondori N, et al. Comparative study of immune status to infectious agents in elderly patients with multiple myeloma, Waldenström's macroglobulinemia, and monoclonal gammopathy of undetermined significance. *Clin Vaccine Immunol.* 2011;18:969-977. doi:10.1128/CVI.00021-11.
19. Kristinsson SY, Tang M, Pfeiffer RM, et al. Monoclonal gammopathy of undetermined significance and risk of infections: a population-based study. *Haematologica.* 2012;97:854-858. doi:10.3324/haematol.2011.054015.
20. Kyle RA, Rajkumar SV. Multiple myeloma. *N Engl J Med.* 2004;351:1860-1873. doi:10.1056/NEJMra041875.
21. Dworkin RH, Johnson RW, Breuer J, et al. Recommendations for the management of herpes zoster. *Clinical Infectious Diseases.* 2007;44:S1-S26. doi:10.1086/510206.