

This is an Open Access article licensed under the terms of the Creative Commons Attribution-NonCommercial 3.0 Unported license (CC BY-NC) ([www.karger.com/OA-license](http://www.karger.com/OA-license)), applicable to the online version of the article only. Distribution permitted for non-commercial purposes only.

## Stroke Note

---

# Increase in the Size of an Intracardiac Thrombus during Dabigatran Therapy (110 mg b.i.d.) in an Acute Cardioembolic Stroke Patient

Emi Tabata Masahiro Yasaka Yoshiyuki Wakugawa Motohiro Komori  
Kohta Mori Yuichiro Tsurusaki Kazuhito Kokuba Yoshiki Sambongi  
Koichiro Maeda Yasushi Okada

Department of Cerebrovascular Medicine and Clinical Research Institute, National Hospital Organization Kyushu Medical Center, Fukukuoka, Japan

### Key Words

Intracardiac thrombus · Dabigatran · Acute cardioembolic stroke · Transesophageal echocardiography · Nonvalvular atrial fibrillation

### Abstract

We report a case of atrial fibrillation in a patient in whom a mobile thrombus in the left atrial appendage increased in size after low-dose dabigatran therapy. A 74-year-old man was admitted to our hospital because of sudden onset of right hemiparesis and dysarthria. On admission, his National Institutes of Health Stroke Scale score was three. Axial diffusion-weighted magnetic resonance images and magnetic resonance angiography images showed hyperintense signals in the left front-parietal cerebral cortex without any intracranial stenotic lesions, and acute cardioembolic stroke associated with nonvalvular atrial fibrillation was diagnosed. Transesophageal echocardiography revealed a mobile thrombosis (1.0 × 2.2 cm) in the left atrial appendage, and dabigatran therapy (110 mg b.i.d.) was initiated to prevent stroke recurrence. Transesophageal echocardiography performed 6 days later revealed that the size of the thrombus had increased to 1.5 × 3.0 cm. Medication was changed to warfarin, and the thrombosis subsequently decreased in size. The patient did not have a recurrent stroke and was discharged with a National Institutes of Health Stroke Scale score of zero. This case demonstrates that low-dose dabigatran may not be effective in reducing the size of a thrombus.

Copyright © 2013 S. Karger AG, Basel

---

Dr. Emi Tabata  
Department of Cerebrovascular Medicine and Clinical Research Institute  
National Hospital Organization Kyushu Medical Center  
1-8-1 Jigyohama, Chou-ku, Fukukuoka 810-8563 (Japan)  
E-Mail [emiandsmiley@kyumed.jp](mailto:emiandsmiley@kyumed.jp)

## Introduction

Warfarin therapy in patients with intracardiac thrombus is effective in reducing the size of a thrombus by inducing a relative predominance of plasma fibrinolytic activity over anticoagulation-inhibited thrombin activity [1]. However, the effect of novel oral anticoagulants on intracardiac thrombi has not been fully elucidated, and it is controversial whether or not dabigatran therapy is effective in decreasing the size of an intracardiac thrombus. Here, we report a patient with atrial fibrillation in whom a mobile thrombus in the left atrial appendage increased in size after dabigatran therapy (110 mg b.i.d.) was initiated for the prevention of stroke.

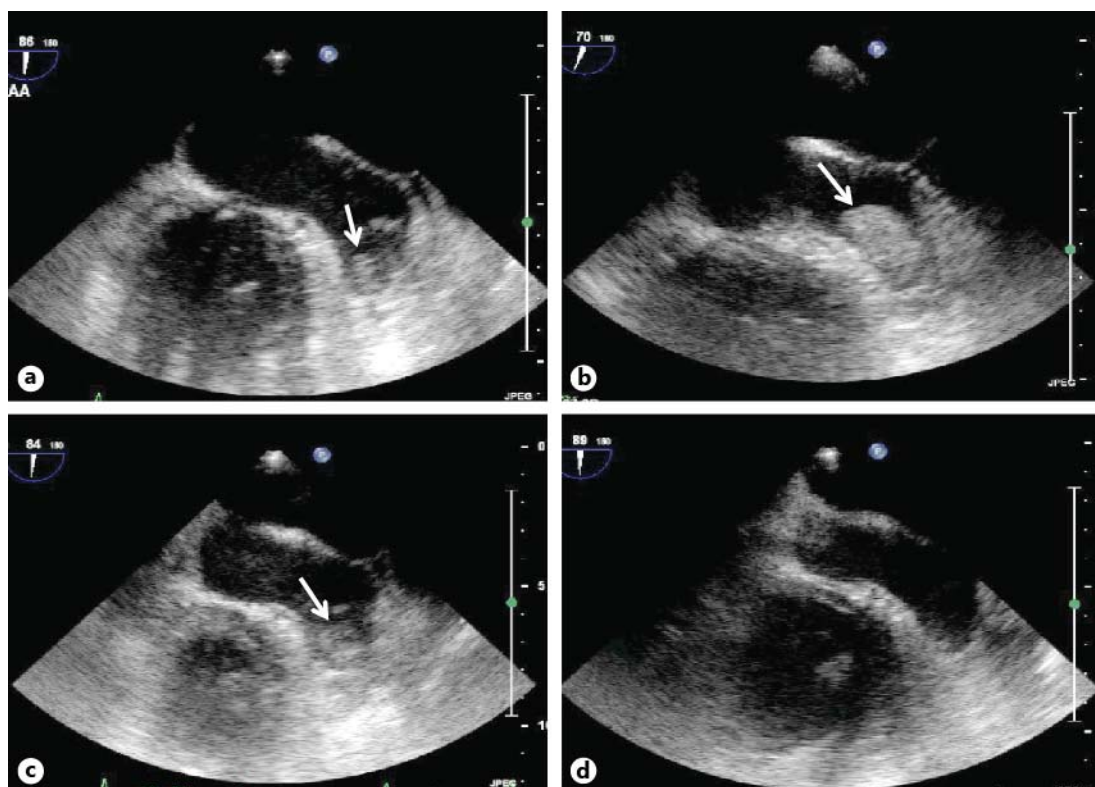
## Case Report

A 74-year-old Japanese man with hypertension, type 2 diabetes mellitus, ischemic heart failure, and nonvalvular atrial fibrillation (NVAf) presented at our hospital after the sudden onset of right hemiparesis and dysarthria. On admission, his National Institutes of Health Stroke Scale (NIHSS) score was three. The plasma level of the thrombin-antithrombin complex was 21.7 ng/ml (normal range: 0–3.0 ng/ml). Axial diffusion-weighted magnetic resonance images and magnetic resonance angiography images showed hyperintense signals in the left front-parietal cerebral cortex without any intracranial stenotic lesions, and acute cardioembolic stroke associated with NVAf was diagnosed.

Transesophageal echocardiography (TEE) performed on day 3 after admission revealed a mobile thrombus (1.0 × 2.2 cm) in the left atrial appendage (fig. 1a), and dabigatran therapy (110 mg b.i.d.) was initiated to prevent stroke recurrence. Activated partial thromboplastin time (APTT) was 31 s before dabigatran and 33 s 3 h after 110 mg dabigatran. TEE performed on day 9 after admission revealed that the size of the thrombus had increased to 1.5 × 3.0 cm (fig. 1b). Medication was changed from dabigatran to warfarin with a target prothrombin time/international normalized ratio of between 2.0 and 3.0. TEE performed on day 23 after admission revealed that the size of the thrombus had decreased (fig. 1c), and TEE performed on day 42 after admission revealed that the thrombus had disappeared (fig. 1d). The patient did not have a recurrent stroke and was discharged from hospital on day 43 with an NIHSS score of zero and a modified Rankin Scale grade of zero.

## Discussion

An intracardiac thrombus is detected by TEE in 12–14% of patients with NVAf [2–4]. The decrease in the size of a thrombus that occurs after warfarin therapy may be due to the relative predominance of plasma fibrinolytic activity over anticoagulation-inhibited thrombin activity [1]. Although warfarin is known to reduce the size of a thrombus, the effect of novel oral anticoagulants on intracardiac thrombi has not been fully elucidated. According to the present case, dabigatran therapy (110 mg b.i.d.) is not sufficient to decrease the size of a thrombus. This may be because dabigatran has a peak and a trough in its concentration curve that warfarin does not have, and the predominance of fibrinolytic activity that occurs in the trough phase may be too small to cause a reduction in the size of the thrombus. On the other hand, Vidal et al. [5] reported that in a 59-year-old woman with a clot in the left atrial appendage, the size of the thrombus decreased after dabigatran (150 mg b.i.d.) was used for 6–7 weeks. Therefore, in the present case, dabigatran 150 mg b.i.d. or warfarin may have been more effective than dabigatran 110 mg b.i.d. at reducing the size of the thrombus. Low



**Fig. 1.** Clinical course of the intracardiac thrombus demonstrated by TEE. **a** TEE obtained on day 3 after admission shows a mobile thrombus (1.0 × 2.2 cm) in the left atrial appendage. Subsequent TEEs show that the thrombus had increased to 1.5 × 3.0 cm on day 9 after admission (**b**), decreased to 0.8 × 1.0 cm on day 23 after admission (**c**), and disappeared on day 42 after admission (**d**).

bioavailability of dabigatran might be another explanation why intracranial thrombus reduction failed in this case. Low availability, absorption, and serum concentration of dabigatran are reflected by the low APTT that was observed 3 h after dabigatran administration. Therefore, for dabigatran treatment of intracardiac thrombus, it is important to ensure that APTT is prolonged in the first hours after administration.

## References

- 1 Yasaka M, Yamaguchi T, Misashita T, et al: Regression of intracardiac thrombus after embolic stroke. *Stroke* 1990;221:1540–1544.
- 2 Broukhim M, Halperin JL: Stroke prevention in the high risk atrial fibrillation patient: medical management. *Curr Cardiol Rep* 2011;13:9–17.
- 3 Medi C, Hankey GJ, Freedman SB: Stroke risk and antithrombotic strategies in atrial fibrillation. *Stroke* 2010; 41:2705–2713.
- 4 Santos-Gallego CG, Bayon J, Badimon JJ: Thrombi of different pathologies: implications for diagnosis and treatment. *Curr Treat Options Cardiovasc Med* 2010;12:274–291
- 5 Vidal A, Vanerio G: Dabigatran and left atrial appendage thrombus. *J Thromb Thrombolysis* 2012;34:545–547.