

## Appendiceal Schistosomiasis Presenting as an Appendiceal Mass

### Abstract

**Background:** Schistosomiasis has been noted to be one of the most widespread parasitic diseases in the world. It is commonest in developing countries and 85% of the infections have been reported in Sub-Saharan Africa. Presentation with an appendiceal mass has been a rarity among the cases reported thus far. **Case Presentation:** We report the case of a 23-year-old man who presented with an appendiceal mass that responded to conservative treatment and had interval appendicectomy with histological confirmation of schistosomal appendicitis. He received post-operative medical therapy for schistosomiasis and had no sequelae thereafter. **Conclusion:** Appendiceal mass from schistosomal appendicitis responds to initial conservative management, followed by interval appendicectomy and post-operative anti-schistosomal medications serving as adequate treatment subsequently.

**Keywords:** Appendiceal schistosomiasis, appendix mass, good outcome, interval appendicectomy, schistosomal treatment

### Introduction

Schistosomiasis has been noted to be one of the most widespread parasitic diseases in the world with estimates of at least 236.6 million people worldwide requiring preventive treatment for the condition in 2019 alone, out of which more than 105.4 million people were reported to have been treated.<sup>[1-5]</sup> Known by several other names including Bilharziasis, Bilharziosis and Snail-water disease, this infestation is caused by trematodes of the *Schistosoma* species. It is commonest in developing countries, especially those in the tropical regions of the world and 85% of the infections have been reported in Sub-Saharan Africa alone, lending credence to the assertion that the infestation occurs in well-defined endemic areas also called the Bilharziasis belts.<sup>[5-7]</sup> Six main species have been reported to cause infestations in humans among which infestations by *Schistosoma haematobium*, *Schistosoma mansoni* and *Schistosoma japonicum* predominate.<sup>[5,8-10]</sup> These trematodes are notorious for causing pathologies involving the gastrointestinal tract and urogenital systems in humans.

Since the first case of appendiceal Schistosomiasis was reported by Turner<sup>[9]</sup> in 1909, many other such case reports have been noted in the literature with presentations as acute and chronic appendicitis being

highlighted.<sup>[8,11-13]</sup> Presentation with an appendiceal mass has, however, been uncommon among the cases reported thus far. This case report will highlight the peculiarities with presentation of schistosomiasis as an appendiceal mass and its subsequent management.

### Case Presentation

The patient was a 23-year-old male student with recurrent colicky migratory right iliac fossa pain of 3 days duration. Symptoms were not relieved with medical interventions at peripheral center before referral. He had a previous episode a month prior to this which was associated with several episodes of bilious vomiting, passage of watery stools and low-grade fever. He was ill looking, not pale, anicteric, warm to touch with a right axillary temperature of 37.3°C, tachycardic with pulse of 114beats/minute, tachypneic with respiratory rate of 28 cycles/minute and vesicular breath sounds. He had right iliac fossa tenderness with positive Rovsing's sign, Obturator sign and Psoas' sign and had a vague right iliac fossa mass with normal bowel sounds and no suprapubic tenderness. Abdominal ultrasound scan showed an appendiceal mass that measured 8 cm x 10 cm. His pack cell volume and serum electrolyte urea and creatinine were within normal limits. He received conservative management with

**Stanley Emeka Nwabuoku<sup>1</sup>, George Duke Mukoro<sup>1</sup>, Muhammad Daniyan<sup>2</sup>, Muhammad Maigatari Dauda<sup>2</sup>, Lawal Khalid<sup>2</sup>, Halima Oziohu Aliyu<sup>3</sup>, Shuaibu M. Shittu<sup>4</sup>, Stephen G. Gana<sup>2</sup>, Aliu Suraj<sup>1</sup>, Emmanuel Idokoko<sup>1</sup>, Cosmas Okeke<sup>1</sup>, Lambert Iji<sup>1</sup>, Jimoh A. Audu<sup>1</sup>**

<sup>1</sup>Department of Surgery, Ahmadu Bello University Teaching Hospital, Zaria, <sup>2</sup>Department of Surgery, Ahmadu Bello University and Ahmadu Bello University Teaching Hospital, Zaria, <sup>3</sup>Pathology Department, Ahmadu Bello University and Ahmadu Bello University Teaching Hospital, Zaria, <sup>4</sup>Department of Pathology, Ahmadu Bello University Teaching Hospital, Zaria, Nigeria

**Received:** 31-Mar-2022

**Accepted:** 19-Apr-2022

**Published:** 23-Aug-2022

#### Address for correspondence:

Dr. Stanley Emeka Nwabuoku, Department of Surgery, Ahmadu Bello University Teaching Hospital, Zaria, Kaduna State, Nigeria. E-mail: emyonyeabor@gmail.com

#### Access this article online

##### Website:

www.jwacs-jcoac.com

DOI: 10.4103/jwas.jwas\_82\_22

##### Quick Response Code:



**How to cite this article:** Nwabuoku SE, Mukoro GD, Daniyan M, Dauda MM, Khalid L, Aliyu HO, et al. Appendiceal schistosomiasis presenting as an appendiceal mass. J West Afr Coll Surg 2022;12:100-3.

This is an open access journal, and articles are distributed under the terms of the Creative Commons Attribution-NonCommercial-ShareAlike 4.0 License, which allows others to remix, tweak, and build upon the work non-commercially, as long as appropriate credit is given and the new creations are licensed under the identical terms.

For reprints contact: reprints@medknow.com

intravenous ceftriaxone and metronidazole as well as analgesics. Forty-eight hours later, his vital signs had normalized and the mass had regressed. He was discharged on oral antibiotics after 6 days on admission. He consented to have interval appendicectomy 3 months later which was done under general anesthesia through a Lanz incision. Intraoperative findings were: a 12 cm long inflamed retrocecal appendix with fibrotic adhesions of the greater omentum to the tip of appendix. The caecum, ileum and colon were grossly normal. There was no fluid collection. He was discharged 2 days after surgery in clinically satisfactory condition on oral antibiotics, analgesics and vitamin C.

Histology of the appendix showed transmural chronic fibrotic granulomatous inflammation around dead and viable schistosoma ova of both *Schistosoma mansoni* and *Schistosoma haematobium* [Figures 1 and 2]. He had stool microscopy done which did not show schistosoma ova. He was then treated with praziquantel 600 mg three times per day for 1 day. At follow-up clinic visit he had a 6 cm healed scar with good integrity and had no new complaints. Post-therapy stool microscopy was done and also showed no evidence of schistosoma ova.

## Discussion

This case report has shown that schistosomal appendicitis is one of the causes of recurrent acute appendicitis. Even though it can cause acute appendicitis, the diagnosis can only be reliably confirmed after a histologic examination of the resected appendix.<sup>[1,14,15]</sup> Two types and pathogenic pathways of schistosomal appendicitis have been described. “Granulomatous acute appendicitis” is caused by an immunological granulomatous reaction to newly deposited ova, with tissue necrosis and eosinophilia occurring early in the infection, usually within days to weeks.<sup>[1,14,15]</sup> On the other hand “obstructive acute appendicitis” is caused by long-standing inflammation and fibrosis around dead schistosoma eggs, leading to obstruction of the appendiceal lumen, increasing the risk of infection from faecal contaminants and occurring in the late phase of schistosomiasis, usually after several months or years.<sup>[1,14,15]</sup>

There have been previous reports of schistosomal appendicitis in patients in Nigeria and other parts of tropical Africa.<sup>[2,5-7,10,16,17]</sup> Most of these have shown a higher prevalence in males compared to females with most of the cases presenting in young

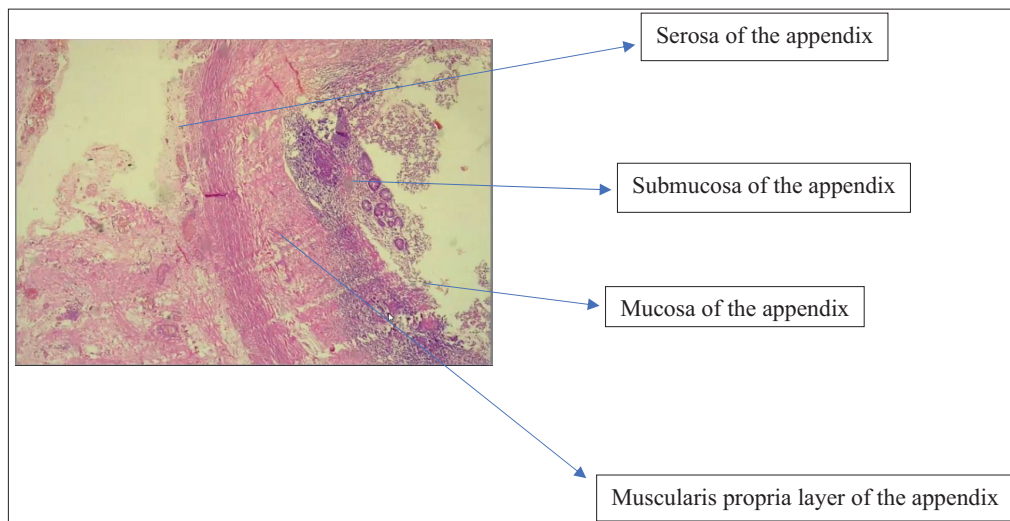


Figure 1: Photomicrograph of the histology slides for the index patient showing the various layers of the appendix

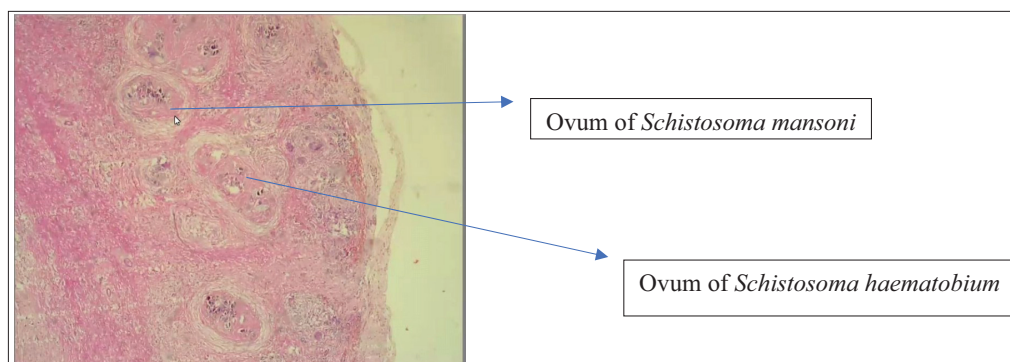


Figure 2: Photomicrograph of the histology slides for the index patient with annotations showing the ova of *S. haematobium* and *S. mansoni*

adults in their 3<sup>rd</sup> decade of life as was seen in the patient in this case report.

Saad *et al*<sup>[7]</sup> reported 30 cases of schistosomal appendicitis in Zaria, Kaduna State in Northwestern Nigeria over an 11-year period with a male:female ratio of 6.5:1 and peak incidence in the 20–29 years age group. Abdominal pain, fever and vomiting were the most common symptoms among these patients, similar to this case.

Adisa *et al*<sup>[6]</sup> reported 22 cases of schistosomal appendicitis in Ile-Ife, Osun State in Southwestern Nigeria over a 17-year period with a male:female ratio of 4.5:1 and a mean age of 28.2±5.6 years. All the patients received anti-schistosomal drugs and one patient developed adhesive intestinal obstruction 9 months after surgery.

Zacarias *et al*<sup>[5]</sup> reported a 13.1% prevalence of schistosomal-related appendicitis in Khartoum, Sudan with mean age of patients of 29.1 years, and 73.7% of these patients being male. Imamura *et al*<sup>[3]</sup> reported an incidence rate of 0.32% of appendiceal schistosomiasis in Japan.

It has been noted that schistosomal appendicitis is not common, even in endemic regions. Duvie *et al*<sup>[10]</sup> reported an incidence of 6.2% in Nigeria, where schistosomiasis is endemic. Sanusi *et al*<sup>[2]</sup> reported an incidence of 3.2% from studies in Kano State in Northwestern Nigeria while studies in other parts of Nigeria have noted rates ranging from 2.3% to 4.2%.<sup>[6,7,10,16]</sup> The incidence is much lower in non-endemic regions with some studies noting an incidence rate as low as 0.001% in non-endemic regions and these were related to individuals involved in traveling or labour migration from endemic regions to non-endemic areas.<sup>[1,8,18,19]</sup>

The current diagnostic methods for the diagnosis of schistosomiasis and schistosome acute appendicitis include the use of microbiologic tests like stool or urine microscopy, haematological tests like complete blood count, pathological studies like PCR, ELISA, indirect haemagglutination or immunofluorescence assays and anti-schistosomal antibodies as well as special imaging modalities like contrast or non-contrast abdominal CT scan and histologic examination of rectal or bladder biopsy specimens.<sup>[6,7,20-22]</sup> The response of the index case to initial non-operative management suggests that schistosomal appendicitis masses respond to initial non-operative management providing opportunity for interval appendectomy at a later date.

This patient responded well to anti-schistosomal medication which was given following histological diagnosis with no adverse event in the immediate follow-up period. All the patients in the previous reports from Nigeria also had anti-schistosomal medications but one patient developed adhesive intestinal obstruction 9 months after surgery among the cases reported by Adisa *et al*<sup>[6]</sup> buttressing the need for follow-up after treatment (surgical and/or medical) for schistosomal appendicitis.

## Conclusion

Schistosomiasis can cause appendicitis which could present as simple appendicitis or with complications such as appendiceal mass. Post-operatively, the definitive diagnosis is made following histologic examination of the excised appendix. Appendectomy with post-operative anti-schistosomal medications are usually adequate treatment and may prevent further complications in majority of the patients.

## Financial support and sponsorship

Nil.

## Conflicts of interest

The authors declare no conflict of interests.

## References

1. Malallah H, Al-Onaizi T, Shuaib A, Alsharaf K, Behbehani A. Schistosomiasis as a Cause of Acute Appendicitis in Non-Endemic Areas. *Trop Med Surg* 2017;5:216-7.
2. Sanusi HM, Bello U. Histopathological analysis of schistosomal appendicitis in Kano North-Western Nigeria. *Indian J Pathol Oncol* 2021;8:267-70.
3. Imamura H, Haraguchi M, Isagawa Y, Morita M, Hirabaru M, Kawahara D, *et al.* Acute appendicitis associated with the presence of schistosome eggs in a sailor: A case report. *Surg Case Rep* 2019;5:55.
4. Doudier B, Parola P, Dales JP, Linzberger N, Brouqui P, Delmont J. Schistosomiasis as an unusual cause of appendicitis. *Clin Microbiol Infect* 2004;10:89-91.
5. Zacarias M, Pizzol D, de Miranda H, Colangelo AC, Veronese N, Smith L. Schistosomal appendicitis: Case series and systematic literature review. *PLoS Negl Trop Dis* 2021;15:e0009478.
6. Adisa AO, Omonisi AE, Osasan SA, Alatisie OI. Clinicopathological review of schistosomal appendicitis in south western nigeria. *Trop Gastroenterol* 2009;30:230-2.
7. Ahmed SA, Mohammed U, Sanda RB, Makama J, Shehu MS, Ameh EA, *et al.* Schistosomiasis of the appendix in a tertiary hospital in northern nigeria: A 22-year review. *J Lab Physicians* 2014;6:18-21.
8. Gundlapali V, Shah M, Basakara A, Fobia J. Atypical appendicitis: Schistosomal infection causing perforated appendicitis. *Int J Surg* 2012;28:42-5.
9. Gryseels B, Polman K, Clerinx J, Kestens L. Human schistosomiasis. *Lancet* 2006;368:1106-18.
10. Duvie SO, Diffang C, Guirguis MN. The effects of schistosome haematobium infestation on the vermiform appendix: The nigerian experience. *J Trop Med Hyg* 1987;90:13-8.
11. Turner SA. Bilharziasis of the appendix. *Trans Med J* 1909;5: 210-2.
12. Vos T, Flaxman AD, Naghavi M, Lozano R, Michaud C, Ezzati M, *et al.* Years lived with disability (ylds) for 1160 sequelae of 289 diseases and injuries 1990-2010: A systematic analysis for the global burden of disease study 2010. *Lancet* 2012;380:2163-96.
13. Augusto G, Nalá R, Casmo V, Sabonete A, Mapaco L, Monteiro J. Geographic distribution and prevalence of schistosomiasis and soil-transmitted helminths among schoolchildren in mozambique. *Am J Trop Med Hyg* 2009;81:799-803.
14. Callisto M, Hisham H. Schistosomiasis of the appendix. *J R Soc Med* 2006;99:473-4.

15. Weber G, Borer A, Zirkin HJ, Riesenber K, Alkan M. Schistosomiasis presenting as acute appendicitis in a traveler. *J Travel Med* 1998;5:147-8.
16. Gali BM, Nggada HA, Eni EU. Schistosomiasis of the appendix in maiduguri. *Trop Doct* 2006;36:162-3.
17. Der EM, Quayson SE, Mensah JE, Tetty Y. Tissue Schistosomiasis in Acca Ghana: A retrospective histopathologic review at the Korle-Biu teaching hospital (2004–2011). *Path Discov* 2004;3:1-6.
18. Nandipati K, Parithivel V, Niazi M. Schistosomiasis: A rare cause of acute appendicitis in the african american population in the united states. *Am Surg* 2008;74:221-3.
19. Carballo M, Divino JJ, Zeric D. Migration and health in the european union. *Trop Med Int Health* 1998;3:936-44.
20. Valluru B, Zhou Z, Sah D, Du W, Ali MO, Adam AA, *et al.* Analysis of Ct characteristics in the diagnosis of schistosoma japonicum associated appendicitis with clinical and pathological correlation: A diagnostic accuracy study. *JPN J Radiol* 2020;38:178-91.
21. Gray DJ, Ross AG, Li YS, McManus DP. Diagnosis and management of schistosomiasis. *BMJ* 2011;342:d2651.
22. Sayasone S, Utzinger J, Akkhavong K, Odermatt P. Repeated stool sampling and use of multiple techniques enhance the sensitivity of helminth diagnosis: A cross-sectional survey in southern lao people's democratic republic. *Acta Trop* 2015;141:315-21.