


Type A aortic syndromes in COVID-19 positive patients: Case series from a UK multicentre study

Ana Lopez-Marco PhD¹  | Amer Harky MRCS, MSc²  | Pietro G. Malvindi PhD³ | Danilo Verdichizzo MD⁴ | Iain McPherson MD⁵  | Marius Roman MD⁶ | Aug Oo MD¹ | Sunil Ohri MD³

¹Departments of Cardiothoracic Surgery, St Bartholomew's Hospital, London, UK

²Departments of Cardiothoracic Surgery, Liverpool Heart and Chest Hospital, Liverpool, UK

³Departments of Cardiothoracic Surgery, University Hospital Southampton, Southampton, UK

⁴Departments of Cardiothoracic Surgery, John Radcliffe Hospital, Oxford, UK

⁵Departments of Cardiothoracic Surgery, Freeman Hospital, Newcastle, UK

⁶Departments of Cardiothoracic Surgery, Glenfield Hospital, Leicester, UK

Correspondence

Ana Lopez-Marco, PhD, St Bartholomew's Hospital, West Smithfield, London EC1A 7BE, UK.

Email: ana.lopez-marco@nhs.net

Abstract

Objective: The coronavirus disease (COVID-19) increases the respiratory complications and carries a higher mortality in the immediate postoperative period. The aim of this study was to analyze the outcomes of patients with type A acute aortic syndromes (AAS) diagnosed with COVID-19 in the perioperative period.

Methods: Retrospective analysis of prospectively collected data between March and August 2020 from 20 participating cardiac surgery centers in the United Kingdom.

Results: Among 122 patients who underwent emergency surgical repair for type A AAS at the participating centers, 3 patients (2.5%) tested positive for COVID-19 in the preoperative screening, and 4 cases turned to be positive in the postoperative period having been operated on an unknown COVID-19 status. Another patient was diagnosed of COVID-19 disease based on radiological features. These eight patients had increased postoperative complications, including respiratory failure, longer ventilation times, and Intensive Therapy Unit (ITU) stay and increased mortality when compared with COVID-19 negative patients.

Conclusion: COVID-19 disease in the perioperative period of type A AAS poses a challenge. Despite the increasing morbidity and mortality associated with the virus, the prognosis of the aortic disease is poorer and emergency surgery should not be contraindicated based on the COVID-19 diagnosis alone.

KEYWORDS

aorta, aortic disease, COVID-19, coronavirus, dissection

1 | INTRODUCTION

Severe acute respiratory syndrome coronavirus 2 (SARS-CoV-2), the virus that causes COVID-19, was first described as a cluster of cases of pneumonia in Wuhan (China) on the December 31, 2019. The number of cases exponentially increased and spread rapidly to other geographical locations, reaching the global pandemic status on the March 11, 2020.

Diagnosis of COVID-19 is based on detection of the ribonucleic acid (RNA) of the virus via reverse polymerase chain reaction (PCR) analysis on nasopharyngeal swabs and/or tracheal aspirates. These tests can detect the virus within days of infection, even before the subject becomes symptomatic, and the results are available between 4 and 72 h.

Acute aortic syndromes (AAS) represent a surgical emergency, with devastating natural history carrying high mortality (1%–2%

each hour) if not treated immediately.^{1,2} Hence, when a COVID-19 screening fast test is not available, emergency aortic surgery with universal personal protective equipment (PPE) precautions is advised, as the risk of aortic rupture and death outweighs the risk of COVID-19 in the postoperative period.³

When there is a confirmed COVID-19 result preoperatively, one has to balance the risks of the two diseases. Our approach has been to offer emergency aortic surgery to those individuals who despite a positive COVID-19 test, do not present any symptoms of the disease (i.e., fever and respiratory insufficiency) and pass a “fitness for surgery” assessment.³

The aim of this study was to analyze early outcomes of COVID-19 positive patients with acute type A AAS who had undergone emergency surgery for aortic repair.

2 | METHODS

Retrospective analysis of prospectively collected data from a multi-centre study with 20 participating aortic centers from the UK (66% of the aortic units in the country, including the largest specialized aortic centers and covering most of the geographical areas), designed to assess the impact of the COVID-19 pandemic in the delivery of services for aortovascular disease in the UK between March and August 2020.

The other 14 aortic units declined to participate in the study for different reasons including inability to provide emergency surgery cover during the COVID-19, insufficient resources to collect the data and/or individual preferences.

In this substudy, we concentrate in patients who were admitted to specialized aortic units with the diagnosis of acute type A AAS: either aortic dissection (AD), intramural hematoma (IMH) or penetrating aortic ulcer (PAU) and tested positive for COVID-19 in the PCR-RNA analysis or had lung parenchyma changes suggestive of COVID-19 disease in the non-contrast CT scan during the preoperative period.

Patients who were turned down for surgery or those presenting with other diagnosis, including type B AAS, were excluded from this substudy.

We report demographics and clinical outcomes, including respiratory complications, length of intensive care (Intensive Therapy Unit [ITU]) stay, and mortality.

3 | RESULTS

Between March and August 2020, 122 patients were admitted with a diagnosis of type A AAS and offered emergency surgical repair at the participating centers.

The preoperative COVID-19 screening protocol consisted of two consecutive nasopharyngeal swabs for PCR-RNA analysis and a noncontrast CT chest to assess changes in the lung parenchyma.³

Thirty-three patients (27%) had a confirmed negative test before the start of the surgical procedure, while in 3 patients (2.5%), the test resulted positive for COVID-19. The majority of the patients (70.5%, $n = 86$) were operated on an unknown COVID-19 status which ultimately turned to be positive in four cases (Table 1).

The analysis of the noncontrast windows of the preoperative CT chest revealed changes in the lung parenchyma suggestive of COVID-19 disease (i.e., acute diffuse ground glass opacities) in only two patients (1.6%). One of these patients was referred with a negative COVID-19 test but tested positive after surgery (Table 1).

3.1 | Patients with a positive PCR-RNA result for COVID-19 in a preoperative nasopharyngeal swab

Three patients were diagnosed of COVID-19 infection in the preoperative period—either in the referring center or with a rapid test on admission on the aortic center.

They were all young fit females (mean age: 52.7 years, 52–53), with no significant comorbidities apart from hypertension and smoking

TABLE 1 Demographics, aortovascular diagnosis, and details of the preoperative screening for COVID-19

Patient	Sex	Age	Diagnosis	Preoperative status-PCR-RNA analysis	Preoperative signs of lung disease on CT	Surgery	Euro-Score II
1	M	55	Acute AD DeBakey I	Unknown	Yes	Root, ascending and arch	6.04
2	M	54	Acute AD DeBakey I	Unknown	No	Root, ascending and hemiarch	10.83
3	M	67	Acute AD DeBakey II	Unknown	No	Ascending and hemiarch	5.34
4	M	58	Acute AD DeBakey I	Unknown	No	Ascending and hemiarch	3.65
5	F	53	Acute IMH DeBakey I	Positive	No	Ascending and hemiarch	7.19
6	M	82	Acute IMH DeBakey III	Negative	Yes	Ascending, arch and frozen elephant trunk	13.00
7	F	54	Acute IMH DeBakey I	Positive	No	Ascending, arch and frozen elephant trunk	11.79
8	F	53	Acute AD DeBakey I	Positive	No	Ascending and hemiarch	4.04

Abbreviations: AD, aortic dissection; CT, computed tomography; F, female; IMH, intramural hematoma; M, male.

TABLE 2 Postoperative respiratory complications, length of stay, and status at discharge for the corresponding patients listed in Table 1

Patient	Reintubation	Tracheostomy	Mechanical ventilation times (hours)	Length of ITU admission (days)	Total length of postoperative stay (days)	Postoperative status - PCR-RNA analysis	Outcome	Cause of death
1	Yes	Yes	960	45	45	Positive	Alive	N/A
2	No	No	18	3	15	Positive	Alive	N/A
3	No	No	24	3	9	Positive	Alive	N/A
4	No	No	114	4	4	Positive	Died	Neurological
5	Yes	Yes	72	23	28	Positive	Alive	
6	Yes	No	720	21	21	Negative	Died	Respiratory failure
7	No	No	20	2	9	Positive	Alive	N/A
8	No	No	16	3	15	Negative	Alive	N/A

Abbreviations: ITU, Intensive Therapy Unit; N/A, non-applicable; PCR-RNA, polymerase chain reaction–ribonucleic acid.

habitus. Diagnosis was: type A IMH ($n = 2$) and type A AD ($n = 1$), all of them extending from the aortic root to the iliacs. One patient had Turner Syndrome and had a known root aneurysm (65 mm) and another patient had a known bicuspid aortic valve (Table 1).

All three received emergency surgery without any delays. Only one patient required reintubation and tracheostomy due to progressive respiratory failure (Table 2).

3.2 | Patients with radiological appearances of COVID-19 lung disease in the preoperative CT scan

Two patients had significant radiological changes in the noncontrast lung fields on the presenting CT chest compatible with COVID-19 disease, and both developed severe respiratory complications in the immediate postoperative period (Figure 1).

The first patient, a 55-year-old male with hypertension, current smoking history and a prior myocardial infarct, presented with an acute type A AD. He underwent emergency surgery (aortic root, ascending aorta, and arch replacement) without waiting for the COVID-19 test but turned out to be positive in the postoperative period. Shortly after extubation, he was reintubated due to progressive respiratory failure and subsequently required a tracheostomy for weaning. He was transferred to another acute hospital after 45 days. (Tables 1 and 2).

The second patient, a fit and well 82-year-old male with hypertension, presented with an acute type A IMH in the aortic arch and proximal descending thoracic aorta while exercising. He was initially managed conservatively with blood pressure control and close radiological surveillance. He had at least three negative PCR-RNA swab results. His aorta expanded rapidly showing signs of impending rupture, hence emergency surgery was performed (aortic arch replacement and frozen elephant trunk repair). He required reintubation shortly after initial extubation due to progressive respiratory failure. He could not be weaned and died of respiratory failure 21 days after the operation (Tables 1 and 2).

3.3 | Patients with positive PCR-RNA result for COVID-19 in a postoperative nasopharyngeal swab

Another three patients were offered emergency surgery on an unknown COVID-19 status as the screening results were not awaited outweighing the risk of aortic complications, but the results were positive in the immediate postoperative period. We can probably assume that these patients would have already tested positive preoperatively, but have not developed active pulmonary disease.

In this group, all patients were young males (mean age: 59.7 year, 54–67), with no relevant medical history other than hypertension. All three presented with a type A AD in nondilated aortas. Emergency surgery (ascending aorta and hemiarch replacement) was offered without delays (Table 1).

There were no respiratory complications in this group, but one of the patients died of neurological complications (Table 2).

In our series, those who underwent AAS repair being COVID-19 positive or with signs of acute lung disease, had a higher incidence of respiratory complications, compared with those who were COVID-19 negative.

We report 37.5% reintubation rate and 25% of tracheostomy in our COVID-19 patients when compared with those COVID-19 negative (7.5% reintubation, 10% tracheostomy).

Mean mechanical ventilation times in COVID-19 positive patients was 243 h compared with 54.2 h for negative patients. Length of ITU stay was increased by and average of 8 days in COVID-19 patients (14.4 vs. 5.6 days) (Table 3).

4 | DISCUSSION

The pathogenesis of COVID-19 is complex and includes activation of the systemic inflammation cascade and prothrombotic effects that manifest as heterogenous organ damage and a highly variable clinical course.^{4,5} Cardiac surgery, with the use of extracorporeal circulation, causes similar

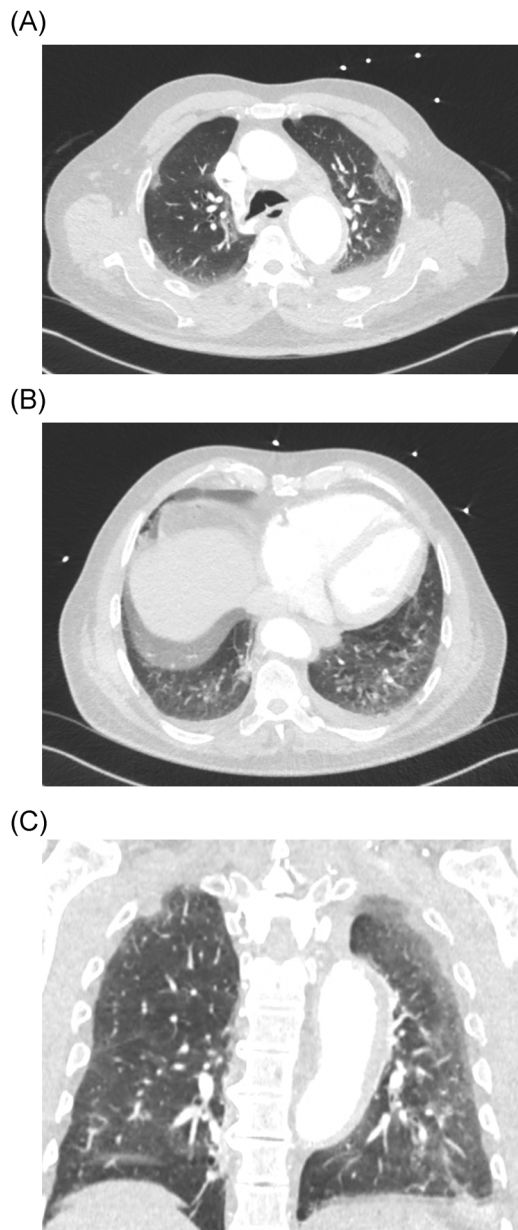


FIGURE 1 Noncontrasted CT chest—lung windows—in mid-apical (A), lower base apical (B) and coronal views (C), evidencing the presence of acute diffuse ground-glass opacities, compatible with COVID-19 pneumonitis. CT, computed tomography

alterations, which may act synergistically with COVID-19 disease and increase the occurrence of postoperative complications as result of an excessive systemic inflammatory reaction and alterations of the coagulation system. Not surprisingly, the initial experiences in COVID-19 positive patients undergoing cardiac surgery reported high mortality and morbidity.^{6–8}

With only a few reports available in the literature,^{9–12} there is limited evidence to drive valid conclusions about prognosis and outcomes for patients with AAS and COVID-19 disease, and to establish clear recommendations for their management.

However, even from these limited number of reports, delayed postoperative respiratory failure requiring reintubation and

TABLE 3 Respiratory postoperative complications, mortality, and length of stay in Intensive Therapy Unit (ITU) for patients operated of acute type A AAS with and without COVID-19 disease in the perioperative period

	COVID-19 positive	COVID-19 negative
Reintubation	3 (37.5%)	9 (7.5%)
Tracheostomy	2 (25%)	12 (10%)
Mortality	2 (25%)	15 (12.5%)
Mechanical ventilation time (hours)	243 (16–960)	54.2 (1–1272)
Length of ITU stay (days)	18.2 (4–45)	5.6 (2–53)

Abbreviation: AAS, acute aortic syndrome.

tracheostomy seems to be a frequent complication in the immediate postoperative period. In addition, complications derived from an altered coagulation system—either excessive bleeding or prothrombotic effect—have also been described.^{9–12}

The majority of PCR-RNA analysis tests used in the different participating centers during the early months of the pandemic required 24–72 h to generate a result. Hence, in the majority of the cases, these preoperative results were not awaited, as the risks of mortality associated with the type A AD outweighed the risk of COVID-19 disease in the postoperative period. These patients were treated as COVID-19 positive and universal PPE measures were taken during the perioperative period (anesthetic induction, surgical procedure, and postoperative care) until a negative result was confirmed.³

Currently, some of the participating centers are using rapid PCR-RNA analysis tests, that can provide a reliable result in approximately 4 h. However, we strongly advocate not to delay emergency surgery while waiting for a COVID-19 test result.

Even a confirmed positive test should be analyzed carefully, as it may represent an active infection or an infection that has resolved but the individual is still excreting virus particles detected by the PCR test.

It remains unclear whether preoperative lung parenchymal changes suggest a worse postoperative respiratory outcome. COVID-19 causes a variety of changes in the lung parenchyma, from acute interstitial infiltrates to chronic pulmonary fibrosis. In our experience, those who underwent emergency AAS surgery with acute interstitial infiltrates had the worse respiratory outcomes, but whether the AAS and CPB played a role in exacerbating the ARDS postoperatively is unclear.

Based on the assumption that COVID-19 status may play a significant role in exacerbating the expected complications after major aortic surgery, it is paramount to assess the patients' physiological reserve before the operation,¹² with the expectation of deranged hematological and inflammatory responses,^{9,12} as well as potential respiratory complications.^{10,11}

The consensus from the participating centers, was that young and fit patients, (e.g., below 70 years) should undergo emergency type A AAS repair as the risk posed by the AAS largely exceeds the risk of COVID-19 complications and mortality.^{1–3} However, with the increased availability of the rapid PCR test, delays in decision-making and offering emergency surgery can be overcome.

The decision to operate in elderly patients should be made on an individual basis, balancing the existence of other comorbidities with COVID status and existing complications if any. We did not turn down for surgery any patients with AAS based on COVID-19 status alone.¹³ Furthermore, the resources needed in the immediate post-operative period for these complicated cases (multiple organ support, ITU resources) in the midst of a pandemic with its shortages, have also to be considered.

Surgical mortality in these group of patients is higher than for those without COVID-19 (25% vs. 12% in our series), but still better than the alternative with conservative treatment.^{1,2}

There are several limitations associated with our study, including the small sample size in this subcohort of patients and the variation in practice among the participating centers.

5 | CONCLUSIONS

Diagnosis of COVID-19 disease in the perioperative period of type A AAS poses a challenge to the management of these patients. Despite the increasing morbidity and mortality associated with the virus, the prognosis of the aortic disease is poorer and emergency surgery should not be contraindicated based on the COVID-19 diagnosis alone.

ACKNOWLEDGEMENTS

S. Bhudia, U. Rosendahl, B. Rosser (Royal Brompton and Harefield NHS Trust), Y. Abdullahi, J. Anderson, (Hammersmith Hospital), L. Holland, J. Jessup, J. Hyde (Royal Sussex County Hospital, Brighton), E. Hope, G. Tsang (University Hospital Southampton), G. Krasopoulos (John Radcliffe Hospital, Oxford), G. Mariscalco (Glenfield Hospital, Leicester), V. Dronavalli, J. Mascaro (Queen Elizabeth Hospital, Birmingham), U. Dandekar, A. Brazier (University Hospital Coventry), S. Mohamed, D. Blessom, L. Balacumaraswani (Royal Stoke University Hospital), M. Kuduvali, M. Field (Liverpool Heart and Chest Hospital), S. Qadri, A. Finch, M. Bittar (Blackpool Victoria Hospital), S. Forlani, R. Greco, G. Chetty, S. Sadeque (Sheffield Teaching Hospital), Y. Haqzad, A. Cale (Castle Hill Hospital), K. Booth (Freeman Hospital, Newcastle), T. Smiles, M. Kanani (James Cook University Hospital, Middlesbrough), G. Gradinariu, H. El-Shafei (Aberdeen Royal Infirmary), K. Lim (Edinburgh Royal Infirmary), S. Jahangeer, H. Bilal (Manchester Royal Infirmary) and A. Gregg, R. Kelly, R. Jeganathan (Royal Victoria Hospital, Belfast).

CONFLICT OF INTERESTS

The authors declare that there are no conflict of interests.

ETHICS STATEMENT

None obtained as no patient identifiable information has been shared.

ORCID

Ana Lopez-Marco  <http://orcid.org/0000-0001-9330-3948>

Amer Harky  <http://orcid.org/0000-0001-5507-5841>

Iain McPherson  <http://orcid.org/0000-0002-2268-615X>

REFERENCES

1. Tsai TT, Nienaber CA, Eagle KA. Acute aortic syndromes. *Circulation*. 2005;112:3802-3813.
2. Erbel R, Aboyans V, Boileau C, et al. 2014 ESC Guidelines on the diagnosis and treatment of aortic diseases: document covering acute and chronic aortic diseases of the thoracic and abdominal aorta of the adult. The Task Force for the Diagnosis and Treatment of Aortic Diseases of the European Society of Cardiology (ESC). *Eur Heart J*. 2014;35:2873-2926.
3. Lopez-Marco A, Rosser B, Harky A, Verdichizzo D, et al. The fate of patients with acute aortic syndromes during the coronavirus (COVID-19) pandemic: a UK multicenter study. *JTCVS Open*. 2020. <https://doi.org/10.1016/j.xjon.2020.11.008>
4. Domingo P, Mur I, Pomar V, Corominas H, Casademont J, De Benito N. The four horsemen of a viral Apocalypse: the pathogenesis of SARS-CoV-2 infection (COVID-19). *EBioMedicine*. 2020; 58:102887.
5. Guan WJ, Ni ZY, Hu Y, et al. Clinical characteristics of coronavirus disease 2019 in China. *N Engl J Med*. 2020;382(18):1708-1720.
6. Yates MT, Balmforth D, Lopez-Marco A, Uppal R, Oo AY. Outcomes of patients diagnosed with COVID-19 in the postoperative period following cardiac surgery. *Interact Cardiovasc Thorac Surg*. 2020;31: 1-3.
7. Fattouch K, Corrao S, Augugliaro E, et al. Cardiac surgery outcomes in patients with coronavirus disease 2019 (COVID-19): a case-series report. *J Thorac Cardiovasc Surg*. 2020;S0022-5223(20): 32872-32875.
8. Barkhordari K, Khajavi MR, Bagheri J, et al. Early respiratory outcomes following cardiac surgery in patients with COVID-19. *J Card Surg*. 2020;35(10):2479-2485. <https://doi.org/10.1111/jocs.14915>
9. Akgul A, Turkyilmaz S, Turkyilmaz G, Toz H. Acute aortic dissection surgery in a patient with COVID-19. *Ann Thorac Surg*. 2021;111(1): e1-e3.
10. Mori M, Geirsson A, Vallabhajosyula P, Assi R. Surgical management of thoracic aortic emergency with pre- and postoperative COVID-19 disease. *J Card Surg*. 2020; 35(10):2832-2834.
11. Martens T, Vande Weygaerde Y, Vermassen J, Malfait T. Acute type A aortic dissection complicated by COVID-19 infection. *Ann Thorac Surg*. 2020; 110(5):e421-e423.
12. Fukuhara S, Tang H, Kim KM, et al. Type A aortic dissection during COVID-19 pandemic: report from tertiary aortic centers in the United States and China. *Semin Thorac Cardiovasc Surg*. 2020;S1043-0679(20):30382-30388.
13. Roman M, Harky A, Brazier A, et al. Turn down of acute aortic syndrome cases during COVID-19: results from UK multicentre studies. *J Card Surg*. 2020;36:1-4.

How to cite this article: Lopez-Marco A, Harky A, Malvindi PG, et al. Type A aortic syndromes in COVID-19 positive patients: Case series from a UK multicentre study. *J Card Surg*. 2021;36: 2692-2696. <https://doi.org/10.1111/jocs.15625>