



Contents lists available at ScienceDirect

International Journal of Surgery Case Reports

journal homepage: www.casereports.com

Diagnostic pitfall: Adenoid cystic carcinoma of the tongue presenting as an isolated hypoglossal nerve palsy, case report and literature review



Wee Hide Elfrida^a, Rafay Azhar^b, Tang Po Yin^b, Teo Tze Hern^c,
Narayanan Gopalakrishna Iyer^a, Tan Hiang Khoon^a, Tan Ngian Chye^{a,*}

^a Department of Surgical Oncology, National Cancer Centre Singapore, 11 Hospital Drive, Singapore 169610

^b Singapore General Hospital, Outram Rd, Singapore 169608

^c Division of Oncologic Imaging, National Cancer Center Singapore, 11 Hospital Drive, Singapore 169610

ARTICLE INFO

Article history:

Received 10 March 2016

Received in revised form 31 May 2016

Accepted 31 May 2016

Available online 4 June 2016

Keywords:

Adenoid cystic carcinoma

Head and neck cancer

Hypoglossal

Isolated twelfth nerve palsy tongue

Lower motor neuron disease

Case report

ABSTRACT

INTRODUCTION: We describe a patient with an unusual presentation of an isolated hypoglossal nerve palsy as a result of perineural invasion (PI) from adenoid cystic carcinoma (ACC). We will also discuss the diagnostic pitfalls as well as present a short literature review of adenoid cystic carcinomas and suggest improvement to the current diagnostic algorithm for isolated hypoglossal nerve palsies.

PRESENTATION OF CASE: A 63 year old Malay female presented with progressive dysphagia and slurred speech for one year. Physical examination showed unilateral right tongue wasting, fasciculation and deviation to the right. An MRI showed atrophy of the tongue due to denervation and subsequently she was treated in a neurology clinic for 8 months.

Due to lack of improvement, she was referred to our surgical unit and underwent examination under anaesthesia (EUA) and biopsy. Histology showed adenoid cystic carcinoma with perineural involvement, resulting in lower motor neuron signs.

She underwent radiotherapy to the base of her tongue (70 Gy/35#). A PET-CT one month post treatment showed complete response.

DISCUSSION: Adenoid cystic carcinoma (ACC) is a salivary gland neoplasm. It is characterized by local invasiveness with frequent recurrence and indolent growth. It affects major salivary glands more than minor salivary glands.

In malignancies that have a propensity for PI such as ACC, patients may present atypically with nerve palsies. In infiltrative lesions, the primary tumour may not be evident on magnetic resonance imaging. Therefore, to achieve a diagnosis, a high index of suspicion is required. When the diagnosis is in question, deep biopsy and positron emission tomography may be useful.

© 2016 The Authors. Published by Elsevier Ltd on behalf of IJS Publishing Group Ltd. This is an open access article under the CC BY-NC-ND license (<http://creativecommons.org/licenses/by-nc-nd/4.0/>).

1. Introduction

ACC is a malignant neoplasm originating in both major and minor salivary glands. It is diffusely infiltrative and has the propensity for PI and hence cause nerve palsies. This can lead to a

diagnostic pitfall and therapeutic delay when the patient presents atypically as with this case report.

2. Case report

A 63 year old Malay lady with a family history of breast, lung and haematological malignancies presented to neurology with progressive dysphagia and slurred speech of one year duration. She had oropharyngeal dysphagia which was worse with solids.

Physical examination showed an isolated hypoglossal nerve palsy with unilateral right tongue wasting, fasciculation and deviation to the right (*Image 1*).

A brain MRI was done on suspicion of a stroke and showed mild increase in fat in the right half of the tongue with mild TIRM hyper intensity and enhancement suggestive of atrophy of the right half of the tongue due to denervation. (*Image 2*)

Abbreviations: PI, Perineural invasion; ACC, Adenoid cystic carcinoma; EUA, Examination under anaesthesia; PET-CT, Positron emission tomography-computed tomography; FDG, Fludeoxyglucose.

* Corresponding author.

E-mail addresses: Hide.wee@mohh.com.sg (H.E. Wee), rafay.azhar@singhealth.com.sg (R. Azhar), poyin.tang@mohh.com.sg (P.Y. Tang), patrick.teo.t.h@singhealth.com.sg (T.H. Teo), gopaliyer@nccs.com.sg (N.G. Iyer), tan.hiang.khoon@singhealth.com.sg (H.K. Tan), tan.ngian.chye@nccs.com.sg (N.C. Tan).

<http://dx.doi.org/10.1016/j.ijscr.2016.05.060>

2210-2612/© 2016 The Authors. Published by Elsevier Ltd on behalf of IJS Publishing Group Ltd. This is an open access article under the CC BY-NC-ND license (<http://creativecommons.org/licenses/by-nc-nd/4.0/>).

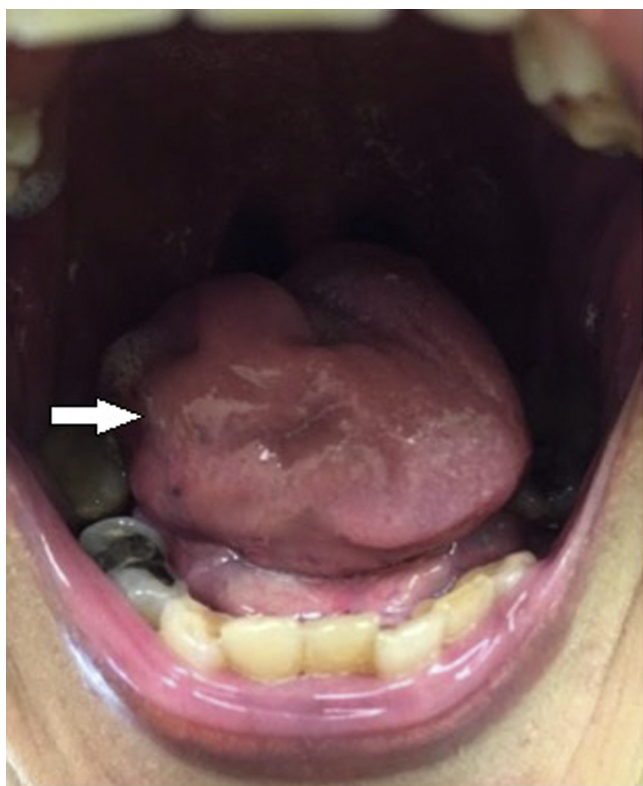


Image 1. Unilateral wasting of right hemi tongue.

She was started on Gabapentin without improvement.

In view of worsening speech she was referred to our department where she underwent examination under anaesthesia (EUA) and was found to have a 1.5 cm induration at the tongue base with overlying mucosal ulceration.

Positron emission tomography-computed tomography (PET-CT) showed a Fludeoxyglucose (FDG) avid nodule at the right vallecula and tongue base abutting the hyoid. (*Image 4*)

A base of tongue biopsy was performed and histology showed non keratinizing stratified squamous epithelium with sub epithelial infiltrate of malignant cells composed of bilayer glands and nests of cells in a mixed tubular, cribriform and focal solid (< 30%) architecture.

Perineural involvement was seen. Immunohistochemical staining confirmed a dual population of the malignant cells with CD117 positivity in the luminal cells and p40 positivity in the myoepithe-

lial layer. (*Image 3*) The diagnosis of Adenoid Cystic Carcinoma (ACC) was made. Due to this patient's unusual presentation, the time interval between initial presentation and diagnosis was 8 months.

She subsequently declined surgery and underwent radiotherapy to base of tongue (70 Gy/35#). A follow up post treatment PET showed minimal residual metabolic activity and an MRI six months post treatment showed complete response.

3. Discussion

Isolated hypoglossal nerve palsy of various aetiologies are rare and limited to case reports [1] In an Asian population, this would normally alert the surgeon to the possibility of a nasopharyngeal carcinoma. Most are idiopathic, while other causes include radiation induced neuropathy, infectious mononucleosis, metastatic disease at base of skull, sarcoidosis, vasculitis, multiple sclerosis and hypoglossal nerve schwannoma [2,3]. When a cause can be determined, one-third is due to malignancy [1,4].

We are the second case with a patient presenting with slurred speech and dysphagia. Twenty five years ago, Silvester KC et al [1] reported a patient who presented in a similar fashion as ours. As a result of this rarity, the patient suffered a long delay in the diagnosis. Only an incisional biopsy was later performed, allowing a correct diagnosis to be made.

ACC is a malignant neoplasm originating in both major and minor salivary glands.

Epidemiologically, there is a female preponderance (F:M 1.2:1) and most occur in the 6th decade of life [5]. It makes up 1–2% of all malignant neoplasms of the head and neck and up to 10–15% of malignant salivary gland neoplasms. 1–19.6% of ACCs manifest in minor salivary glands in the tongue [6]. Of minor salivary gland neoplasms, ACCs comprise of 22% [7].

ACC is characterized by slow progression, local invasiveness and PI. Late metastasis to the lung, bone and liver is common [8]. It presents as a painful mass secondary to PI. In parotid tumours, this is sometimes seen as facial nerve dysfunction [9,10].

PI is defined as tumour invasion through nerves [11]. And frequently occurs in head and neck SCC, pancreas, colon, rectum and prostate cancer. [11].

PI occurs in up to 70% of ACCs [5]. This is an independent prognostic marker for overall survival and disease specific survival [12,13].

ACCs are frequently FDG negative or only mildly avid and pathological lesions may be obscured by physiologic FDG uptake of major salivary glands [14].

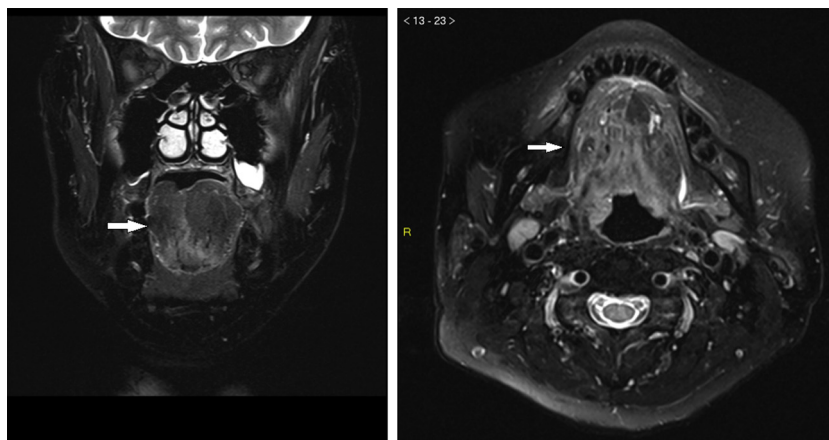


Image 2. T2W MRI with fat saturation in Coronal and Axial view depicting wasting of the right hemitongue.

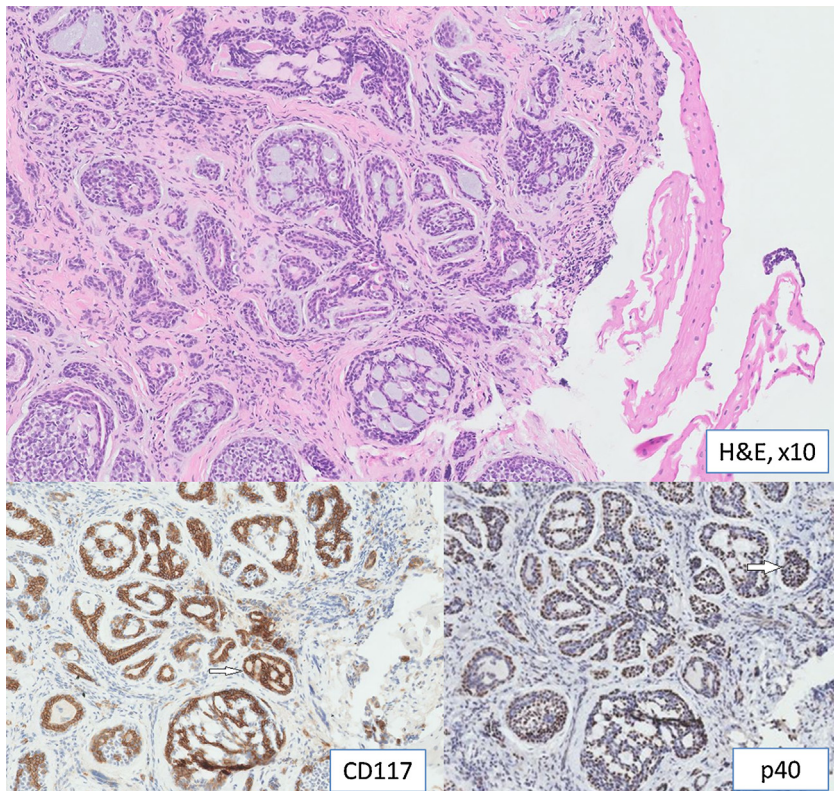


Image 3. Tumor demonstrating dual population of cells, with the luminal cells positive for CD117 and the myoepithelial cells positive for p40.

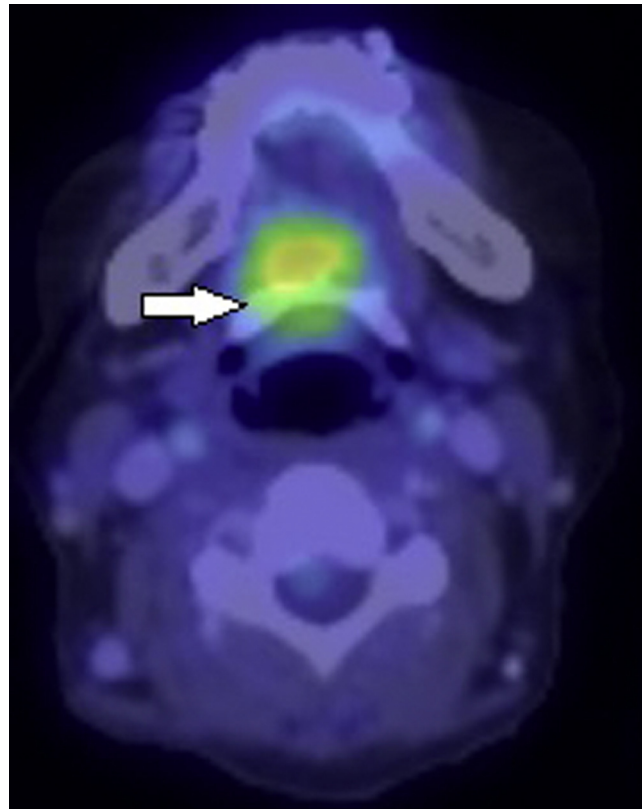


Image 4. PET scan showing FDG avid lesion in right hemi tongue.

The mainstay of treatment of ACC is surgery, which may involve a subtotal, hemiglossectomy or total glossectomy and reconstruction. A neck dissection may be required if there is evidence of

lymphatic spread to the neck. Radiotherapy has been used mainly as second line treatment with mixed response. The literature for the use of chemotherapy in ACC remains scarce but agents used

include 5-fluorouracil, Adriamycin and Cytosan [15] Most cases are managed with a combination of the above three modalities.

The prognosis of ACC is fair. Overall survival rates at 5, 10 and 15 years are 71%, 54% and 37% with a mean overall survival of 11.2 years [8].

4. Conclusion

Isolated hypoglossal nerve palsy may be the only presenting complaint in a patient with ACC of the tongue and also in other neurotrophic malignancies and one must avoid the pitfall of missing a malignancy.

Most diagnostic algorithms for the investigation of isolated hypoglossal nerve palsies include imaging, however this may still be negative in infiltrative lesions such as ACC.

We recommend that diagnostic algorithms should be modified such that, in addition to routine investigations, examination under anaesthesia and deep biopsy should be considered in a lesion that eludes diagnosis.

Conflict of interest

The authors declare that there is no conflict of interest.

Funding

No sources of funding.

Ethical approval

No ethical approval required.

Patient consent

The patient provided written permission for publication of this case report.

This work has been reported in line with the CARE criteria [16].

Author contribution

Hide Elfrida Wee: Concept and design of study, Drafting of manuscript.

Rafay Azhar: Conception of design and study Drafting of manuscript, approval of final manuscript.

Tang Po Yin: Conception of design and study Drafting of manuscript, approval of final manuscript.

Teo Tze Hern: Conception of design and study Drafting of manuscript, approval of final manuscript.

Narayanan Gopalakrishna Iyer: Drafting of manuscript, approval of final manuscript Tan Hiang Khoon: Drafting of manuscript, approval of final manuscript.

Tan Ngian Chye: Conception of design and study Drafting of manuscript, approval of final manuscript.

Guarantor

Mr Tan Ngian Chye.

References

- [1] K.C. Silvester, S. Barnes, Adenoid cystic carcinoma of the tongue presenting as a hypoglossal nerve palsy, *Br. J. Oral Maxillofac. Surg.* 28 (2) (1990) 122–124.
- [2] M.W. Ho, M.J. Fardy, S.J. Crean, Persistent idiopathic unilateral isolated hypoglossal nerve palsy: a case report, *Br. Dent. J.* 196 (4) (2004) 205–207.
- [3] B. Sharma, P. Dubey, S. Kumar, A. Panagariya, A. Dev, Isolated unilateral hypoglossal nerve palsy: a study of 12 cases, *J. Neurol. Neurosci.* (2011).
- [4] A. Coca-Pelaz, J.P. Rodrigo, P.J. Bradley, V. Vander Poorten, A. Triantafyllou, J.L. Hunt, et al., Adenoid cystic carcinoma of the head and neck – An update, *Oral Oncol.* 51 (7) (2015) 652–661.
- [5] S. van Weert, E. Bloemena, I. van der Waal, R. de Bree, D.H. Rietveld, J.D. Kuik, et al., Adenoid cystic carcinoma of the head and neck: a single-center analysis of 105 consecutive cases over a 30-year period, *Oral Oncol.* 49 (8) (2013) 824–829.
- [6] E.C. Soares, F.P. Carreiro Filho, F.W. Costa, A.C. Vieira, A.P. Alves, Adenoid cystic carcinoma of the tongue: case report and literature review, *Med. Oral Patol. Oral Cir. Bucal.* 13 (8) (2008) E475–8.
- [7] C.A. Waldron, S.K. El-Mofty, D.R. Gnepp, Tumors of the intraoral minor salivary glands: a demographic and histologic study of 426 cases, *Oral Surg. Oral Med. Oral Pathol.* 66 (3) (1988) 323–333.
- [8] H. Kokemueller, A. Eckardt, P. Brachvogel, J.E. Hausamen, Adenoid cystic carcinoma of the head and neck—a 20 years experience, *Int. J. Oral Maxillofac. Surg.* 33 (1) (2004) 25–31.
- [9] V.L. Vander Poorten, A.J. Balm, F.J. Hilgers, I.B. Tan, B.M. Loftus-Coll, R.B. Keus, et al., The development of a prognostic score for patients with parotid carcinoma, *Cancer* 85 (9) (1999) 2057–2067.
- [10] K.D. Biswas, J. Saha, I. Sen, G. Biswas, R. Sinha, D. Saha, et al., Unusual presentations of adenoid cystic carcinoma in extra-salivary gland subsites in head and neck region: a case series, *Indian J. Otolaryngol. Head Neck Surg.* 66 (Suppl. 1) (2014) 286–290.
- [11] C. Liebig, G. Ayala, J.A. Wilks, D.H. Berger, D. Albo, Perineural invasion in cancer: a review of the literature, *Cancer* 115 (15) (2009) 3379–3391.
- [12] M. Amit, Y. Binenbaum, L. Trejo-Leider, K. Sharma, N. Ramer, I. Ramer, et al., International collaborative validation of intraneural invasion as a prognostic marker in adenoid cystic carcinoma of the head and neck, *Head Neck.* 37 (7) (2015) 1038–1045.
- [13] M. Huang, D. Ma, K. Sun, G. Yu, C. Guo, F. Gao, Factors influencing survival rate in adenoid cystic carcinoma of the salivary glands, *Int. J. Oral Maxillofac. Surg.* 26 (6) (1997) 435–439.
- [14] S.W. Chen, Z.M. Guo, Q. Zhang, A.K. Yang, Q.L. Li, S.M. Zhuang, et al., Invasion of the hypoglossal nerve by adenoid cystic carcinoma of the tongue: case report and review of the literature, *Pathol. Oncol. Res.* 17 (4) (2011) 965–968.
- [15] K. Luna-Ortiz, T. Carmona-Luna, A.M. Cano-Valdez, A. Mosqueda-Taylor, A. Herrera-Gomez, V. Villavicencio-Valencia, Adenoid cystic carcinoma of the tongue—clinicopathological study and survival analysis, *Head Neck Oncol.* 1 (2009) 15.
- [16] J.J. Gagnier, G. Kienle, D.G. Altman, D. Moher, H. Sox, D. Riley, et al., The CARE guidelines: consensus-based clinical case report guideline development, *J. Diet Suppl.* 10 (4) (2013) 381–390.

Open Access

This article is published Open Access at sciendo.com. It is distributed under the [IJSCR Supplemental terms and conditions](#), which permits unrestricted non commercial use, distribution, and reproduction in any medium, provided the original authors and source are credited.