

Intermediate nerve neuralgia developed during hemifacial spasm follow-up: illustrative case

Keisuke Onoda, MD, PhD, Ryohei Sashida, MD, Ren Fujiwara, MD, Tomihiro Wakamiya, MD, PhD, Yuhei Michiwaki, MD, PhD, Tatsuya Tanaka, MD, PhD, Kazuaki Shimoji, MD, PhD, Eiichi Suehiro, MD, PhD, Fumitaka Yamane, MD, PhD, Masatou Kawashima, MD, PhD, and Akira Matsuno, MD, PhD

Department of Neurosurgery, International University of Health and Welfare, School of Medicine, Narita Hospital, Chiba, Japan

BACKGROUND Intermediate nerve neuralgia (INN) is a rare condition believed to be caused by vascular compression, with external auditory canal pain as the chief symptom. The authors reported a rare case of a 78-year-old woman who developed INN during follow-up for hemifacial spasm (HFS).

OBSERVATIONS The patient had been receiving Botox treatment for right HFS for 20 years when she developed paroxysmal electric shock pain in the right external auditory canal and tinnitus induced by opening her mouth. A three-dimensional magnetic resonance fusion image showed the cisternal portion of the facial-vestibulocochlear nerve complex to be compressed by the meatal loop of the anterior inferior cerebellar artery (AICA), which was pressed against by the posterior inferior cerebellar artery. The authors diagnosed INN, and microvascular decompression (MVD) was performed. Surgical findings were consistent with preoperative neuroimaging. In addition, the proximal portion of the meatal loop of the AICA had passed between the facial and vestibulocochlear nerves, compressing both. The AICA was moved and the nerve completely decompressed. All symptoms improved immediately following surgery.

LESSONS When INN occurs during HFS follow-up, aggressive MVD should be considered based on detailed neuroimaging. This treatment is a very effective single-stage cure for INN, HFS, and vestibulocochlear symptoms.

<https://thejns.org/doi/abs/10.3171/CASE22144>

KEYWORDS intermediate nerve neuralgia; hemifacial spasm; microvascular decompression

Intermediate nerve neuralgia (INN) is a rare disorder believed to be caused by vascular compression of the intermediate nerve, a component of the facial nerve.^{1–3} Taste, salivation, and lacrimal gland secretion are all controlled by the intermediate nerve, which enters the inner ear canal and becomes the tympanic nerve and the greater pyramidal nerve.^{1,3} Furthermore, the nerve is distributed as a superficial sensory nerve in the posterior auricular region and external auditory canal.^{1,3} It is widely accepted that hemifacial spasm (HFS) is induced by vascular compression at the root exit zone (REZ) of a motor branch of the facial nerve.^{4,5} Despite their shared etiology, the co-occurrence of INN and HFS is extremely rare.⁵ We report a case of a 78-year-old woman who developed INN during follow-up for HFS. We also review the literature to discuss the

pathophysiology of the simultaneous presence of INN and HFS based on surgical findings.

Illustrative Case

Presentation and History

In this case, a 78-year-old woman developed involuntary movements around the right periocular eyelid. Over the next 6 months, they gradually spread to the right side of the mouth, and a diagnosis of right HFS was made by her family doctor. The patient received Botox treatment once every 3 months after diagnosis, and her HFS was under control. Her medical history included hypertension and hyperlipidemia, which were controlled with medication.

ABBREVIATIONS AICA = anterior inferior cerebellar artery; CN = cranial nerve; HFS = hemifacial spasm; INN = intermediate nerve neuralgia; MVD = microvascular decompression; PICA = posterior inferior cerebellar artery; REZ = root exit zone; TN = trigeminal neuralgia; 3DMRC/MRA = three-dimensional magnetic resonance cisternogram/magnetic resonance angiogram.

INCLUDE WHEN CITING Published June 20, 2022; DOI: 10.3171/CASE22144.

SUBMITTED March 23, 2022. **ACCEPTED** April 6, 2022.

© 2022 The authors, CC BY-NC-ND 4.0 (<http://creativecommons.org/licenses/by-nc-nd/4.0/>).

The patient's family history was unremarkable. Treatment continued for 20 years, at which time she began experiencing paroxysmal electrical pain in her right external auditory canal induced by opening her mouth. She also reported tinnitus in her right ear and was referred to our department by her family doctor, who suspected right trigeminal neuralgia (TN). The patient's pain radiated to the right posterior auricular region. There was no dysgeusia, hypersalivation, or facial pain; moreover, there was no pain in the pharyngeal region when swallowing. No other abnormal neurological findings were identified.

Neuroimaging was performed using a three-dimensional magnetic resonance cisternogram/magnetic resonance angiogram (3DMRC/MRA) fusion image. These images provide 3D visualizations of the structures of the cerebral cistern, including blood vessels, nerves, and brain parenchyma. In our department, 3DMRC/MRA fusion images are used for preoperative diagnosis of TN and HFS. They are useful for surgical simulation because they can detect detailed anatomical relationships between nerves and vessels. The 3DMRC/MRA fusion images showed that the cisternal portion of the facial-vestibulocochlear nerve complex (cranial nerve [CN] VII/VIII complex) was severely compressed by the meatal loop of the anterior inferior cerebellar artery (AICA). Proximal site of meatal loop was inserted between the facial nerve and vestibulocochlear nerve. Moreover, the meatal loop was compressed by the posterior inferior cerebellar artery (PICA) from behind (Fig. 1A and B). No vascular compression of the trigeminal and glossopharyngeal nerves was observed. The diagnosis was preexisting HFS with ipsilateral INN. The patient was initially treated with carbamazepine, which was effective against the right external auditory canal pain, but the effect gradually decreased, and the decision was made to perform microvascular decompression (MVD) of the CN VII/VIII complex.

Under general anesthesia, the patient was in the left lateral decubitus position, and MVD was carried out with continuous monitoring of the auditory brainstem response. Surgical findings confirmed that the cisternal portion of the CN VII/VIII complex was severely compressed. The intermediate nerve was not visualized. It was confirmed that the proximal site of the meatal loop of the AICA passing between the facial and vestibulocochlear nerves was compressing both nerves. In addition, the AICA loop was compressed by the PICA from behind (Fig. 2A). The AICA loop was dissected and mobilized. Teflon tape was wrapped around the PICA, which was pulled out and secured to the cerebellar surface with fibrin glue (Fig. 2B). Next, the AICA loop was moved and secured to the dura

mater of the petrosal bone with fibrin glue (Fig. 2C). Finally, sufficient nerve decompression was confirmed. Immediately following surgery, the right external auditory canal pain, right tinnitus, and right HFS were resolved. Postoperative 3DMRC/MRA fusion image showed sufficient decompression of the CN VII/VIII complex (Fig. 1C). The patient was discharged from the hospital on the seventh day after surgery with no new neurological deficits. Six months after surgery, there was no apparent recurrence.

Discussion

Observations

The intermediate nerve exits the brainstem between the facial and vestibulocochlear nerves, following the medial side of the facial nerve. It then enters the internal auditory canal, where it merges with the facial nerve.² The intermediate nerve is a sensory branch of the facial nerve, which is concerned with taste, salivation, and other functions.¹⁻³ It is also distributed as a superficial sensory nerve in the posterior auricular region and external auditory canal.¹⁻³ One of the causes of INN is neurovascular conflict on the intermediate nerve,^{1,2,6} but the details are still undetermined. As far as we were able to ascertain from our search of the literature, there have been approximately 150 detailed reports of INN.^{2,3} The co-occurrence of HFS and INN is extremely rare, with only three reported cases at this time.^{3,6,7} One of these cases was previously published by the present authors and focuses on the diagnosis of INN and appropriate surgical procedures.³

We reviewed the clinical characteristics and surgical findings of four cases, including the present case, to investigate the etiology of comorbid HFS and INN. Ages ranged from 44 to 78 years, with an average of 61 years, and there were two male and two female cases. Two patients (cases 1 and 4) initially suffered from HFS and developed INN during follow-up, whereas the other two patients (cases 2 and 3) suffered from INN and developed HFS during follow-up. In cases 1 and 4, the interval between the onset of HFS and the development of INN was 10 and 20 years, respectively. The interval between the initial presentation of INN and the development of HFS in cases 2 and 3 was 4 and 20 years, respectively. The sequence of HFS and INN can be bidirectional. Long-term follow-up of either INN or HFS should be attentive to the possible development of the second condition. Hearing disturbances and tinnitus were observed in three cases (75%) as cochlear nerve

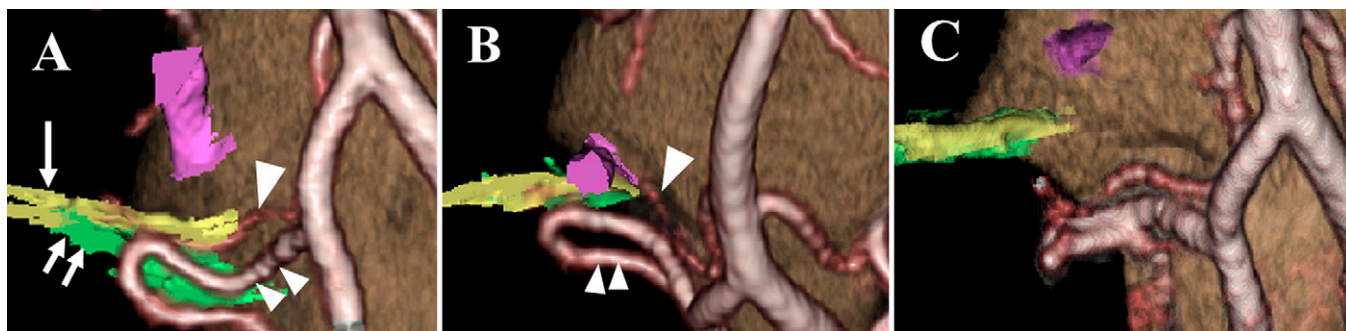

FIG. 1. A: Preoperative 3DMRC/MRA fusion image showing compression of the facial nerve (*single arrow*) and vestibulocochlear nerve (*double arrows*) by the AICA (*single arrowhead*) in the cisterna and posterior compression of the AICA by the PICA (*double arrowheads*). Moreover, the image indicated that the proximal site of the meatal loop of the AICA passing between the facial and vestibulocochlear nerves was compressing both nerves. **B:** The PICA (*double arrowheads*) has not contacted the REZ. **C:** Postoperative 3DMRC/MRA fusion image showing new placement of the responsible vessels and decompression of the nerves.

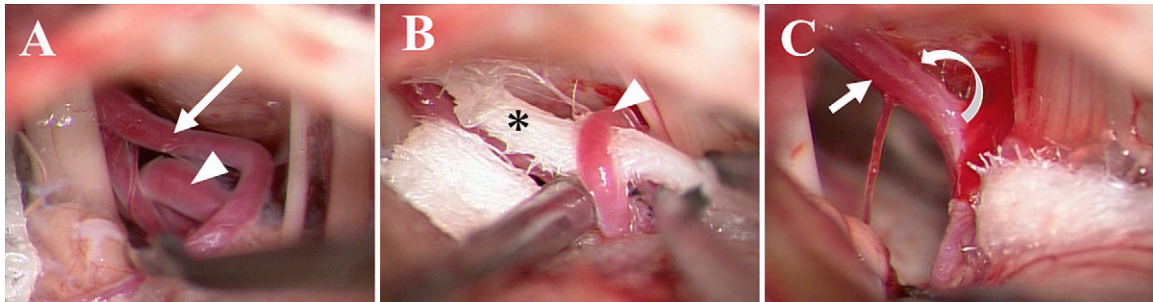


FIG. 2. A: The cisternal portion of the CN VII/VIII complex was compressed by the AICA (arrow); the AICA was compressed posteriorly by the PICA (arrowhead). **B:** Teflon tape (*) was wrapped around the PICA (arrowhead) and secured to the surface of the cerebellum. **C:** The AICA was moved to the dura mater of the petrosal bone and secured with fibrin glue. Curved arrow indicates attachment site of the dura.

symptoms. Although AICA is the most commonly responsible cause, the involvement of PICA in the present case cannot be ruled out. Interestingly, in two cases (50%), including the present case, the compression site was not in the REZ but rather the cisternal portion of the facial nerve.^{1,3} However, it is still possible that the REZ was affected by nerve stretching due to vascular compression.

It is generally accepted that HFS is caused by vascular compression of the REZ of the facial nerve.^{4,5} Ryu et al. reported five cases of HFS due to compression in the cisternal portion of the facial nerve, emphasizing that this can also cause HFS.⁸ The common characteristic of all four cases was the surgical finding that the responsible vessels had passed between the facial and vestibulocochlear nerves, compressing both. This appears to result in direct intermediate nerve compression. In addition, it may cause cochlear symptoms in up to 75% of cases. A case of INN with dizziness and tinnitus as vestibulocochlear nerve symptoms has been reported in which the symptoms were found, on autopsy, to be attributable to compression of the facial and vestibulocochlear nerve by a vessel running between the two.⁹ However, this case was not accompanied by HFS. Zheng et al. found that the responsible vessel ran between the facial and vestibulocochlear nerve and compressed the facial nerve in 21 of 355 cases of HFS (5.6%). They termed this crossed-type HFS.¹⁰ However, there is no mention of concomitant INN in their report. The occurrence of INN is less frequent than that of HFS, despite their shared etiology of compression of the facial nerve. The true pathogenesis of the concomitant occurrence of INN in HFS remains to be clarified, and further investigation is warranted based on the accumulating number of cases. Surgical outcomes were favorable in all four of the cases we examined (100%). This supports the hypothesis that the co-occurrence of INN and HFS arises due to neurovascular conflict and that MVD is a beneficial surgical approach. Hearing loss occurred in one of the four cases (25%) as a permanent complication. Therefore, it is necessary to pay scrupulous attention to the surgical technique and avoid damaging the labyrinthine artery and vestibulocochlear nerve.^{3,6,7}

We have previously reported on the efficacy of 3DMRC/MRA fusion imaging as a modality for preoperative evaluation of TN and HFS, with a detailed discussion on 3D detection of neurovascular conflict.^{11,12} 3DMRC/MRA fusion images are used for preoperative diagnosis of TN and HFS, evaluation of the anatomical relationship of the nerves and responsible vessels, and identification of any nerve deformities. In the present case, 3DMRC/MRA fusion imaging was conducted, but no

obvious neurovascular conflict was found around the trigeminal nerve or glossopharyngeal nerve. Only severe compression in the cisternal portion of the CN VII/VIII complex by the AICA was observed. The intermediate nerve was not identified. The findings were informative for surgical decision-making. This imaging method was also used for surgical simulation. The accuracy of 3DMRC/MRA fusion imaging was confirmed because the preoperative imaging evaluation was consistent with the intraoperative findings. The intermediate nerve is thin and difficult to directly detect with currently available technology. Therefore, further research is needed to enable more detailed and accurate neuroimaging diagnoses.

Lessons

When paroxysmal electrical pain occurs in the external auditory canal during follow-up of HFS, INN should be kept in mind. MVD can provide treatment for INN, HFS, and vestibulocochlear symptoms in a single surgery. Both HFS and INN may be caused by the responsible vessel passing between the facial nerve and the vestibulocochlear nerve. Because MVD is effective in improving these conditions, aggressive surgical treatment should be considered based on detailed neuroimaging.

Acknowledgments

We would like to thank Enago for the English language review.

References

- Goulin Lippi Fernandes E, van Doormaal T, de Ru S, Miller K, Han KS. Microvascular decompression of the VII/VIII cranial nerve complex for the treatment of intermediate nerve neuralgia: a retrospective case series. *Oper Neurosurg (Hagerstown)*. 2018;15(4):378–385.
- Inoue T, Shima A, Hirai H, Suzuki F, Matsuda M. Nervus intermedius neuralgia treated with microvascular decompression: a case report and review of the literature. *NMC Case Rep J*. 2017;4(3):75–78.
- Onoda K, Kawaguchi A, Takaya Y, et al. A case of nervus intermedius neuralgia. *World Neurosurg*. 2020;137:89–92.
- Jannetta PJ, Kassam A. Hemifacial spasm. *J Neurol Neurosurg Psychiatry*. 1999;66(2):255–256.
- Sindou M, Mercier P. Hemifacial spasm associated with other cranial nerve syndromes: literature review. *Neurochirurgie*. 2018;64(2):101–105.
- Chen Y, Song Z, Wan Y, et al. Intermediate nerve neuralgia can be diagnosed and cured by microvascular decompression. *J Craniofac Surg*. 2014;25(4):1187–1189.

7. Yeh HS, Tew JM Jr. Tic convulsif, the combination of geniculate neuralgia and hemifacial spasm relieved by vascular decompression. *Neurology*. 1984;34(5):682–683.
8. Ryu H, Yamamoto S, Sugiyama K, Uemura K, Miyamoto T. Hemifacial spasm caused by vascular compression of the distal portion of the facial nerve. Report of seven cases. *J Neurosurg*. 1998;88(3):605–609.
9. Ouaknine GE, Robert F, Molina-Negro P, Hardy J. Geniculate neuralgia and audio-vestibular disturbances due to compression of the intermediate and eighth nerves by the postero-inferior cerebellar artery. *Surg Neurol*. 1980;13(2):147–150.
10. Zheng X, Feng B, Zhang W, Ying T, Li S. Hemifacial spasm caused by cross type vascular compression. *Neurol Res*. 2011;33(9):965–969.
11. Satoh T, Onoda K, Date I. Preoperative simulation for microvascular decompression in patients with idiopathic trigeminal neuralgia: visualization with three-dimensional magnetic resonance cisternogram and angiogram fusion imaging. *Neurosurgery*. 2007;60(1):104–113.
12. Satoh T, Onoda K, Date I. Fusion imaging of three-dimensional magnetic resonance cisternograms and angiograms for the assessment of microvascular decompression in patients with hemifacial spasms. *J Neurosurg*. 2007;106(1):82–89.

Disclosures

The authors report no conflict of interest concerning the materials or methods used in this study or the findings specified in this paper.

Author Contributions

Conception and design: Onoda, Fujiwara, Michiwaki, Tanaka, Shimoji, Suehiro, Yamane, Kawashima. Acquisition of data: Onoda, Michiwaki, Kawashima. Analysis and interpretation of data: Onoda, Michiwaki. Drafting the article: Onoda, Tanaka, Suehiro. Critically revising the article: Onoda, Sashida, Fujiwara, Michiwaki, Tanaka, Shimoji, Suehiro. Reviewed submitted version of manuscript: Onoda, Sashida, Fujiwara, Michiwaki, Shimoji, Kawashima, Matsuno. Statistical analysis: Fujiwara, Shimoji, Yamane. Administrative/technical/material support: Sashida, Fujiwara, Wakamiya, Tanaka, Yamane. Study supervision: Suehiro, Kawashima, Matsuno.

Correspondence

Keisuke Onoda: International University of Health and Welfare, School of Medicine, Narita Hospital, Chiba, Japan. onoda3883@gmail.com.