



Complications of surgical reconstruction of multiligament injuries of the knee joint: diagnosis, prevention and treatment

E. Carlos Rodríguez-Merchán^{1,2}
 Hortensia De la Corte-Rodríguez³
 Carlos A. Encinas-Ullán¹
 Primitivo Gómez-Cardero¹

- The main complications of surgical reconstruction of multiligament injuries of the knee joint are residual or recurrent instability, arthrofibrosis, popliteal artery injury, common peroneal nerve injury, compartment syndrome, fluid extravasation, symptomatic heterotopic ossification, wound problems and infection, deep venous thrombosis, and revision surgery.
- Careful surgical planning and execution of the primary surgical reconstruction of multiligament injuries of the knee joint can minimize the risk of the aforementioned complications.
- Careful postoperative follow-up is required to detect complications. Early recognition and prompt treatment are of paramount importance.
- To obtain good results in the revision surgery of failed multiligamentary knee reconstructions, it is crucial to perform a thorough and exhaustive evaluation to detect all the causes of failure.
- Addressing all associated injuries during revision surgery will lead to the best possible subjective and objective results, although functional outcomes are often modest.
- However, advanced age and high-energy injuries have been associated with the poorest functional outcomes after revision surgery of failed multiligament injuries of the knee joint.

Keywords: knee; multiligament injury; surgical reconstruction

Cite this article: *EFORT Open Rev* 2021;6:973-981.
 DOI: 10.1302/2058-5241.6.210057

Introduction

Multiligament knee injuries (MLKIs) are rare (0.02% of all injuries treated in orthopaedic surgery). However, such

injuries are usually serious for the patients who experience them.¹ Due to the paucity of data with a high degree of evidence, the best treatment strategy for MLKIs remains unclear. It is generally accepted that acute-phase or staged surgical reconstructions give the best results. In addition, an effective repair can only be achieved within the first three weeks post injury; and early mobilization of the knee after MLKI surgery results in less loss of joint mobility.²

The timing of surgical reconstruction of MLKIs should be individualized. The approach should take into consideration which ligaments are injured, the neurovascular and skin status of the surgical site, and the general health of the patient. It is essential to perform an examination under anaesthesia before starting surgery to confirm which structures are damaged (Table 1).^{3,4}

Reconstruction of multiligament knee injuries

The technique generally recommended in MLKIs is surgical reconstruction of the injured structures. These structures are basically the anterior cruciate ligament (ACL), the posterior cruciate ligament (PCL), the posteromedial corner (PMC), and the posterolateral corner (PLC).

Table 1. Physical examination of knee ligament injuries

Structure	Test
Anterior cruciate ligament (ACL)	Lachman's test, pivot shift
Posterior cruciate ligament (PCL)	Posterior drawer, posterior sag sign
Medial collateral ligament (MCL)	Valgus stress at 0° and 30° of flexion
Lateral collateral ligament (LCL)	Varus stress at 30° of flexion
Posteromedial corner (PMC)	Slocum test*
Posterolateral corner (PLC)	External rotation dial testing, posterolateral drawer

*Slocum's test represents a modification of the anterior drawer test, which tests anteromedial rotary instability (AMRI) and anterolateral rotary instability (ALRI) of the knee.⁴

Table 2. Surgical management in relation to existing ligament injuries

ACL + MCL or PLC + MCL	Single-bundle superficial MCL reconstruction. If MCL and concomitant tear of ACL or PCL are present, it has been suggested to pass the cruciate graft (ACL or PCL) into the femur and fix them at this point without securing them to the tibia. The second step should be MCL graft placement in the femoral tunnel, and lastly, the cruciate graft can be secured at the tibial attachment sites (Geeslin and Laprade ⁶).
ACL + PLC or PCL + PLC	Reconstruct the PLC together with the ACL or PCL to unload the immature graft. In this setting, the fixation of the PLC graft should be performed before the fixation of the ACL graft: this will prevent an external rotation of the tibia. However, for a combined PCL and PLC injury, the PCL graft should be tensioned and fixed prior to the PLC graft fixation (Wentorf et al ⁷).
ACL + PCL + PLC	The PCL graft needs to be secured first to restore the central pivot of the knee, then the ACL is fixed, and lastly the PLC.

Note. ACL, anterior cruciate ligament; MCL, medial collateral ligament; PLC, posterolateral corner; PCL, posterior cruciate ligament.

Reconstruction should be decided on an individualized basis, taking into account the expectations of each patient and the healing potential of the damaged ligaments and structures. The posterior oblique ligament (POL) should be reconstructed too.⁵ Table 2 summarizes the most common surgical management of MLKIs.^{1,6,7}

Ligamentous reconstruction can be performed acutely or early (within three weeks of injury) or be delayed. On the other hand, reconstruction can be performed in a single stage, in which all the injured structures are reconstructed together, or in two stages. That is, in the first stage the medial or lateral structures are reconstructed with or without the PCL, and in the second stage the ACL is reconstructed.^{1,2}

The choice of grafts to be used in MLKI reconstructions is another controversial issue. There are currently three options: autografts, allografts, or synthetic grafts, although we think that it is better to use a fresh frozen non-irradiated allograft. Each of these options has pros and cons. The choice of graft usually depends on the number of ligaments requiring reconstruction, the availability of grafts, the surgical technique used for reconstruction (some techniques require longer grafts), and the surgeon’s preferences. Possible autografts to be used are the hamstring (gracilis and semitendinosus) tendon,

bone-patella tendon-bone (BPTB), and quadriceps tendon (with or without a distal bone block). These grafts can be obtained from the injured knee or from the contralateral knee. Allografts include Achilles tendon, extensor mechanism apparatus, BPTB, or tibialis anterior tendon. The problem with allografts is that they are expensive and sometimes not readily available. Synthetic grafts, such as the Ligament Augmentation and Reconstruction System, can also be used in MLKI reconstruction.²

Regarding the choice of graft for combined ACL and medial collateral ligament (MCL) reconstruction, Figueroa et al have suggested performing allograft-only reconstructions, which limit donor site morbidity, or using an allograft and an autograft. When a hamstring tendon autograft is harvested, these authors recommend maintaining the integrity of the sartorius fascia and the gracilis. The important role of the semitendinosus-gracilis-sartorius complex in valgus stability in the context of an MCL-deficient knee should not be overlooked.⁸

In chronic knee ligamentous injuries, the damaged ligaments often have poor quality tissue; precisely for this reason, primary PLC repair in chronic injuries is not the best option. In combined chronic ACL and PLC injuries, it is advisable to surgically reconstruct both structures. The surgical technique to be used should be the same as in the acute setting. Long-term instability can result in varus knee malalignment, which will benefit from an opening wedge high tibial osteotomy that should be performed prior to surgical reconstruction. Therefore, it is crucial to perform standing mechanical axis radiographs in all chronic cruciate-deficient knee injuries, in knees with multiple ligament injuries, and in patients with failed cruciate ligament surgery. After osteotomy as a first stage, we should assess whether ligament reconstruction is necessary in a second stage.⁹ Table 3 summarizes the grafts and techniques used in MLKI.³

Fig. 1 shows an intraoperative image of an anatomical reconstruction of the PLC. Fig. 2 shows an anatomical reconstruction of the PMC. Fig. 3 shows a preparation image of a PCL plasty by inlay technique with double femoral fascicle and Achilles allograft. Although surgical

Table 3. Grafts and techniques used in multiligamentous knee injuries (MLKIs)

Structure	Technique	Graft	Fixation
ACL	Single-bundle anatomic reconstruction via independent tunnels	Quadrupled ipsilateral hamstring autograft	Tibia: interference screw/sheath Femur: Endobutton
PCL	Single-bundle anatomic reconstruction via transtibial tunnel	Ipsilateral patella tendon autograft/ ipsilateral quadriceps tendon autograft	Femur and tibia: interference screw
MCL/PMC	Primary repair + modified Bosworth or allograft reconstruction	Semitendinosus autograft (modified Bosworth) or semitendinosus allograft	Femur and tibia: screw and spiked washer
PLC/LCL	Primary repair + Larson figure-of-8 + Müller popliteal bypass	Hamstring allografts (2- or 3-tailed)	Femur (both grafts): screw and spiked washer Tibia (Müller graft): interference screw/staple Fibula (Larson graft): looped through tunnel

Note. ACL, anterior cruciate ligament; LCL, lateral collateral ligament; MCL, medial collateral ligament; PCL, posterior cruciate ligament; PLC, posterolateral corner; PMC, posteromedial corner.

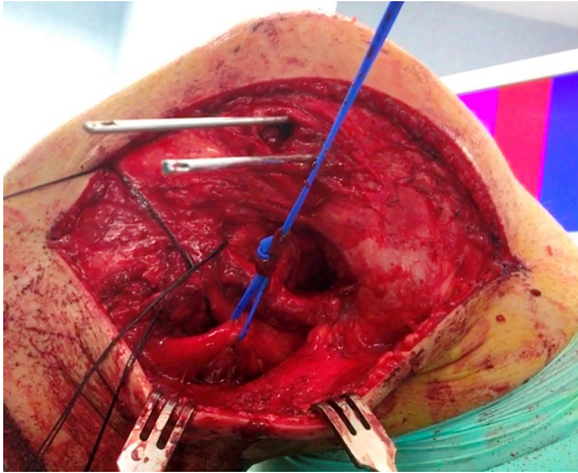


Fig. 1 Intraoperative image of anatomical reconstruction of the posterolateral corner (PLC). A vessel loop has been placed separating the peroneal nerve; the two needles mark the tunnels of the lateral collateral ligament (LCL) and the popliteal tendon, which are 18 mm apart. For this procedure, a tunnel must be made in the fibula and a tunnel in the tibia.

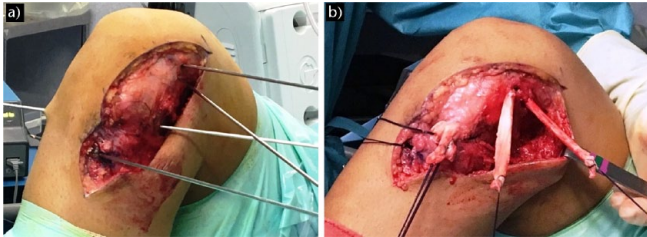


Fig. 2 Anatomical reconstruction of the posteromedial corner (PMC). (a) The needles mark the tunnels for this reconstruction. (b) The grafts of the superficial collateral ligament and the posterior oblique ligament (POL) fixed in the femur are observed.

treatment generally gives better results than non-surgical treatment, surgical reconstruction of MLKIs is not without potential complications.¹⁰ The diagnosis, prevention, and treatment of complications associated with surgical reconstruction of MLKIs are reviewed below. These complications are summarized in Table 4.

Table 4. Main complications of surgical reconstruction of multiligament knee injuries (MLKIs)

Instability
Arthrofibrosis
Popliteal artery injury
Common peroneal nerve injury
Compartment syndrome due to fluid extravasation
Symptomatic heterotopic ossification
Wound problems and infection
Deep venous thrombosis
Revision surgery

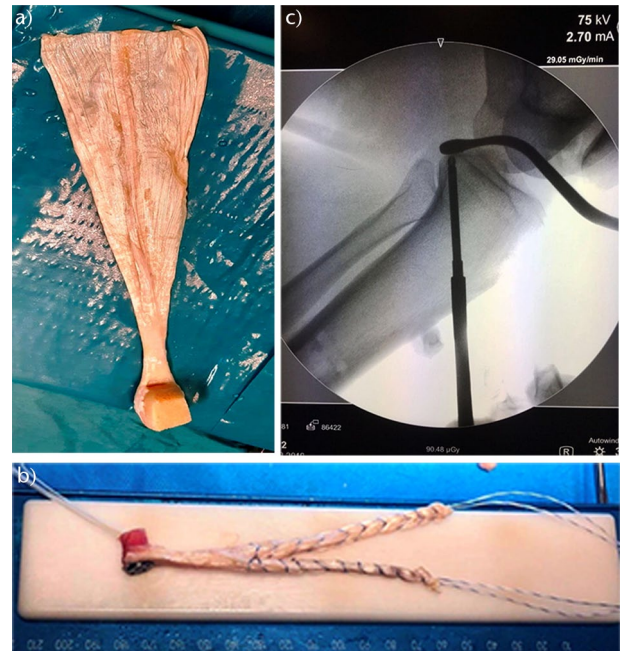


Fig. 3 Image of preparation of a posterior cruciate ligament (PCL) reconstruction by inlay technique with double femoral fascicle and image of Achilles allograft (a) and (b) used for multiligamentous reconstructions. (c) Intraoperative fluoroscopic control is essential.

Recurrent instability

Recurrent or persistent instability is a common complication of surgical treatment (reconstruction of MLKIs). Its published prevalence is 42%.¹¹ Regarding its diagnosis, magnetic resonance imaging (MRI) is essential for identifying the injured ligaments and determining the site of injury. Plain radiographs can detect possible bony avulsions. An examination under anaesthesia at the time of surgical reconstruction is crucial to assessing pathologic laxity. Multiple allograft and autograft options (semitendinosus, gracilis, tibialis anterior, or Achilles tendons with or without bone plugs) should be available. Various fixation techniques should also be available.

As far as prevention is concerned, factors that can adversely affect knee stability after multiligamentous reconstruction are summarized in Table 5. All factors shown in Table 5 can predispose the patient to recurrent instability and necessitate revision surgery.¹⁰ On the other hand, persistent instability predisposes to new meniscal and articular cartilage injuries of the knee. In fact, in patients with chronic instability, the published incidence of articular or meniscal lesions requiring revision surgery is 75%, compared with no meniscal or articular cartilage lesions in patients treated with early surgery.¹² The systematic review published by Levy et al found that direct cruciate

Table 5. Factors that can adversely affect knee stability after multiligamentous reconstruction

Severity of initial injury
Existing pathology at the time of surgical reconstruction
* Malalignment of the limb
* Meniscal incompetence
* Cartilage injuries
Failure to identify all knee injuries
Technical errors
* Absence of reconstruction of an injured ligament
* Use of a structurally weak graft
* Non-anatomic placement of ligamentous grafts
* Inadequate fixation of grafts
Inadequate postoperative rehabilitation protocol
Possible additional traumatic events

ligament repair resulted in greater loss of flexion, higher rates of PCL instability, and lower rates of return to pre-injury activity level than cruciate ligament reconstructions.¹²

Following multiligamentous knee reconstructions, the postoperative rehabilitation protocol is important for therapeutic success. This protocol should be slower than when an isolated ACL reconstruction is performed. Stretching of the graft during postoperative rehabilitation is common.¹³ However, efforts should be made to prevent postoperative loss of joint mobility. Therefore, protocols should be patient-specific, depending on the structures that have been surgically reconstructed. There must be continuous communication between the surgeon, patient, and rehabilitation physician. The main factors contributing to the risk of graft failure in the early postoperative period are the use of allografts, hyperextension, varus or valgus loads, and rotational forces, which can place high loads on healing ligaments. Routinely, a brace should be worn for a minimum of six weeks after reconstruction. Open chain exercises can place high loads on reconstructed cruciate ligaments and can lead to graft stretching if started too early. Therefore, such exercises should be avoided for three months. The patient cannot start running until they have full range of motion (ROM), no effusion, and good muscle control, which is usually achieved in about four months. Pivoting activities should be started at 6–9 months, avoiding the return to any sporting activity for at least one year. The risk of graft failure due to overly aggressive rehabilitation should be weighed against the risk of arthrofibrosis due to an overly restrictive rehabilitation programme.

Regarding surgical treatment for recurrent instability, revision surgery of the structures causing the instability should be performed.¹⁰ In revision surgery, it is essential to avoid all the errors and factors that led to knee instability after primary ligamentous reconstruction.

In short, correct surgical technique is essential to achieving a stable knee after multiligamentous knee reconstructions. All injured structures must be accurately identified and adequately reconstructed. In this way, we will prevent postoperative instability.

Arthrofibrosis

According to Johannesmeyer et al, it is advisable to perform surgery as soon as the soft tissue envelope of the knee has recovered from the acute trauma to prevent arthrofibrosis, provided that the patient’s general condition allows them to actively participate in postoperative rehabilitation. If it is necessary to delay surgery, the knee can be stabilized with a spanning external fixator or a hinged knee brace. However, concomitant injuries, such as bucket handle meniscus tears, significant avulsion injuries amenable to repair, and irreducible knee dislocations, such as those observed with MCL invagination, might warrant more urgent surgical intervention.¹⁰ Table 6 shows the fundamental data related to the prevention of arthrofibrosis. With regard to ROM exercises, if aggressive motion exercises are started too early there is a risk of stretching the healing grafts. After multiligament knee reconstructions, we must balance the risk of recurrent laxity with the risk of arthrofibrosis. An individualized rehabilitation protocol should be developed for each patient in collaboration with the rehabilitation physician. Johannesmeyer et al recommend immobilizing the knee near full extension for approximately two weeks before starting ROM exercises; hyperextension, flexion > 90°, and weight bearing should be avoided for six weeks to protect the reconstructed ligaments during the initial phase of healing. It should be remembered that allografts tolerate long periods of immobilization better than autografts. Johannesmeyer et al use an algorithm developed by Cosgarea et al to treat stiff knees.^{10,14}

Regarding the treatment of arthrofibrosis, when arthrofibrosis is detected at an early stage of rehabilitation, it is advisable to perform ROM exercises and patellar mobilization, together with anti-inflammatory and analgesic medication. If, despite such treatment, the patient still has significant loss of joint mobility at three months, it is advisable to perform closed manipulation under anaesthesia followed by an aggressive rehabilitation programme. An indwelling epidural catheter might be necessary for pain control if pain limits the patient’s ability to participate in rehabilitation. Surgical intervention will only be indicated in recalcitrant cases, especially those with significant flexion contractures. Such interventions consist of performing an arthroscopic lysis of adhesions and fat pad debridement. If the above treatments fail, a limited arthrotomy

Table 6. Prevention of arthrofibrosis after multiligamentous knee reconstruction

Minimize surgical trauma by using arthroscopic techniques whenever possible.
Limit the harvesting of autografts from the injured knee.
Minimize postoperative swelling (with rest, ice, compression and elevation).
Range of motion (ROM) exercises should be initiated as soon as possible depending on the pattern of injury, choice of graft, and ligament fixation.

might be required to remove the anterior scar tissue. Using this technique, Cosgarea et al observed significant gains in joint mobility in both flexion and extension. However, the final functional results were not satisfactory. Radiologically, 89% of patients had osteophytes in at least one compartment and 20% had joint space narrowing. The results were poorer in patients with severe loss of joint mobility and arthrofibrosis of long duration (> 6 months).¹⁴

Paulos et al also observed significant improvement of joint mobility in patients diagnosed with infrapatellar contracture syndrome (IPCS).¹⁵ IPCS consists of an exaggerated pathologic fibrous hyperplasia of the anterior soft tissues of the knee. Sometimes the syndrome is secondary to prolonged immobilization and lack of extension associated with knee surgery, especially intra-articular ACL reconstruction. The improvement observed by Paulos et al was associated with significant pain and functional limitation. These authors made it clear that the best approach to arthrofibrosis is prevention or early surgical intervention. Once the early phase has passed, IPCS should be treated by debridement and anterior intra-articular and extra-articular capsular release, followed by extensive rehabilitation.¹⁵

Popliteal artery injury

The possibility of vascular obstruction due to an intimal popliteal artery injury (detected or undetected) must be carefully considered when performing a multiligament surgical reconstruction. A thorough neurovascular examination is mandatory immediately after every multiligament knee reconstruction. Any abnormality detected will require urgent consultation with a specialist in vascular surgery.

The popliteal artery can be injured when performing PCL reconstruction. With the transtibial technique, the artery can be injured during the passage of a guide pin or when drilling the tibial tunnel.¹⁶ Matava et al have shown that the distance between the PCL tibial attachment and the popliteal artery averages 7.2 mm in the sagittal plane from full extension to 100° flexion, with a maximum distance of 9.3 mm at 100° flexion.¹⁷

There are commercially available PCL tibial guides that provide some protection against the guide pin penetrating the posterior capsule. Fluoroscopic imaging in perfect lateral projection of the tibial plateau can help prevent popliteal artery injury (Fig. 3c). However, it is better to directly visualize the guide pin exiting the PCL tibial footprint.

The PCL tibial footprint can be visualized by placing the 70° arthroscope through an accessory posteromedial portal. Once the guide pin has been satisfactorily placed, a curette or commercially available pin shield should be placed over the guide pin while tunnel reaming is performed. Proper visualization, capping the pin, and careful reaming can prevent us from penetrating the popliteal

space and injuring the popliteal artery. The transeptal approach is another alternative for proper visualization utilizing a 30° arthroscope from the posteromedial portal and capping the pin from the posterolateral portal.

The tibial inlay technique for PCL reconstruction can also minimize popliteal artery injury. In this technique, the PCL tibial footprint is approached through a posterior or posteromedial incision. The medial head of the gastrocnemius is retracted laterally to expose the PCL footprint and protect the popliteal structures. A burr is then used to create a trough in the PCL footprint where the graft will be attached. However, even with this technique, there is the potential for injury to the popliteal artery due to vigorous retraction or subluxation of the joint. We must always be aware of the risk of popliteal artery injury in any multiligament reconstruction.

Nerve injury

In surgical approaches to reconstruct the MCL and PLC, great care must be taken to identify and protect the common peroneal nerve, because injury to this nerve can occur in up to 2% of surgeries.¹⁸ The common peroneal nerve can be identified and marked early in the surgical dissection, because it is at risk if bony tunnels must be drilled into the fibular head for PLC reconstruction or biceps femoris tendon repair. The nerve is best identified proximal to the fibular head on the posterior aspect of the biceps femoris tendon.¹⁶ Some authors do not dissect the peroneal nerve unless there is an avulsion of the biceps femoris. They stated that staying within 2 cm of the tip of the fibular head is safe.¹⁹ As the nerve advances towards the fibular head, there are numerous fascial bands encompassing both the biceps femoris tendon and the common peroneal nerve. Once identified, a vessel loop should be placed around it to serve as a visual reminder of its location. The use of a haemostat should be avoided to prevent the possibility of traction injury to the nerve. The fascial plane posterior to the biceps femoris should not be closed to prevent the nerve from being compressed by postoperative swelling. When releasing the common peroneal nerve, we should consider performing a short release (5 mm) of the fascia of the peroneus longus muscle.

The saphenous nerve can also be injured during the surgical approach. The saphenous nerve lies beneath the sartorius muscle and the gracilis tendon. The main branch of this nerve, the sartorial branch, travels distally to provide sensation to the medial aspect of the calf. The sartorial branch can be injured when creating a posteromedial arthroscopy portal, harvesting the pes anserine tendons, or performing an MCL repair or reconstruction. If the sartorial branch is cut, the patient will present with numbness on the anteromedial aspect of the calf. A painful neuroma

can also occur. Transillumination of the saphenous vein with a 70° arthroscope through the notch, and keeping the posteromedial portal anterior to the vein, will minimize the risk of nerve injury, although a 30° arthroscope will do the job too. Careful retraction of the pes anserine tendons and placing the knee flexed during medial knee exposure also help protect the saphenous nerve during open medial reconstructions. When the aforementioned neuritic symptoms occur postoperatively, gabapentin or similar drugs are usually indicated.

The infrapatellar branch of the saphenous nerve can be injured when an arthroscopic medial portal is created and it is often transected during anteromedial knee incisions. When this nerve is cut, the patient will have numbness on the anterolateral aspect of the knee. Occasionally, a painful neuroma can occur. When planning an anteromedial incision, we should explain to the patient preoperatively that there will be a numb area lateral to the incision after the operation. The numb area usually decreases and becomes less noticeable over time.^{20–22}

Compartment syndrome and fluid extravasation

Significant capsular tears occur in MLKI, which can cause fluid extravasation if arthroscopy is performed soon after injury (before the capsular tears have healed). Arthroscopic fluid extravasation can cause compartment syndrome.^{23–25} Postponing surgery for 10 to 15 days allows the capsular tear to heal, thereby reducing the risk of extravasation. However, such a delay can make surgical dissection of the medial and lateral structures more difficult. Other strategies to prevent extravasation include using a low-flow pump, gravity flow, or performing the reconstruction with open techniques.

Regardless of the surgical timing, if arthroscopy is performed, we must pay close attention to possible fluid extravasation by frequently palpating the compartments during surgery. If the compartments are swelling, the arthroscopy should be abandoned, the compartment pressures measured, and, if necessary, urgent fasciotomies performed.

Wound problems and infection

When we perform a multiligament surgical reconstruction, we must take certain measures aimed at minimizing the risk of wound complications. We must avoid incisions that cross previous scars, avoid excessive undermining of the skin flap, and avoid an extended anterior ‘total knee’ incision. In addition, a sufficient skin bridge (> 10 cm) should be maintained between the incisions. In general, an anteromedial arthrotomy and an extensile lateral

incision allow adequate exposure of all injured areas of the knee without compromising the integrity of the skin.

Patients undergoing ligamentous reconstruction of the knee should be given perioperative intravenous antibiotics. It is paramount to prevent haematoma formation, given that postoperative haematomas are a major cause of skin necrosis and infection.²⁶ Gentle and careful manipulation of the tissues must be performed during the surgical procedure.

Finally, we must ensure that there is no excessive tension on the wound at the time of closure. Elevation of the operated limb and cryotherapy can minimize early postoperative swelling. Surgical wounds should be monitored for the first few weeks after surgery. If the wound shows any erythema or drainage, antibiotic treatment should be initiated. In severely infected wounds, surgical debridement will be necessary. Early detection of wound infection will prevent the need to remove ligament grafts and hardware.

An important and controversial issue that has arisen in the last few years is the role of vancomycin-soaking of the grafts with respect to reducing the incidence of septic arthritis. In 2020, Naendrup et al compared the incidence of postoperative septic arthritis after anterior cruciate ligament reconstruction (ACLR) between patients who received routine preoperative intravenous prophylaxis and patients who received additional graft-soaking in a vancomycin solution (5 mg/ml) perioperatively. They also reviewed the literature on the effects of graft-soaking in vancomycin solutions on outcomes, complication rates, and tendon properties in ACLR (level IV study, systematic review of level III and level IV studies).²⁷ After selecting 785 articles, they included eight studies (5075 patients) in their systematic review. Follow-up was six to 52 weeks. In the routine preoperative intravenous prophylaxis group ($n = 2099$) there were 44 (2.1%) cases of early septic arthritis. In contrast, there were no cases of septic arthritis after ACLR in the vancomycin-soaked graft patients ($n = 2976$). The meta-analysis yielded an odds ratio of 0.04 in favour of the addition of intraoperative vancomycin-soaking of grafts. There were no differences in clinical outcomes (i.e. incidence of ACL revision, International Knee Documentation Committee [IKDC] score, or Tegner score), tendon biomechanical properties, or cartilage integrity between patients with and without vancomycin-soaked grafts. Ultimately, the incidence of septic arthritis after ACLR can be dramatically reduced by vancomycin-soaking the grafts intraoperatively prior to graft passage and fixation. Intraoperative graft-soaking in vancomycin appears to be a safe and effective method to reduce the incidence of septic arthritis after ACLR. However, it remains debatable whether it should be widely recommended or instead reserved for at-risk patients (those with the use of hamstring tendons, revision cases, and in the presence of medical preconditions).²⁷

Heterotopic ossification

Heterotopic ossification (HO) is one of the possible causes of reduced knee mobility after surgical treatment of a multiligamentous lesion. The published incidence of symptomatic HO following such treatment ranges from 26% to 45%. Risk factors for developing HO are time to surgery, degree of soft tissue trauma, and high injury severity scores. In a study by Whelan et al, risk factors for the development of HO after surgical treatment of MLKIs were analysed, and the only independent risk factor found was PCL reconstruction.²⁸

In patients with significant risk factors for the development of HO, prophylaxis with indomethacin can be employed. Radiation has been used for HO prophylaxis in other conditions, but there is no record of its use in patients with MLKI. If follow-up radiographs show asymptomatic HO, no treatment is indicated. Treatment of symptomatic HO can be difficult and usually involves excision of the heterotopic bone. If the heterotopic bone is close to neurovascular structures, great care must be taken during surgical dissection to avoid injuring them. After removal of the HO, early ROM should be initiated and indomethacin prophylaxis employed.

Deep venous thrombosis

The incidence of symptomatic deep venous thrombosis (DVT) after MLKI reconstruction has been reported to range from 2.0% to 3.5% despite treatment with chemoprophylaxis.²⁹ These figures are consistent with other published studies on the use of low molecular weight heparin after ACLR and the use of external fixation devices for lower extremity trauma.³⁰ After surgical reconstruction of knee ligaments, anticoagulation should be continued until the patient is fully weight bearing. If leg swelling or calf pain is present, a duplex scan should be performed to determine whether DVT is present. If DVT is detected in the postoperative period, long-term anticoagulation should be performed. It is advisable to consult with an angiologist before and after MLKI reconstruction surgery.

Revision surgery

In 2021, Floyd et al stated that in patients with MLKIs careful attention to tunnel trajectory is of paramount importance to minimize the risk of convergence.³¹ According to Marom and Marx, revision multiligament knee reconstruction can restore stability in a high percentage of cases, when well executed.³² To obtain good results in cases of revision surgery for failed multiligament knee reconstructions, it is crucial to perform a thorough and comprehensive evaluation of the causes of failure. Addressing

all associated injuries during surgery, whether staged or not, will provide better subjective and objective results. However, advanced age and high-energy mechanisms of injury have been associated with the poorest functional outcomes.³²

In 2018, Woodmass et al evaluated the clinical outcomes of revision knee multiligamentous reconstructions, with a mean follow-up of 7.5 years (minimum two years).³³ In their level IV study (case series), they retrospectively analysed 23 patients who underwent revision reconstructions (≥ 2 ligaments reconstructed). The mean age of the patients was 26.7 years for primary surgery and 30.8 years for revision surgery. Of the 23 patients, 10 (43.4%) underwent staged revision procedures: isolated bone graft in three, osteotomy in four, hardware removal with osteochondral allograft in one, hardware removal with bone graft in one, and meniscal repair in a locked knee in one. The average IKDC and Lysholm scores were 74.5 and 79.4, respectively. High-energy injuries and an older age at the time of revision surgery were the only risk factors associated with significantly poorer outcomes. Patients with recurrent instability after multiligamentous knee reconstruction often have concomitant pathologies, such as limb malalignment, bone tunnel widening, retained hardware, meniscal incompetence, and cartilage defects. According to Woodmass et al, revision multiligamentous reconstruction can provide modest functional improvement if the concomitant pathology is identified and treated, often in a staged manner.

In 2020, Worley et al analysed the outcomes and factors associated with the need for revision ACLR after MLKI.³⁴ They retrospectively studied 231 MLKIs in 225 patients treated over a 12-year period. Patients with two or more injured knee ligaments requiring surgical reconstruction, including ACL, were included. Ten per cent ($n = 24$) of the 231 knees that underwent ACLR required revision ACLR. There were no significant differences in age, sex, tobacco use, diabetes, or body mass index between the groups requiring or not requiring revision ACL. However, patients requiring ACL revision had significantly longer follow-up (55.1 vs. 37.4 months), more ligament reconstructions/repairs (mean 3 vs. 1.7), more non-ligament surgeries (mean 2.2 vs. 0.7), more total surgeries (mean 5.3 vs. 2.4), and more graft reconstructions (mean 4.7 vs. 2.7). At the end of the follow-up, patients in both groups had similar levels of return to work and activity. Patients who underwent ACL revision took significantly longer to return to work at their highest level (18 vs. 12 months), although the time to return to their highest level of activity was similar. ROM (134 vs. 127 degrees), pain intensity (2.2 vs. 1.7), and Lysholm scores (86.3 vs. 90) were similar in both groups at the end of the follow-up. Patients who required ACLR revision in the context of an MLKI had more overall concurrent surgeries and other ligament reconstructions,

but had similar final outcome scores to those who did not require revision surgery. Ligament revision surgery can be associated with increased pain and stiffness as well as poorer patient outcomes. Revision surgery is often necessary after multiligament knee reconstructions. Patients requiring ACLR in the context of MLKI typically have good outcomes, with a revision rate of 10%.

In 2020, Stuart et al reported that the management of failed multiligament knee reconstruction is a difficult problem because of recurrent pathologic laxity. This laxity is frequently associated with other problems: limb malalignment, meniscus deficiency, articular cartilage insufficiency, reduced motion, compromised bone stock, and a paucity of graft sources.³⁵ The indication and surgical technique to be performed during revision surgery require a thorough evaluation of each patient and their injury and treatment factors. It also requires a good physical examination and advanced imaging tests. A stepwise treatment approach can be effective in revision surgery, allowing realistic goals to be set for the patient.

In 2021, Patel et al studied possible risk factors for complications after multiligamentous knee reconstructions (level III evidence, case-control study).³⁶ They performed a retrospective analysis of 134 patients with MLKI. Patients had undergone surgery by planned surgical reconstruction of more than one ligament based on clinical examination and MRI. Complications included wound infection requiring irrigation and debridement; arthrofibrosis requiring manipulation under anaesthesia and/or lysis of adhesions; DVT; need for hardware removal; and ligament revision surgery. A total of 108 patients met the inclusion criteria; of these, 29.6% had at least one complication. Smoking and planned staged surgery significantly increased the overall risk of complications, whereas increasing the time from injury to surgery significantly reduced the risk. Increasing the time from injury to surgery also led to a slight but significantly reduced risk of arthrofibrosis. Ultimately, the results of this study suggest that smoking, reduced time from injury to initial surgery, and planned staged procedures can increase the rate of complications.³⁶

Conclusion

Patients with MLKI present the surgeon with the difficult task of restoring stability to the knee without causing major complications. A thorough understanding of knee anatomy and biomechanics, combined with careful surgical planning and execution, can minimize the risk of serious complications. Careful postoperative follow-up is required to identify complications that can occur. Early recognition and prompt treatment will result in a satisfactory result in most patients.

A thorough and comprehensive evaluation of the causes is crucial to obtaining good results in cases of failed revision multiligament knee reconstructions. Revision multiligamentous reconstruction can provide modest functional results, even when concomitant pathologies are identified and treated, often in a staged manner. Advanced age and high-energy mechanism of injury have been associated with the poorest functional outcomes.

AUTHOR INFORMATION

¹Department of Orthopedic Surgery, La Paz University Hospital-IdiPaz, Madrid, Spain.

²Osteoarticular Surgery Research, Hospital La Paz Institute for Health Research – IdiPAZ (La Paz University Hospital – Autonomous University of Madrid), Madrid, Spain.

³Department of Physical and Rehabilitation Medicine, La Paz University Hospital, Madrid, Spain.

Correspondence should be sent to: Dr. E. Carlos Rodríguez-Merchán, Department of Orthopaedic Surgery, La Paz University Hospital-IdiPaz, Paseo de la Castellana 261, 28046-Madrid, Spain.
Email: ecrmerchan@hotmail.com

ICMJE CONFLICT OF INTEREST STATEMENT

The authors declare no conflict of interest relevant to this work.

FUNDING STATEMENT

No benefits in any form have been received or will be received from a commercial party related directly or indirectly to the subject of this article.

OPEN ACCESS

© 2021 The author(s)

This article is distributed under the terms of the Creative Commons Attribution-Non Commercial 4.0 International (CC BY-NC 4.0) licence (<https://creativecommons.org/licenses/by-nc/4.0/>) which permits non-commercial use, reproduction and distribution of the work without further permission provided the original work is attributed.

REFERENCES

1. Grassi A, di Sarsina TR, Lucidi GA, Raggi F, Macchiarola L, Zaffagnini S. Surgical timing in combined ligamentous injuries. In: Margheritini F, Espregueira-Mendes J, Gobbi A, eds. *Complex knee ligament injuries: from diagnosis to management*. Berlin-Heidelberg: Springer, 2019:35–44.
2. Ng JWG, Myint Y, Ali FM. Management of multiligament knee injuries. *EFORT Open Rev* 2020;5:145–155.
3. Buyukdogan K, Laidlaw MS, Miller MD. Surgical management of the multiple-ligament knee injury. *Arthrosc Tech* 2018;7:e147–e164.
4. Slocum DB, Larson RL. Rotatory instability of the knee: its pathogenesis and a clinical test to demonstrate its presence. *J Bone Joint Surg [Am]* 1968;50-A:211–225.
5. Laprade RF, Wijdicks CA. Surgical technique: development of an anatomic medial knee reconstruction. *Clin Orthop Relat Res* 2012;470:806–814.

6. **Geeslin AG, LaPrade RF.** Outcomes of treatment of acute grade-III isolated and combined posterolateral knee injuries: a prospective case series and surgical technique. *J Bone Joint Surg [Am]* 2011;93-A:1672–1683.
7. **Wentorf FA, LaPrade RF, Lewis JL, Resig S.** The influence of the integrity of posterolateral structures on tibiofemoral orientation when an anterior cruciate ligament graft is tensioned. *Am J Sports Med* 2002;30:796–799.
8. **Figueroa F, Figueroa D, Calvo R, Vaisman A, Espregueira-Mendes J.** Graft choice in combined anterior cruciate ligament and medial collateral ligament reconstruction. *EFORT Open Rev* 2020;5:221–225.
9. **Vogel LA, Edgar CM, Arciero RA.** Surgical treatment of combined anterior cruciate ligament and lateral-side injuries: acute and chronic. In: Margheritini F, Espregueira-Mendes J, Gobbi A, eds. *Complex knee ligament injuries: from diagnosis to management*. Berlin-Heidelberg: Springer, 2019:153–168.
10. **Johannesmeyer DC, Richter DL, Schenck RC Jr, Wascher DC.** Complications associated with the treatment of the multiple ligament injured knee. In: Fanelli GC, ed. *The multiple ligament injured knee*. Cham: Springer Nature Switzerland AG, 2019:561–570.
11. **Stannard JP, Schenck RC Jr, Fanelli GC.** Knee dislocations and fracture-dislocation. In: Bucholz RW, Court-Brown C, Heckman JD, eds. *Rockwood and Green's fractures in adults*. Philadelphia: Lippincott, Williams, and Wilkins, 2009:1832–1866.
12. **Levy BA, Dajani KA, Whelan DB, et al.** Decision making in the multiligament-injured knee: an evidence-based systematic review. *Arthroscopy* 2009;25:430–438.
13. **Lynch AD, Chmielewski T, Bailey L, et al; STaR Trial Investigators.** Current concepts and controversies in rehabilitation after surgery for multiple ligament knee injury. *Curr Rev Musculoskelet Med* 2017;10:328–345.
14. **Cosgarea AJ, DeHaven KE, Lovelock JE.** The surgical treatment of arthrofibrosis of the knee. *Am J Sports Med* 1994;22:184–191.
15. **Paulos LE, Rosenberg TD, Drawbert J, Manning J, Abbott P.** Infrapatellar contracture syndrome: an unrecognized cause of knee stiffness with patella entrapment and patella infera. *Am J Sports Med* 1987;15:331–341.
16. **Jackson DW, Proctor CS, Simon TM.** Arthroscopic assisted PCL reconstruction: a technical note on potential neurovascular injury related to drill bit configuration. *Arthroscopy* 1993;9:224–227.
17. **Matava MJ, Sethi NS, Totty WG.** Proximity of the posterior cruciate ligament insertion to the popliteal artery as a function of the knee flexion angle: implications for posterior cruciate ligament reconstruction. *Arthroscopy* 2000;16:796–804.
18. **Johnson ME, Foster L, DeLee JC.** Neurologic and vascular injuries associated with knee ligament injuries. *Am J Sports Med* 2008;36:2448–2462.
19. **Teo HLT, Ang KXM, Loh SYJ.** A reproducible reference point for the common peroneal nerve during surgery at the posterolateral corner of the knee: a cadaveric study. *Knee Surg Relat Res* 2020;32:23.
20. **Figueroa D, Calvo R, Vaisman A, Campero M, Moraga C.** Injury to the infrapatellar branch of the saphenous nerve in ACL reconstruction with the hamstrings technique: clinical and electrophysiological study. *Knee* 2008;15:360–363.
21. **Kjaergaard J, Faunø LZ, Faunø P.** Sensibility loss after ACL reconstruction with hamstring graft. *Int J Sports Med* 2008;29:507–511.
22. **Luo H, Yu JK, Ao YF, et al.** Relationship between different skin incisions and the injury of the infrapatellar branch of the saphenous nerve during anterior cruciate ligament reconstruction. *Chin Med J (Engl)* 2007;120:1127–1130.
23. **Ekman EF, Poehling GG.** An experimental assessment of the risk of compartment syndrome during knee arthroscopy. *Arthroscopy* 1996;12:193–199.
24. **Amendola A, Faber K, Willits K, Miniaci A, Labib S, Fowler P.** Compartment pressure monitoring during anterior cruciate ligament reconstruction. *Arthroscopy* 1999;15:607–612.
25. **Marti CB, Jakob RP.** Accumulation of irrigation fluid in the calf as a complication during high tibial osteotomy combined with simultaneous arthroscopic anterior cruciate ligament reconstruction. *Arthroscopy* 1999;15:864–866.
26. **Hegyes MS, Richardson MW, Miller MD.** Knee dislocation: complications of nonoperative and operative management. *Clin Sports Med* 2000;19:519–543.
27. **Naendrup J-H, Marche B, de Sa D, et al.** Vancomycin-soaking of the graft reduces the incidence of septic arthritis following ACL reconstruction: results of a systematic review and meta-analysis. *Knee Surg Sports Traumatol Arthrosc* 2020;28:1005–1013.
28. **Whelan DB, Dold AP, Trajkovski T, Chahal J.** Risk factors for the development of heterotopic ossification after knee dislocation. *Clin Orthop Relat Res* 2014;472:2698–2704.
29. **Born TR, Engasser WM, King AH, et al.** Low frequency of symptomatic venous thromboembolism after multiligamentous knee reconstruction with thromboprophylaxis. *Clin Orthop Relat Res* 2014;472:2705–2711.
30. **Sems SA, Levy BA, Dajani K, Herrera DA, Templeman DC.** Incidence of deep venous thrombosis after temporary joint spanning external fixation for complex lower extremity injuries. *J Trauma* 2009;66:1164–1166.
31. **Floyd ER, Monson JK, LaPrade RF.** Multiple ligament knee reconstructions. *Arthroscopy* 2021;37:1378–1380.
32. **Marom N, Marx RG.** Revision multiligament knee reconstruction can restore stability in a high percentage of the cases when well executed. *Arthroscopy* 2018;34:745–746.
33. **Woodmass JM, O'Malley MP, Krych AJ, et al.** Revision multiligament knee reconstruction: clinical outcomes and proposed treatment algorithm. *Arthroscopy* 2018;34:736–744.e3.
34. **Worley JR, Brimmo O, Nuelle CW, Zitsch BP, Leary EV, Cook JL, et al.** Revision anterior cruciate ligament reconstruction after surgical management of multiligament knee injury. *J Knee Surg* 2020. doi:10.1055/s-0040-1712969 [Epub ahead of print].
35. **Stuart MB, Woodmass JM, Krych AJ, Levy BA, Stuart MJ.** Revision multiligament knee reconstruction surgery. *J Knee Surg* 2020;33:346–350.
36. **Patel NK, Lian J, Nickoli M, et al.** Risk factors associated with complications after operative treatment of multiligament knee injury. *Orthop J Sports Med* 2021;9:2325967121994203.