

Multilevel cervical laminectomy and fusion with posterior cervical cages

ABSTRACT

Context: Cervical spondylotic myelopathy (CSM) is a progressive disease that can result in significant disability. Single-level stenosis can be effectively decompressed through either anterior or posterior techniques. However, multilevel pathology can be challenging, especially in the presence of significant spinal stenosis. Three-level anterior decompression and fusion are associated with higher nonunion rates and prolonged dysphagia. Posterior multilevel laminectomies with foraminotomies jeopardize the bone stock required for stable fixation with lateral mass screws (LMSs).

Aims: This is the first case series of multilevel laminectomy and fusion for CSM instrumented with posterior cervical cages.

Settings and Design: Three patients presented with a history of worsening neck pain, numbness in bilateral upper extremities and gait disturbance, and examination findings consistent with myeloradiculopathy. Cervical magnetic resonance imaging demonstrated multilevel spondylosis resulting in moderate to severe bilateral foraminal stenosis at three cervical levels.

Materials and Methods: The patients underwent a multilevel posterior cervical laminectomy and instrumented fusion with intervertebral cages placed between bilateral facet joints over three levels. Oswestry disability index and visual analog scores were collected preoperatively and at each follow-up. Pre- and post-operative images were analyzed for changes in cervical alignment and presence of arthrodesis.

Results: Postoperatively, all patients showed marked improvement in neurological symptoms and neck pain. They had full resolution of radicular symptoms by 6 weeks postoperatively. At 12-month follow-up, they demonstrated solid arthrodesis on X-rays and computed tomography scan.

Conclusions: Posterior cervical cages may be an alternative option to LMSs in multilevel cervical laminectomy and fusion for cervical spondylotic myeloradiculopathy.

Keywords: Cervical, intervertebral cage, laminectomy, myelopathy, spondylosis

INTRODUCTION

In 1952, Brain *et al.* were the first to describe cervical spondylotic myelopathy (CSM) and its presentation spanning minor symptoms to significant neurological compromise.^[1] Symptoms of CSM range from pain and numbness to weakness, gait instability, bowel and bladder dysfunction, and ultimately significant disability.^[1-3] The clinical course of CSM usually follows steadily progressive course of neurologic dysfunction. Treatment consists of decompression and fusion and may be performed through anterior, posterior, or combined surgical approaches. The anterior approach is commonly used for one- or two-segment pathology and offers better correction of kyphotic deformity and restoration/maintenance of sagittal

balance.^[4] Posterior techniques are preferred in cases of multisegmental involvement^[5-7] although such an approach is associated with a higher risk of postoperative kyphosis.^[8] The literature reflects comparable efficacy of both techniques in multisegmental pathology in improving pain and functional outcomes.^[7,9]

JAD N BOU MONSEF, KRZYSZTOF B SIEMIONOW

Department of Orthopaedics, University of Illinois at Chicago, Chicago, Illinois, USA

Address for correspondence: Dr. Krzysztof B Siemionow, 835 South Wolcott Avenue, Rm E-270, Chicago, Illinois 60612, USA.
E-mail: siemiok@gmail.com

Access this article online	
Website: www.jcvjs.com	Quick Response Code 
DOI: 10.4103/jcvjs.JCVJS_69_17	

This is an open access article distributed under the terms of the Creative Commons Attribution-NonCommercial-ShareAlike 3.0 License, which allows others to remix, tweak, and build upon the work non-commercially, as long as the author is credited and the new creations are licensed under the identical terms.

For reprints contact: reprints@medknow.com

How to cite this article: Bou Monsef JN, Siemionow KB. Multilevel cervical laminectomy and fusion with posterior cervical cages. *J Craniovert Jun Spine* 2017;8:316-21.

Facetal distraction as a treatment of cervical spondylosis with radiculopathy and myelopathy was described by Goel.^[10,11] Recently, intervertebral cervical cages implanted by a posterior approach bilaterally between the facet joints have demonstrated^[12-15] good clinical and radiological outcome at 24 months.^[16] Stabilization achieved after bilateral posterior cervical cage implantation is reported to be similar to anterior cervical discectomy and fusion (ACDF) and lateral mass screws (LMSs) in biomechanical studies.^[17,18] This technique stabilizes the facet with instrumented distraction and achieves indirect posterior cervical nerve root decompression by significantly increasing foraminal area.^[19] Results have supported its safety and efficacy for treatment of single-level cervical radiculopathy.^[20] This is the first reported case series of multilevel laminectomies and fusions for CSM instrumented with posterior cervical cages.

MATERIALS AND METHODS

Between 2015 and 2016, three patients with cervical spondylotic disease were treated using the proposed technique. Written informed consent was obtained from all patients. These patients were analyzed prospectively, and all patients underwent surgery performed by the corresponding author. The indication for the procedure was characteristic cervical spondylotic disease manifested by secondary canal stenosis. Patients had progressive neurological symptoms, bowel or bladder alterations, and failure of nonoperative management. None of the patients had ossification of the posterior longitudinal ligament, posttraumatic injuries, associated infective and tumorous pathology, and rheumatoid disease.

Three patients with ages ranging from 63 to 80 years presented with a history of progressively worsening neck pain, radiculopathy, and mild to moderate gait disturbance. Clinical history and neurological examination were consistent with myeloradiculopathy in all patients. All patients were evaluated using static and dynamic cervical spine radiography, computed tomography scanning, and magnetic resonance imaging (MRI). Static neutral lateral radiographs were used to assess cervical sagittal balance, whereas anteroposterior radiographs were used to exclude preoperative abnormal coronal alignment. All radiographic measurements were obtained with the neck in neutral position [Figure 1].

Cervical MRI demonstrated multilevel spondylosis resulting in moderate to severe bilateral foraminal stenosis at three cervical levels. The patients underwent a multilevel

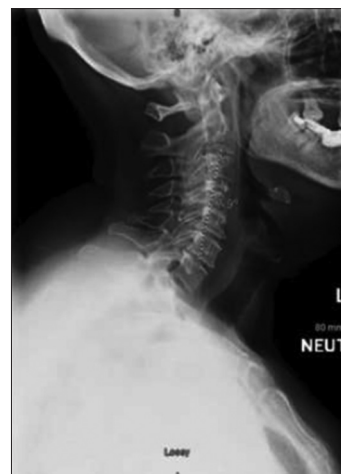

Figure 1: Preoperative lateral X-ray demonstrating multilevel spondylosis

posterior cervical laminectomy and instrumented fusion with intervertebral cages placed between bilateral facet joints from C4 to C7, C2 to C5, and C3 to C6, respectively. Oswestry disability index (ODI) and visual analog score (VAS) were collected preoperatively and at postoperative follow-up at 14 days, 6 months, and 12 months. Preoperative and postoperative images were analyzed for changes in cervical alignment and presence of arthrodesis [Figure 2].

The technique relied on a Mayfield head holder with the patients positioned prone on a Jackson table and the neck placed in neutral position. A midline approach was performed and the posterior elements were exposed. At this point, posterior cervical cages were placed in between the facet joints^[20] [Figure 3].

A high-speed burr was used to drill a trough between the junction of the lamina and the lateral mass. The lamina was removed *en bloc* with a Leksell Rongeur and the spinal cord was exposed. The lamina bone was ground down in a bone mill and used posterolaterally for autograft. In addition, 30cc of allograft chips was added posterolaterally [Figure 4].

RESULTS

At initial examination, all three patients had moderate neck pain (mean VAS 8/10) and cervical radiculopathy (mean VAS 8/10), mean ODI of 60%. Initial treatment was nonoperative for 6 months, including 6 weeks of physical therapy. They experienced no improvement in pain or function, and the next step was referral to pain management for cervical epidural steroid injections. The injections also failed to provide any symptomatic or functional improvement. Shortly thereafter, the symptoms progressed to include numbness and weakness

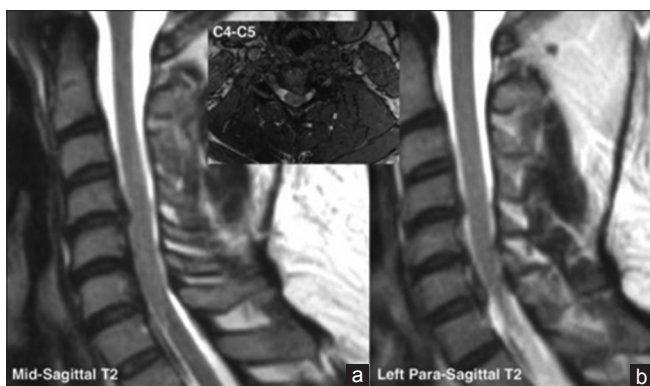


Figure 2: Midsagittal magnetic resonance imaging (a) demonstrating left C4–C5 paracentral disc herniation with spinal cord compression (inset). Parasagittal magnetic resonance imaging (b) demonstrating left C5–C7 foraminal stenosis and lateral recess stenosis dorsal to the vertebral body of C5 and C6

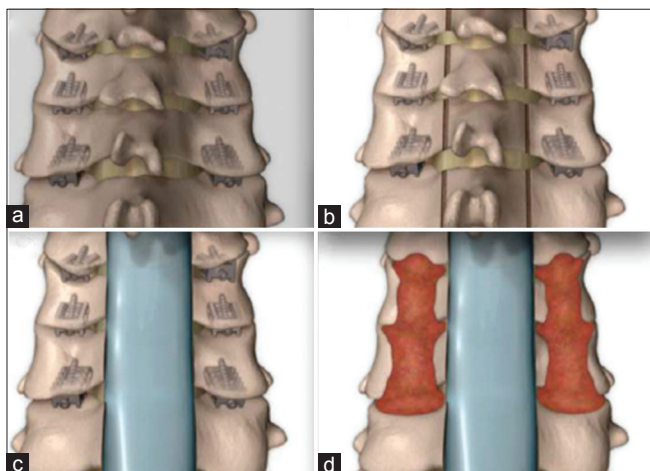


Figure 4: Illustration demonstrating surgical technique which starts with placement of the cervical cages (a), followed by drilling of the laminectomy trough (b), *en bloc* removal of the lamina (c), and placement of autograft posterolaterally (d)

in bilateral upper and lower extremities. Bladder and bowel function were normal [Figure 5].

All patients showed marked improvement in neurological symptoms and neck pain postoperatively. The patients achieved full recovery of bilateral upper and lower extremity function at 14 days postoperatively and reported a mean VAS arm score of 4/10, VAS neck score of 6/10, and mean ODI 40. They reported full resolution of radicular symptoms by 6 weeks postoperatively. At 6 months, the pain had markedly improved, with mean VAS arm score of 2/10, VAS neck score of 3/10, and ODI 28. Sagittal radiographs of the cervical spine revealed solid arthrodesis in all cases. At 12-month follow-up, the patients reported a mean ODI of 28, cervical VAS for neck of 2/10, arm of 1/10, and solid arthrodesis on X-rays. No kyphotic deformity, implant failure, or loosening was observed. No

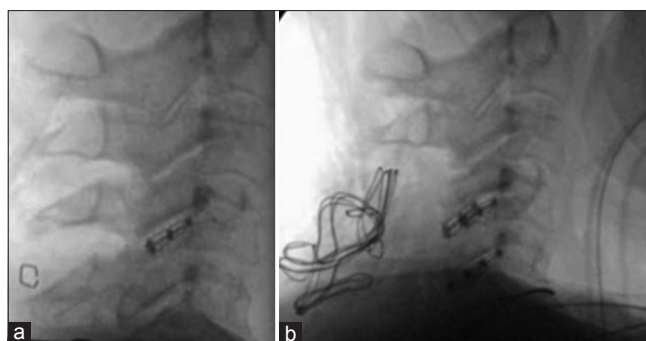


Figure 3: Lateral X-rays obtained intraoperatively demonstrate no change in cervical lordosis before (a) and after (b) placement of C5–C6 cage. The biggest determinant of postoperative alignment is cervical lordosis obtained in the Mayfield on the operative table

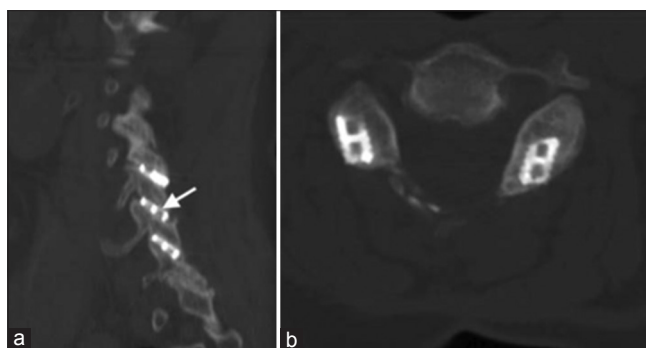


Figure 5: Sagittal computed tomography scan (a) of the cervical spine obtained 12 months after surgery demonstrating evidence of bridging bone (arrow) with no evidence of cage migration or subsidence. Axial computed tomography scan (b) of the cervical spine obtained 12 months after surgery demonstrating location of cervical cage in relationship to the facet joint

kyphotic deformity, implant failure, or loosening has been observed [Figure 6].

DISCUSSION

Surgical management of cervical spondylosis may be performed through the anterior, posterior, and combined (i.e., anterior and posterior) surgical approach.^[21] Pathology location, number of levels involved, cervical alignment, and degree of neck pain are some of the factors that influence approach selection. The alternative is posterior laminectomy or laminotomy/foraminotomy for lateral or foraminal discs, which could be performed through minimally invasive incisions. Cervical laminectomy can effectively decompress the spinal cord but carries the risk of postlaminectomy kyphosis, segmental instability, and neurological deterioration.^[22-24] Posterior laminoforaminotomy has proven to be effective for cervical mononeuropathy, with the advantage of maintaining stability and near-normal biomechanics.^[25,26] However, treatment of multilevel cervical spine myelopathy is subjected to several different considerations than single level disease.^[9]

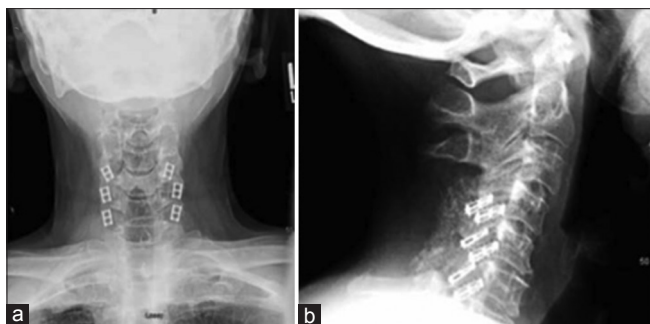


Figure 6: Anteroposterior (a) and lateral (b) cervical X rays obtained 12 months postoperatively demonstrating solid arthrodesis from C4 to C7. There was no change in cervical lordosis between 6 and 12 months

Conventionally, anterior approaches have been preferred for patients with one- or two-segment pathology and posterior techniques for patients with multisegmental involvement in the absence of kyphosis.^[9,27] The anterior approach may be particularly difficult in such cases and carries a subsequent risk of adjacent segment degeneration in the future. The advantages of the minimally invasive approach would be significantly reduced due to the wide exposure required.^[5] Furthermore, a multilevel ACDF may not achieve sufficient decompression of spinal cord. The technique optimally addresses compression secondary to disc herniation and osteophytes located at the posterior edges of vertebral body and the posterior longitudinal ligament.^[5] However, it is unable to address degenerative and enlarged facet joints which were present in this particular patient scenario. The alternative then would be a posterior multilevel laminectomy or laminotomy/foraminotomy.^[28] The drawback of posterior foraminotomy for root decompression is the technical difficulty when performed through minimal access incisions as well as the risk of axial neck pain and even instability as the segment is not stabilized. Furthermore, foraminotomy at C4-5 has been associated with motor palsies of the C-5 root. Posterior laminectomy with wide opening of the foraminal space would be favorable in this particular case, allowing decompression away from the offending pathology including osteophytes, ligaments, and discs. This would, however, require fusion which is usually achieved through posterior LMS fixation systems^[29] [Table 1].

Posterior cervical cages have shown comparable efficacy and safety to ACDF for treatment of single level cervical radiculopathy as well as foraminal stenosis.^[19,20] The cervical cage is a titanium cage designed to be placed into the cervical facets.^[10,11,30] By taking advantage of the inclination of the cervical facet in the transverse plane, the cage achieves indirect root decompression by opening the neural foramina. The distraction stabilizes the facet, while rasp and decorticator are used to promote definitive bone healing.

The biomechanical stability achieved by the construct is comparable to that of a posterior LMS systems.^[18]

Multilevel laminectomy increases the size of the spinal canal and allowed us to address cord compression. The choice of posterior cervical cage as opposed to LMSs to address the radiculopathy was multifactorial. Using LMSs would require performing foraminotomies to decompress the nerve roots. Performing such a procedure during laminectomy requires more extended bone removal of the cervical laminae at all 3 levels, which may compromise the bone stock required to achieve a stable fixation with LMS as well as it potentially distorts the visual landmarks for LMS entry points. The bone loss associated with foraminotomies along with the space occupied by LMS decreases the surface area available for bone graft placement increasing the risks of pseudoarthrosis. In the described technique, fewer implants are required to stabilize the treated levels (6 cages vs. 8 screws + rods + locking caps) significantly reducing the number of steps in the instrumentation part of the case. The risk of vertebral artery injury with cervical screws fixation must always be taken into consideration. The posterior cervical cage technique has not been associated with any vertebral artery injuries. Cervical laminectomy with the posterior cervical cage placement provides direct decompression of the central spinal canal and indirect decompression of the neural foramina and stabilizes the subaxial cervical spine while fusion takes place.

It is important to note that if the patient is placed in a Mayfield head-holder, as was the case with the patient in this case report, the cervical lordosis is dictated by head positioning in the Mayfield. Placement of cages will maintain the cervical lordosis obtained on the table without a kyphosis effect. This was demonstrated with intraoperative lateral X-rays. The final lordosis did not differ from immediate postoperative lordosis. Careful attention to preoperative cervical alignment is advised.

CONCLUSIONS

Combined laminectomy with posterior cervical cage application achieved safe and effective decompression of both central and foraminal stenosis, restoration of cervical stability, and subsequent bone fusion. This technique may have advantages over other techniques in decompression and stabilization of multilevel CSM with foraminal stenosis.

Financial support and sponsorship

Nil.

Conflicts of interest

Medical Director Providence Medical Technology.

Table 1: Reported complications of posterior cervical cage and posterior screw stabilization

	Author/Trial	Neurological complications	Vascular complications	Other complications
Posterior cervical cage	Dtrax n=169	1.81%	0	1.8%
Posterior screws stabilization	Moh'd ^[25] n=110	20.3%	0	8.5%
	Gordon ^[26] n=21	9.52%	0	8.5%
	Dhruv ^[27] n=198	17.2%	0	23.9%
	Mokbel ^[28] n=44	6.8%	0	0
	Hwang ^[29] n=32	0	0	12.5%
	Lali H. S ^[30] n=143	2.79%	0	13.28%
	Katonis ^[31] n=225	3.5%	0	0.8%
	Barbarawi ^[41] n=430	8.14%	0	3.25%
	Graham ^[42] n=21	14%	0	4.8%
	Abumji ^[43] n=180	1.7%	0.6%	2.22%
	Fehlings ^[44] n=44	0	0	27.3%
	Heller ^[45] n=78	5.1%	0	7.7%
	Levine ^[46] n=24	25%	0	29.2%
	Wellman ^[47] n=43	0%	0	9.3%

REFERENCES

- Brain WR, Northfield D, Wilkinson M. The neurological manifestations of cervical spondylosis. *Brain* 1952;75:187-225.
- Toledano M, Bartleson JD. Cervical spondylotic myelopathy. *Neurol Clin* 2013;31:287-305.
- Hofstetter CP, Wang MY. Diagnostic and therapeutic challenges of cervical myelopathy. *World Neurosurg* 2014;82:e173-5.
- Greenberg MS. Degenerative cervical disc disease and cervical myelopathy. In: *Handbook of Neurosurgery*. 8th ed., Ch. 71. New York, USA: Thieme; 2016.
- Caridi JM, Pumberger M, Hughes AP. Cervical radiculopathy: A review. *HSS J* 2011;7:265-72.
- Matz PG, Holly LT, Groff MW, Vresilovic EJ, Anderson PA, Heary RF, *et al*. Indications for anterior cervical decompression for the treatment of cervical degenerative radiculopathy. *J Neurosurg Spine* 2009;11:174-82.
- Ruetten S, Komp M, Merk H, Godolias G. Full-endoscopic cervical posterior foraminotomy for the operation of lateral disc herniations using 5.9-mm endoscopes: A prospective, randomized, controlled study. *Spine (Phila Pa 1976)* 2008;33:940-8.
- Suda K, Abumi K, Ito M, Shono Y, Kaneda K, Fujiya M. Local kyphosis reduces surgical outcomes of expansive open-door laminoplasty for cervical spondylotic myelopathy. *Spine (Phila Pa 1976)* 2003;28:1258-62.
- Lebl DR, Bono CM. Update on the diagnosis and management of cervical spondylotic myelopathy. *J Am Acad Orthop Surg* 2015;23:648-60.
- Goel A, Shah A. Facetal distraction as treatment for single- and multilevel cervical spondylotic radiculopathy and myelopathy: A preliminary report. *J Neurosurg Spine* 2011;14:689-96.
- Goel A. Facet distraction spacers for treatment of degenerative disease of the spine: Rationale and an alternative hypothesis of spinal degeneration. *J Craniovertebr Junction Spine* 2010;1:65-6.
- Goel A. Interfacetal intra-articular spacers: Emergence of a concept. *J Craniovertebr Junction Spine* 2016;7:72-4.
- Goel A, Shah A, Patni N, Ramdasi R. Immediate postoperative reversal of disc herniation following facetal distraction-fixation surgery: report of four cases. *World Neurosurg* 2016;94:339-44.
- Goel A. Facet distraction spacers for treatment of degenerative disease of the spine: Rationale and an alternative hypothesis of spinal degeneration. *J Craniovertebr Junction Spine* 2010;1:65-6.
- Goel A. Facet distraction-arthrodesis technique: Can it revolutionize spinal stabilization methods? *J Craniovertebr Junction Spine* 2011;2:1-2.
- Siemionow K, Janusz P, Phillips FM, Youssef JA, Isaacs R, Tyrakowski M, *et al*. Clinical and radiographic results of indirect decompression and posterior cervical fusion for single-level cervical radiculopathy using an expandable implant with 2-year follow-up. *J Neurol Surg A Cent Eur Neurosurg* 2016;77:482-8.
- Voronov LI, Siemionow KB, Havey RM, Carandang G, Phillips FM, Patwardhan AG. Bilateral posterior cervical cages provide biomechanical stability: Assessment of stand-alone and supplemental fixation for anterior cervical discectomy and fusion. *Med Devices (Auckl)* 2016;9:223-30.
- Voronov LI, Siemionow KB, Havey RM, Carandang G, Patwardhan AG. Biomechanical evaluation of DTRAX(®) posterior cervical cage stabilization with and without lateral mass fixation. *Med Devices (Auckl)* 2016;9:285-90.
- Siemionow K, Janusz P, Glowka P. Cervical cages placed bilaterally in the facet joints from a posterior approach significantly increase foraminal area. *Eur Spine J* 2016;25:2279-85.

20. McCormack BM, Bundoc RC, Ver MR, Ignacio JM, Berven SH, Eyster EF. Percutaneous posterior cervical fusion with the DTRAX Facet System for single-level radiculopathy: Results in 60 patients. *J Neurosurg Spine* 2013;18:245-54.
21. Odate S, Shikata J, Kimura H, Soeda T. Hybrid decompression and fixation technique versus plated three-vertebra corpectomy for four-segment cervical myelopathy. *J Spinal Disord Tech* 2013;29:226-33. [Doi: 10.1097/bsd.0b013e31827ada34].
22. Dai L, Ni B, Yuan W, Jia L. Radiculopathy after laminectomy for cervical compression myelopathy. *J Bone Joint Surg Br* 1998;80:846-9.
23. Guigui P, Benoist M, Deburge A. Spinal deformity and instability after multilevel cervical laminectomy for spondylotic myelopathy. *Spine (Phila Pa 1976)* 1998;23:440-7.
24. Lonstein JE. Post-laminectomy kyphosis. *Clin Orthop Relat Res* 1977;28:93-100.
25. Zdeblick TA, Zou D, Warden KE, McCabe R, Kunz D, Vanderby R. Cervical stability after foraminotomy. A biomechanical *in vitro* analysis. *J Bone Joint Surg Am* 1992;74:22-7.
26. Heary RF, Ryken TC, Matz PG, Anderson PA, Groff MW, Holly LT, *et al.* Cervical laminoforaminotomy for the treatment of cervical degenerative radiculopathy. *J Neurosurg Spine* 2009;11:198-202.
27. Lawrence BD, Brodke DS. Posterior surgery for cervical myelopathy: Indications, techniques, and outcomes. *Orthop Clin North Am* 2012;43:29-40, vii-viii.
28. Dodwad SJ, Dodwad SN, Prasarn ML, Savage JW, Patel AA, Hsu WK. Posterior cervical foraminotomy: Indications, technique, and outcomes. *Clin Spine Surg* 2016;29:177-85.
29. Khuyagbaatar B, Kim K, Park WM, Kim YH. Effect of posterior decompression extent on biomechanical parameters of the spinal cord in cervical ossification of the posterior longitudinal ligament. *Proc Inst Mech Eng Part H* 2016;230:545-52.
30. Shah A. Morphometric analysis of the cervical facets and the feasibility, safety and effectiveness of Goel inter-facet spacer distraction technique. *J Craniovertebr Junction Spine* 2014;5:9-14.