

Case Report

# Successful cataract surgery in a patient with refractory Wegener's granulomatosis effectively treated with rituximab: A case report



Abdullah M. Alfawaz\*

## Abstract

Wegener's granulomatosis is a granulomatous disorder associated with systemic necrotizing vasculitis. Eye involvement occurs in approximately 50% of Wegener's granulomatosis patients and is an important cause of morbidity. Conventional treatment-related morbidity and failure have led to studies of alternative treatment modalities. In this case of a 35-year-old man with severe Wegener's granulomatosis, conventional therapy failed to induce remission. Despite the standard immunosuppressive therapy, progression of the disease was observed, mainly with ocular manifestations and renal impairment. Rituximab was given intravenously and led to remission of both systemic and ocular manifestations of the disease. After 1 year of disease quiescence, he was admitted one week after his third regularly-scheduled rituximab treatment and was started on intravenous methylprednisolone, 500 mg/day for 3 days, before cataract surgery. Subsequently, the patient underwent phacoemulsification cataract surgery in his left eye. Six months later, in the same manner he underwent uneventful phacoemulsification cataract surgery in the right eye with a favorable outcome in both eyes. Conclusion: In this patient, rituximab was a well-tolerated and effective remission induction agent for severe refractory Wegener's granulomatosis and led to successful cataract surgery.

**Keywords:** Anti-CD20 antibodies, Cataract, Uveitis, Rituximab, Wegener's, Granulomatosis

© 2016 The Author. Production and hosting by Elsevier B.V. on behalf of Saudi Ophthalmological Society, King Saud University. This is an open access article under the CC BY-NC-ND license (<http://creativecommons.org/licenses/by-nc-nd/4.0/>). <http://dx.doi.org/10.1016/j.sjopt.2016.02.002>

## Introduction

Wegener's granulomatosis (WG) is a primary systemic small-vessel vasculitis with eye, respiratory tract, and kidney involvement.<sup>1</sup> B lymphocytes are important for the regulation of immune responses and production of antibodies. B cells function as antigen-presenting cells, express costimulatory molecules, produce cytokines, and regulate the differentiation and activation of T lymphocytes. The role of B cells in the pathogenesis of autoimmune diseases including WG is well-established.<sup>2</sup> Rituximab is a chimeric monoclonal antibody directed against CD20, a cell surface protein expressed

almost exclusively on B cells.<sup>3</sup> Binding of rituximab to CD20 results in the selective depletion of B cells by a variety of mechanisms.<sup>4</sup> Hence, rituximab has become an important component of standard treatment regimens for non-Hodgkin's B-cell lymphoma.<sup>5</sup> Because B cells play an important role in autoimmune diseases,<sup>6</sup> rituximab is increasingly being investigated as a therapeutic agent for these indications. Early reports of its successful use in autoantibody-mediated autoimmune diseases were followed by promising results in multisystem autoimmune diseases such as rheumatoid arthritis. In a report of 10 patients with ocular and orbital WG, the authors found that intravenous infusions of

Received 3 August 2015; received in revised form 2 November 2015; accepted 9 February 2016; available online 15 February 2016.

Department of Ophthalmology, College of Medicine, King Saud University, Riyadh, Saudi Arabia

\* Address: Department of Ophthalmology, College of Medicine, King Saud University, PO Box 245, Riyadh 11411, Saudi Arabia.  
e-mail address: [idr\\_alfawaz@yahoo.com](mailto:idr_alfawaz@yahoo.com)



Peer review under responsibility of Saudi Ophthalmological Society, King Saud University



Production and hosting by Elsevier

Access this article online:  
[www.saudiophthaljournal.com](http://www.saudiophthaljournal.com)  
[www.sciencedirect.com](http://www.sciencedirect.com)

rituximab can lead to the induction of long-term remission.<sup>7</sup> In the present case report of an individual with ocular and generalized WG who failed conventional treatment, administration of rituximab led to a complete control of the disease.

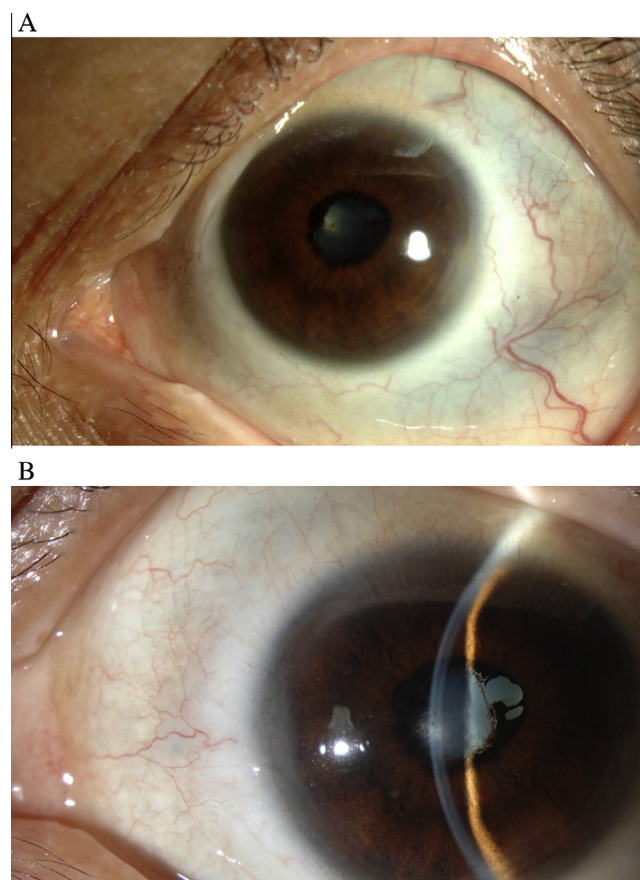
### Case report

A 35-year-old man presented with complaints of poor vision in his right eye for the previous eight months. His eye symptoms started with a gradual painless reduction of vision for which he was seen at another institute and diagnosed as having a choroidal mass for investigations. When he came to our hospital his best-corrected visual acuity was 20/200 in the right eye and 20/60 in the left eye. Intraocular pressure (IOP) was 17 mmHg in each eye and generalized scleral thinning was occurring in both eyes without inflammation or active necrosis. Conjunctiva was normal in both eyes, the anterior chamber showed 1+ cells and 1+ flare in both eyes, and there was 360° posterior synechia in the right eye. The patient had a dense white cataract in the right eye with no view to the retina and an immature posterior subcapsular cataract in the left eye. Fundus examination of the left eye showed a normal optic nerve and mild choroidal folds. Ultrasonography of the right eye showed mild macular elevation but was otherwise normal. Laboratory studies showed high plasma levels of urea and creatinine (14.2 mmol/L and 156 µmol/L respectively) and the presence of circulating cytoplasmic anti-neutrophilic cytoplasmic antibodies (c-ANCA).

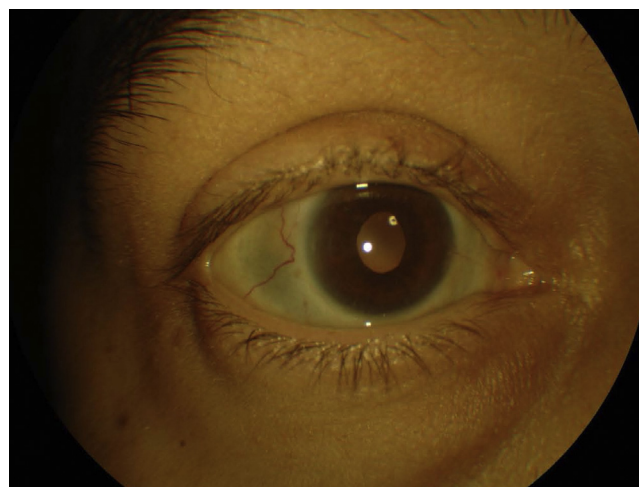
The patient was admitted to complete his workup. During hospitalization he was diagnosed with WG, renal failure, and eye involvement. A kidney biopsy revealed necrotizing and crescentic glomerulonephritis. A lung biopsy confirmed the diagnosis by showing granulomatous inflammation with extensive necrosis and vasculitis. The patient was started on oral prednisolone 50 mg (0.75 mg/kg) and cyclophosphamide 100 mg (1.5 mg/kg) once-daily. After 1 month of treatment, no improvement was observed. The patient was then treated with rituximab (MabThera; Hoffmann-La Roche, Basel, Switzerland) in 2 intravenous doses of 1 g each, given 2 weeks apart and repeated at 6 month intervals, supplemented with daily oral prednisolone 10 mg. After initiation of this treatment regimen, the patient exhibited complete resolution of his symptoms and WG was in clinical remission.

After complete remission for one year, the patient reported poor vision in both eyes. His visual acuity in the right eye was counting finger near face and 20/200 in the left eye. Slit-lamp examination revealed quiet eyes and IOP was 14 mm Hg in each eye. There was no view to the fundus in the right eye, and the left eye showed a normal optic nerve and an early epiretinal membrane (Fig. 1A and B). The patient was admitted one week after his third regularly-scheduled rituximab treatment and was started on intravenous methylprednisolone, 500 mg/day for 3 days (half the usual dose given in uveitis patients because of his kidney status) before cataract surgery. On the second day, he underwent release of posterior synechia, phacoemulsification with clear corneal incision, and implantation of posterior chamber intraocular lens in the left eye. On the first day postoperatively, the patient's visual acuity in the left eye improved to 20/60 with no activation of scleritis or uveitis. The vision did not improve completely because of macular dragging and a thick epiretinal membrane. Six months later immediately after his fourth

dose, the patient underwent uneventful phacoemulsification cataract surgery in the right eye with coverage by intravenous methylprednisolone, 500 mg/day for 3 doses. Six months after the second eye surgery his best-corrected visual acuity was 20/60 in the right eye and 20/30 in the left eye, after being on rituximab infusion every 6 months and azathioprine (imuran) 25 mg daily (Fig. 2). Based on the quiescence



**Figure 1.** A and B: Preoperative photographs of the left eye with scleral thinning, posterior synechia and cataract.



**Figure 2.** Postoperative photograph of the right eye showing quiet eye with intraocular lens.

of both ocular and systemic manifestations, the patient was able to stop rituximab infusions and was maintained on 5 mg oral steroid without any exacerbation of disease for eight months.

## Discussion

This is a case of a male patient with a severe form of WG who had impairment of vision secondary to cataract and choroidal granuloma and responded well to systemic rituximab infusion. One long-term study of WG patients found that 52% of them developed ophthalmologic disease, and 8% of the patients had disease-related vision loss.<sup>8</sup> WG may affect any part of the eye and WG-related eye pathologies frequently manifest as a component of a multisystem presentation.<sup>9</sup> They often occur secondary to contiguous granulomatous sinus or nasal disease, and patients may present with proptosis, obstruction of the nasolacrimal duct, ocular muscle involvement, or optic neuropathy. In a study of 140 WG patients, Bullen and colleagues noted ocular disease in 29% of cases (40/140). Orbital disease was the most common manifestation (18/140, 15%), followed by scleral (7%) and episcleral (3.5%) involvement.<sup>10</sup>

It is crucial to recognize that any signs of ocular inflammation in a patient with WG may indicate active disease in other organs. Therefore, thorough clinical and laboratory examinations should be performed to determine the extent of the disease.<sup>9</sup>

Patients with WG can initially present with various ophthalmologic manifestations. Hoffman et al. reported scleritis as the most common presenting ophthalmologic manifestation, occurring in approximately 10% of WG patients.<sup>8</sup> The ophthalmologist may make an initial diagnosis of WG in patients who present with ocular complaints or patients who have undiagnosed systemic involvement in addition to their ocular disease.<sup>11</sup> In our patient, the ocular manifestations were the presenting complaints which preceded the systemic manifestations by several months. Retinal and choroidal involvements in WG seem to be rare.<sup>8</sup> In Bullen's study, 2.9% of patients had retinitis and one had a branch venous obstruction.<sup>9</sup> Sclero-choroidal granulomas may mimic the appearance of a uveal melanoma.<sup>12</sup> Choroidal folds, choroidal effusions, or an exudative retinal detachment may be seen in association with chorioretinal granulomas or posterior scleritis.<sup>9</sup> Our patient initially presented to ophthalmic emergency and was found to have a choroidal mass, thought to be choroidal melanoma, in his right eye. Subsequently he had bouts of bilateral low-grade anterior uveitis, which was managed with topical anti-inflammatory medications. Uveitis is an uncommon manifestation in WG patients. It was the least common form of ocular involvement in patients with WG in Bullen's study (4/140, 2.9%).<sup>10</sup> Anterior, posterior, or pan-uveitis may be present in WG patients. Rarely, uveitis may be the initial manifestation, followed by active inflammation in surrounding structures.<sup>13</sup>

Other important systemic features in WG patients include pyrexia, weight loss, recurrent epistaxis, sinus discharge, hemoptysis, peripheral neuropathy, cerebral vasculitis, and renal failure (the major cause of death). Our patient had severe renal impairment which was irreversible even after the initiation of rituximab treatment. His treatment course suggests

that the early use of rituximab in patients with severe WG is recommended to prevent irreversible systemic and ocular damage.<sup>14</sup>

Cataract development in WG patients is reported to be as common as 28%.<sup>15</sup> Its causes include uveitis and use of topical or systemic steroids. Literatures are lacking for studies discussing cataract surgery in WG patients and its outcome. Successful treatment of ocular involvement or complications of WG are dependent on treatment of the underlying disease with systemic immunomodulators. Precautions should be taken to achieve favorable outcomes after cataract surgery. These precautions should include quiescence of ocular inflammation for a period of at least three months before surgery. In addition, one may use periocular steroids immediately before and after surgery. Avoiding scleral manipulation is important to prevent activating scleral inflammation. Clear corneal incision phacoemulsification is a better option than extracapsular cataract extraction. In our patient all of these measures were taken, plus timing the surgery to be within one week of rituximab infusion. It seems that all of these factors led to a favorable outcome in both eyes without exacerbation of the disease.

In conclusion, this case showed that intravenous infusions of rituximab can induce long-term remission in refractory ophthalmic WG. Rituximab-mediated clinical remission allows for safe and successful surgical intervention.

## Declaration of interest

The author reports no conflict of interest.

## Acknowledgments

The author thanks Dr. Mohammed Omair from the Rheumatology department in King Saud University for helping with the management of the patient. Also, the author would like to thank Ms. Priscilla M.W. Gikandi from the Ophthalmology Research Unit for formatting the manuscript.

## References

- Jennette JC, Falk RJ, Andrassy K, et al. Nomenclature of systemic vasculitides. Proposal of an international consensus conference. *Arthritis Rheum* 1994;**37**:187–92.
- Martin F, Chan AC. Pathogenic roles of B cells in human autoimmunity; insights from the clinic. *Immunity* 2004;**20**:517–27.
- Tedder TF, Engel P. CD20: a regulator of cell-cycle progression of B lymphocytes. *Immunol Today* 1994;**15**:450–4.
- Uchida J, Hamaguchi Y, Oliver JA, et al. The innate mononuclear phagocyte network depletes B lymphocytes through Fc receptor-dependent mechanisms during anti-CD20 antibody immunotherapy. *J Exp Med* 2004;**199**:1659–69.
- Silverman GJ, Weisman S. Rituximab therapy and autoimmune disorders: prospects for anti-B cell therapy. *Arthritis Rheum* 2003;**48**:1484–92.
- Davidson A, Diamond B. Autoimmune diseases. *N Engl J Med* 2001;**345**:340–50.
- Taylor SR, Salama AD, Joshi L, et al. Rituximab is effective in the treatment of refractory ophthalmic Wegener's granulomatosis. *Arthritis Rheum* 2009;**60**:1540–7.
- Hoffman GS, Kerr GS, Leavitt RY, et al. Wegener granulomatosis: an analysis of 158 patients. *Ann Intern Med* 1992;**116**:488–98.
- Tarabishy AB, Schulte M, Papaliodis GN, et al. Wegener's granulomatosis: clinical manifestations, differential diagnosis, and management of ocular and systemic disease. *Surv Ophthalmol* 2010;**55**:429–44.

10. Bullen CL, Liesegang TJ, McDonald TJ, et al. Ocular complications of Wegener's granulomatosis. *Ophthalmology* 1983;**90**:279–90.
11. Harper SL, Letko E, Samson CM, et al. Wegener's granulomatosis: the relationship between ocular and systemic disease. *J Rheumatol* 2001;**28**:1025–32.
12. Janknecht P, Mittelviehhaus H, Loffler KU. Sclerochoroidal granuloma in Wegener's granulomatosis simulating a uveal melanoma. *Retina* 1995;**15**:150–3.
13. Samuelson TW, Margo CE. Protracted uveitis as the initial manifestation of Wegener's granulomatosis. *Arch Ophthalmol* 1990;**108**:478–9.
14. Lim KS, Lee GA, Pavesio CE, et al. Wegener's granulomatosis. *Br J Ophthalmol* 2003;**87**:500.
15. Kamali S, Erer B, Artim-Esen B, et al. Predictors of damage and survival in patients with Wegener's granulomatosis: analysis of 50 patients. *J Rheumatol* 2010;**37**:374–8.