

Available online at www.sciencedirect.com

ScienceDirect

journal homepage: www.elsevier.com/locate/radcr

Case Report

A diffuse granulomatous inflammation secondary to a trauma of hand: a case report. ☆☆☆★

Sui Zheng, BSc, Jiagang Wang, MD, Zhongyuan Ji, BSc*

Department of Ultrasound, Shantou Central Hospital, Shantou, Guangdong, China

ARTICLE INFO

Article history:

Received 1 May 2021

Revised 15 May 2021

Accepted 15 May 2021

Keywords:

Granulomatous Disease

Wrist

Magnetic Resonance Imaging

Ultrasonography

ABSTRACT

Granulomatous inflammation is rare in the musculoskeletal system and difficult to diagnose. Here we describe a case of a 62-year-old woman with a history of being stabbed by a fishbone presented with a soreness, swelling, and limitation of movement of her right palm and wrist for 4 months. Surgery was done and the histopathology of specimens demonstrated granulomatous lesion, which was negative for acid-fast bacilli. This case demonstrates the diagnosis of granulomatous tenosynovitis on MRI, ultrasound, and surgical examination under anesthesia.

© 2021 The Authors. Published by Elsevier Inc. on behalf of University of Washington.

This is an open access article under the CC BY-NC-ND license

(<http://creativecommons.org/licenses/by-nc-nd/4.0/>)

Introduction

Granulomatous inflammation is a special type of chronic hyperplastic inflammation which is rare in the musculoskeletal system. The most common types of granulomatous inflammation in the musculoskeletal system include foreign body granuloma and infectious granuloma, such as tuberculosis bacillus, etc. [1,2]. A superficial palpable mass with or without pain is frequently seen as the initial sign or symptom. As the onset is gradual, some patients may present with carpal tunnel syndrome or worst. The correct diagnosis and treatment plan is vital to prevent delay in diagnosis and treatment with its attendant complications [3].

Case report

A 62-year-old woman was referred to the hand surgeon suffering from soreness, swelling, and limitation of movement of her right palm and wrist that had been present for 4 months. She had a history of being stabbed by a fishbone 6 months ago. She was diagnosed as tenosynovial giant cell tumor by magnetic resonance imaging (MRI) examination in the local hospital and treated with traditional Chinese medicine. The symptoms were not diminished but took a turn for the worse in the last 2 months.

She had neither respiratory symptoms nor a history of any skin disorders. There was no family history of inflammatory

☆ Acknowledgement: This research did not receive any specific grant from funding agencies in the public, commercial, or not-for-profit sectors.

☆☆ Funding: This research did not receive any specific grant from funding agencies in the public, commercial, or not-for-profit sectors.

★ Competing Interest: The authors declare that they have no conflict of interest.

* Corresponding Author.

E-mail address: 13502980145@163.com (Z. Ji).

<https://doi.org/10.1016/j.radcr.2021.05.040>

1930-0433/© 2021 The Authors. Published by Elsevier Inc. on behalf of University of Washington. This is an open access article under the CC BY-NC-ND license (<http://creativecommons.org/licenses/by-nc-nd/4.0/>)

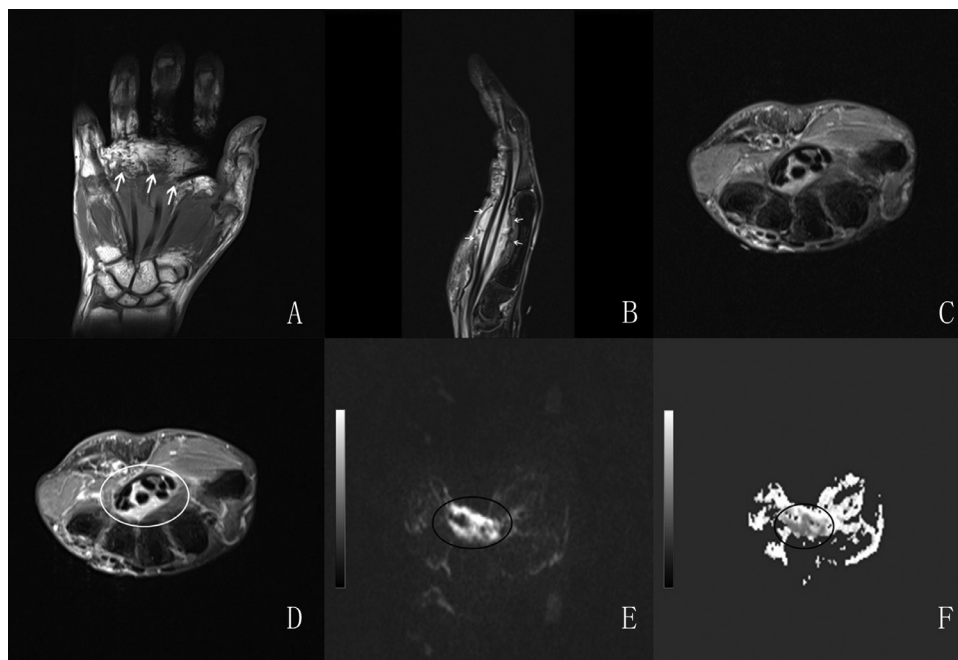


Fig. 1 – Magnetic resonance images of the right wrist and hand: (A) Coronal T1-weighted image demonstrates a slightly decreased signal intensity tissue lesion surrounding the flexor tendon(arrowheads). (B) Sagittal, T2-weighted, demonstrating the increased signal within the lesion(arrowheads). (C) Pre-contrast and (D) post-contrast axial proton density images at the level of the right wrist joints demonstrate a overall and homogeneous enhancement of the lesion in the carpal tunnel(circle). (E) Coronal DWI shows that some lesions were diffused and limited. (F) ADC shows slightly decreased or decreased signal of lesion.

arthritis or psoriasis. She denied a history of recent travel or exposure to tuberculosis.

On admission, physical examination revealed swelling, tenderness, limitation of movement of right palm and fingers, without percussion pain or palpable bone friction or bone friction sensation. Physiological reflexes existed and pathological reflex was not drawn out.

Pertinent laboratory data were within normal range including leukocyte, C-reactive protein (CRP) and erythrocyte sedimentation rate (ESR). Her rheumatoid factor was negative.

Non-contrast MRI of right hand demonstrated that patchy abnormal signal around the deep flexor tendon and carpal canal of each finger concerning for synovial proliferative lesions, presenting as hypointense in T1-weighted imaging and hyperintense in proton density weighted imaging-fat suppression (PDWI-FS) sequence. Post-contrast images showed homogeneous enhancement uptake in the tendons in question and the surrounding synovial membrane, supporting the diagnosis of synovial hyperplasia. While proton density weighted imaging (DWI) and apparent diffusion coefficient (ADC) suggested restricted diffusion so that tumor lesions remained to be ruled out. The median nerve was compressed and deformed slightly. Degenerative changes of some bones were seen in the right hand (Fig. 1).

Ultrasonography (USG) of the right hand showed that the surface of the bone of the wrist was rough, thickened and decreased echogenicity with irregular shape and unclear boundary of the metacarpophalangeal joints, proximal interphalangeal joints, wrists as well as tendons including flexor polli-

cis longus, superficial flexor muscle tendon and deep flexor muscle of the right finger were observed. The lesion of the middle finger continued to the level of the distal phalanx of the middle finger, while the decrease echogenicity around the other tendons continued to the level of the metacarpophalangeal joint. It showed peripheral and internal flow on color Doppler assessment. Besides, the flexor retinaculum raised about 3.8mm at the level of the proximal carpal canal. The median nerve had a deformity as a result of its compression, the anterior and posterior diameter of the smallest part was about 1.8mm, while it was 2.3mm of the non-compressed segment (Fig. 2).

Based on imaging figures, the preliminary diagnoses of degenerative arthritis, synovitis, tenosynovitis and atypical carpal tunnel syndrome were considered. The differential diagnosis included neoplastic lesion. Surgical enucleation of the lesion was then performed, with brachial plexus anesthesia. Surgical access was performed through a linear incision in the right wrist. A large amount of white hyaline synovitis tissue was seen under the skin, which was removed. Exposing the right palmar longus tendon then pulling the right palmar longus tendon and radial carpal flexor muscle to both sides, the transverse carpal ligament was exposed. The flexor retinaculum longitudinally which was slightly thickened and widened was cut. The mass was seen around the flattened median nerve. After removing it, separating the adhesion and releasing the adventitia of the median nerve, the lesions could still be detected at the proximal end of the palm, especially in the intermuscular space and the tendons of the

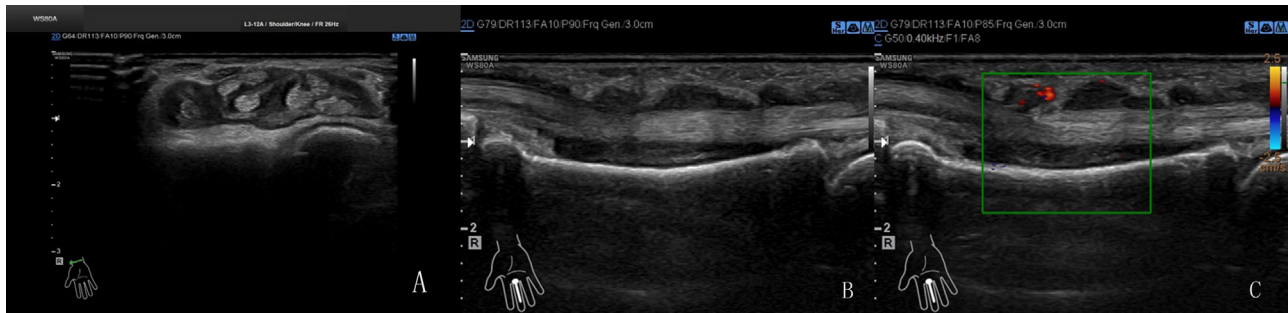


Fig. 2 – Ultrasonic images of the wrist and hand: (A) Axial grey-scale image at the level of wrist joint demonstrates thickened and decreased echogenicity surrounding the tendons in the carpal tunnel and the median nerve had a deformity as a result of compression. (B) Longitudinal US images showing the synovitis and tenosynovitis of the distal phalanx of the middle finger with peripheral and internal flow on (C) color Doppler assessment.

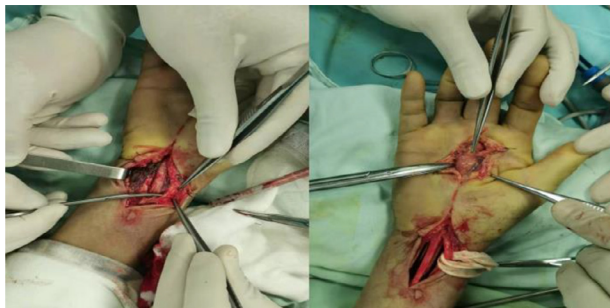

Fig. 3 – Surgical access was performed through a linear incision in the right wrist.

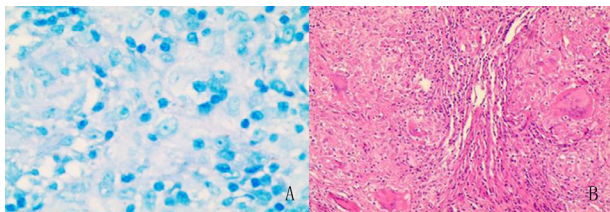


Fig. 4 – (A) Histological view under microscope considering granulomatous lesion (at 100x). (B) acid-fast bacilli was negative (at 400x).

third metacarpal bone (Fig. 3). After thorough dissection, the wound was sutured layer-by-layer and covered with an aseptic bandage. The specimen was sent for histopathologic examination and culture. Its histopathology demonstrated granulomatous lesions and which were acid-fast stain negative (Fig. 4). After the operation, clinical symptoms of the patient were markedly improved and after 2 months has had no recurrence of carpal tunnel syndrome or synovitis of the wrist (Figs. 5 and 6).

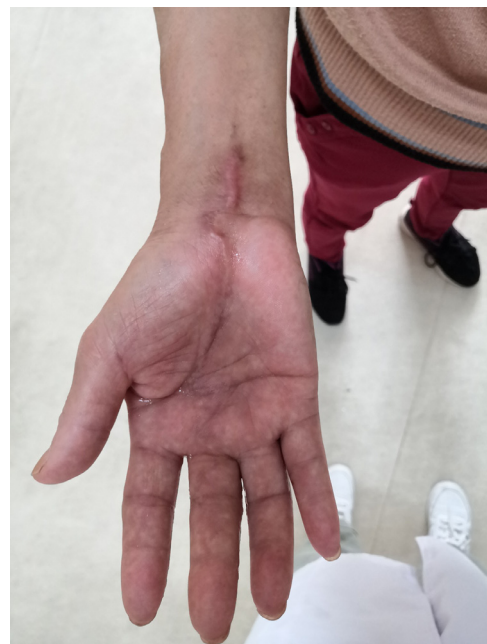

Fig. 5 – Postoperative view of the hand after 2 months.

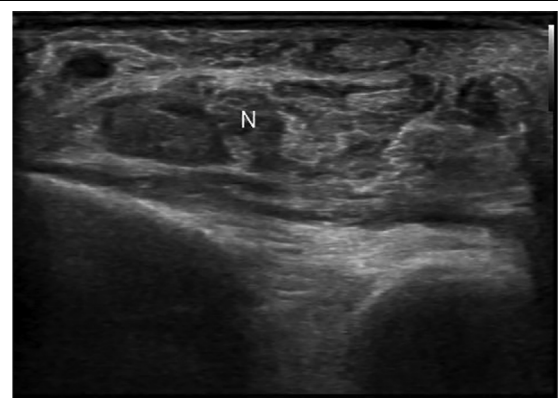


Fig. 6 – Ultrasonic image of wrist showing no recurrence of the median nerve ("N") compression or synovitis at the level of wrist joint.

Discussion

Granulomatous inflammation is a special type of chronic hyperplastic inflammation which is rare in the musculoskeletal system. Granulomatous tenosynovitis also called “fish-tank granuloma” was first described in patients using swimming pools [3]. The aspect of granulomatous inflammation predominated with nodules or large zones formed from histiocytes, epithelioid cells and other cells (especially lymphocytes, plasma cells, and fibroblasts) [4]. The most common types of granulomatous inflammation in the musculoskeletal system include foreign body granuloma and infectious granuloma, such as tuberculosis bacillus, typhoid bacillus, *Treponema pallidum*, fungi, etc. [1,2]. While noninfectious causes include sarcoidosis and chronic tophaceous gout, etc. [5].

A superficial palpable mass with or without pain is frequently seen as the initial sign or symptom. As the onset is gradual, some patients may present with carpal tunnel syndrome. Thickening of the involved tendon with increasing color Doppler signal and enhancement of the involved tendon sheaths and the common sign presents in US and MRI. These changes may extend to the adjacent bone and periarticular soft tissue. MRI can observe the size, shape, site of the lesion and the condition of adjacent organizations, while ultrasound of musculoskeletal is developing rapidly at present which can examine in multiple sections in different positions, is better in the observation of fine structures [6,7]. Combined diagnosis of ultrasound and MRI can reflect the pathological and histological changes of granulomatous inflammation to a certain extent, and greatly improve the diagnostic accuracy [8,9]. The challenge is that this condition is difficult to diagnose due to the complexity of histology, the diversity of morphology, the diversity of pathogenic factors and its clinically insidious onset as well as the presentation, laboratory analysis, imaging (MRI, US) and microbiology are useful to help reach a diagnosis, but finally confirmation is from histopathology [13].

Here we present a case of a 62-year-old female with a history of being stabbed by a fishbone. The lesion involves a rare wide range including tendons of wrists, proximal interphalangeal joints, metacarpophalangeal joints, even the distal phalanx of the middle finger. Foreign body granulomatous inflammation should be considered first based on the history. Secondly, tuberculous tenosynovitis as a relatively common type should also be taken into account.

Foreign bodies, such as wooden splinters, etc., occur frequently in children. If the foreign body is not removed timely, or is not phagocytosed during the acute inflammatory reaction, it will be encapsulated with fibrous tissue resulting in a granuloma [10]. The foreign bodies may be shown in examination Imaging (MRI, ultrasonography, X-ray).

Tuberculous tenosynovitis is rare which affects the wrist and hand and accounts for 5% of musculoskeletal tuberculosis cases. The mechanism of the infection may be direct inoculation or hematogenous spread from a primary lesion such as lungs, spine, and lymph nodes. Most tuberculous tenosynovitis were found in the flexor side and ulnar border [11-13]. The disease progresses include 3 histopathological stages. In the first place, the tendon is replaced by granulation tissue. Subsequently, the sheath is obliterated by fibrous tissue,

following the appearance of rice or melon bodies as a result of caseation. Finally, extensive caseation and tendon rupture. The progress depends on the duration, the virulence of pathogen, and the interaction of pathogen with its host [14-17]. Rice or melon bodies, consisting of fibrous masses, considered to be due to micro-infarction following inflammation and ischemia of the synovial sheath, are present in about 50% of cases [18-21]. On account of the low sensitivity and specificity of laboratory investigations such as ESR, CRP are low for diagnosis of tuberculous tenosynovitis, the condition cannot be excluded when these results are normal [18,22]. Ultrasound images show thickening or granuloma of the involved tendon with increasing color Doppler signal. Cyst-like lesions (high signal on T2WI) with diaphysis expansion and bone sequestration, as well as tendon sheath enhancement are presented in MRI. Confirmation is from the open biopsy and culture of the histopathological specimen. Characteristic findings of histopathology include caseous granulomas, tuberculosis bacillus, and multinucleated Langerhans giant cells [23].

However, based on the ancillary examinations, intraoperative findings, and postoperative pathology, neither of these diagnoses of the considerations mentioned above is likely to be correct. Due to the lack of understanding of this disease and the choice of patient and surgeon, we did not further culture the specimen to explore the real pathogenic factors, which is the limitation of this case.

For granulomatous inflammation involving the musculoskeletal system, we suggest conservative treatment first. In this case, the patient received the therapy of traditional Chinese medicine but the symptoms got worse. Surgical treatment should be performed without delay if conservative treatment fails or carpal tunnel syndrome happens [24]. Certainly, if the pathological examination is completed and the pathogen culture results are obtained, the follow-up treatment according to the above results should be conducted.

Patient Consent

Informed consent: Informed consent was obtained from the patient.

Consent for written: Consent for written was obtained from the patient.

Consent for publication: Consent for publication was obtained from the patient.

REFERENCES

- [1] Khalbuss WE, Michelow P, Benedict C, Monaco SE, Pantanowitz L. Cytomorphology of unusual infectious entities in the Pap test. *Cytojournal* 2012;9:15.
- [2] Brito AC, Bittencourt MJS. Chromoblastomycosis: an etiological, epidemiological, clinical, diagnostic, and treatment update. *An Bras Dermatol* 2018;93(4):495–506.
- [3] Swift S, Cohen H. Granulomas of the skin due to *Mycobacterium balnei* after abrasions from a fish tank. *Eng J med* 1962;267:1244–6.

- [4] Tan JN, Mohd Saffian S, Buang F, Jubri Z, Jantan I, Husain K. Mohd Fauzi N: Antioxidant and anti-inflammatory effects of genus *Gynura*: A systematic review. *Front Pharmacol* 2020;11:504624.
- [5] Schwartz DA. Sporothrix tenosynovitis—differential diagnosis of granulomatous inflammatory disease of the joints. *J Rheumatol* 1989;16(4):550–3.
- [6] Jardin E, Delord M, Aubry S, Loisel F, Obert L. Usefulness of ultrasound for the diagnosis of pyogenic flexor tenosynovitis: A prospective single-center study of 57 cases. *Hand Surg Rehabil* 2018;37(2):95–8.
- [7] Tamborrini G, Backhaus M, Schmidt W, Ziswiler HR. [Ultrasound and arthritis]. *Z Rheumatol* 2010;69(10):889–901 quiz 902.
- [8] Al-Ani Z, Oh TC, Macphie E, Woodruff MJ. Sarcoid tenosynovitis, rare presentation of a common disease. Case report and literature review. *J Radiol Case Rep* 2015;9(8):16–23.
- [9] Platzgummer H, Schueller-Weidekamm C. [Radiological imaging in early diagnosis of rheumatoid arthritis. The role of ultrasound and magnetic resonance imaging]. *Radiologe* 2012;52(2):124–31.
- [10] Borgia CA. An unusual bone reaction to an organic foreign body in the hand. *Clin Orthop Relat Res* 1963;30:188–93.
- [11] Fnini S, Ouara M, Rafai M, Cohen D, Largab A, Trafeh M. [An uncommon occupational accident: tuberculous tenosynovitis of the extensor tendons of the hand]. *Chir Main* 1999;18(4):309–12.
- [12] Al-Qattan MM, Al-Namla A, Al-Thunayan A. Al-Omawi M: Tuberculosis of the hand. *J Hand Surg Am* 2011;36(8):1413–21 quiz 1422.
- [13] Higuchi S, Ishihara S, Kobayashi H, Arai T. A mass lesion of the wrist: a rare manifestation of tuberculosis. *Internal med* 2008;47(4):313–16 Tokyo, Japan.
- [14] Hodgson AR, Smith TK, Gabriel S. Tuberculosis of the wrist with a note on chemotherapy. *Clin Orthop Relat Res* 1972;83:73–83.
- [15] Robins RH. Tuberculosis of the wrist and hand. *Br J Surg* 1967;54(3):211–18.
- [16] Bickel WH, Kimbrough RF, Dahlin DC. Tuberculous tenosynovitis. *J Am Med Assoc* 1953;151(1):31–5.
- [17] Suwannaphisit S, Ranong NN. Tuberculous tenosynovitis of the flexor tendons of the hand and wrist: A case report and mini-review. *Ann Med Surg (Lond)* 2020;57:249–52.
- [18] Baidoo PK, Baddoo D, Ocloo A, Agbley D, Lartey S, Baddoo NA. Tuberculous tenosynovitis of the flexor tendons of the wrist: a case report. *BMC Res Notes* 2018;11(1):238.
- [19] Aboudola S, Sienko A, Carey RB, Johnson S. Tuberculous tenosynovitis. *Hum Pathol* 2004;35(8):1044–6.
- [20] Hoffman KL, Bergman AG, Hoffman DK, Harris DP. Tuberculous tenosynovitis of the flexor tendons of the wrist: MR imaging with pathologic correlation. *Skeletal Radiol* 1996;25(2):186–8.
- [21] Celikyay F, Yuksekkaya RZ, Bostan B. Flexor tenosynovitis of the wrist including rice bodies. *Joint Bone Spine* 2018;85(3):373.
- [22] Hogan JI, Hurtado RM, Nelson SB. Mycobacterial Musculoskeletal Infections. *Infect Dis Clin North Am* 2017;31(2):369–82.
- [23] Kabakas F, Ugurlar M, Turan DB, Yesiloglu N, Mersa B, Ozcelik IB. Flexor tenosynovitis due to tuberculosis in hand and wrist: Is tenosynovectomy imperative? *Ann Plast Surg* 2016;77(2):169–72.
- [24] Wang HT, Sunil TM, Kleinert HE. Multiple unusual complications after extensive chronic sarcoid tenosynovitis of the hand: a case report. *J Hand Surg Am* 2005;30(3):610–14.