



# Intercarpal fusions: indications, treatment options and techniques

Patrick Houvet

- Partial wrist fusion is a useful technique for the treatment of such specific carpal disorders as arthritis, Kienböck's disease, midcarpal instability, scaphoid nonunion, etc.
- Many techniques have been described by removing arthritic joint surfaces and transferring load, using, for bone fixation, K-wires, screws, staples, and more recently dedicated plates.
- The goal of this procedure is to maximise wrist motion and strength while minimizing or eliminating pain.
- The purpose of this article is to discuss the most commonly used combination of intercarpal arthrodeses, to clarify the indications for each fusion, to describe the appropriate surgical technique for each fusion, and to provide an overview of results and current concepts.

**Keywords:** midcarpal; osteoarthritis; intercarpal fusions; wrist fusion

Cite this article: Houvet, P. Intercarpal fusions: indications, treatment options and techniques. *EFORT Open Rev* 2016;1:45-51. DOI: 10.1302/2058-5241.1.000019.

Intercarpal arthrodesis is a well-recognised treatment option and a time-tested procedure. The various partial fusions of the carpus are performed most commonly for arthritis, scaphoid nonunion, Kienböck's disease, chondrocalcinosis, and carpal instability. Although these procedures usually yield good and predictable outcomes, many complications have been reported and described in detail in the medical literature. The purpose of this article is to review the most commonly used combination of intercarpal arthrodeses, to clarify the indications for each fusion, to describe the most suitable surgical technique for each fusion, and to provide an overview of outcomes and current concepts.

The most common form of degenerative wrist osteoarthritis is secondary to scapholunate instability. Watson and Ballet have described the predictable pattern of degenerative changes that occur when the scapholunate ligament becomes compromised.<sup>1</sup> They refer to this progressive joint destruction as Scapho-Lunate-Advance-Collapse or

SLAC-wrist. Subsequently, similar progressive degeneration has been designated SNAC-wrist, for Scapho-Nonunion-Advance-Collapse; or SCAC-wrist, for Scapho Chondrocalcinosis-Advance-Collapse.<sup>2-5</sup>

The first limited wrist fusion case was reported less than a century ago, and until the 1980s only a few case reports had been published (for example by Watson).<sup>6</sup> Commonly used midcarpal fusion procedures include scaphotrapezotrapezoid (STT), scaphocapitate (SC), capitate-hamate-lunate-triquetrum or four-corner fusion (4-CF), and capitulate (CL). With regard to the proximal row, luno-triquetrum (LT) and scapholunate (SL) arthrodesis concern specific lesions.<sup>7</sup>

These partial fusions are essentially salvage procedures that are aimed at restoring a degree of function to the wrist, while minimizing pain and maximizing motion. The biomechanics of the wrist are substantially altered by all intercarpal arthrodesis procedures. In the unaltered wrist, 20% of axial force is transmitted across the ulnocarpal articulation and 80% across the radiocarpal articulation. Sixty per cent of this occurs at the radioscapoid articulation, and 40% through the radiolunate articulation. Modification of the carpal bone position and motion involves a load transfer that is usually beneficial for the joint.

The surgical objectives may be achieved by removing painful arthritic joint surfaces. This involves fixing the arthritic joint, removal of bone that has undergone deterioration, stabilisation of an unstable bone (mainly the scaphoid), stabilisation of an unstable joint directly or indirectly (mainly scapholunate joint), or restoration of the congruence between the radius and the proximal row (to repair the damage due to the arthritic process). Predicted loss of motion with all combinations of limited wrist fusions has been demonstrated biomechanically, and typically occurs with each specific arthrodesis.

## Surgical technique

### *Fundamentals*

The objective of an intercarpal fusion is to establish a stable, load-bearing joint at the congruent radiolunate interface. It requires a broad area of surface contact for fusion to occur, a large healthy bone graft, and stable fixation. When performing an intercarpal fusion, it is critical to correct the lunate or the scaphoid position, so as to allow the

bone to again participate in load sharing. The position of the lunate has been demonstrated biomechanically to be predictive of the total active motion of the wrist following midcarpal arthrodesis.<sup>8,9,10</sup> Intercarpal arthrodesis requires up to six weeks of wrist immobilisation in either a cast or a plastic splint before initiation of the rehabilitation period. Assessment of bone healing can be difficult, and only a CT-scan at this time can reveal the bone bridging trabeculae.<sup>11</sup>

#### *Approach, preparation, and bone grafting*

The surgical approach should allow for proper positioning of the bones in a manner that allows fusion and optimal implementation of the medical devices. A short transverse wrist incision may be considered, although it should not adversely affect being able to perform the remainder of the procedure. A dorsal longitudinal approach between the third and fourth extensor tendon compartments is the most versatile, and therefore more common, apart from specific radial or ulnar side arthrodesis.<sup>12</sup> After checking for arthritic lesions and making an assessment of the extent of their effects, the surgeon will have to sequentially perform the following:

1. Excision of the cartilage and the subchondral bone until the cancellous bone of each carpal bone is reached. For this, a rongeur, a curette, or an osteotome is sufficient. Use of a power tool can lead to thermal bone necrosis. This is the first key consideration to avoid compromising bone healing.
2. Reduction manoeuvres are frequently difficult and often incomplete. It may be necessary to remove the fibrosis in between each bone and at the radiocarpal space:
  - a) To reduce the scaphoid, it is necessary to perform a forced ulnar inclination and to push on the scaphoid tubercle. Alternatively, one can use K-wires as joy-sticks.
  - b) To reduce the midcarpal joint, it is necessary to pull the wrist upward while at the same time also pushing up the dorsal capitate and the palmar sides of the lunate. Performing a forced ulnar inclination then allows the position of the lunate at the top of the head of the capitate to be restored.
3. Following the reduction, the bones need to be temporarily fixed using K-wires, whilst maintaining a space in between them so as not to alter the biomechanics of the carpus.
4. The bone graft must be of adequate quality and size. This is another key consideration for achieving a good outcome. The bone harvested from the scaphoid or from reaming debris may not be of adequate quality to allow for fusion, compared to bone from the distal radius or iliac crest. Bone from

the distal radial epiphysis is generally harvested through the same incision.

5. The harvested cancellous bone is then packed down into the gap between each bone.

#### *Method of fixation*

The method of fixation of these partial fusions has been the subject of extensive debate. Multiple devices are now available to perform the fixation, including K-wires, memory staples, headless screws, variable pitch canulated compression screws, and circular plates.

### Description of fusion types

These have been described previously by Saffar, and we will review the main partial arthrodesis performed with this type of procedure for partial fusion according to the column concept on the radial side, the ulnar side, the central column, and the borders.<sup>13,14</sup>

#### *Radial side*

##### *Scaphotrapeziotrapezoid (STT)*

STT arthrodesis (see Fig. 1) was first described by K. Watson,<sup>6</sup> and it has been used for multiple indications, including carpal instability, STT osteoarthritis, traumatic carpal dislocation *sequelae*, and Kienböck's disease. At present, the latter is the most common indication reported in the literature.<sup>15</sup> Fusion of the STT joint is meant to transfer force away from the radiolunate joint and toward the radioscaphoid articulation. Even though alteration of force transfer across the wrist has been confirmed by biomechanical analysis, the fusion greatly reduces wrist motion, while the flexion extension arc decreases to 60% of the contralateral side and the radial and ulnar deviation decreases up to 52%. We recommend a vertical approach between the EPL and the EDC. Scaphoid adjustment is less readily achieved using a dorsal horizontal approach or a palmar approach. A short radial styloidectomy is often considered to decrease the risk of radial impingement. We currently use a customised 14 mm circular plate for this type of fusion. While some authors have reported good results with STT arthrodesis in terms of motion and grip strength, others have reported results that are less encouraging, as complications may often be encountered, including avascular necrosis, progressive instability, or persistent pain without arthrosis. The nonunion rate is variable, ranging between 4% and 15%.

##### *Scaphocapitate (SC)*

In 1946, Suto described this procedure for the treatment of scaphoid nonunion. Indications for SC arthrodesis (see Fig. 2) currently include SL instability, arthritis, and Kienböck's disease.<sup>14,16</sup>

Carpal force transmission is modified to offload the lunate with a carpal alignment preservation that prevents rotatory subluxation of the scaphoid. We use a vertical

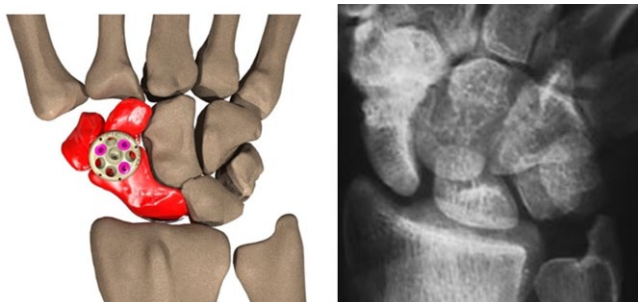


Fig. 1 An example of STT fusion.

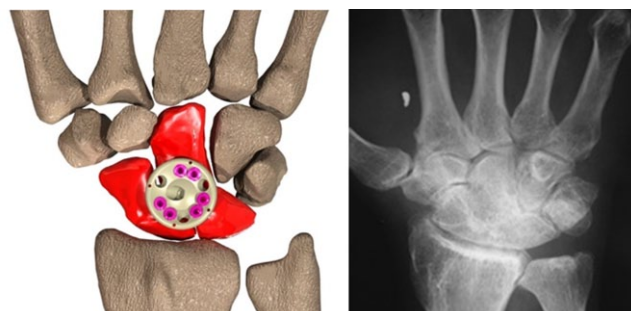


Fig. 3 SLC fusion.

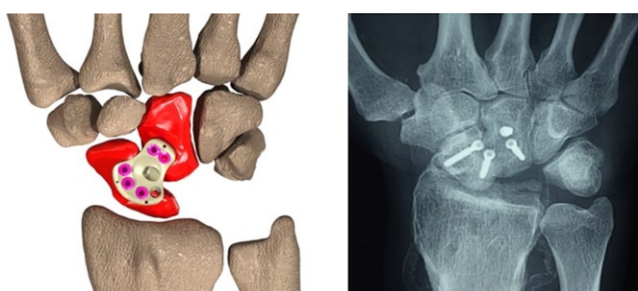


Fig. 2 SC fusion and lunarectomy.

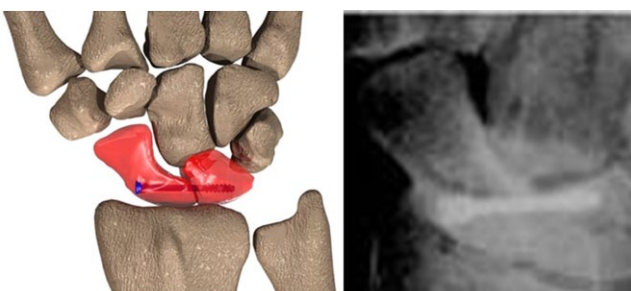


Fig. 4 SL arthrodesis.

approach between the EPL and the EDC, and in this case it is relatively straightforward to achieve scaphoid adjustment. Furthermore, there is a large surface area for contact between both bones, thus generally permitting a good rate of healing. We use memory staples, or a plate with a specific customised shape for this fusion. The DASH score is often good, and it persists over time. The nonunion rate is very low.<sup>17</sup>

#### Scapholunocapitate (SLC)

This procedure can be used when all of the proximal row bone cartilage is damaged, or when a scaphoid nonunion is involved (see Fig. 3). This is a frequent occurrence following a transscapho-perilunate dislocation, as well as with certain specific types of scaphoid nonunion. The approach is exactly the same as for SC fusion. We use a circular plate to secure the three bones, with two screws in each bone.

#### Scapholunate (SL)

SL instability without arthrosis is generally viewed as the main indication for surgery (see Fig. 4). The approach is usually through a dorsal vertical or transverse incision. We prefer to use a small two-hole locking plate, however, instead of an axial screw to fix both bones. In theory, the main advantage is that it allows for retention of good mobility. Carpal force transmission is not altered. This procedure is, however, technically demanding due to the small surface area available for fusion and the very large forces imposed on the SL joint. The overall outcomes for SL arthrodesis are therefore unpredictable. Persistent wrist pain is common, and the ultimate success of SL arthrodesis cannot be predicted in advance. The rate of nonunion

is very high, reaching as much as 87%, although a fibrous union is thought to be sufficient to obtain a good clinical outcome.<sup>18-20</sup>

#### Ulnar side

##### Lunotriquetral (LT)

LT arthrodesis (see Fig. 5) has been used mainly to treat LT instability and degenerative joint disease. Whilst we use a dorsal transverse or longitudinal incision, the approach is not easy because the joint axis is oblique. Neither of the bone adjustments are straightforward. It is necessary to intercalate a 3–5 mm cancellous bone graft to avoid a nonunion that tends to be the main complication. We prefer to use a locking plate with two holes to provide a solid assembly, instead of a staple, axial screw, or K-wires. It is paramount to search for associated regional lesions, such as congenital or post-traumatic ulnar impaction syndrome, a TFCC tear, or SL instability. The literature reports variable outcomes, and improvements in pain and function tend to be unpredictable. Associated regional lesions could contribute to residual pain if they are not treated at the same time. LT fusion must be applied with caution due to the high rate of nonunion (57%).<sup>21-23</sup>

##### 'Four corner' fusion (4-CF)

First described by Watson in 1984, the four-corner fusion (4-CF; see Fig. 6) is the most common intercarpal arthrodesis. The procedure includes a scaphoidectomy and a fusion of the capitate, lunate, hamate, and triquetrum. The main indication for 4-CF is degradation of the radio-scaphoid joint and the luno-capitate joint, with the radiolunate articulation remaining unscathed. This pattern

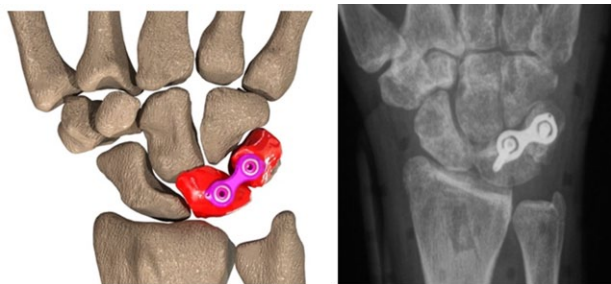


Fig. 5 LT arthrodesis.

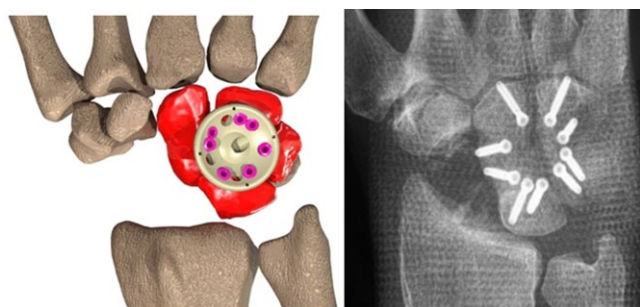


Fig. 6 4-CF fusion and scaphoidectomy.

of arthritis is seen in SLAC 3, as well as in SNAC and SCAC 3. We use a longitudinal dorsal approach at the junction of the third compartment. The arthritic cartilage surfaces are removed entirely after the scaphoid excision, and the remaining carpal bones are stabilised by fusion of the four bones. We use a radiolucent plastic circular plate for this procedure. We find this requires placing two screws in each bone, and the bone grafting inbetween each carpal joint must be done with precision and the greatest of care.

Radiolucency of the plate is useful, as it allows the bone healing and fusion to be readily checked. In studies with cadavers, four-corner fusion has been shown to increase the radiolunate contact force, with no change in the transmission of force across the ulnar carpal joint. The total arc of the wrist motion (flexion, extension, as well as radial and ulnar deviation) is reduced to 47% of the contralateral side, and grip strength averages 74% of the intact side. Four-corner fusion consistently yields good outcomes in terms of pain relief and patient satisfaction. In the series by Watson et al using 4-CF, 91% of patients had pain relief and 80% of patients returned to their original form of employment. The rate of nonunion is between 3 and 17%.<sup>24–33</sup>

There are several variations of the traditional 4-CF:

a) One is a scaphoidectomy with bicolunar fusion, in which the capitulate and triquetrum joints are fused with the articulation between the two columns that are being left intact.<sup>34,35,68</sup> Wang et al have demonstrated good outcomes with this

technique, with a union rate exceeding 95%, average wrist flexion and extension of 45° and 46° respectively, and average grip strength of 70% of the contralateral side.

b) An alternative procedure is a scaphoid and triquetrum excision with capitohamate or 3-corner arthrodesis, as first described by Delattre.<sup>36,38</sup>

c) Korus<sup>41</sup> proposed a new procedure, namely the ‘2-corner, 3-carpal’ fusion. This involves fusing only the capitate, lunate, and triquetrum, while excluding the hamate. Through judicious use of compression screws, he was able to achieve union and an acceptable range of motion in ten patients.

### Central column

#### Lunocapitate

This procedure involves scaphoid excision with capitulate arthrodesis (see Fig. 7). Depending on Viegas’ anatomical classification, type I lunates are typically associated with a higher prevalence of dorsal intercalated segment instability (DISI), which equates to a deformity in the setting of scaphoid fracture nonunion (75% vs 20%). Yet with this type of procedure the lunate positioning is easier to achieve, and the rate of fusion is higher.

In type II, with an additional distal articular facet medial to the hamate, contact is harder to achieve. The problem is the same when there has been extensive lunato-ulnar shifting.<sup>44</sup> Early trials with isolated capitulate arthrodesis demonstrated an unacceptably high rate of nonunion. With more recent uses of this procedure, it has been shown that union rates are actually similar to those with 4-CF. This difference is probably due to improved fixation techniques, as well as the use of canulated headless compression screws, memory staples, or dedicated radiolucent four-hole plates. This surgery is technically easier than a 4-CF, and it may improve motion compared with 4-CF, although there are no reports yet in the literature to support this assertion.<sup>45</sup>

#### Radiolunate (RL), Radioscaphoid (RS), Radioscapholunate (RSL)

Regarding the borders of the carpal arthrodesis, we will review radiocarpal arthrodesis with radiolunate, radioscaphoid, or radioscapholunate fusion (see Fig. 8).

### Indications

Intercarpal arthrodesis is performed most frequently to treat carpal instability with arthritis. Yet partial fusion of specific carpal units can also be used for other pathologies, with or without arthritis; such as scaphoid nonunion with arthritis, midcarpal instability and Kienböck’s disease, for example.<sup>46,6</sup>

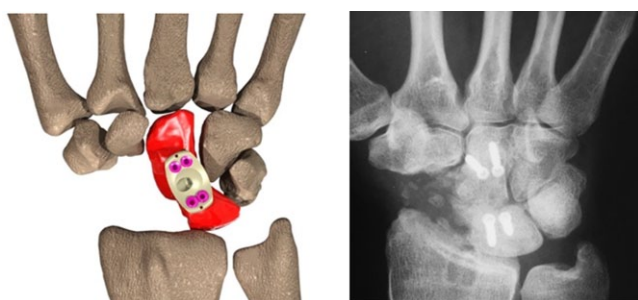


Fig. 7 LC fusion+ scaphoidectomy.

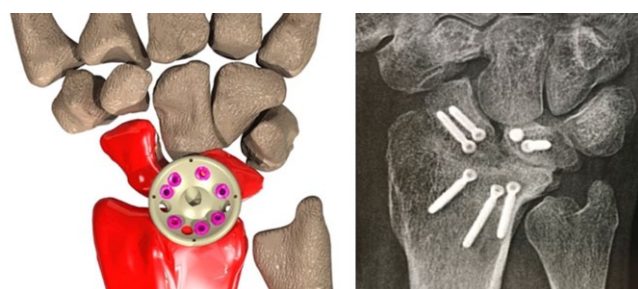


Fig. 8 RSL fusion.

1) Instabilities without arthritis:

a) *Scapholunate instability without arthritis* constituted 25% of our indications 20 years ago (58% in the Watson series). The percentage is currently much lower, because we tend to perform many more ligamentoplasties. SL arthrodesis is not a reliable procedure, and we therefore prefer SC fusion if it is deemed to be necessary. The drawbacks are significant, and include limitation of the ulnar inclination and a reduction in normal mobility of 50%. The nonunion rate is, however, much better.<sup>47,49</sup>

b) *Lunotriquetral instability*: LT fusion typically has a bad reputation due to the high nonunion rate. The availability of new devices has, however, changed the outcomes, which are now comparable with published results of ligament reconstruction or ligamentoplasty.<sup>21,50</sup>

c) *Midcarpal instability* is less of a common occurrence. It tends to occur in young patients with hypermobility. LC fusion is an option, and this does not progress into stiffness for these particular patients.<sup>51</sup>

2) Arthritis:

a) Sooner or later, the progression of scapholunate instability with arthritis (SLAC), scaphoid nonunion with arthritis (SNAC), and chondrocalcinosis (SCAC) all result in the same state of the carpus. When stage 3 is reached, the cartilage of the head of the capitate is damaged and hence cannot be preserved.<sup>4,5,52</sup> Such a situation is the best indication for a 4-CF. The outcomes for proximal

row carpectomy have been shown to be superior to those for 4-CF, at least in the short term. Thus, this procedure may be considered in cases where the capitulate articulation has only minimal chondromalacia.<sup>53–61</sup>

b) *Focal osteoarthritis*: the most common occurrence is isolated STT osteoarthritis. It is frequently associated with chondrocalcinosis. STT fusion is the default option.

c) *Radiocarpal arthritis*: Radiolunate arthrodesis is very appropriate when the radial fossa cartilage is damaged, as may occur for example with a Dye-punch fracture.<sup>62</sup>

3) Kienböck's disease:

Numerous types of partial arthrodesis have been described with different biomechanical objectives of joint decompression for stage 4 with arthritis.

a) STT or SC arthrodesis (which is our preference) that involves transferring the load to the external column after removal of the lunate.<sup>63–65</sup>

b) Capito-hamate (CH) with or without shortening of the capitate. We do not, however, have experience with this procedure.<sup>66,67</sup>

## Conclusions

Partial wrist fusions are justified based on biomechanics because wrist osteoarthritis only involves a limited number of joints. These are mainly the radioscaphoid and lunocapitate joints. Limited carpal fusion allows numerous wrist pathologies to be corrected, including osteoarthritis, instability, and specific diseases. At the same time, this also helps the patient to maintain a functional range of motion by correcting the carpus height and by suppressing the pain due to the loss of cartilage.

This surgery is, however, technically demanding. Meticulous bone surface preparation, adequate bone grafting, and reliable fixation are required to optimise outcomes and minimise complications. Being able to adequately achieve these requirements is probably why the literature is rife with reports of high nonunion rates, while others report excellent results.

### AUTHOR INFORMATION

Institut Français de Chirurgie de la Main, Paris, France.

Correspondence should be sent to Patrick Houvet.

Email: phouvet@ifcm.org

### CONFLICT OF INTEREST

The author is eligible to receive royalties from the sale of the Xpode® cup from Wright Medical USA and would benefit from the outright sale of the manufacturing rights.

**FUNDING**

No benefits in any form have been received or will be received from a commercial party related directly or indirectly to the subject of this article.

**LICENCE**

© 2016 The author(s)

This article is distributed under the terms of the Creative Commons Attribution-NonCommercial 4.0 License (<http://www.creativecommons.org/licenses/by-nc/4.0/>) which permits non-commercial use, reproduction and distribution of the work without further permission provided the original work is attributed.

**REFERENCES**

1. **Watson HK, Ballet FL.** The SLAC wrist: scapholunate advanced collapse pattern of degenerative arthritis. *J Hand Surg Am* 1984;9:358–365.
2. **Krakauer JD, Bishop AT, Cooney WP.** Surgical treatment of scapholunate advanced collapse. *J Hand Surg Am* 1994;19:751–759.
3. **Linscheid RL, Rettig ME.** The treatment of displaced scaphoid nonunion with trapezoidal bone graft. In: Gelberman RH, ed. *Masters techniques in orthopaedic surgery: the wrist*. New York: Lippincott Williams & Wilkins, 1994:119–131.
4. **Romano S.** Non-traumatic osteoarthritis of the wrist: chondrocalcinosis. *Chir Main* 2003;22:285–292.
5. **Saffar P.** Chondrocalcinosis of the wrist. *J Hand Surg Br* 2004;29:486–493.
6. **Watson HK, Goodman ML, Johnson TR.** Limited wrist arthrodesis. Part II: intercarpal and radiocarpal combinations. *J Hand Surg Am* 1981;6:223–233.
7. **Clayton ML, Ferlic DC.** Arthrodesis of the arthritic wrist. *Clin Orthop Relat Res* 1984;187:89–93.
8. **De Carli P, Donndorff AG, Alfie VA, et al.** Four-corner arthrodesis: influence of the position of the lunate on postoperative wrist motion: a cadaveric study. *J Hand Surg Am* 2007;32:1356–1362.
9. **Gellmann H, Kaufmann D, Lenihan M, Botte MJ, Sarmiento A.** An in vitro analysis of wrist motion: the effect of limited intercapal arthrodesis and the contributions of the radiocarpal and midcarpal joints. *J Hand Surg Am* 1988;13:378–383.
10. **Skie M, Grothaus M, Ciocanel D, Goel V.** Scaphoid excision with four-corner fusion: a biomechanical study. *Hand (NY)* 2007;2:194–198.
11. **Clendenin MB, Green DP.** Arthrodesis of the wrist – complications and their management. *J Hand Surg Am* 1981;6:253–257.
12. **Berger RA, Bishop AT, Bettinger PC.** New dorsal capsulotomy for the surgical exposure of the wrist. *Ann Plast Surg* 1995;35:54–59.
13. **Saffar P.** *Indications, techniques et resultats des arthrodeses partielles du carpe. Cahier d'Enseignement de la chirurgie de la Main*. Paris: Expansion Scientifique Publications, 1997:41–54.
14. **Stewart DT, Froelich JM, Shin AY.** Intercarpal arthrodeses. *J Hand Surg Am* 2014;39:373–377.
15. **Watson HK, Weinzeig J, Guidera PM, Zeppieri J, Ashmead D.** One thousand intercarpal arthrodeses. *J Hand Surg Br* 1999;24:307–315.
16. **Pisano SM, Peimer CA, Wheeler DR, Sherwin F.** Scaphocapitate intercarpal arthrodesis. *J Hand Surg Am* 1991;16:328–333.
17. **Matheson LN, Melhorn JM, Mayer TG, Theodore BR, Gatchel RJ.** Reliability of a visual analog version of the QuickDASH. *J Bone Joint Surg [Am]* 2006;88-A:1782–1787.
18. **Alnot JY, De Cheveigne C, Bleton R.** Instabilité scapho-lunaire chronique post-traumatique traitée par arthrodesis scapho-lunaire. *Ann Chir Main* 1992;11:107–118.

19. **Hom S, Ruby LK.** Attempted scapholunate arthrodesis for chronic scapholunate dissociation. *J Hand Surg Am* 1991;16:334–339.
20. **Zubairy AI, Jones WA.** Scapholunate fusion in chronic symptomatic scapholunate instability. *J Hand Surg Br* 2003;28:311–314.
21. **Kirschenbaum D, Coyle MP, Leddy JP.** Chronic lunotriquetral instability: diagnosis and treatment. *J Hand Surg Am* 1993;18:1107–1112.
22. **Sennwald GR, Fischer M, Mondi P.** Lunotriquetral arthrodesis. A controversial procedure. *J Hand Surg Br* 1995;20:755–760.
23. **Vandesande W, De Smet L, Van Ransbeeck H.** Lunotriquetral arthrodesis, a procedure with a high failure rate. *Acta Orthop Belg* 2001;67:361–367.
24. **Chung KC, Watt AJ, Kotsis SV.** A prospective outcomes study of four-corner wrist arthrodesis using a circular limited wrist fusion plate for stage II scapholunate advanced collapse wrist deformity. *Plast Reconstr Surg* 2006;118:433–442.
25. **Delétang F, Segret J, Dap F, Dautel G.** Chronic scapholunate instability treated by scaphocapitate fusion: a midterm outcome perspective. *Orthop Traumatol Surg Res* 2011;97:164–171.
26. **Kendall CB, Brown TR, Millon SJ, et al.** Results of four-corner arthrodesis using dorsal circular plate fixation. *J Hand Surg Am* 2005;30:903–907.
27. **Luegmair M, Houvet P.** Effectiveness of four-corner arthrodesis with use of a locked dorsal circular plate. *Clin Orthop Relat Res* 2012;470:2764–2770.
28. **Merrell GA, McDermott EM, Weiss AP.** Four-corner arthrodesis using a circular plate and distal radius bone grafting: a consecutive case series. *J Hand Surg Am* 2008;33:635–642.
29. **Rhee PC, Shin AY.** The rate of successful four-corner arthrodesis with a locking dorsal circular PEEK-Optima plate. *J Hand Surg Eur Vol* 2013;38:767–773.
30. **Rodgers JA, Holt G, Finnerty EP, Miller B.** Scaphoid excision and limited wrist fusion: a comparison of K-wire and circular plate fixation. *Hand (NY)* 2008;3:276–281.
31. **Rudnick B, Goljan P, Pruzansky JS, et al.** Four-corner arthrodesis with a radiolucent locking dorsal circular plate: technique and outcomes. *Hand (NY)* 2014;9:315–321.
32. **Shindle MK, Burton KJ, Weiland AJ, Domb BG, Wolfe SW.** Complications of circular plate fixation for four-corner arthrodesis. *J Hand Surg Eur Vol* 2007;32:50–53.
33. **Vance MC, Hernandez JD, Didonna ML, Stern PJ.** Complications and outcome of four-corner arthrodesis: circular plate fixation versus traditional techniques. *J Hand Surg Am* 2005;30:1122–1127.
34. **Wang ML, Bednar JM.** Lunatocapitate and triquetrohamate arthrodeses for degenerative arthritis of the wrist. *J Hand Surg Am* 2012;37:1136–1141.
35. **Ashmead D IV, Watson HK, Damon C, Herber S, Paly W.** Scapholunate advanced collapse wrist salvage. *J Hand Surg Am* 1994;19:741–750.
36. **Calandrucchio JH, Gelberman RH, Duncan SF, et al.** Capitulum arthrodesis with scaphoid and triquetrum excision. *J Hand Surg Am* 2000;25:824–832.
37. **Cohen MS, Werner FW, Sutton LG, Short WH.** Scaphoid excision and midcarpal arthrodesis: the effect of triquetral excision – a biomechanical study. *J Hand Surg Am* 2012;37:493–499.
38. **Delattre O, Dupont P, Reau AF, et al.** Shortening arthrodesis of three wrist bones. *Ann Chir Main* 1997;16:292–299.
39. **Dutly-Guinand M, von Schroeder HP.** Three-corner midcarpal arthrodesis and scaphoidectomy: a simplified volar approach. *Tech Hand Up Extrem Surg* 2009;13:54–58.
40. **Gaston RG, Greenberg JA, Baltera RM, Mih A, Hastings H.** Clinical outcomes of scaphoid and triquetral excision with capitulum arthrodesis versus scaphoid excision and four-corner arthrodesis. *J Hand Surg Am* 2009;34:1407–1412.

41. **Korus LJ, Ball B, Morhart M.** Exclusion of the hamate in 4-corner fusion: technique and outcomes of a novel approach to intercarpal arthrodesis. *Tech Hand Up Extrem Surg* 2013;17:102–105.
42. **Mahmoud M, El Shafie S.** Bicolunar fusion for scaphoid nonunion advanced collapse without bone grafting. *Tech Hand Up Extrem Surg* 2012;16:80–85.
43. **van Riet RP, Bain GI.** Three-corner wrist fusion using memory staples. *Tech Hand Up Extrem Surg* 2006;10:259–264.
44. **Viegas SF.** The lunatohamate articulation of the midcarpal joint. *Arthroscopy* 1990;6:5–10.
45. **Kirschenbaum D, Schneider LH, Kirkpatrick WH, Adams DC, Cody RP.** Scaphoid excision and capitulate arthrodesis for radioscaphoid arthritis. *J Hand Surg Am* 1993;18:780–785.
46. **Alnot JY, Houvet P.** Chirurgie des traumatismes récents du carpe. *Encycl Méd Chir. Techniques Chirurgicales-Orthopédie-Traumatologie* 1995;44–352.
47. **Kleinman WB, Carroll CIV.** Scapho-trapezio-trapezoid arthrodesis for treatment of chronic static and dynamic scapho-lunate instability: a 10-year perspective on pitfalls and complications. *J Hand Surg Am* 1990;15:408–414.
48. **Luegmair M, Saffar P.** Scaphocapitate arthrodesis for treatment of scapholunate instability in manual workers. *J Hand Surg Am* 2013;38:878–886.
49. **Pettersson K, Wagnsjö P.** Arthrodesis for chronic static scapholunate dissociation: a prospective study in 12 patients. *Scand J Plast Reconstr Surg Hand Surg* 2004;38:166–171.
50. **Shin AY, Battaglia MJ, Bishop AT.** Lunotriquetral instability: diagnosis and treatment. *J Am Acad Orthop Surg* 2000;8:170–179.
51. **Rao SB, Culver JE.** Triquetrohamate arthrodesis for midcarpal instability. *J Hand Surg Am* 1995;20:583–589.
52. **Tomaino MM, Miller RJ, Cole I, Burton RI.** Scapholunate advanced collapse wrist: proximal row carpectomy or limited wrist arthrodesis with scaphoid excision? *J Hand Surg Am* 1994;19:134–142.
53. **Ali MH, Rizzo M, Shin AY, Moran SL.** Long-term outcomes of proximal row carpectomy: a minimum of 15-year follow-up. *Hand (NY)* 2012;7:72–78.
54. **Blankenhorn BD, Pfaeffle HJ, Tang P, et al.** Carpal kinematics after proximal row carpectomy. *J Hand Surg Am* 2007;32:37–46.
55. **Cohen MS, Kozin SH.** Degenerative arthritis of the wrist: proximal row carpectomy versus scaphoid excision and four-corner arthrodesis. *J Hand Surg Am* 2001;26:94–104.
56. **De Smet L, Degreef I, Robijns F, Truyen J, Deprez P.** Salvage procedures for degenerative osteoarthritis of the wrist due to advanced carpal collapse. *Acta Orthop Belg* 2006;72:535–540.
57. **DiDonna ML, Kiefhaber TR, Stern PJ.** Proximal row carpectomy: study with a minimum of ten years of follow-up. *J Bone Joint Surg [Am]* 2004;86-A:2359–2365.
58. **Hogan CJ, McKay PL, Degnan GG.** Changes in radiocarpal loading characteristics after proximal row carpectomy. *J Hand Surg Am* 2004;29:1109–1113.
59. **Jebson PJ, Hayes EP, Engber WD.** Proximal row carpectomy: a minimum 10-year follow-up study. *J Hand Surg Am* 2003;28:561–569.
60. **Vanhove W, De Vil J, Van Seymortier P, Boone B, Verdonk R.** Proximal row carpectomy versus four-corner arthrodesis as a treatment for SLAC wrist. *J Hand Surg Eur Vol* 2008;33:118–125.
61. **Wyrick JD, Stern PJ, Kiefhaber TR.** Motion-preserving procedures in the treatment of scapholunate advanced collapse wrist: proximal row carpectomy versus four-corner arthrodesis. *J Hand Surg Am* 1995;20:965–970.
62. **Foucher G.** L'opération dite Dye-punch dans les séqueles de fracture articulaire du radius. *Ann Chir Main* 1995;14:100–102.
63. **Iwasaki N, Genda E, Barrance PJ, et al.** Biomechanical analysis of limited intercarpal fusion for the treatment of Kienböck's disease: a three-dimensional theoretical study. *J Orthop Res* 1998;16:256–263.
64. **Meier R, van Griensven M, Krimmer H.** Scaphotrapeziotrapezoid (STT)-arthrodesis in Kienböck's disease. *J Hand Surg Br* 2004;29:580–584.
65. **Moy OJ, Peimer CA.** Scaphocapitate fusion in the treatment of Kienböck's disease. *Hand Clin* 1993;9:501–504.
66. **Almquist EE.** Capitate shortening in the treatment of Kienböck's disease. *Hand Clin* 1993;9:505–512.
67. **Inoue G.** Capitate-hamate fusion for Kienböck's disease. Good results in 8 cases followed for 3 years. *Acta Orthop Scand* 1992;63:560–562.
68. **Draeger RW, Bynum DK, Schaffer A, Patterson MM.** Bicolunar intercarpal arthrodesis: minimum 2 years follow-up. *J Hand Surg Am* 2014;39:888–894.