

## Original Article

# Clinical application of percutaneous kyphoplasty under the guidance of DynaCT in the treatment of compression fractures of thoracolumbar

Guanghui He<sup>1</sup>, Qilong Yu<sup>2</sup>, Kunning Yang<sup>3</sup>, Zhi Gao<sup>1</sup>, Aiqiang Han<sup>4</sup>

<sup>1</sup>Department of Interventional Therapy, The Second People's Hospital of Weifang, P.R. China; <sup>2</sup>Department of Orthopedics, The Second People's Hospital of Weifang, P.R. China; <sup>3</sup>Department of Respiratory Medicine, The Second People's Hospital of Weifang, P.R. China; <sup>4</sup>Department of Endocrinology, The 89th Hospital of CPLA, P.R. China

## Abstract

**Objectives:** This study aims to investigate the clinical application values of percutaneous kyphoplasty (PKP) under the guidance of DynaCT in the treatment of compression fractures of thoracolumbar. **Methods:** 57 patients with compression fractures of thoracolumbar who were treated with PKP in The Second People's Hospital of Weifang from December 2014 to August 2016 were selected. Patients were randomly divided into DynaCT+DSA treatment group (27 cases) and DSA treatment group (30 cases) for PKP surgery. There were 19 cases of simple thoracic compression fractures, 28 cases of simple lumbar compression fractures, and 10 cases of thoracic vertebral compression fractures. Bone cement filling and leakage conditions were recorded after surgery. Efficacy of PKP was evaluated at 3 days after operation using visual analogue scale (VAS) and the maximal depth of the affected vertebrae. 71 lesioned vertebrae were treated and all punctures were successful. **Results:** VAS score and height of the largest depression in vertebrae were significantly improved after surgery ( $p < 0.05$ ), while no significant differences were found between 2 groups. The leakage rate of bone cement in the two groups was 24.3% and 18.4%, respectively. **Conclusion:** DynaCT can be used to guide the development of vertebral puncture program before PKP, guide the accurate puncture during operation, and can be used to evaluate the leakage of bone cement timely and reliably.

**Keywords:** DynaCT, Percutaneous Kyphoplasty, Vertebrae, Pain

## Introduction

Percutaneous kyphoplasty (PKP) is the percutaneous vertebroplasty (PVP) supplemented by balloon vertebrae expansion. This method can not only correct the fracture deformity of vertebrae but also create a cavity in vertebrae. Besides that, this method can reduce the permeability of bone cement under low-pressure injection, so as to correct kyphosis, enhance vertebral strength, and eliminate lesions

of vertebrae, which in turn improves clinical efficacy and safety<sup>1</sup>. With the advantages of strong analgesic effect and small trauma, PKP has been widely used in the treatment of osteoporotic vertebral compression fractures, vertebral metastases and vertebral myeloma<sup>2</sup>.

Digital Subtraction Angiography (DSA) and helical CT are widely used in the treatment and efficacy evaluation of PKP. DSA can monitor the puncture and treatment in real time; the operation of DSA is easy, but it cannot detect the leakage of bone cement. Helical CT can locate accurately and reveal the distribution of bone cement. Those two methods have their own advantages and cannot be replaced by each other. DSA DynaCT is a new imaging technology developed in recent years. DSA DynaCT has functions of both DSA and helical CT, which is more accurate and convenient in the guidance, treatment, and evaluation of PKP. In this study, DynaCT was used in the treatment of diseases associated with vertebral pain.

The authors have no conflict of interest

Corresponding author: Dr. Aiqiang Han, Department of Endocrinology, The 89th Hospital of CPLA, No.256 Beigong West Street, Weifang 261041, P.R. China  
E-mail: ho632h@163.com

Edited by: G. Lyritis

Accepted 16 January 2019



## Materials and methods

### General information

57 patients with thoracic and lumbar vertebral compression fractures treated with DynaCT-guided PKP from December 2014 to August 2016 in The Second People's Hospital of Weifang were selected. Those patients included 18 males and 39 females, and their age ranged from 62 to 87 year, with a mean age of (77.5±5.2) years. There were 19 cases of simple thoracic compression fractures, 28 cases of simple lumbar compression fractures, and 10 cases of thoracic vertebral compression fractures. All patients underwent standard PKP treatment and were randomly divided into DynaCT+DSA treatment group (27 cases) and simple DSA treatment group (30 cases).

All of the 57 patients had low back pain with varying degrees of motion, and no symptoms of neurospinal cord injury. Senile osteoporosis is the main type and no history of malignant tumors or metastases was observed. Before PKP treatment, MRI (3.0T) and CT examinations were performed on the lesioned vertebral bodies. The routine examination was performed to exclude surgical contraindications as well as iodohexol skin test.

### Equipment and materials

Siemens Atis Zee Floor digital imaging angiography system with DynaCT function (Siemens, Germany) and Siemens 3D imaging workstation (Siemens, Germany) were used. Puncture Kit for vertebrae (Jinan Guantong Commercial And Trading Co., Ltd., Jinan, China): bone puncture needle, balloon, balloon expansion pressure pump, working column, high precision bone drill, Kirschner wire, bone cement (Heraeus Medical company, Germany).

### Surgical methods

**DynaCT+DSA group:** patients were subjected to intramuscular injection of 10 mg diazepam at 30 min before surgery. Patients were fixed in a prone position with console entered the 3D-CT mode. The affected vertebral body was placed in the center of the display field and was rotated to collect data. Data acquisition parameters were: rotation angle of 230, duration of 8 s, display field of 40 cm, matrix of 1024\*1024. After that, data were transferred to 3D imaging workstation. Three-dimensional cross-sectional images were constructed through multiplanar reformat (MPR) or maximum intensity projection (MIP). Three-dimensional images were reconstructed using volume rendering technique. Vertebral puncture guide path was established using those three-dimensional images. **PKP:** Routine disinfection was performed, and "bovine eye position" was determined. The puncture needle was inserted into the guidance path to reach pedicle. Cross-sectional images were rebuilt with DynaCT to observe the relative position of the puncture needle and pedicle, and to predict the position needle can reach, and the angle and position of the needle were adjusted if it was necessary. When puncture needle reached the center of responsible vertebrae

under the guidance of DSA, the balloon was inserted under lateral fluoroscopy, then balloon dilatation was performed with pressure of 3-5 atm. Bone cement was prepared and balloon was removed. Toothpaste-like bone cement was injected using a 1 ml syringe. Injection was stopped when the bone cement reached the front or rear edge of vertebrae. Then trocar was inserted and puncture needle was removed. With patients fixed in the same position, puncture point was pressed for 3-5 min to stop bleeding. DynaCT technique was used to reconstruct the cross-section, coronal plane, sagittal plane, and three-dimensional images to observe the leakage of bone cement. Patients were in horizontal position after surgery and were allowed to move at 6 h after the operation. Routine anti-infection, anti-inflammatory and symptomatic supportive treatments were also performed after surgery.

**(DSA group:** All operations were performed under the guidance of DSA, while the DynaCT technology was not used).

### Observation indicators

The degree of pain was assessed by visual analogue scale (VAS) before operation and 3 days after operation. Scores ranged from 1 to 10 points, and higher scores indicated more severe pain. The maximal depth of the responsible vertebrae was measured by helical CT. Bone cement leakage and occurrence of complications were recorded.

### Statistical analysis

SPSS19.0 statistical software was used for statistical analysis. Data were expressed as mean ± standard deviation. VAS score and vertebral compression degree were compared using t-test. Count data were expressed as rate (%) and compared by  $\chi^2$  test.  $p < 0.05$  was considered to be statistically significant.

## Results

### Success rate of PKP

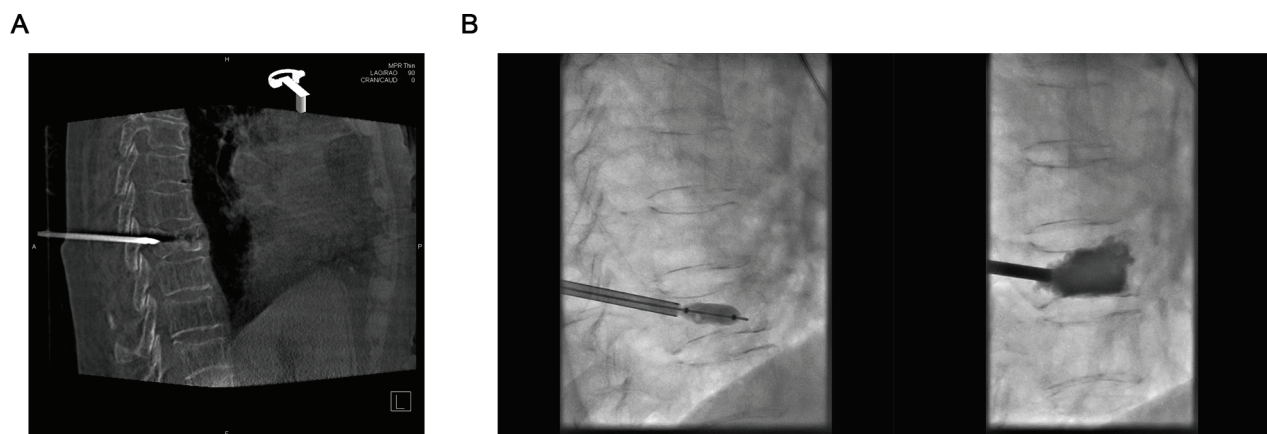
A total of 71 lesioned vertebrae were treated with PKP. 23 lesioned vertebrae were treated with unilateral pedicle puncture, and 48 were treated with bilateral pedicle puncture. Puncture was performed for 119 times, and success rate was 100% (Figure 1). Each vertebral body was injected with 1.8-6.3 ml (average of 4.05 ml) of bone cement.

### Comparison of VAS scores before and after surgery

VAS score on the 3rd day after surgery was significantly lower than that before surgery in both groups ( $p < 0.05$ ) (Table 1).

### Comparison of the depth of vertebral body's maximal collapse before and after surgery

The height of the depth of vertebral body's maximal collapse after operation in both groups was significantly lower than before surgery ( $p < 0.05$ ). There were no significant differences between two groups (Table 2).



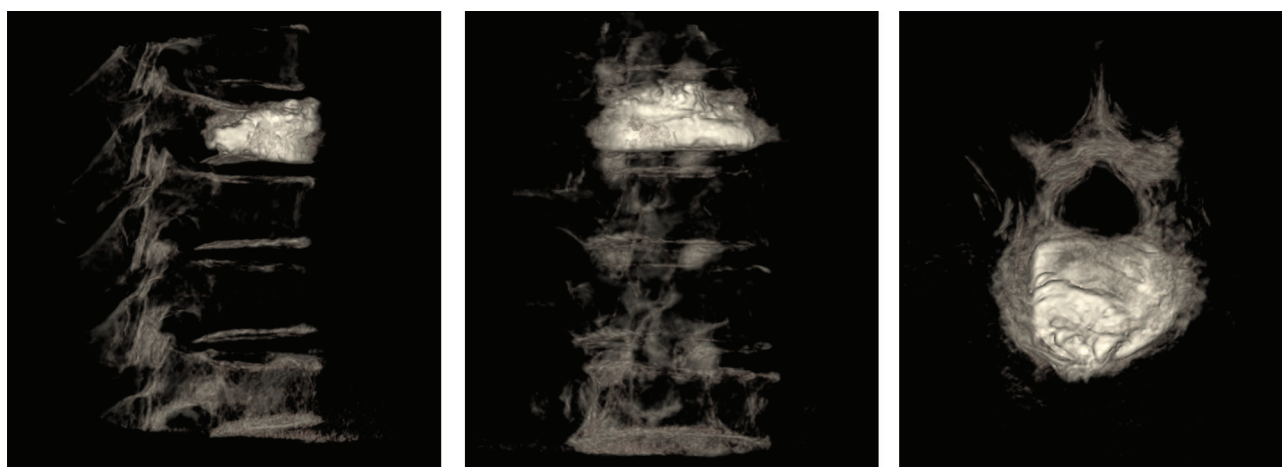
**Figure 1.** Representative case of an 80 years old female patient with a T8 compression fracture. A. Images reconstructed by DynaCT showed that puncture needle was fully located in the pedicle, and the angle of puncture was satisfactory, no adjustment was needed; B. Injection of bone cement after intraoperative balloon dilatation.

**Table 1.** Comparison of VAS scores before and after surgery in both groups (mean  $\pm$  SD).

Groups	Cases	Before surgery/ points	After surgery/ points	<i>p</i> -value
DynaCT+DSA	27	8.12 $\pm$ 0.49	2.06 $\pm$ 0.31	0.002
DSA	30	8.36 $\pm$ 0.51	2.13 $\pm$ 0.93	0.003

**Table 2.** Comparison of the depth of vertebral body's maximal collapse before and after surgery (mean  $\pm$  SD).

Groups	Cases	Before surgery/ mm	After surgery/ mm	<i>p</i> -value
DynaCT+DSA	27	14.96 $\pm$ 1.75	22.07 $\pm$ 2.11	0.004
DSA	30	15.02 $\pm$ 1.98	21.93 $\pm$ 2.37	0.002



**Figure 2.** Postoperative DynaCT 3D reconstruction images showed that bone cement was well dispersed without leakage.

#### Adverse reactions

In the DynaCT+DSA treatment group, a total of 33 lesioned vertebral bodies were treated and bone cement leakage was found in 8 cases (8/33, 24.3%) including 6 cases of

paravertebral venous leakages (6/33, 18.2%) and 2 cases of intervertebral spacer leakages (2/33, 6.1%). In the DSA treatment group, a total of 38 lesioned vertebral bodies were treated and bone cement leakage was found in 7 cases

(8/33, 24.3%) including 2 cases of paravertebral venous leakages (6/33, 18.2%) and 5 cases of intervertebral space leakages (2/33, 6.1%). Some patients had postoperative pain and soreness at the puncture site and were relieved after anti-inflammatory and anti-infective treatments. None of the patients had complications such as spinal cord, nerve root compression, or pulmonary embolism (Figure 2).

## Discussion

### *Characteristics of DynaCT imaging technique*

DynaCT is a new imaging technique based on DSA to generate CT-like images. Data were collected through rotation and then transferred to workstation. After that, corresponding software will be used to reconstruct the cross-section, coronal plane, sagittal plane and three-dimensional image<sup>3</sup>. This technique can clearly show the structure and blood vessels through the tomography and three-dimensional images, and provide the surgeon with information that cannot be obtained by conventional DSA. It has obvious advantages in showing the details of the lesion, the distribution of small blood vessels, and the presence or absence of local bleeding. So the success rate and accuracy of puncture were increased. At present, DynaCT technology has been widely used in the nerve intervention<sup>4</sup>, and the application in bone and joint intervention is relatively less. Compared with helical CT, DynaCT is relatively worse in density resolution and spatial resolution. However, DSA can provide real-time images during interventional surgery, and the three-dimensional DynaCT images can be used to obtain anatomical information of cross-section that cannot be obtained by traditional DSA, which is conducive to the design of surgical procedures, intraoperative observation of surgical conditions, postoperative examination of outcomes, and determination of the occurrence of complications. This technique provided valuable information for the selection of surgical path of PKP and PVP, so as to increase the quality of surgery. Significant improvements in VAS score and depth of vertebral body's maximal collapse were found in both groups after surgery, indicating that the precise positioning of DynaCT can bring similar surgical outcomes.

### *Puncture and biopsy guided by DynaCT in PKP*

Before PKP, DynaCT scan can directly show the degree of bone destruction of the vertebrae, vertebral posterior margin integrity and changes in the curvature of the spine, so as to identify the "responsible lesion" that causes pain. Puncture plan can be made according to the location and degree of vertebral bone destruction, the use of unilateral or bilateral puncture, puncture needle abduction, and the angle of needle<sup>5</sup>. Needle insertion by DSA guidance was performed according to the measurement data from preoperative CT. Corresponding reconstruction technique was immediately used to show the relative position of the puncture needle and pedicle after the needle reached the pedicle. In this study, 71 cases of diseased vertebrae were treated in the two groups

of patients, and puncture was performed for 119 times. Among the 119 times of puncture, needle was adjusted for 25 times using the information obtained from reconstructed cross-section images to increase the safety. For patients with localized bone destruction, the angle of needle should be adjusted before puncture needle enter the vertebrae. The needle tip should reach the center region of lesions, and bone cement should be fully dispersed in lesion area to improve treatment effect. It has been reported that<sup>6</sup> DSA rotation imaging technique can ensure the accuracy of puncture, but the guidance process requires a special puncture frame, and the operation process is relatively complex.

### *The evaluation of the use of DynaCT in the bone cement leakage after PKP*

Bone cement leakage is the main adverse reaction of PKP treatment. Bone cement leakage can be classified into different groups according to the ways or positions of leakage<sup>7</sup>. In this study, balloon dilatation was performed during PKP surgery to create a cavity in the lesion area of vertebrae, which in turn reduced the occurrence of leakage under low pressure. In this study, leakage rate of bone cement in DynaCT group was significantly higher than that in DSA group. The possible explanation is that drainage veins of some vertebrae are thin and bone cement infiltration may not be observed by DSA. With high resolution, DynaCT can timely detect the distribution of bone cement from sagittal, coronal and cross-sectional angles, so as to increase the probability of finding minor bone cement leakage, vertebral epidural leakage, and intervertebral foramen leakage.

The mechanism of pain relief after PKP is still unclear. It has been reported that cytotoxicity of bone cement can lead to tumor tissue necrosis, reduce sensitivity of nerve endings in peripheral tissue, increase spinal stability and reduce physical and chemical, mechanical irritation, which in turn reduce the pain. It is reported that the analgesic effect is not proportional to the amount of bone cement used in injection, while the mechanical support is positively correlated with the dosage of injection, so it is not necessary to fill the entire vertebrae<sup>8,9</sup>. In this study, each vertebral bone was injected with 3~10 ml of bone cement with an average volume of 4.2 ml. Compared with preoperative levels, VAS scores were significantly reduced, and maximal depth of the affected vertebrae was significantly increased.

In conclusion, PKP is a safe, effective and easy-to-use minimally invasive technique for the treatment of thoracolumbar vertebral compression fractures. It can rapidly relieve pain, restore function, and significantly reduce bed rest time. DynaCT technology combines the advantages of DSA and helical CT. It can provide cross-section images to ensure the accuracy of puncture, and can also dynamically monitor bone cement dispersion. Performs of DynaCT are comparable to helical CT in preoperative observation of cortical continuity and postoperative observation of bone cement leakage, and surgical accuracy was increased. Therefore, DynaCT technology should be popularized in PKP.



#### Authors' contributions

GH drafted this manuscript. GH and QY collected and interpreted the data. KY and ZG revised it critically for important intellectual content. GH and AH were responsible for the conception and design of the study. All authors read and approved the final manuscript.

#### Ethics approval and consent to participate

The study was approved by the Ethics Committee of The Second People's Hospital of Weifang. Signed written informed consents were obtained from the patients and/or guardians.

## References

1. Jost GF, Walti J, Mariani L and Cattin P. A novel approach to navigated implantation of S-2 alar iliac screws using inertial measurement units. *J Neurosurg Spine* 2016; 24:447-453.
2. Bredow J, Oppermann J, Kraus B, Schiller P, Schiffer G, Sobottke R, Eysel P and Koy T. The accuracy of 3D fluoroscopy-navigated screw insertion in the upper and subaxial cervical spine. *Eur Spine J* 2015; 24:2967-2976.
3. Gailloud P, Oishi S and Murphy K. Three-dimensional fusion digital subtraction angiography: new reconstruction algorithm for simultaneous three-dimensional rendering of osseous and vascular information obtained during rotational angiography. *AJNR Am J Neuroradiol* 2005;26:908-911.
4. Lu T, Chinnadurai P, Anaya-Ayala JE and Diaz OM. DynaCT angiography for the diagnosis of bilateral bow hunter's syndrome. *Int Neuroradiol* 2017;23:73-78.
5. Yang Z, Tan J, Xu Y, Sun H, Xie L, Zhao R, Wang J and Jiang H. Treatment of MM-associated spinal fracture with percutaneous vertebroplasty (PVP) and chemotherapy. *Eur Spine J* 2012;21:912-919.
6. Stephenson MB, Glaenger B and Malamis A. Percutaneous minimally invasive techniques in the treatment of spinal metastases. *Curr Treat Options Oncol* 2016;17:56.
7. Vanni D, Galzio R, Kazakova A, Pantalone A, Grillea G, Bartolo M, Salini V and Magliani V. Third-generation percutaneous vertebral augmentation systems. *J Spine Surg* 2016;2:13-20.
8. Kaufmann TJ, Trout AT and Kallmes DF. The effects of cement volume on clinical outcomes of percutaneous vertebroplasty. *AJNR Am J Neuroradiol* 2006; 27:1933-1937.
9. Sebaaly A, Nabhane L, Issa El Khoury F, Kreichati G and El Rachkidi R. Vertebral augmentation: state of the art. *Asian Spine J* 2016;10:370-376.