

Sclerotherapy using 1% sodium tetradecyl sulfate to treat a vascular malformation: a report of two cases

Hong-Gi Min, Su-Gwan Kim, Ji-Su Oh, Jae-Seek You

Department of Oral and Maxillofacial Surgery, School of Dentistry, Chosun University, Gwangju, Korea

Abstract (J Korean Assoc Oral Maxillofac Surg 2015;41:322-326)

Vascular malformations are the most common congenital and neonatal vascular anomalies in the head and neck region. The demand for simple and esthetic vascular malformation treatments have increased more recently. In this study, two patients that were diagnosed with venous malformations were treated with sodium tetradecyl sulfate as a sclerosing agent. Recurrence was not found one year after the surgery. This article gives a brief case report of sclerotherapy as an effective approach to treat vascular malformations in the oral cavity.

Key words: Hemangioma, Vascular diseases, Vascular malformation

[paper submitted 2015. 4. 23 / revised 2015. 6. 11 / accepted 2015. 6. 11]

I. Introduction

A vascular malformation is a congenital lesion that occurs frequently in the oral cavity, in the head, and in the neck, and vascular malformations are bluish, compressible, and non-pulsatile¹. Because vascular malformations do not have clinically specific symptoms and do not resolve independently, they must be treated with laser therapy, embolization, electrocauterization, steroid administration, surgical removal, or sclerotherapy, depending on the type, location, and depth of the lesion and the patient's conditions²⁻⁵.

There are several agents that are used for sclerotherapy, and sodium tetradecyl sulfate is known to induce extra-vascular inflammation as well as thrombosis, resulting in ischemic necrosis of blood vessels⁶.

Two patients visited the Department of Oral and Maxillofacial Surgery at Chosun University Dental Hospital (Gwangju, Korea) to be treated for intraoral vascular malformations, and

we injected 1% sodium tetradecyl sulfate into the lesions. After treatment, the lesions degenerated, and the results were aesthetically satisfying to the patients. The treatments were effective, within a short period of time after the injection and no lesion recurrence was observed one year postoperatively. We are providing the patient case reports and discussion about this treatment application.

II. Cases Report

The patients were given explanations of various types of treatment and they opted for 1% sodium tetradecyl sulfate (Tromboject; Omega, Montreal, QC, Canada) to induce vascular sclerosis in the lesions, because both patients wanted a safe, noninvasive therapy.

1. Case 1

A 57-year-old man visited the hospital, mainly because of painless soft tissue swelling in the tongue, in the left buccal mucosa, and in the lower lip.(Fig. 1) He had first noticed symptoms in his tongue about ten years previously and had noticed symptoms in the lower lip and in the left buccal mucosa for a year. Magnetic resonance imaging (MRI) found severe soft tissue hypertrophy on the left side of the tongue. (Fig. 2) The MRI indicated that there was a 3×3 cm region in tongue, and the sizes of the multiple buccal mucosa varied.

Su-Gwan Kim

Department of Oral and Maxillofacial Surgery, College of Dentistry, Chosun University, 303 Pilmun-daero, Dong-gu, Gwangju 61452, Korea

TEL: +82-62-220-3815 FAX: +82-62-228-7316

E-mail: sgckim@chosun.ac.kr

ORCID: <http://orcid.org/0000-0002-0424-9984>

©This is an open-access article distributed under the terms of the Creative Commons Attribution Non-Commercial License (<http://creativecommons.org/licenses/by-nc/4.0/>), which permits unrestricted non-commercial use, distribution, and reproduction in any medium, provided the original work is properly cited.

Copyright © 2015 The Korean Association of Oral and Maxillofacial Surgeons. All rights reserved.

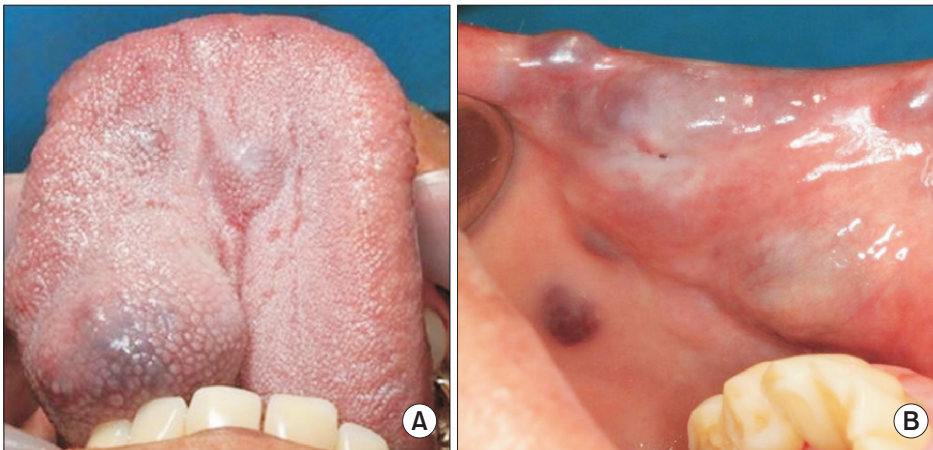


Fig. 1. Multicentric venous malformations of the tongue (A) and oral mucosa (B) in a 57-year-old man before sclerotherapy.

Hong-Gi Min et al: Sclerotherapy using 1% sodium tetradecyl sulfate to treat a vascular malformation: a report of two cases. J Korean Assoc Oral Maxillofac Surg 2015

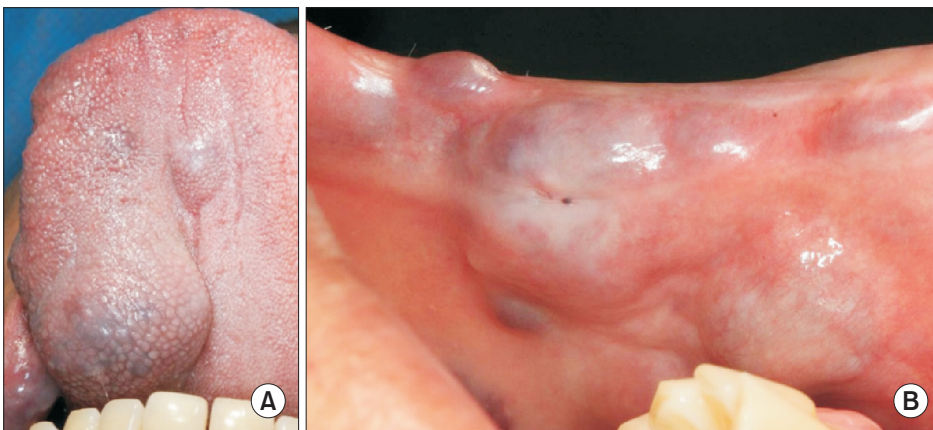


Fig. 3. The lesion still remained two months after the 1% sodium tetradecyl sulfate injection. A. Tongue. B. Oral mucosa.

Hong-Gi Min et al: Sclerotherapy using 1% sodium tetradecyl sulfate to treat a vascular malformation: a report of two cases. J Korean Assoc Oral Maxillofac Surg 2015

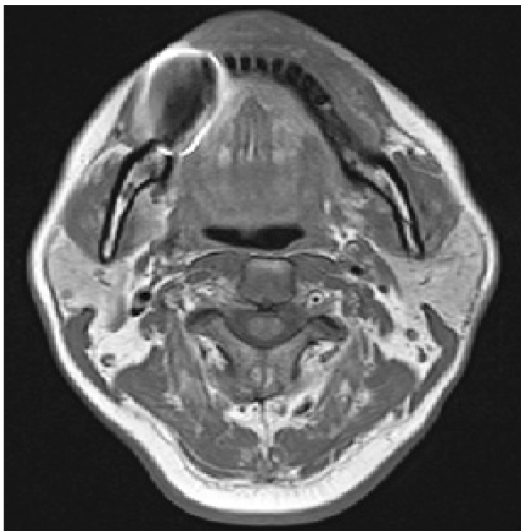


Fig. 2. Preoperative magnetic resonance imaging axial view.
Hong-Gi Min et al: Sclerotherapy using 1% sodium tetradecyl sulfate to treat a vascular malformation: a report of two cases. J Korean Assoc Oral Maxillofac Surg 2015

The patient was diagnosed with multiple vein malformations and 2 mL of 1% sodium tetradecyl sulfate was directly injected into the lesions (1 mL on the tongue and 1 mL on multiple

buccal mucosa lesions) according to the manufacturer's instructions. Wet gauze was used to apply pressure about 5 minutes after the injection. A week later, another injection of 1% sodium tetradecyl sulfate was given in the same doses into the lesions in the lower lip and in the left buccal mucosa. When he revisited the hospital two months later, all of the lesions had disappeared.(Fig. 3) All of the patient's intraoral lesions satisfactorily degenerated two months later, and upon follow-up, the patient has not developed any specific complications for a full year after the treatment was finished.(Fig. 4)

2. Case 2

A 45-year-old man visited the hospital mainly because of painless red swelling in the left buccal mucosa.(Fig. 5) He had experienced the condition for seven or eight years and was clinically diagnosed with venous malformation in the left buccal mucosa. On the day he visited the hospital, 1 mL of 1% sodium tetradecyl sulfate was directly injected into the lesion, according to the manufacturer's instructions. Two weeks later, he complained of mild pain at the treatment site;

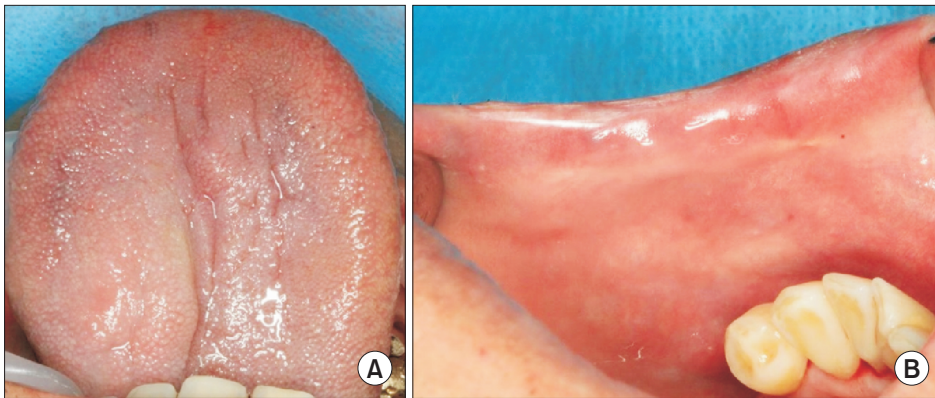


Fig. 4. The lesion had almost completely regressed four months after the 1% sodium tetradecyl sulfate injection. A. Tongue. B. Oral mucosa.
Hong-Gi Min et al: Sclerotherapy using 1% sodium tetradecyl sulfate to treat a vascular malformation: a report of two cases. J Korean Assoc Oral Maxillofac Surg 2015

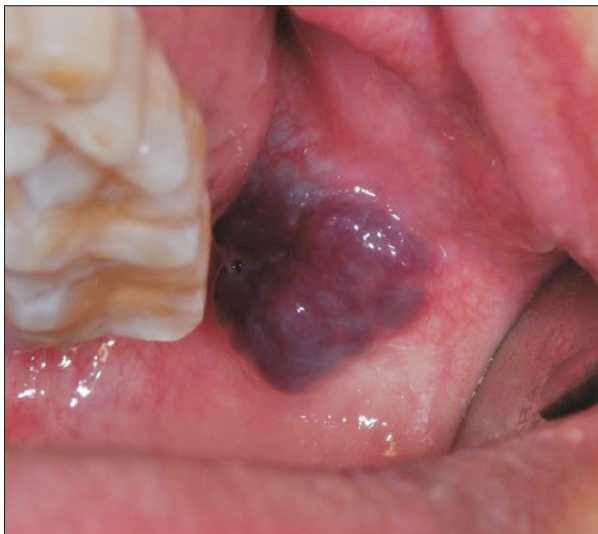

Fig. 5. Venous malformation of the left buccal mucosa before sclerotherapy.
Hong-Gi Min et al: Sclerotherapy using 1% sodium tetradecyl sulfate to treat a vascular malformation: a report of two cases. J Korean Assoc Oral Maxillofac Surg 2015

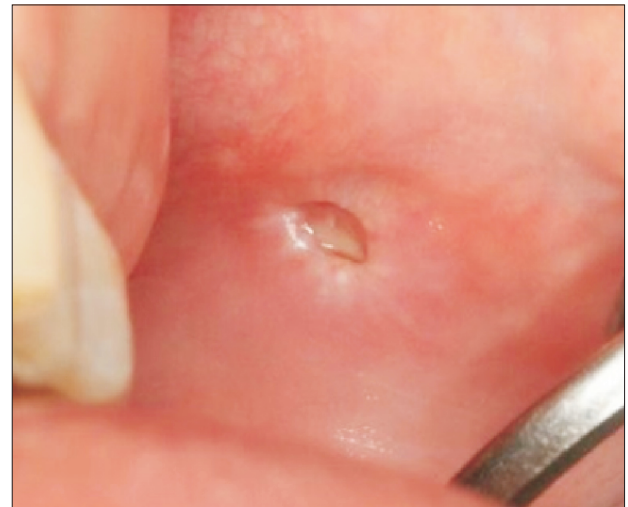

Fig. 7. The lesion had almost completely regressed four weeks after the 1% sodium tetradecyl sulfate injection.
Hong-Gi Min et al: Sclerotherapy using 1% sodium tetradecyl sulfate to treat a vascular malformation: a report of two cases. J Korean Assoc Oral Maxillofac Surg 2015

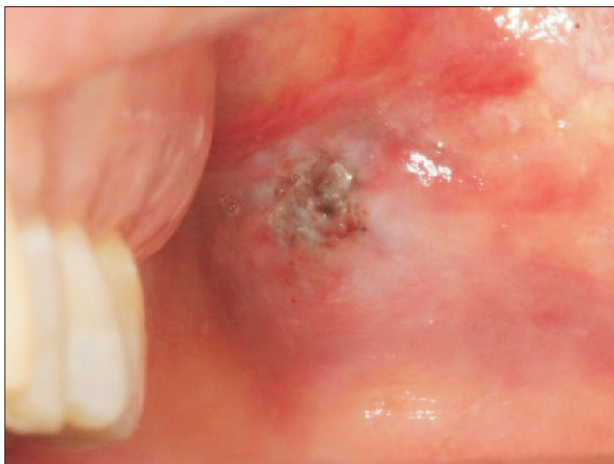

Fig. 6. The lesion still remained two weeks after the 1% sodium tetradecyl sulfate injection.
Hong-Gi Min et al: Sclerotherapy using 1% sodium tetradecyl sulfate to treat a vascular malformation: a report of two cases. J Korean Assoc Oral Maxillofac Surg 2015

however, the lesion became smaller and normal color was returning to the site.(Fig. 6) When he revisited the hospital two weeks later, the pain had subsided, the lesion had completely degenerated, and the site had regained normal color.(Fig. 7) The patient has maintained good conditions and has not experienced lesion recurrence for a year after the treatment was completed.

III. Discussion

Mulliken and Glowacki⁷ note that vascular malformations are congenital and tend to become more visible over time, even if they are not observed in early stages. These types of malformations can be classified into arterial, arteriovenous, venous, capillary, and lymphatic malformations, based on the blood vessel that is associated with the lesion. The male-to-female ratio of occurrence is 1 to 1, and the process

involves constant expansion of an abnormal blood vessel that is surrounded by squamous endothelial cells, with no cellular hyperplasia in the histological respect. Waner and Suen⁸ grouped arterial and arteriovenous malformations into fast flow lesions and venous, capillary, and lymphatic malformations into slow flow lesions.

Clinically, the malformations are bluish, compressible, and non-pulsatile and they are primarily connected with various anatomical structures in outer and deep layers¹. An intraoral lesion tends to be asymptomatic in many cases, but never disappears by itself and results in bleeding, pain, tissue necrosis, secondary infection, or aesthetic defects, if neglected^{2,4,9}. An intraoral lesion can be treated with surgical removal, embolization, cryotherapy, steroid administration, laser therapy, sclerotherapy, or a combination of these techniques³⁻⁵. Since the treatment depends on the type, location, and size of lesions, it is essential to correctly examine the malformation. Doppler ultrasound is recommended for examination and can best be supplemented by computed tomography or by MRI¹⁰.

Surgical removal is the most widely-used method to treat vascular malformations. However, the demand for less invasive treatments, which are useful especially in cases that involve important anatomical structures or small lesions, has resulted in the introduction of sclerotherapy¹¹. The sclerosants used to treat the condition include ethanolamine oleate, et-hibloc, bleomycin, and sodium tetradecyl sulfate^{11,12}. These agents commonly provide a stimulus to vascular endothelial intima, induce extra-vascular inflammatory reactions, and ultimately cause vascular fibrosis and occlusion.

Of these, ethanolamine oleate is known to be a sclerosant with the lowest recurrence rate, which is effective even against venous malformation lesions that are more than 5 cm in diameter. However, this agent should be injected with care because it can affect normal structures if it flows into neighboring normal tissues¹. Johann et al.¹³ injected 1.25% or 2.5% ethanolamine oleate into intraoral vascular malformation lesions in thirty patients at fifteen-day intervals. They found that more than 20 mm lesions disappeared with six injections on average, and less than 20 mm lesions disappeared with two injections, on average. They reported that seventeen patients complained of symptoms that included pain, edema, and flare for a maximum of 72 hours after the treatment, and, similarly, the patient in the second case of this study experienced mild pain after the treatment.

Hassan et al.¹¹ injected a maximum of 15 mg bleomycin into intravascular lesions, three or four times on average and six times at maximum, in 69 patients and observed definite

improvement in 71% of the patients. This result demonstrates that simple, noninvasive sclerotherapy, instead of surgical treatment, can generate good and aesthetically pleasing results. Additionally, definite lesion degeneration was found in both cases in this study.

Similar to the other sclerosants, sodium tetradecyl sulfate also induces extra-vascular inflammatory reactions and causes vascular fibrosis and occlusion. Baurmash and Mandel¹⁴ reported that sodium tetradecyl sulfate injected into vascular malformation lesions could induce allergic and anaphylactic reactions. An injection of 0.5 to 2 mL per dose in lesions is possible, and the minimum dose is recommended. In addition, an injection dose greater than 2 mL is not recommended in one lesion, but interval injections over 5 to 7 days are recommended, based on the manufacturer's instructions.

In these cases, since the lesions were in the outer layer and were relatively small, sclerotherapy that applied 1% sodium tetradecyl sulfate injected directly into the lesions was used to minimize both the side effects of the agent and the surgical burden on the patient. A maximum of two injections of the sclerosant generated lesion degeneration and aesthetically satisfactory effects in both cases. The treatment was finished when no recurrence was found in either patient upon follow-up a year later. However, it is unreasonable to use sclerotherapy alone for large-sized vascular lesions in the deep layer. In such cases, it is possible to use sclerotherapy as supplementary therapy before a surgical procedure to preoperatively reduce the size of the lesions¹³.

Conflict of Interest

No potential conflict of interest relevant to this article was reported.

ORCID

Hong-Gi Min, <http://orcid.org/0000-0003-1741-6830>
 Su-Gwan Kim, <http://orcid.org/0000-0002-0424-9984>
 Ji-Su Oh, <http://orcid.org/0000-0002-8369-5025>
 Jae-Seek You, <http://orcid.org/0000-0001-7638-9583>

References

1. Zheng JW, Zhou Q, Yang XJ, Wang YA, Fan XD, Zhou GY, et al. Treatment guideline for hemangiomas and vascular malformations of the head and neck. *Head Neck* 2010;32:1088-98.
2. Kohout MP, Hansen M, Pribaz JJ, Mulliken JB. Arteriovenous malformations of the head and neck: natural history and management.

- Plast Reconstr Surg 1998;102:643-54.
3. Hohenleutner S, Badur-Ganter E, Landthaler M, Hohenleutner U. Long-term results in the treatment of childhood hemangioma with the flashlamp-pumped pulsed dye laser: an evaluation of 617 cases. *Lasers Surg Med* 2001;28:273-7.
 4. Kim JY, Kim DI, Do YS, Lee BB, Kim YW, Shin SW, et al. Surgical treatment for congenital arteriovenous malformation: 10 years' experience. *Eur J Vasc Endovasc Surg* 2006;32:101-6.
 5. Sadan N, Wolach B. Treatment of hemangiomas of infants with high doses of prednisone. *J Pediatr* 1996;128:141-6.
 6. Ramírez-Amador V, Esquivel-Pedraza L, Lozada-Nur F, De la Rosa-García E, Volkow-Fernández P, Súchil-Bernal L, et al. Intralesional vinblastine vs. 3% sodium tetradecyl sulfate for the treatment of oral Kaposi's sarcoma: a double blind, randomized clinical trial. *Oral Oncol* 2002;38:460-7.
 7. Mulliken JB, Glowacki J. Hemangiomas and vascular malformations in infants and children: a classification based on endothelial characteristics. *Plast Reconstr Surg* 1982;69:412-22.
 8. Waner M, Suen JY. Hemangiomas and vascular malformations of the head and neck. New York: Wiley-Liss; 1999.
 9. Buckmiller LM, Richter GT, Suen JY. Diagnosis and management of hemangiomas and vascular malformations of the head and neck. *Oral Dis* 2010;16:405-18.
 10. Dubois J, Garel L. Imaging and therapeutic approach of hemangiomas and vascular malformations in the pediatric age group. *Pediatr Radiol* 1999;29:879-93.
 11. Hassan Y, Osman AK, Altyeb A. Noninvasive management of hemangioma and vascular malformation using intralesional bleomycin injection. *Ann Plast Surg* 2013;70:70-3.
 12. da Silva WB, Ribeiro AL, de Menezes SA, de Jesus Viana Pinheiro J, de Melo Alves-Junior S. Oral capillary hemangioma: a clinical protocol of diagnosis and treatment in adults. *Oral Maxillofac Surg* 2014;18:431-7.
 13. Johann AC, Aguiar MC, do Carmo MA, Gomez RS, Castro WH, Mesquita RA. Sclerotherapy of benign oral vascular lesion with ethanolamine oleate: an open clinical trial with 30 lesions. *Oral Surg Oral Med Oral Pathol Oral Radiol Endod* 2005;100:579-84.
 14. Baurmash H, Mandel L. The nonsurgical treatment of hemangioma with Sotradecol. *Oral Surg Oral Med Oral Pathol* 1963;16:777-82.