

Functional and clinical anatomy of the obturator externus muscle: Cadaveric studies and clinical findings for total hip arthroplasty in the posterior approach

Yasuhiko Kawaguchi^{a,b,*}, Takuya Otani^{a,b}, Hideki Fujii^a, Tetsuo Hayama^a, Keishi Marumo^a, Mitsuru Saito^a

^a Department of Orthopaedic Surgery, The Jikei University School of Medicine, 3-25-8 Nishi-Shinbashi, Minato-ku, Tokyo, 105-8461, Japan

^b Department of Orthopaedic Surgery, The Jikei University DAISAN Hospital, 4-11-1 Izumi-Honcho, Komae-shi, Tokyo, 201-8601, Japan

ARTICLE INFO

Keywords:

Obturator externus
External rotator muscles
Total hip arthroplasty (THA)
Posterior approach

ABSTRACT

Repairing released posterior soft tissues is important in preventing dislocation after total hip arthroplasty (THA) via the posterior approach. We clarify the functional and the clinical anatomy of obturator externus. We performed cadaveric studies and investigated clinically in primary THA cases. The location, trajectory, and size of the muscular tendon was recorded. The trajectory of the obturator externus ran orthogonal to the femoral axis with the hip in 90° flexion whereas that of the obturator internus muscle ran parallel. Because the trajectory of obturator externus and the obturator internus differ, their functions also differ.

1. Introduction

The posterior approach is a basic approach to the hip joint and is currently one of the most frequently used approaches in universal total hip arthroplasty (THA). Regarding the posterior approach to the hip, the joint is typically exposed by releasing the tendon of the three short external rotators, the piriformis, the conjoined tendon of the superior gemellus, the obturator internus, the inferior gemellus, and the external obturator tendon from the greater trochanter. The importance of repairing the released posterior soft tissues in preventing dislocations after THA via the posterior approach has been reported in recent years.^{1–4} However, details of the role of each posterior tissue, and the underlying mechanism by which they contribute to preventing dislocation has not been elucidated.

Of the short external rotators, the literature has limited information on the obturator externus muscle in particular. In the classic and representative reports regarding the posterior approach to the hip by Osborne⁵ and Moore,⁶ while the release of the piriformis tendon and the conjoined tendon are described, there is no description on the procedure for the obturator externus tendon. The procedure is described as having sufficient exposure from the neck region to the lesser trochanter, and so even though the obturator externus tendon appears to be released, there

is no clear description. This may be because the muscle has a different trajectory from the other external rotators, and the muscle belly lies deep to the surgical field on the distal aspect of the joint, and with deep retraction once the tendon is released, it is difficult to verify under direct vision.

As such, while reports regarding the obturator externus and its anatomy, function, and actual clinical findings in THA are few, there have been some reports of studies in recent years regarding its anatomy,^{7,8} function,^{9,10} and relevant clinical findings.¹¹

The authors considered that the obturator externus has a completely different trajectory from the other external rotators, and so initiated basic studies on the obturator externus muscle in 2008 and clinical studies from December 2008, in THA via the posterior approach. This also included repair of the obturator externus tendon in addition to the previously performed piriformis tendon, conjoined tendon, and the posterior capsule repair. The basic science study reported on anatomy and function from cadaveric studies in 2009¹² and 2014,¹³ but these were reported only in Japanese. The clinical study reported focused on the effect of obturator externus repair on clinical outcomes after THA via the posterior approach.¹⁴

The purpose of this study was to describe the functional anatomy of the obturator externus based on basic cadaveric studies performed by

* Corresponding author. Department of Orthopaedic Surgery, The Jikei University School of Medicine, 3-25-8 Nishi-Shinbashi, Minato-ku, Tokyo, 105-8461, Japan.

E-mail address: y.kawaguchi@jikei.ac.jp (Y. Kawaguchi).

<https://doi.org/10.1016/j.jor.2021.04.002>

Received 29 December 2020; Received in revised form 5 March 2021; Accepted 16 April 2021

Available online 21 April 2021

0972-978X/© 2021 Published by Elsevier B.V. on behalf of Professor P K Surendran Memorial Education Foundation.

the authors in the English literature, and to elucidate the clinical anatomy of the actual appearance of the obturator externus in comparison to the other external rotators during THA surgery performed via a posterior approach.

The cadaveric studies were implemented under the guidance of a qualified anatomist. In addition, both the cadaveric and the clinical studies were implemented with approval of the Institutional Review Board of the authors' institution. Informed consent was obtained from all patients. Permission to publish the Japanese studies from 2009 to 2014 in English has been duly obtained from the Japanese Hip Society.

2. Materials and methods

2.1. Cadaveric investigations

2.1.1. Comparative study on the functional anatomy of the obturator externus and obturator internus from the standpoint of preventing hip dislocation after THA¹²

One formalin-treated cadaver hip joint from one adult (male, 78 years) subject donated to the university anatomy department was used. It was confirmed that the hip joint had no obvious deformities or joint disease. Leaving the entire obturator internus and the obturator externus *in situ*, all other soft tissues were removed from the hip joint, and an experimental specimen comprising the sacrum, pelvis, and proximal femur was constructed. The trajectory of the obturator internus and the obturator externus along with the change in tension of the muscles were observed by stabilizing the specimen's pelvis with passive movement of the femur. Because the obturator internus bends as it runs over the lesser sciatic notch, the trajectory of the tendon was observed to be the direction of action of the muscle traction force around its insertion to the greater trochanter. Tension was observed for adduction, abduction, internal rotation, and external rotation with the hip joint in neutral and 90° flexion. With the initiation of motion as baseline (0), tension the same as baseline was evaluated as (0), mild increase in tension as (+), increase as (++) , marked increase as (+++), mild relaxation as (-), and relaxation as (-).

2.1.2. Functional anatomy of the obturator externus accompanying hip motion¹³

Six formalin-treated hip joints from three adult cadavers (2 males and 1 female, range 78 years) donated to the university anatomy department were used. All hip joints were confirmed to have no obvious deformities or hip joint disease. The entire obturator externus and part of the capsule were left *in situ* while the soft tissues were removed from around the hip joint and experimental specimens comprising the sacrum, pelvis, and proximal femur were constructed. First, the location of the insertion of the obturator externus tendon to the greater trochanter was observed and recorded. Next, the tension on the obturator externus was observed for each of the flexion angles 0°, 60°, and 90° in the position of neutral adduction/abduction and neutral internal rotation/external rotation. Also, at flexion angles 0°, 60°, and 90°, the tension on the obturator externus was observed by adding internal rotation. Each motion was repeated 3 times, and the status of the obturator externus was recorded with a digital video camera. In evaluating the tension on the obturator externus, the muscle was divided into 3 regions (anterior, middle and posterior), tension status at neutral position was considered baseline, and tension the same as baseline was evaluated as (0), mild increase in tension as (+), increase as (++) , marked increase as (+++), mild relaxation as (-), and relaxation as (-).

2.2. Clinical investigation: clinical anatomy of the obturator externus in THA via the posterior approach

The cases were 141 hips in 137 consecutive patients for whom primary THA was performed via the posterior approach in our department. Hips with previous surgeries or trauma, or those with history of

treatment for Perthes disease or septic hip arthritis were excluded. There were 113 females and 28 males, and mean age at time of surgery was 65 (range, 37–91) years. In total, 119 patients had hip osteoarthritis, 12 had avascular necrosis of the femoral head, and 4 had rheumatoid arthritis. All surgeries utilized the posterior approach with the patient in the lateral decubitus position. The external rotators from the piriformis to the obturator externus were released from their insertion to the greater trochanter together with the underlying posterior capsule. After placement of the implant, during the repair of the soft tissues in the posterior aspect of the hip joint, I) the piriformis tendon, II) the conjoined tendon (bundle of superior and inferior gemelli and the obturator internus), and III) the obturator externus tendon were identified, and their locations and trajectory directions were observed. The identified location of the released end of the obturator externus tendon was recorded in detail defining the superior aspect of the acetabulum as 12 o'clock, the posterior aspect as 3 o'clock, and the inferior aspect as 6 o'clock in relation to the capsule. Also, for the three identified external rotator tendons, the transverse and longitudinal diameters of the elliptical shaped released cross-sectional area were measured with a ruler. The area of the ellipse was approximated as major diameter/2 × minor diameter/2 × π (3.14) and the cross-sectional area of each tendon was calculated and compared.

3. Results

3.1. Cadaveric investigations

3.1.1. Comparative study on the functional anatomy of the obturator externus and obturator internus from the standpoint of preventing hip dislocation after THA¹²

3.1.1.1. Trajectory of tendons. Regarding the trajectory of tendons close to the insertion to the greater trochanter, at neutral, the obturator internus tendon ran from the posteromedial aspect to the anterolateral aspect after circumscribing the posterior margin of the ischium; the obturator externus ran almost entirely from the medial to the lateral aspect, and in the coronal plane, the trajectory of both tendons was showed orthogonal to the axis of the femur (Fig. 1).

At 90° flexion, the direction of the axis of the femur was changed, the trajectory of the obturator internus in the axial plane ran oblique to the femoral axis, and in the sagittal plane, the direction became the same as that of the femoral axis. In contrast, the obturator externus tendon ran from the medial to the lateral aspect just orthogonal to the femoral axis in the axial plane when the hip was in flexion (Fig. 2).

3.1.1.2. Change in muscle tension with motion. For moving the hip to adduction, abduction, internal rotation, and external rotation from neutral position and from 90° flexion, changes in tension for the obturator internus and obturator externus are shown in Table 1.

In internal rotation at the neutral position, both the obturator internus and obturator externus had marked increased in tension. At 90° flexion, the tension on the obturator externus markedly increased with internal rotation. In contrast, tension on the obturator internus only mildly increased with internal rotation, but markedly increased in adduction.

3.1.2. Functional anatomy of the obturator externus accompanying hip motion¹³

The insertion of the obturator externus to the greater trochanter was fixed at the trochanteric fossa 25–38 (mean 32) mm distal to the piriformis fossa, with almost no variations amongst the specimens. Changes in tension in the anterior, middle, and posterior fibers of the obturator externus accompanying the flexion motion as well as internal rotation are shown in Table 2.

In flexion motion from 0° to 60°, all fibers relaxed from anterior to

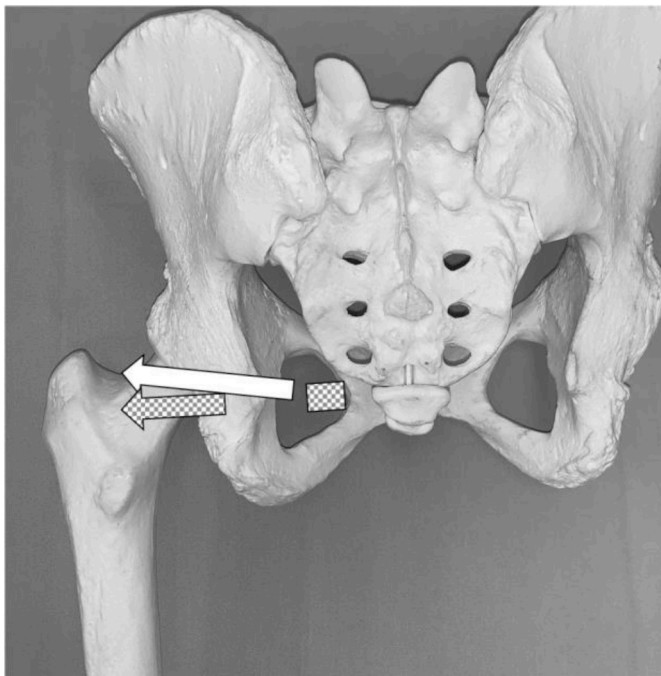


Fig. 1. Direction of the obturator externus (meshed arrow) and obturator internus (white arrow) tendons relative to the axis of the femur in neutral position (coronal plane). The trajectory of both tendons is orthogonal to the axis of the femur.

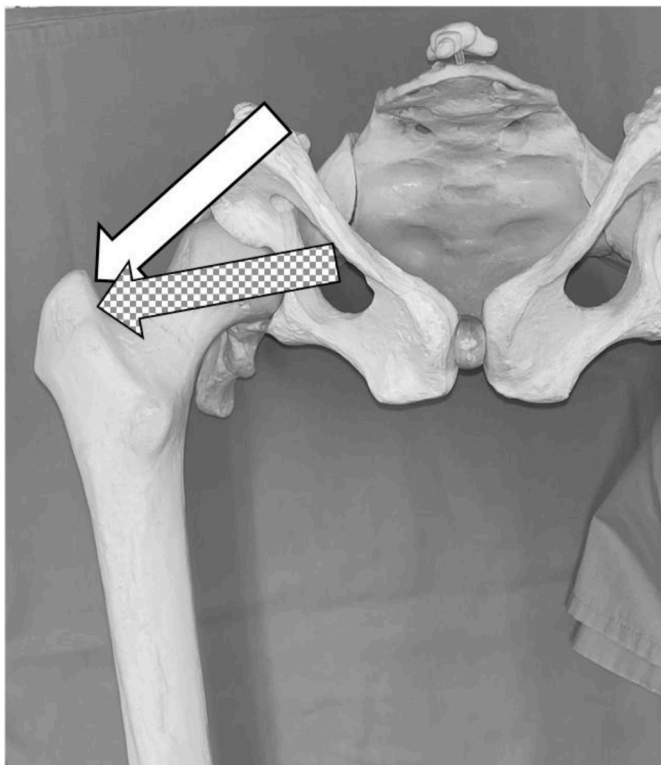


Fig. 2. Direction of obturator externus (meshed arrow) and obturator internus (white arrow) tendons relative to femoral axis at 90° flexion (axial plane). In hip flexion, obturator internus trajectory runs oblique to femoral axis. Obturator externus runs orthogonal to femoral axis.

Table 1

Changes in tension of the obturator internus and obturator externus with various hip motion from the neutral position and from 90° flexion.¹²

1) Neutral position		
	Obturator internus	Obturator externus
Adduction	++	--
Abduction	--	+++
Internal rotation	+++	+++
External rotation	--	--
2) 90° flexion		
	Obturator internus	Obturator externus
Adduction	+++	--
Abduction	--	++
Internal rotation	+	+++
External rotation	-	--

With initiation of motion as baseline, tension the same as baseline was recorded as (0), mild increase in tension as (+), increase as (++), marked increase as (+++), mild relaxation as (-), and relaxation as (--). Cited from reference.

posterior, but at flexion of approximately 60°, the posterior fibers gradually started to regain tension. From 60° to 90° flexion, all fibers of the obturator externus increased in tension while producing a twist, and at 90° flexion, the anterior and middle fibers returned to tension similar to that of neutral, with an associated increase in tension in the posterior fibers. In contrast, during internal rotation motion of the hip joint, increased tension was noted at all flexion angles, especially at 90° flexion, where the largest tension in the posterior fibers was observed.

3.2. Clinical investigation: clinical anatomy of the obturator externus in THA via the posterior approach

During closure, in identifying the released end of the three tendons, the piriformis tendon lay posteromedially and somewhat superior to the greater trochanter in the superficial layer; the conjoint tendon was posteromedial to the greater trochanter a little deeper to the piriformis tendon next to the capsule and these were easily found. When the retracted tendon was pulled with forceps, the piriformis tendon ran posteromedially, and somewhat superiorly, while the conjoint tendon ran posteromedially also. Conversely, the end of the obturator externus tendon had retracted to a position completely different from these other tendons, and differentiating this from the surrounding soft tissues was difficult and it was somewhat hard to find. However, it was identified by picking up the soft tissue adjacent to the capsule with forceps from the posterior aspect of the hip joint to the inferior aspect. For 5 out of the 141 hips (3.5%), a clear tendinous material could not be identified and the dimension of the released end could not be measured. After several cases, identification of the obturator externus tendon became easier, and time to detection was thus shortened.

In the 136 hips where the obturator externus tendon was identified, the location of the released end was at 4 o'clock in 90 hips (66%), 5 o'clock in 43 hips (32%), and 6 o'clock in 3 hips (2%). The trajectory of the tendon differed completely from the posteromedial trajectory of the other 2 tendons, and ran along the inferior face of the capsule towards the medial and somewhat anterior direction.

The transverse/longitudinal diameters of the cross-sections of the 3 tendons were I) 4–13 mm/3–10 mm (mean 7.9 ± 0.2/5.0 ± 0.2 mm) for the piriformis tendon, II) 7–20 mm/4–11 mm (mean 12.2 ± 0.2/6.1 ± 0.1 mm) for the conjoint tendon, and 6–14 mm/3–8 mm (mean 9.1 ± 0.2/4.5 ± 0.1 mm) for the obturator externus tendon; each cross-sectional area was, I) 29.5 ± 1.4 mm², II) 59.0 ± 2.3 mm², and III) 35.4 ± 1.2 mm² (Table 3).

The size of the tendons according to cross-sectional area increased in the order of the conjoint tendon, the obturator externus, and the piriformis tendon; each differed significantly. No differences in cross-sectional area based on underlying disease were noted. By sex, the

Table 2
Changes in tension in each fibers of the obturator externus accompanying various flexion motions with or without internal rotation.¹³

	0° flexion (neutral)	0° flexion with internal rotation	60° flexion	60° flexion with internal rotation	90° flexion	90° flexion with internal rotation
Anterior fiber	+	++	-	+	+	++
Middle fiber	+	++	-	+	+	++
Posterior fiber	+	++	0	++	++	+++

Tension status at the neutral position was considered baseline, tension the same as baseline was recorded as (0), mild increase in tension as (+), increase as (++) , marked increase as (+++), mild relaxation as (-), and relaxation as (--). Cited from reference.

Table 3
Transverse/longitudinal diameters and cross-sectional area of each tendon.

	Transverse diameter (mm)	Longitudinal diameter (mm)	Cross-sectional area (mm ²)
Piriformis tendon	4-13 (7.9 ± 0.2)	3-10 (5.0 ± 0.2)	7.1–77.8 (29.5 ± 1.4)
Conjoined tendon	7-20 (12.2 ± 0.2)	4-11 (6.1 ± 0.1)	25.1–106.0 (59.0 ± 2.3)
Obturator externus tendon	6-14 (9.1 ± 0.2)	3-8 (4.5 ± 0.1)	17.3–56.5 (35.4 ± 1.2)

conjoined tendon (males 67.0 ± 7.6 mm²/females 59.9 ± 2.4 mm²) and the piriformis tendon (males 38.5 ± 3.1 mm²/females 30.2 ± 1.7 mm²) were significantly larger in males, but the obturator externus tendon (males 32.6 ± 2.1 mm²/females 32.6 ± 1.1 mm²) showed no significant differences.

4. Discussion

According to anatomy texts, the obturator externus originates from the lateral margin of the obturator foramen of the innominate bone, runs over the posterior surface of the femoral neck laterally to externally rotate and adduct the femur. While reported studies on the anatomy and function of obturator externus are few, Solomon et al.⁷ have evaluated this anatomically using 20 cadaver specimens. Because only a few fibers connect the obturator externus tendon to the surrounding tissues, it is reported that the tendon will shrink and retract in cases where it is released without stay sutures, and therefore will not be repairable. However, from our clinical evaluation of intraoperative findings, even in cases where it was released without stay sutures, searching with an understanding of the anatomy of the released tendon made it possible to identify and repair the obturator externus tendon in 96.5% of cases. The 5 hips where the tendinous material could not be clearly identified were mostly early cases in the beginning of the study, and in addition to the lack of experience in searching to identify it, individual variations, atrophy, and degeneration of the muscle and tendon due to disease can also account for the difficulty in locating and identifying it.

Furthermore, Gudena et al.⁹ in their study on cadaver and anatomical models in 2015, reported that the main function of the obturator externus is external rotation at neutral and 90° flexion, and that it functions as a hip stabilizer in flexion and internal rotation. In the Japanese literature, Hirano et al.¹² and Kinoshita et al.¹³ likewise reported in 2009 and 2014, studies on the functional anatomy of the obturator externus and obturator internus using cadaveric specimens. They found that the functions of obturator internus and obturator externus differ based on their varying trajectories, the obturator internus functions against adduction in flexion, and the obturator externus (especially the posterior fibers) functions against internal rotation in flexion, as the main dynamic stabilizers, respectively. Also, measurements of released tendons from the present clinical anatomical study show that the thickness of the cross-sectional area was largest for the conjoined tendon, followed by the obturator externus and the piriformis; thus, the obturator externus tendon provides an important function. THA via the posterior approach is associated with significant posterior dislocation from the combination of hip flexion, adduction, and internal

rotation. It is thus considered that combining the repair of both the conjoined tendon and the obturator externus tendon is most effective for prevention of posterior dislocation.

This current study has some limitations. First, particularly regarding the cadaveric study the sample size is relatively small. Second and both the cadaveric and clinical studies are limited in that all cases are in the Asian (Japanese) population. However, it can be inferred that individual and racial variations are minimal with regard to the anatomical origin and insertion of each muscle along with their trajectory. Japanese individuals have a smaller frame, and so the possibility of having a small muscle and tendon size compared to Westerners must be taken into consideration. Third, because the cases in the clinical study are actual cases of primary THA, pathological factors such as disuse atrophy, adhesions, and contractures in the muscles and tendons around the hip joint could have brought about some variability compared to normal anatomy. However, because the essential purpose of this study is to elucidate clinical anatomy in actual THA patients, we think that these errors can be overlooked.

In recognizing the posterior soft tissues in THA via the posterior approach, both historically and considering the current universal procedure, while surgeons pay adequate attention to the piriformis tendon and the conjoined tendon, little attention has been paid to the obturator externus tendon. This is likely because the anatomy and function of the obturator externus is unclear. Thus, understanding the location and course of the obturator externus and its role would facilitate adequate repair of the posterior soft tissues including capsular ligaments.

5. Conclusion

We evaluated the functional anatomy and the clinical anatomy of the short external rotators of the hip, which are important in posterior approach THA. Because the trajectory of the conjoined tendon (obturator internus tendon) and the obturator externus tendon differ, their functions also differ. The conjoined tendon and the obturator externus each serve important roles in stabilization during adduction in flexion, and stabilization during internal rotation in flexion, respectively. Therefore, repair of both tendons would be most effective in preventing posterior dislocation after surgery. In primary THA via the posterior approach, it is important for surgeons to understand that the obturator externus that has been released and typically is found in the 4 o'clock to 5 o'clock position posteroinferiorly to the hip joint along the capsule, with a released end size of about 9 × 5 mm, and when pulled, its trajectory is directed medially and somewhat anteriorly.

Funding sources

This research did not received any specific grant from any funding agencies in the public, commercial, or not-for-profit sectors.

CRedit authorship contribution statement

Yasuhiko Kawaguchi: Conceptualization, Methodology, Formal analysis, Visualization. **Takuya Otani:** Conceptualization, Writing – original draft. **Hideki Fujii:** Investigation, Resources. **Tetsuo Hayama:** Investigation, Resources. **Keishi Marumo:** Supervision. **Mitsuru Saito:** Project administration.

Declaration of competing interest

None.

Acknowledgements

We thank Kazuhiro Hirano, RPT and Kazuo Kinoshita, RPT, Department of Rehabilitation, The Jikei University School of Medicine, for their extensive contribution to the performing the experiments, and date collection.

References

- White Jr RE, Forness TJ, Allman JK, Junick DW. Effect of posterior capsular repair on early dislocation in primary total hip replacement. *Clin Orthop Relat Res.* 2001;393:163–167.
- Suh KT, Park BG, Choi YJ. A posterior approach to primary total hip arthroplasty with soft tissue repair. *Clin Orthop.* 2004;418:162–167.
- Browne JA, Pagnano MW. Surgical technique. A simple soft-tissue-only repair of the capsule and external rotators in posterior-approach THA. *Clin Orthop Relat Res.* 2012;470:511–515. <https://doi.org/10.1007/s11999-011-2113-6>.
- Loiba V, Stucinskas J, Robertsson O, Wingstrand H, Tarasevicius S. The analysis of posterior soft tissue repair durability after total hip arthroplasty in primary osteoarthritis patients. *Hip Int.* 2015;25:420–423. <https://doi.org/10.5301/hipint.5000232>.
- Osborne RP. The approach to the hip-joint: a critical review and a suggested new route. *Br J Surg.* 1930;18:49.
- Moore AT. The self-locking metal hip prosthesis. *J Bone Joint Surg.* 1957;39:811–827.
- Solomon LB, Lee YC, Callary SA, Beck M, Howie DW. Anatomy of piriformis, obturator internus and obturator externus. Implications for the posterior surgical approach to the hip. *J Bone Joint Surg.* 2010;92:1317–1324. <https://doi.org/10.1302/0301-620X.92B9>.
- Ito Y, Matsushita I, Watanabe H, Kimura T. Anatomic mapping of short external rotators shows the limit of their preservation during total hip arthroplasty. *Clin Orthop Relat Res.* 2012;470:1690–1695. <https://doi.org/10.1007/s11999-012-2266-y>.
- Gudena R, Alzahrani A, Railton P, Powell J, Ganz R. The anatomy and function of the obturator externus. *Hip Int.* 2015;25:424–427. <https://doi.org/10.5301/hipint.5000249>.
- Vaarbakken K, Steen H, Samuelsen G, Dahl HA, Leergaard TB, Stuge B. Primary functions of the quadratus femoris and obturator externus muscles indicated from lengths and moment arms measured in mobilized cadavers. *Clin Biomech.* 2015;30:231–237. <https://doi.org/10.1016/j.clinbiomech.2015.02.004>.
- Müller M, Dewey M, Springer I, Perka C, Tohtz S. Relationship between cup position and obturator externus muscle in total hip arthroplasty. *J Orthop Surg Res.* 2010;5:44. <https://www.josr-online.com/content/5/1/44>.
- Hirano K, Kinoshita K, Kato T, Otani T. A cadaveric study of functional anatomy of the hip external rotators. The role of the obturator internus and obturator externus in prevention of dislocation after THA. *Hip Joint.* 2009;35(Suppl):174–176 (in Japanese).
- Kinoshita K, Hirano K, Nakajima T, et al. A cadaveric observation of functional anatomy of external obturator during joint movement. *Hip Joint.* 2014;40(Suppl):180–183 (in Japanese).
- Fujii H, Otani T, Ueno Y, et al. Effect of posterior soft tissue repair on prevention of dislocation. *Kansetsu Geka (Journal of Joint Surgery).* 2014;33:700–704 (in Japanese).