

Can visual assessment of blood flow patterns by dynamic contrast-enhanced computed tomography distinguish between malignant and benign lung tumors?

Stefan Walbom Harders¹, Hans Henrik Madsen²,
Hanne Marie Nellemann², Torben Riis Rasmussen³,
Jesper Thygesen⁴, Henrik Hager⁵, Niels Trolle Andersen⁶
and Finn Rasmussen²

Acta Radiologica Open
6(5) 1–6
© The Foundation Acta Radiologica
2017
Reprints and permissions:
sagepub.co.uk/journalsPermissions.nav
DOI: 10.1177/2058460117710053
journals.sagepub.com/home/arr



Abstract

Background: Dynamic contrast-enhanced computed tomography (DCE-CT) is a tool, which, in theory, can quantify the blood flow and blood volume of tissues. In structured qualitative analysis, parametric color maps yield a visual impression of the blood flow and blood volume within the tissue being studied, allowing for quick identification of the areas with the highest or lowest blood flow and blood volume.

Purpose: To examine whether DCE-CT could be used to distinguish between malignant and benign lung tumors in patients with suspected lung cancer.

Material and Methods: Fifty-nine patients with suspected lung cancer and a lung tumor on their chest radiograph were included for DCE-CT. The tumors were categorized using structured qualitative analysis of tumor blood flow patterns. Histopathology was used as reference standard.

Results: Using structured qualitative analysis of tumor blood flow patterns, it was possible to distinguish between malignant and benign lung tumors (Fisher–Freeman–Halton exact test, $P = 0.022$). The inter-reader agreement of this method of analysis was slight to moderate ($\kappa = 0.30$; 95% confidence interval [CI] = 0.13–0.46).

Conclusion: DCE-CT in suspected lung cancer using structured qualitative analysis of tumor blood flow patterns is accurate as well as somewhat reproducible. However, there are significant limitations to DCE-CT.

Keywords

Lung neoplasms, radiography, perfusion imaging, X-ray computed tomography

Date received: 3 February 2016; accepted: 27 March 2017

Introduction

In suspected lung cancer, usually the first imaging examination is chest radiography followed by contrast-enhanced computed tomography (CT) of the thorax and upper abdomen. Dependent on local arrangements, this is followed by other examinations, including dynamic contrast-enhanced CT (DCE-CT).

DCE-CT is a tool which can quantify the blood flow and blood volume of tissues (1–3). This is clinically useful and, accordingly, studies investigating the use

¹Department of Radiology, The Regional Hospital in Horsens, Horsens, Denmark

²Department of Radiology, Aarhus University Hospital, Aarhus, Denmark

³Department of Respiratory Medicine and Allergy, Aarhus University Hospital, Aarhus, Denmark

⁴Department of Medical Engineering, Aarhus University Hospital, Aarhus, Denmark

⁵Department of Pathology, Aarhus University Hospital, Aarhus, Denmark

⁶Department of Biostatistics, Institute of Public Health, Aarhus University, Aarhus, Denmark

Corresponding author:

Stefan Walbom Harders, Department of Radiology, The Regional Hospital in Horsens, Sundvej 30, 8700 Horsens, Denmark.
Email: stefhard@rm.dk



of DCE-CT in oncology are increasingly reported in the literature (4–6).

The fundamental principle of DCE-CT is based on the temporal changes in tissue density following intravenous administration of iodinated contrast media. By obtaining in quick succession a series of images of a particular tissue of interest, it is possible to record the temporal changes in the tissue attenuation occurring after intravenous injection of contrast.

However, previously published papers have questioned the usability of quantitative and semi-quantitative DCE-CT in lung cancer (7–9). We therefore decided to try a simpler, alternative approach to DCE-CT.

In structured qualitative analysis, parametric color maps yield a visual impression of the blood flow and blood volume within the tissue being studied, allowing for quick identification of the areas with the highest or lowest blood flow and blood volume (10).

The purpose of this study was to examine whether DCE-CT using structured qualitative analysis of tumor blood flow patterns could be used to distinguish between malignant and benign lung tumors in patients with suspected lung cancer.

Material and Methods

Study population

The study conformed to Danish legal requirements. Institutional Review Board approval was obtained from the Aarhus County Committee on Biomedical Research Ethics, case no. M-AAA-20061020. Patients with suspected lung cancer and a visible tumor on their chest radiograph, which were referred to a tertiary sector hospital for diagnosis, were prospectively identified for inclusion over a 2.5-year period. They all received CE-CT of the chest and upper abdomen. Those who signed an informed consent form to participate in the study also received DCE-CT. The study design was prospective.

Procedures

DCE-CT examinations included only slices with tumors. DCE-CT was performed with a multiple-detector row CT scanner (Philips Brilliance CT 64-channel scanner; Philips Healthcare, Best, The Netherlands). The scan mode was axial. The acquisition parameters were: tube voltage = 100 kV, tube current = 80 mAs, thickness = 5 mm, increment = 5 mm, collimation = 64×0.625 mm. A short sharp bolus injection of 60 mL iodixanole 270 mg/mL (Visipaque[®] 270; GE Healthcare, Oslo, Norway) was administered to all patients at a rate of 6 mL/s. Patients were scanned every other second for a period of 70 s. During the

examination, patients were instructed to hold their breath for as long as possible or to use shallow breathing. Raw picture datasets were transferred to a Philips Extended Brilliance[™] workspace workstation v4.02 and were reviewed with the application Functional CT v. 4.5.2.

Blinded images were reviewed. Primary software input consisted of an arterial ROI placed in the aorta.

Two consultant radiologists reviewed the studies. Tumor blood flow patterns were categorized into five categories using parametric color maps: no blood flow at all; partial ring blood flow (blood flow in the periphery of the lesion, $\leq 75\%$); complete ring blood flow (blood flow in the periphery of the lesion, $> 75\%$); heterogeneous blood flow (spotted blood flow, often including central blood flow); or homogenous blood flow (blood flow through the entire lesion) (Figs. 1 and 2). Both radiologists reviewed all participants' images side by side to obtain consensus results for the study. Six months later, they reviewed the images again, individually, to assess inter-reader agreement.

The reference standard was tissue sampling. As such, all malignant diagnoses were verified by tissue sampling and all non-malignant diagnoses were sought verified by tissue sampling. In this manner, three separately obtained non-malignant tissue samples were accepted as a definitely non-malignant result. In most cases, tumor material was obtained by fluoroscopy-guided or CT-guided transthoracic needle aspiration biopsies. However, in selected cases, tumor material was obtained by bronchoscopy or by video-assisted thoracic surgery. That way, definitive diagnoses in this study were obtained in all cases.

Statistical analysis

The tumor blood flow patterns were categorized from 1 to 5.

The Fisher–Freeman–Halton (FFH) exact test for $r \times c > 2$ was used to test for associations between tumor blood flow patterns and malignancy. $P < 0.05$ was considered statistically significant.

The inter-reader agreement was assessed using unweighted kappa (11). A 95% confidence interval (CI) was computed using exact methods. The resulting kappa value was interpreted as suggested by Landis and Koch (12).

The licensed statistical software package STATA/SE 11 (STATAcorp LP, College Station, TX, USA) was used.

Results

Sixty-seven patients signed the informed consent form and were initially included in the study. However,

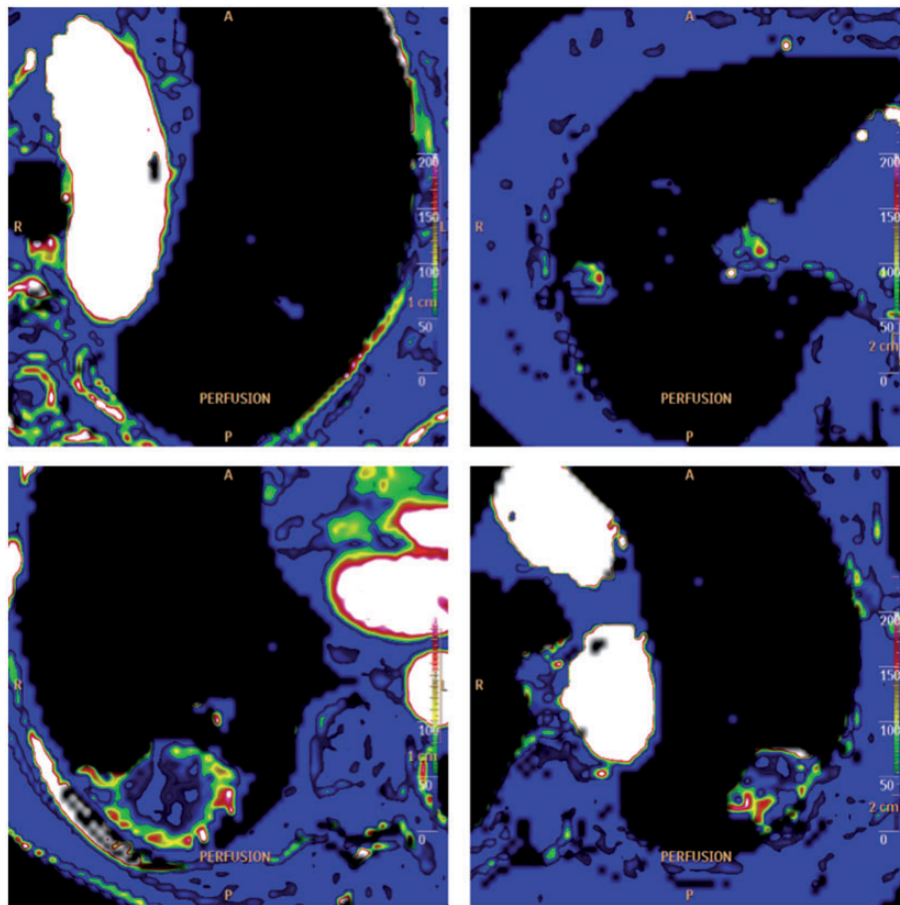


Fig. 1. (a–d; left to right, top to bottom) Four examples of blood flow patterns using structured qualitative analysis. (a) No blood flow. The patient was a 79-year-old man with a squamous cell carcinoma. (b) Partial ring blood flow. The patient was a 66-year-old woman with an adenocarcinoma. (c) Complete ring blood flow. The patient was a 67-year-old woman with an adenocarcinoma. (d) Heterogeneous blood flow. The patient was a 78-year-old man with a squamous cell carcinoma.

in eight cases the DCE-CT scanning did not include the tumor. These “missing tumors” were most likely due to participants’ breathing, either during the acquisition of the scout or during the DCE-CT scanning. Thus, 59 participants, including 29 men and 30 women (age range = 40–86 years) were included in the final analysis. Each participated with a single lung tumor. Tumor sizes were in the range of 11–106 mm.

Of the tumors, 80% (47/59) were malignant and 20% (12/59) were benign. The malignant tumors were further sub-characterized and had the following distribution: 38% (18/47) adenocarcinomas, 28% (13/47) squamous cell carcinomas, 2% (1/47) large cell carcinomas, 19% (9/47) other or undifferentiated non-small-cell lung carcinomas, 4% (2/47) small cell lung carcinomas, and 9% (4/47) metastases from extra-thoracic cancers. The benign tumors were not further sub-characterized.

Using structured qualitative analysis of tumor blood flow patterns, it was possible to distinguish between malignant and benign lung tumors (FFH exact test,

$P=0.022$), with the majority of the malignant tumors exhibiting either partial ring blood flow patterns (7/47), complete ring blood flow patterns (12/47), or heterogeneous blood flow patterns (19/47). On the other hand, the majority of the benign tumors exhibited no blood flow at all (8/12) (Table 1). The inter-reader agreement of this method of analysis was slight to moderate (kappa = 0.30; 95% CI = 0.13–0.46) (Table 1).

Discussion

The purpose of this study was to assess whether DCE-CT could be used to distinguish between malignant and benign lung tumors. This resulted in 59 DCE-CT examinations of lung tumors, which were technically sufficient for analysis.

Using structured qualitative analysis of tumor blood flow patterns, it was possible to distinguish between malignant and benign lung tumors. The inter-reader agreement of this method of analysis was slight to moderate.

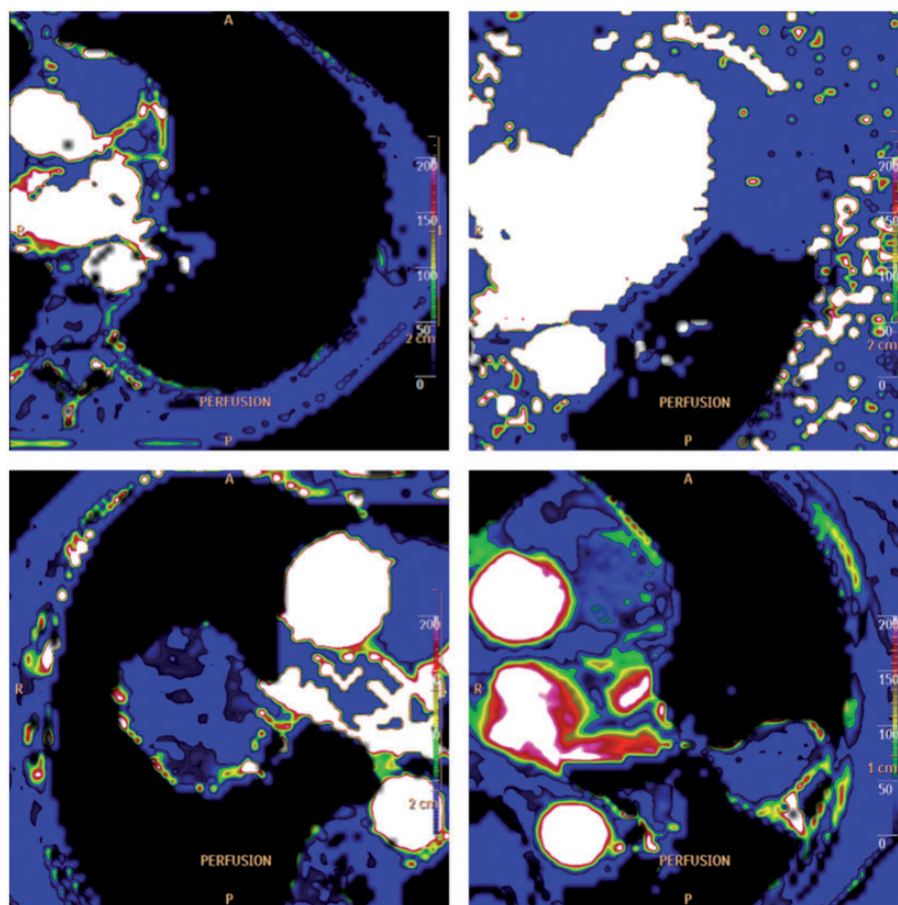


Fig. 2. (a–d; left to right, top to bottom) Four other examples of blood flow patterns using structured qualitative analysis. (a) No blood flow. The patient was a 69-year-old woman with an adenocarcinoma. (b) No blood flow. The patient was a 74-year-old woman with a benign lesion. (c) Complete ring blood flow. The patient was a 70-year-old man with an adenocarcinoma. (d) Complete ring blood flow. The patient was a 71-year-old woman with a metastasis from an extra-thoracic cancer.

Table 1. Blood flow patterns.

	None	Partial ring	Complete ring	Heterogeneous	Homogenous
Benign	8	1	1	2	0
Malignant	9	7	12	19	0

FFH exact test, $P=0.022$.

Kappa = 0.30 (0.13–0.46).

Of the malignant tumors, 41% were assessed as having a partial or complete ring blood flow and another 40% were assessed as having a heterogeneous blood flow. Opposed to these results for the malignant tumors, 67% of the benign tumors were assessed as having no blood flow at all. Throughout this study, blood flow patterns of the entire volume of lung tumors were used to assess the individual tumors, whereas, in the majority of previous studies, only the two or three most central axial levels of the tumors were assessed. It is possible that the blood flow patterns of

the entire tumor diverge significantly from that of the central axial levels. Considering that the blood flow patterns were associated to malignancy, this could be an important aspect in future studies.

Our results indicate that a structured qualitative analysis of blood flow patterns in lung tumors reflects the underlying pathology of these tumors. This is in close agreement with accepted theories of cancerous vascular vessels versus normal ones. Thus, according to Jain et al. (13,14), in the majority of cancers, vessel growth is abnormal in almost every aspect of structure

and function. Cancer vessels are tortuous: they follow a serpentine course; branch irregularly in a chaotic network of tangles; connect to one another randomly; and crisscross the stroma haphazardly. According to our results, it seems possible to identify these cancerous vessels using a simple method of structured qualitative analysis.

Some inherent limitations to this study, as well as to DCE-CT in general, must be mentioned. First, the design of this study limited the participants to patients with suspected lung cancer and a visible tumor on a chest radiograph. Considering the limited spatial resolution of chest radiographs and the fact that the majority of lung tumors >3 cm are malignant (15), this leads to a rather pronounced selection bias in favor of malignancy. This must be addressed in future studies.

As with DCE-CT in general, the greatest technical challenge in this study was respiratory motion. Respiratory motion can cause image misregistration and post-production errors in the calculation of both quantitative and semi-quantitative parameters, as well as reduced reproducibility of these (16). Although neither quantitative nor semi-quantitative analyses were used in this study, image misregistration might well interfere with the layout of the parametric color maps and thereby with the structured qualitative analysis of these. At present, the only method to minimize respiratory motion is to instruct patients to hold their breath or to use shallow breathing. However, tumor-tracking software, which may improve misregistration through a more extensive coverage, while reducing respiratory motion artifacts, is being tested (17,18).

Another technical challenge for DCE-CT concerns the radiation dose delivered to the patient. Fraioli et al. measured the radiation dose from DCE-CT to 21.7 ± 1.6 mSv using a 64-detector row dual-source CT with tube voltage at 100 kV and tube current at 120 mAs (19). In our study, the tube voltage was also 100 kV, but the tube current was only 80 mAs. Although this makes the radiation dose to the patients somewhat lower than in Fraioli et al.'s study, it is still a substantial dose, especially when DCE-CT is performed in addition to other radiation emitting examinations.

Finally, the inter-reader agreement is limited.

In conclusion, DCE-CT in suspected lung cancer using structured qualitative analysis of tumor blood flow patterns is accurate, but the inter-reader agreement is only slight to moderate. Also, there are significant technical limitations to DCE-CT, the most important of which concern image acquisition techniques and radiation dose.

Using the DCE-CT based on the structured qualitative analysis of tumor blood flow patterns may play a role in distinguishing between malignant and benign lung tumors. However, this warrants further studies.

Declaration of conflicting interests

The author(s) declared no potential conflicts of interest with respect to the research, authorship, and/or publication of this article.

Funding

The author(s) received no financial support for the research, authorship, and/or publication of this article.

References

1. Miles KA, Hayball M, Dixon AK. Colour perfusion imaging: A new application of computed tomography. *Lancet* 1991;337:643–645.
2. Miles KA, Hayball MP, Dixon AK. Functional images of hepatic perfusion obtained with dynamic CT. *Radiology* 1993;188:405–411.
3. Miles K, Dawson PH, Blomley M. Functional computed tomography. In: Miles K, Dawson PH, Blomley M (eds) Oxford: Isis Medical Media, 1997.
4. Miles KA. Tumor angiogenesis and its relation to contrast enhancement on computed tomography: A review. *Eur J Radiol* 1999;30:198–205.
5. Miles KA, Charnsangavej C, Lee FT, et al. Application of CT in the investigation of angiogenesis in oncology. *Acad Radiol* 2000;7:840–850.
6. Yi CA, Lee KS, Kim EA, et al. Solitary pulmonary nodules: Dynamic enhanced multi-detector row CT study and comparison with vascular endothelial growth factor and microvessel density. *Radiology* 2004;233:191–199.
7. Ng QS, Goh V, Fichte H, et al. Lung cancer perfusion at multi-detector row CT: Reproducibility of whole tumor quantitative measurements. *Radiology* 2006;239:547–553.
8. Ng QS, Goh V, Klotz E, et al. Quantitative assessment of lung cancer perfusion using MDCT: Does measurement reproducibility improve with greater tumor volume coverage? *Am J Roentgenol* 2006;187:1079–1084.
9. Harders SW, Madsen HH, Nellesmann HM, et al. Dynamic contrast-enhanced CT in suspected lung cancer: Quantitative results. *Br J Radiol* 2013;86:20130257.
10. Coche E. Advances and perspectives in lung cancer imaging using multidetector row computed tomography. *Expert Rev Anticancer Ther* 2012;12:1313–1326.
11. Fleiss JL, Levin BA, Paik MC. Statistical methods for rates and proportions, 3rd ed. Hoboken, NJ: J. Wiley, 2003.
12. Landis JR, Koch GG. The measurement of observer agreement for categorical data. *Biometrics* 1977;33:159–174.
13. Jain RK. Determinants of tumor blood flow: A review. *Cancer Res* 1988;48:2641–2658.
14. Jain RK. Normalization of tumor vasculature: An emerging concept in antiangiogenic therapy. *Science* 2005;307:58–62.
15. Wahidi MM, Govert JA, Goudar RK, et al. Evidence for the treatment of patients with pulmonary nodules: When is it lung cancer? ACCP evidence-based clinical practice guidelines (2nd edition). *Chest* 2007;132:94S–107S.

16. Ng CS, Chandler AG, Wei W, et al. Reproducibility of perfusion parameters obtained from perfusion CT in lung tumors. *Am J Roentgenol* 2011;197:113–121.
17. Sauter AW, Winterstein S, Spira D, et al. Multifunctional profiling of non-small cell lung cancer using 18F-FDG PET/CT and volume perfusion CT. *J Nucl Med* 2012; 53:521–529.
18. Sauter AW, Merkle A, Schulze M, et al. Intraobserver and interobserver agreement of volume perfusion CT (VPCT) measurements in patients with lung lesions. *Eur J Radiol* 2012;81:2853–2859.
19. Fraioli F, Anzidei M, Zaccagna F, et al. Whole-tumor perfusion CT in patients with advanced lung adenocarcinoma treated with conventional and antiangiogenic chemotherapy: Initial experience. *Radiology* 2011;259: 574–582.