



Contents lists available at ScienceDirect

## International Journal of Surgery Case Reports

journal homepage: [www.casereports.com](http://www.casereports.com)

## The steel pan sign of sigmoid volvulus—A case series



Yardesh Singh, Shariful Islam\*, Ammiel Arra, Renee Banfield, Vijay Naraynsingh

Department of Clinical surgical Sciences, University of West Indies, St Augustine, Trinidad and Tobago

## ARTICLE INFO

## Article history:

Received 24 September 2017

Received in revised form 30 October 2017

Accepted 31 October 2017

Available online 11 November 2017

## Keywords:

Sigmoid volvulus

Radiological sign

Trinbagonian steel pan

## ABSTRACT

**INTRODUCTION:** Signs in radiology are usually based on many common objects or patterns that are easily recognizable in everyday life. The objective behind this association is to aid in the understanding and diagnosis of the disease process. These signs can be seen in different imaging modalities such as plain radiograph and computed tomography.

**PRESENTATION OF CASE:** 4 consecutive cases of sigmoid volvulus presented at our tertiary hospital between January 2016 and June 2017. 2 of these cases were managed surgically and others were managed conservatively. The CT scan and abdominal radiographs in these patients were reviewed with consultant radiologist, which bear resemblance to the percussion instrument known as the steel pan.

**DISCUSSION:** The literature has described few radiological signs of sigmoid volvulus in the past. In the following case series, we would like to introduce the “Steel pan Sign”, a novel radiological pattern which bears a close resemblance to the percussion instrument known as the steel pan. The Steel pan sign is easier to recognize on CT scan of the abdomen. However, in some cases it can be seen on plain X-Rays.

**CONCLUSION:** The appearance of sigmoid volvulus on CT scans as well as on plain abdominal X-rays bears a significant resemblance to the pattern observed on the face of the Trinidadian steel pan, the recognition of which can aid in the diagnosis of this disease.

© 2017 The Author(s). Published by Elsevier Ltd on behalf of IJS Publishing Group Ltd. This is an open access article under the CC BY-NC-ND license (<http://creativecommons.org/licenses/by-nc-nd/4.0/>).

## 1. Introduction

This paper documents a novel radiological pattern, Steel pan Sign for sigmoid volvulus. It is reported in line with the PROCESS criteria [1]. Sigmoid volvulus is the most common form of volvulus of the gastrointestinal tract, and is responsible for 8% of all intestinal obstructions. Clinical presentation may include abdominal pain, distention, and absolute constipation.

Signs in radiology are usually based on many common objects or patterns that are easily recognizable in everyday life. The objective behind this association is to aid in the understanding and diagnosis of the disease process. These signs can be seen in different imaging modalities such as plain radiograph and computed tomography.

The key radiologic features include a double-loop obstruction, which has been reported in approximately 50% of patients, in addition to a dilated loop of sigmoid colon in the pelvis, and may exhibit associated features of small-bowel obstruction and retention of feces in collapsed proximal colon [2,3].

In the following case series, we would like to introduce the “Steelpan Sign”, a novel radiological pattern which bears a close resemblance to the percussion instrument known as the steelpan.

## 1.1. Case 1

A 40 year old female presented to the Accident and Emergency Department complaining of a four day history of abdominal distension associated with intermitted colicky abdominal pain. On examination, her abdomen appeared tense and grossly distended, with hyper-resonant percussion noted. Plain radiography of the abdomen showed grossly dilated large bowel, with an abrupt cut-off at the distal descending colon. No classic radio-graphical signs of volvulus were identified. Computed tomography of the abdomen was ordered to rule out an obstructing lesion in the sigmoid colon, however this revealed findings consistent with a sigmoid volvulus and large bowel obstruction. Fig. 1, shows the pattern seen on abdominal CT, and can be compared to an image of the Trinbagonian steel pan, seen in Fig. 2.

The patient was admitted, and was successfully decompressed using rigid sigmoidoscopy. She subsequently declined further surgical intervention once her symptoms had resolved, and continues to be followed up at the surgical outpatient clinic.

## 1.2. Case 2

Our second case was an elderly gentleman, who was also decompressed, however was deemed medically unfit for any major surgical procedure. Supine radiograph of the abdomen seen in Fig. 3, demonstrates the steel pan pattern in the left lower quadrant.

\* Corresponding author at: Department of Clinical surgical Sciences, University of West Indies, St Augustine, Trinidad and Tobago/ San Fernando Teaching Hospital, Trinidad and Tobago.

E-mail addresses: [sss1201198@yahoo.com](mailto:sss1201198@yahoo.com), [shar.islam7@hotmail.com](mailto:shar.islam7@hotmail.com) (S. Islam).

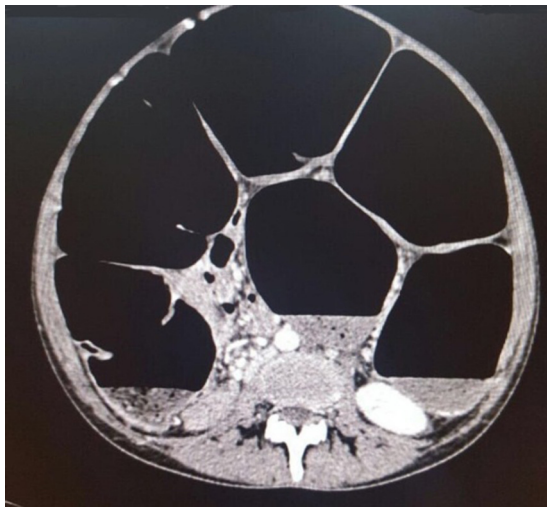


Fig. 1. CT Abdomen showing Sigmoid Volvulus with Steel pan pattern.

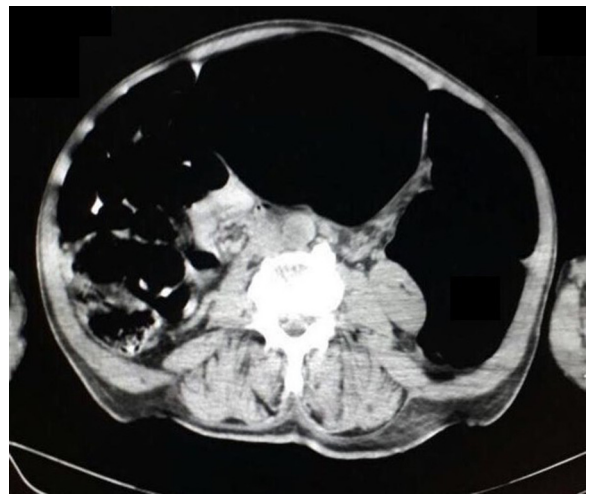


Fig. 4. CT Abdomen showing a Sigmoid Volvulus with Steel pan pattern.



Fig. 2. Trinbagonian Steel pan.

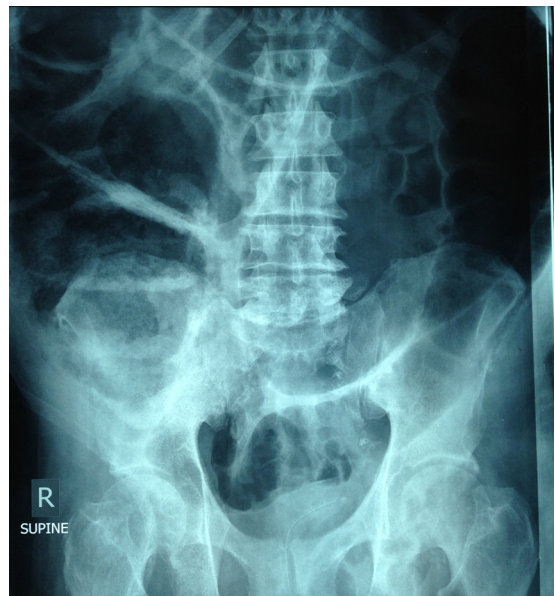


Fig. 5. Abdominal X-ray showing Sigmoid Volvulus with Steel pan pattern.

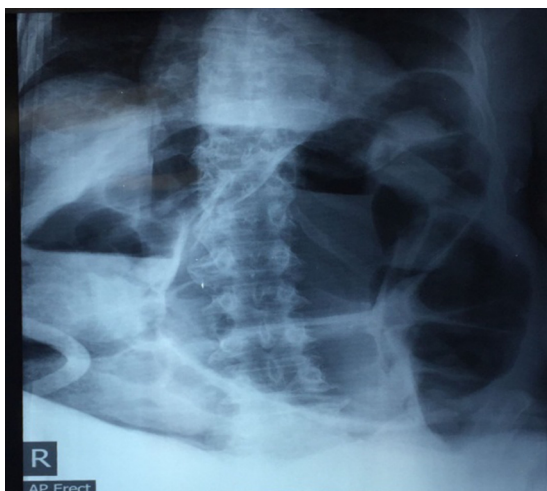


Fig. 3. Abdominal X-ray showing Sigmoid Volvulus with Steel pan pattern.

1.3. Case 3

Unlike the first two cases, our third case had failed attempts at decompression and underwent emergency laparotomy where a subtotal colectomy was performed. The CT scan of abdomen demonstrates the Steel pan pattern of the sigmoid volvulus (Fig. 4).

1.4. Case 4

Our 4th case was an elderly female, who was also decompressed; however it recurred back while on ward and underwent emergency exploratory laparotomy and sigmoid colectomy. Both supine radiograph of the abdomen seen in Fig. 5 and CT scan of abdomen in Fig. 6(A and B); demonstrates the steel pan pattern in the left lower quadrant.

2. Discussion

The term volvulus is derived from the Latin word *volvere* (“to twist”). A colonic volvulus occurs when a part of the colon twists on its mesentery, resulting in acute, sub-acute, or chronic colonic

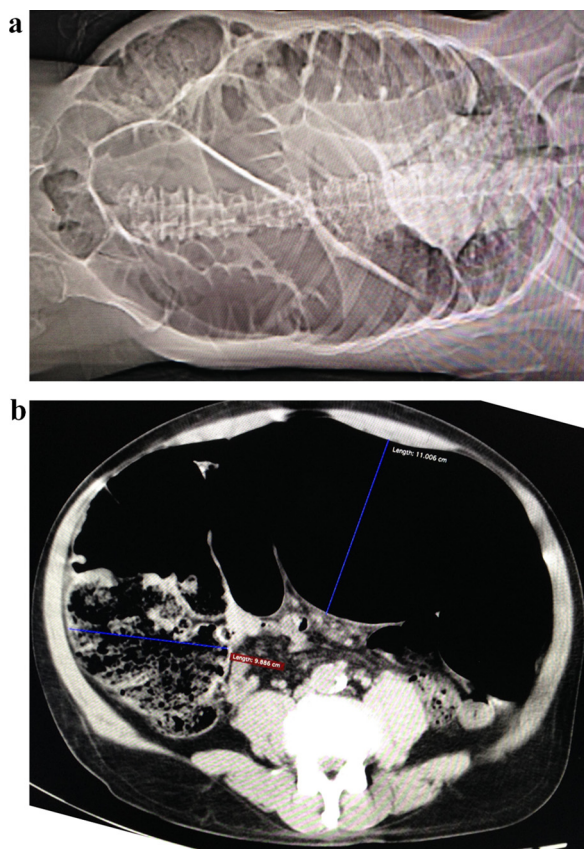


Fig. 6. A&B: CT ski gram (A) and cross section view (B) of abdomen demonstrating the Steel pan sign.

obstruction. The most common type of colonic volvulus is the sigmoid volvulus which is responsible for 8% of all cases of intestinal obstruction [2,4].

Although plain abdominal radiograph findings are usually diagnostic, computed tomography may be useful in identifying the etiology and site of other causes of large bowel obstruction, as well as demonstrate features of ischemia, that result from strangulation [5,6].

Previously described diagnostic X-Ray signs are bird beak sign [7], coffee bean sign [8], bent inner tube or ace of spades sign [9], omega or horse-shoe sign [7], inverted V sign [10], Y sign [7] and northern exposure sign [11]. These easily identified signs aid in the detection and diagnosis of sigmoid volvulus.

CT scan findings of sigmoid volvulus include the whirl sign, which represents tension on the tightly twisted mesocolon by the afferent and efferent limbs of the dilated colon, but the classic appearance may be absent in up to half of the patients. The recent description of two novel signs have attempted to give further information regarding the degree of twisting that occurs. The “X-marks-the-spot” sign signifies complete twisting while the “split-wall sign” is usually associated with less severe twisting [11–13].

In this case series, cross-sectional imaging has demonstrated a pattern which we believe can be likened to the pattern seen on the national instrument of Trinidad and Tobago... the steel pan. The Steel pan sign is easier to recognize on CT scan of the abdomen. However, in some cases it can be seen on plain X-Rays.

The Steel pan (Pan) (often referred to as Steel drums), is a percussion instrument made from a 55 gallon drum. This musical instrument was invented in Trinidad & Tobago during the 1930s in the period around the time of the 2nd world war, and is the sole

percussion instrument created in the 20th century, its history can be traced back to the enslaved Africans who were brought to the islands during the 1700s. They carried with them elements of their African culture including the playing of hand drums. These drums became the main percussion instruments in the annual Trinidadian carnival festivities [14,15].

Its unique design comprises layers of musical notes, concentrically arranged from the outer rim of the instrument toward its centre. Each note is in turn separated from the other by a series of radial grooves.

When compared to the pattern seen on CT imaging of this patient, the arrangement of the haustral folds arranged in a circular pattern has produced a very similar appearance to this national instrument.

### 3. Conclusion

The appearance of sigmoid volvulus on CT scans as well as on plain abdominal X-rays bears a significant resemblance to the pattern observed on the face of the Trinidadian steel pan, the recognition of which can aid in the diagnosis of this disease. This easily recognized symbol enables faster diagnosis and earlier treatment of this disease, thus reducing the morbidity and mortality.

### Conflicts of interest

There is no conflicts of interest amongst the authors in publishing this case series.

### Funding

No fund was received to publish this article.

### Ethical approval

Ethical approval is not required.

### Consent

Informed consent was obtained from all of the patient.

### Author contribution

All authors have contributed significantly in this case report. The first and 2nd author have performed the surgery and recognized the steel pan sign of sigmoid volvulus and other authors have helped in collecting data, designing, organizing to write the manuscript as well as assisted in critical analysing of the manuscript. All authors have approved the final version of this manuscript.

### Guarantor

The corresponding author and the first author will accept the full responsibility for the work.

### Acknowledgement

The authors have nothing to acknowledge.

### References

- [1] R.A. Agha, A.J. Fowler, S. Rammohan, I. Barai, D.P. Orgill, the PROCESS Group, The PROCESS statement: preferred reporting of case series in surgery, *Int. J. Surg.* 36 (Pt A) (2016) 319–323.
- [2] S.S. Atamanalp, M.I. Yildiran, M. Basoglu, et al., Clinical presentation and diagnosis of sigmoid volvulus: outcomes of 40-year and 859-patient experience, *J. Gastroenterol. Hepatol.* (May) (2007) 24.

- [3] M. Kedir, B. Kotisso, G. Messele, Ileosigmoid knotting in Gondar teaching hospital north-west Ethiopia, *Ethiop. Med. J.* 36 (October (4)) (1998) 255–256.
- [4] G. Lianos, E. Ignatiadou, E. Lianou, Z. Anastasiadi, M. Fatouros, Simultaneous volvulus of the transverse and sigmoid colon: case report, *G. Chir.* 33 (October (10)) (2012) 324–326.
- [5] C. Bernard, J. Lubrano, V. Moulin, G. Manton, B. Kastler, E. Delabrousse, Value of multidetector-row CT in the management of sigmoid volvulus, *J. Radiol.* 91 (February (20)) (2010) 213–220.
- [6] T.J. Barloon, C.C. Lu, Diagnostic imaging in the evaluation of constipation in adults, *Am. Fam. Physician* 56 (August (2)) (1997) 513–520.
- [7] K.V. Avots-Avotins, D.E. Waugh, Colon volvulus and geriatric patient, *Surg. Clin. North Am.* 62 (1982) 249–260.
- [8] D. Feldman, The coffee bean sign, *Radiology* 216 (2000) 178–179.
- [9] G.H. Ballantyne, M.D. Brandner, R.W. Beart, D.M. Ilstrup, Volvulus of the colon. Incidence and mortality, *Ann. Surg.* 202 (1985) 83–92.
- [10] S.Y. Chen, C.T. Liu, Y.C. Tsai, J.C. Yu, C.H. Lin, Sigmoid volvulus associated Chilaiditi's syndrome, *Rev. Esp. Enferm. Dig.* 99 (2007) 476–483.
- [11] B.R. Javors, S.R. Baker, J.A. Miller, The northern exposure sign: a newly described finding in the sigmoid volvulus, *AJR* 173 (1999) 571–574.
- [12] K. Hirao, M. Kikawada, H. Hanyu, T. Iwamoto, Sigmoid volvulus showing a whirl sign on CT, *Intern. Med.* 45 (5) (2006) 331–332.
- [13] J.M. Levsky, E.I. Den, R.A. DuBrow, E.L. Wolf, A.M. Rozenblit, CT findings of sigmoid volvulus, *AJR Am. J. Roentgenol.* 194 (January (1)) (2010) 136–143.
- [14] I.R. Blake Felix, The Trinidad and Tobago steel pan, in: *History and Evolution*, 2017.
- [15] <http://www.steelpan-steeldrums-information.com/steel-pan-history.html>.

#### Open Access

This article is published Open Access at [sciencedirect.com](https://www.sciencedirect.com). It is distributed under the [IJSCR Supplemental terms and conditions](#), which permits unrestricted non commercial use, distribution, and reproduction in any medium, provided the original authors and source are credited.