Case Reports in Oncology

Case Rep Oncol 2023;16:1209–1216
DOI: 10.1159/000534278
Received: July 28, 2023
Accepted: September 21, 2023
Published online: October 20, 2023

Case Report

A Rare Association of Mixed Autoimmune Hemolytic Anemia with Gastric Carcinoma

Anu Chinnadurai[a] Scott Strum[a, b] Artin Ghassemian[a, b] Dalilah Fortin[c] Cheryl Foster[a, b] Daniel Breadner[a, b]

[a]Department of Medicine, Schulich School of Medicine and Dentistry, Western University, London, ON, Canada; [b]London Regional Cancer Program, London Health Sciences Centre, Victoria Hospital, London, ON, Canada; [c]Department of Surgery, Schulich School of Medicine and Dentistry, Western University, London, ON, Canada

Keywords
Gastric carcinoma · Autoimmune hemolytic anemia · Mixed autoimmune hemolytic anemia

Abstract
This case report outlines a 70-year-old female patient who presented with a concurrent mixed autoimmune hemolytic anemia (AIHA) and a gastric adenocarcinoma. Her treatment course of these two diseases is summarized, which included supportive care, neoadjuvant chemotherapy for her gastric adenocarcinoma, steroids, rituximab, and surgical resection of the tumor. This approach ultimately led to the stabilization of her AIHA and primary cure for her solid malignancy. We briefly review both AIHA and gastric adenocarcinoma as clinical entities, propose working causes of hemolytic anemia including gastric adenocarcinoma, and outline a successful treatment pathway for these two concurrent conditions.

Introduction

This report describes the case of a 70-year-old female who originally presented to the emergency department with a 3-month history of progressive dizziness, pre-syncope, and malaise, which led to the discovery of significant anemia. Workup revealed the diagnosis of a localized gastric adenocarcinoma and concurrent mixed warm and cold autoimmune

Anu Chinnadurai and Scott Strum are co-first authors.

Correspondence to:
Daniel Breadner, Daniel.breadner@lhsc.on.ca

hemolytic anemia (AIHA), the latter of which ultimately resolved post-resection of her primary gastric tumor. A single etiology of the AIHA was not determined, but a causal link between the solid tumor malignancy and AIHA remains possible. The report herein reviews the importance of considering solid malignancies as an uncommon but potential etiology of mixed AIHA, and the clinical approach used to manage both of these life-threatening illnesses.

Case Report

A 70-year-old female presented to the emergency department in the fall of 2021 with a 3-month history of progressive pre-syncope and malaise. Workup revealed a hemoglobin (Hb) of 62 g/L with spherocyte morphology, low hematocrit of 0.16 L/L, high mean corpuscular volume of 105 fL, leukocytes of 13.6 × 10^9/L, neutrophils of 9.6 × 10^9/L, CRP of 18.95 mg/L. Otherwise, electrolytes, TSH (2.28 mIU/L), INR (1.0), aPTT (25 s), and creatinine (60 μmol/L) within normal limits. Her past medical history was significant for COPD, hypertension, and irritable bowel syndrome. She had a 45 pack-year history of smoking at the time but quit 3 years prior and consumed 4–5 alcoholic drinks per day.

She received two packed red blood cell (RBC) transfusions and underwent a direct antiglobulin test (DAT) test, which was returned positive for IgG and C3. Eluate was pan-reactive. Chest X-ray was unremarkable, and subsequent CT thorax/abdomen/pelvis showed no evidence of malignancy or lymphadenopathy. She underwent upper and lower endoscopies in December 2021, with proximal stomach biopsy, revealing a moderately differentiated invasive gastric adenocarcinoma, MMR-deficient, HER-2 negative (IHC 0). PET scan identified a 3.0 × 2.0 cm mass with an SUV of 10 at the gastroesophageal junction without local or distant metastases.

Given this new diagnosis, she consented to four cycles of neoadjuvant FLOT chemotherapy prior to planned surgical resection in keeping with standard of care peri-operative treatment. However, during the following week, she developed symptomatic acrocyanosis in her feet (Fig. 1). Her Hb was low (88 g/L) with an elevated total bilirubin (86 μmol/L), direct bilirubin (14 μmol/L), and LDH (487 U/L), and an undetectable haptoglobin of <0.10 g/L. INR and PTT were normal. She was started on prednisone 60 mg with oral iron and folic acid supplements. Hematology was consulted, and further workup revealed a positive cold agglutinin screen with a thermal amplitude of 30°C and a titer of 1:256. This confirmed the diagnosis of mixed warm and cold AIHA. Bone marrow report showed cold agglutinin with normal trilineage hematopoiesis. The biopsy and aspirate identified a monoclonal B-cell population <1% of total leukocytes and positive for CD19, CD5, CD20, CD200 and expressing dim kappa light chains and negative for CD10 (CLL-like phenotype). Serum protein electrophoresis identified IgG kappa 3.0 g/L and trace monoclonal IgM kappa. Viral workup including hepatitis B, hepatitis C, and HIV were all negative. Rheumatological etiologies were clinically negative, as were rheumatoid factor, anti-nuclear antibodies, and extractable nuclear antigen.

She received her first dose of neoadjuvant FLOT chemotherapy in February 2022. One week post-treatment, she was admitted to hospital with significant anemia (Hb 52 g/L) and elevated hemolytic markers. Neoadjuvant therapy was thus suspended. As the patient's hemolytic parameters and symptoms did not improve with prednisone and packed RBC transfusion support, second-line of treatment with rituximab was introduced. She received four doses of rituximab 375 mg/m^2 between April 13th and May 11th, 2022. Prednisone was simultaneously tapered, and ultimately discontinued on May 15th. Once her hematologic and hemodynamic parameters stabilized, she underwent proximal gastrectomy and total

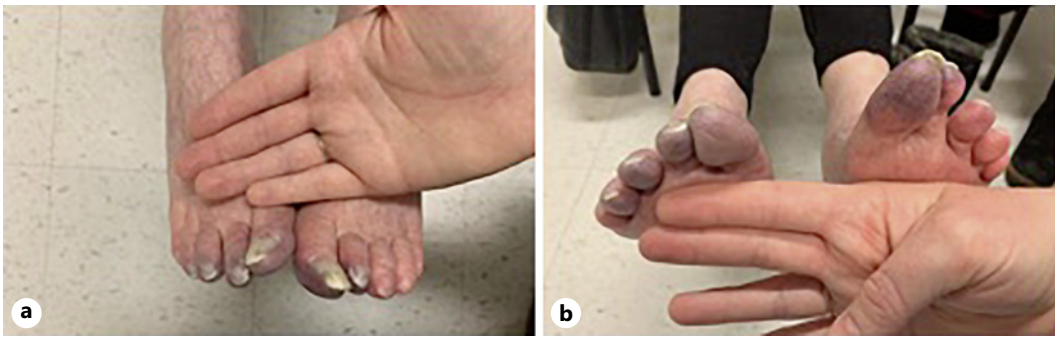

Fig. 1. a, **b** Acrocyanosis of the patient's distal lower extremities, which began shortly after initiating neoadjuvant FLOT chemotherapy for her gastric adenocarcinoma. Complete clinical resolution was observed shortly after surgical resection of the gastric tumor.

esophagectomy with jejunostomy tube and subsequently discharged home on June 10th, 2022. Prior to surgery, she developed bilateral lower extremity deep vein thrombosis, which prompted anticoagulation initiation after surgery.

Within a few weeks after surgery, her Hb showed notable improvement, trending upward from 70 to 120 g/L by July 28, 2022 (shown in Fig. 2). Her hemolytic markers showed normalization post-operatively, with a total bilirubin of 9 μmol/L, direct bilirubin of 3 μmol/L, and LDH of 360 U/L. Importantly, she remained transfusion-free post-surgery. Symptomatically, her acrocyanosis and dry gangrenous digits showed remarkable improvement in pain and appearance. As of March 2023, the patient had no clinical recurrence of her AIHA, including acrocyanosis. Biochemically, her total bilirubin stabilized in the 25–30 μmol/L range, LDH remained slightly above normal, and haptoglobin normalized. Her DAT remains persistently positive for C3 only with positive cold agglutinin screen. Overall, her picture was clinically consistent with chronic low-grade compensated extravascular hemolysis. She now remains on surveillance for her gastric cancer, with no clinical or radiographic signs of recurrence (Fig. 3).

Discussion

The case detailed herein presents a 70-year-old female with mixed warm and cold AIHA in the context of a newly diagnosed localized gastric adenocarcinoma. Her anemia was refractory to iron and B12 supplementation, alongside steroid treatment with prednisone. Early rituximab therapy and surgical resection of gastric carcinoma resulted in remarkable improvement in her mixed AIHA. Although it is possible that the AIHA was due to the underlying monoclonal B-cell clone, the gastric adenocarcinoma was a uniquely possible causative factor of the mixed AIHA. Support for this hypothesis is outlined below, alongside the rationale behind the clinical decisions made in her management. A CARE Checklist has been completed for this case report as well, attached as online supplementary material (for all online suppl. material, see https://doi.org/10.1159/000534278).

In brief review, gastric cancer is the fifth most common malignancy worldwide and affects approximately 1 in 98 Canadians in their lifetime. Endoscopic or surgical resection is favorable for stage 1A gastric cancer. Stage 1b or greater generally warrants a multimodal approach with neoadjuvant chemotherapy, radical gastrectomy and/or adjuvant treatment. Platinum–fluoropyrimidine doublet regimen is often considered in advanced disease along with immunotherapy and/or targeted therapies as indicated [1].

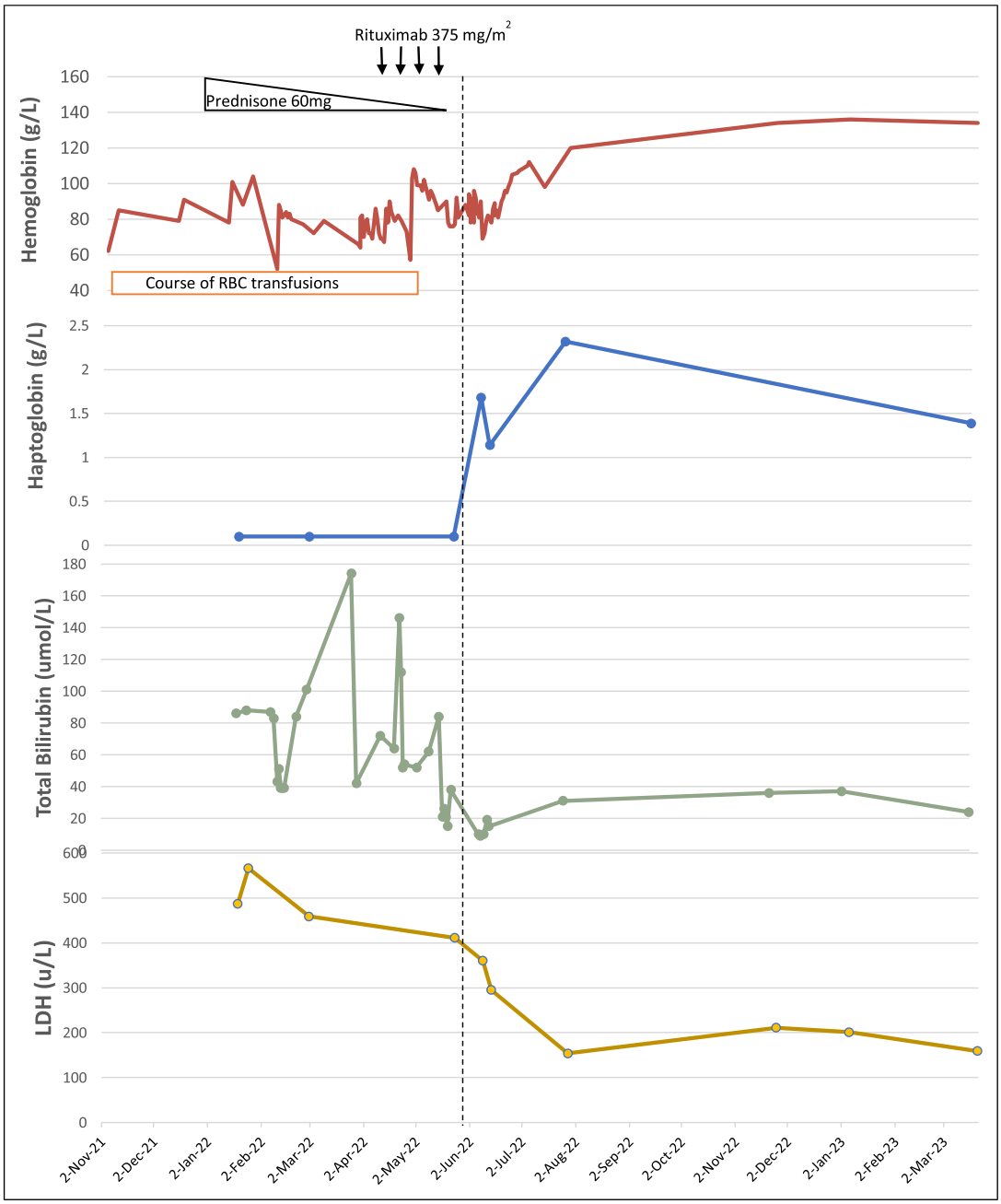

Fig. 2. Overall trend of Hb and hemolytic markers across various treatments modalities. **a** Hb (g/L). **b** Haptoglobin (g/L). **c** Total bilirubin (μmol/L). **d** Lactate dehydrogenase (U/L). The dotted black line depicts the time of gastric resection, which occurred on May 30, 2022.

AIHA is a rare disorder where antibodies are directed against self-RBC. Symptoms typically include fatigue, dyspnea on exertion, pallor, palpitations, and shortness of breath. More progressive disease can present with dizziness, jaundice, dark urine, and/or splenomegaly [2]. AIHA can be primary (idiopathic) or secondary in nature and is often classified as warm, cold, or mixed type. Warm AIHA, the most common type, constitutes approximately 70% of all AIHA subtypes. Global incidence is approximately 5–10 per 1,000,000 people [2]. It is most frequently seen in pediatric populations, patients with lymphoproliferative cancers,

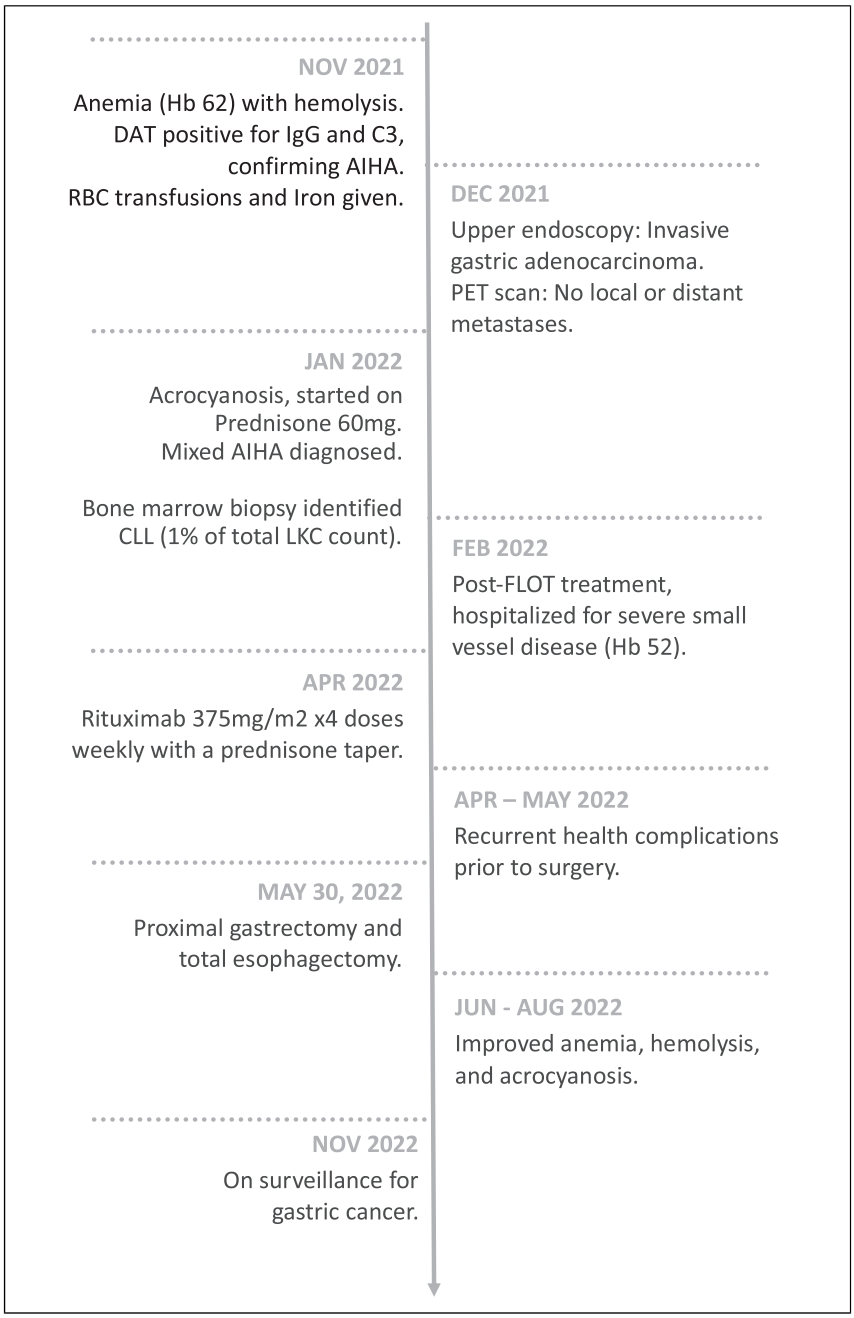

Fig. 3. Timeline of disease diagnosis and management.

and connective tissue disorders [2–4]. Pathogenesis involves autoantibodies (mainly IgG) that bind to RBC antigens, most commonly Rh-group antigens, and causes extravascular hemolysis at body temperature (~37C). Diagnosis requires the presence of hemolysis as well as positive direct or indirect antiglobulin test with IgG coating red cells and a pan-reactive eluate [3].

The pathogenesis of warm AIHA still remains poorly understood, and no underlying etiology is identified in approximately 50% of cases. The standard first-line treatment for warm AIHA is corticosteroids which is effective in approximately 80% of patients, in addition to treating any underlying conditions [5]. Median time of response is approximately 2 weeks, and if there is no improvement beyond the third week, prednisone is assumed ineffective [1].

For refractory presentations, second-line therapies such as rituximab and/or splenectomy can be considered. Rituximab has been shown to be effective both in idiopathic and secondary AIHA, including those associated with autoimmune and lymphoproliferative disorders. The majority of patients respond to rituximab within 1–3 months after their first dose [6]. Thereafter, immunosuppressive drugs such as azathioprine, cyclophosphamide, cyclosporine, or mycophenolate mofetil are considered [7].

Complementing warm AIHA is cold agglutinin disease (CAD), which has an incidence of 0.5–2 cases per million people and occurs primarily among elderly populations [2]. Unlike warm AIHA antibodies, cold-reactive antibodies are typically IgM immunoglobulins that bind to the red cell I-antigen at temperatures below 37°C and are efficient at fixing complement, resulting in extravascular hemolysis and hepatic clearance. Thus, cooling of the blood in the peripheral extremities results in agglutination and impaired circulation in CAD patients. Nearly half of patients with CAD have cold-induced acrocyanosis or Raynaud-like phenomena [3], the former of which was observed in this patient. Blood smear at room temperature typically shows agglutination and bloodwork demonstrates positive hemolytic markers with DAT demonstrating C3 coating red cells. A thermal amplitude of 30°C or higher is generally accepted as clinically significant, as are titers of >1:64, although there is no strict lower minimum. Associated etiologies include infection (i.e., mycoplasma, Epstein-Barr virus, cytomegalovirus), lymphoproliferative neoplasms, and connective tissue disorders. The decision to treat CAD is often reserved for patients with symptomatic anemia, transfusion dependence, and/or disabling circulatory signs. First-line treatment is cold avoidance and folic acid followed by a rituximab-containing regimen, although evidence typically shows only modest response rates [8].

In our patient's case, she presented with a simultaneous mixed warm and cold AIHA. This rare condition represents less than 10% of all AIHA. It is defined by the presence of warm IgG autoantibodies as well as clinically significant cold agglutinins [4]. A literature review of mixed AIHA cases between 1975 and 2007 identified only 98 cases overall in the literature and the causes remain largely unknown [9]. Mixed warm and cold AIHA is often characterized by lower Hb levels and a worse prognosis than warm AIHA, and thus two or more lines of therapy are frequently needed [10]. Some reports show a robust response to steroid treatment, but data on outcomes are often sparse while other reports harbor a grimmer prognosis. Etiologies are poorly defined in the literature, with autoimmune disorders and/or lymphoma being slightly more commonly cited [11]. Treatment is typically guided toward warm and cold AIHA. No formal guidelines exist to date to the author's knowledge. In our patient's case, it was not until her tumor resection that her Hb and hemolytic markers stabilized, marking the end of the need for supportive packed RBC transfusions. However, we recognize that this timeline may be confounded by the administration of rituximab, of which she completed a 4-dose course just under 3 weeks prior to resection. This is within the timeframe a rituximab response would be expected.

The occurrence of AIHA in the setting of solid tumors is rare in general. A 2010 analysis of AIHA in solid tumors revealed fifty-two cases between 1945 and 2009 in PubMed. AIHA (of all subtypes) were most commonly seen in renal cell cancers and Kaposi sarcomas but were also documented in ovarian, liver, colorectal, breast, and uterine cancers [12]. In our case, we describe a rare incidence of AIHA occurring in the setting of gastric carcinoma. Our literature review of AIHA in the setting of gastric adenocarcinoma revealed less than ten cases. We searched PubMed (1975–2023) for case reports or series of patients with the search terms "autoimmune hemolytic anemia" and "stomach or gastric cancer." A similar case by Agrawal and Alfonso reported the rare association between warm AIHA and stage 4 gastric adenocarcinoma in an 80-year-old patient. Although their report was limited to warm AIHA, they similarly showed persistent hemolysis despite adequate steroids, immunoglobin-based

treatment, and RBC transfusions. The initiation of palliative chemotherapy led to a stabilization in Hb levels and hemolysis within a few weeks [13]. Another study described a case of persistent warm AIHA with underlying stage 1 gastric stromal tumor in a 76-year-old patient. Post-splenectomy and curative resection, the hematological symptoms quickly resolved within 2 weeks. There was complete and/or sustained remission of AIHA, indicating a link between the anemia and the tumor [14].

In this case, surgical resection of the gastric adenocarcinoma was followed by the stabilization of the patient's hemolytic anemia in a short period of time, without further immunosuppressive treatments. The likelihood of AIHA being related to the underlying low clonal population CLL remains more likely; however, it is also important to consider the possibility of her solid tumor contributing to the pathogenesis. Fortunately, the patient ultimately recovered and this case also highlights one clinical approach to the simultaneous management of two life-threatening comorbidities.

Conclusion

This case report follows a 70-year-old female with a known diagnosis of mixed AIHA in the setting of gastric adenocarcinoma. The association of AIHA secondary to solid tumors is uncommon and under-studied. In our patient, there was a remarkable stabilization of her AIHA after successful resection of gastric adenocarcinoma. A hematologic cause remains as a probable etiology, but there remains a distinct plausible link between the mixed AIHA and gastric adenocarcinoma. Clinicians should consider solid tumors as a documented etiologic consideration on the differential of AIHAs, and pursue simultaneous management of AIHA and solid tumors when clinically appropriate.

Statement of Ethics

Ethical approval is not required for this study in accordance with local or national guidelines. All ethical standards of case report publication were adhered to under the policies of Western University. Written informed consent was obtained from the patient directly for publication of the details of their medical case and any accompanying images.

Conflict of Interest Statement

The authors have no conflicts of interest to declare.

Funding Sources

This manuscript received no specific funding.

Author Contributions

Anu Chinnadurai: investigation, resources, analysis, data curation, writing, reviewing, visualization. Scott Strum: investigation, resources, analysis, data curation, writing, reviewing, visualization methodology, supervision. Artin Ghassemian: analysis, writing, reviewing.

Dalilah Fortin: reviewing, visualization. Cheryl Foster: analysis, reviewing, visualization. Daniel Breadner: conceptualization, methodology, analysis, writing, reviewing, supervision, project administration.

Data Availability Statement

All data generated or analyzed during this study are included in this article. Further inquiries can be directed to the corresponding author.

References

1 Lordick F, Carneiro F, Cascinu S, Fleitas T, Haustermans K, Piessen G, et al. Gastric cancer: ESMO Clinical Practice Guideline for diagnosis, treatment and follow-up. Ann Oncol. 2022 Oct;33(10):1005–20.
2 Berentsen S, Barcellini W. Autoimmune hemolytic anemias. N Engl J Med. 2021 Oct 7;385(15):1407–19.
3 Hill QA, Hill A, Berentsen S. Defining autoimmune hemolytic anemia: a systematic review of the terminology used for diagnosis and treatment. Blood Adv. 2019 Jun 25;3(12):1897–906.
4 Tranekær S, Hansen DL, Frederiksen H. Epidemiology of secondary warm autoimmune haemolytic anaemia-a systematic review and meta-analysis. J Clin Med. 2021 Mar 17;10(6):1244.
5 Hill A, Hill QA. Autoimmune hemolytic anemia. Hematol Am Soc Hematol Educ Program. 2018 Nov 30;2018(1): 382–9.
6 Murakhovskaya I. Rituximab use in warm and cold autoimmune hemolytic anemia. J Clin Med. 2020 Dec 13; 9(12):4034.
7 Michalak SS, Olewicz-Gawlik A, Rupa-Matysek J, Wolny-Rokicka E, Nowakowska E, Gil L. Autoimmune hemolytic anemia: current knowledge and perspectives. Immun Ageing. 2020 Nov 20;17(1):38.
8 Berentsen S, Ulvestad E, Gjertsen BT, Hjorth-Hansen H, Langholm R, Knutsen H, et al. Rituximab for primary chronic cold agglutinin disease: a prospective study of 37 courses of therapy in 27 patients. Blood. 2004 Apr 15;103(8):2925–8.
9 Mayer B, Yürek S, Kiesewetter H, Salama A. Mixed-type autoimmune hemolytic anemia: differential diagnosis and a critical review of reported cases. Transfusion. 2008 Oct;48(10):2229–34.
10 Barcellini W, Fattizzo B, Zaninoni A. Current and emerging treatment options for autoimmune hemolytic anemia. Expert Rev Clin Immunol. 2018 Oct;14(10):857–72.
11 Win N, Tiwari D, Keevil VL, Needs M, Lakhani A. Mixed-type autoimmune haemolytic anaemia: unusual cases and a case associated with splenic T-cell angioimmunoblastic non-Hodgkin's lymphoma. Hematology. 2007 Apr;12(2):159–62.
12 Puthenparambil J, Lechner K, Kornek G. Autoimmune hemolytic anemia as a paraneoplastic phenomenon in solid tumors: a critical analysis of 52 cases reported in the literature. Wien Klin Wochenschr. 2010 Apr; 122(7–8):229–36.
13 Agrawal K, Alfonso F. A rare association of autoimmune hemolytic anemia with gastric adenocarcinoma. Case Rep Oncol Med. 2017;2017:8414602.
14 Guillaume N, Alimardani G, Chatelain D, Henry X, Claisse JF. Disappearance of auto-antibody-induced haemolysis after resection of a gastric stromal tumor. Case report and review of the literature. Rev Med Interne. 2003 Feb;24(2):131–5. French.