

[Primary Care]

Grade III Liver Laceration in a Female Volleyball Player

Abby E. Milton, MATrg, ATC,[†] Pamela J. Hansen, EdD, ATC,^{*†} Kevin C. Miller, PhD, ATC,[†] and Yeong S. Rhee, PhD[†]

A 20-year-old female collegiate volleyball athlete (body mass, 74.8 kg; height, 177.8 cm), with no previous history of abdominal injury, dove for a ball during a match and was struck in the anterolateral abdominal region by a teammate's knee. She experienced a solar plexus spasm, shortness of breath, and nausea. On-site evaluation revealed sharp pain in the right upper quadrant and epigastric area, pallor, continued nausea, and excessive sweating. Upon arrival to the emergency department, an abdominal/pelvic computed tomography (CT) scan with intravenous contrast showed a small amount of fluid along the posteromedial surface of the liver indicating a subcapsular hematoma. A trace amount of free fluid in the right paracolic gutter and pelvis was also noted, suggesting a hemoperitoneum. The athlete was diagnosed with a grade III laceration (> 3 cm parenchymal depth) on the right lobe of the liver. She was hemodynamically stable and vital sign values were normal ~2.5 hours postinjury (blood pressure, 118/76 mm Hg; heart rate, 68 beats per minute; respiratory rate, 16 breaths per minute; tympanic temperature, 36.3°C). The athlete was admitted into the intensive care unit for observation, and the attending physician decided on a conservative, nonoperative approach to treatment. Forty-eight hours postinjury, a second abdominal/pelvic CT scan was ordered and revealed no increased bleeding or extensive damage to the liver. Two days later, after being discharged from the hospital, she was prohibited from practicing until a third abdominal/pelvic CT scan was performed and showed no residual injury to the liver (5 weeks postinjury). The athlete returned to play 6 weeks postinjury without complications; however, she continued performing rehabilitation focusing on cardiorespiratory endurance.

Keywords: liver laceration; collegiate athlete; noncontact sport; blunt abdominal injuries

Traumatic abdominal injuries are rare in athletics and even rarer in noncollision or noncontact sports. Volleyball, a noncontact sport, is considered low risk for traumatic injuries, particularly to the abdominal region. More than half (55%) of all injuries in volleyball matches and practices affect the lower extremity.¹ Of those injuries to the abdomen, most are musculotendinous strains: an injury rate of 1:25, 000 athlete exposures in matches and 1:12, 500 athlete exposures in practices.¹ Although rare, health care professionals that work with an athletic population must remain cognizant of the signs, symptoms, and emergency management of blunt abdominal trauma since these injuries can be life threatening. We present the case of a female volleyball athlete who, during a collegiate volleyball match, suffered a grade III liver laceration on the right hepatic lobe due to a blunt abdominal blow from a teammate's knee.

CASE REPORT

A 20-year-old female intercollegiate volleyball athlete (mass, 74.8 kg; height, 177.8 cm) with no prior history of abdominal

injury was struck in the right anterolateral abdominal region by a teammate's knee while diving for a ball. Following the collision, she experienced a solar plexus spasm, dyspnea, and nausea. She was unable to stand and needed assistance off the court. The persistence of the athlete's signs and symptoms prompted further evaluation by the team physician, who observed sharp pain in the right upper quadrant and epigastric region, pallor, continued nausea, diaphoresis, ptyalism (hypersalivation), and a feeling of having a bowel movement. She exhibited point tenderness along the lower anterior costal margin bilaterally and over the xiphoid process. Anterior and lateral compression tests of the ribs were positive. There was no radiating pain, palpable deformities or abnormalities, crepitus, ecchymosis, or rigidity in the abdominal region. Ice was administered to her right side, and she was referred to the local emergency department for further evaluation and testing. In addition to a liver injury, the differential diagnoses included a rib/xiphoid process fracture, costochondral separation, splenic injury, and/or a solar plexus injury.

Upon arrival to the emergency room, the athlete described her pain as severe (8 of 10; 0 = no pain, 10 = severe pain) in the right hypochondriac and epigastric area. She continued to

From [†]North Dakota State University, Fargo, North Dakota

^{*}Address correspondence to Pamela Hansen, North Dakota State University, PO Box 6050, Dept 2620, Fargo, ND 58104 (e-mail: pamela.j.hansen@ndsu.edu).

DOI: 10.1177/1941738112451429

© 2012 The Author(s)

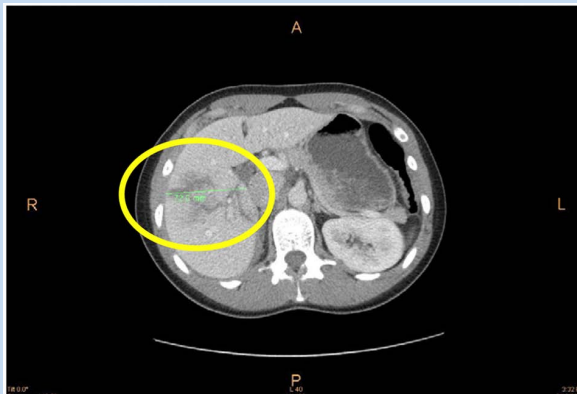


Figure 1. Transverse abdominal/pelvic computed tomography scan at 2.5 hours postinjury. Note the area of linear hypoenhancement involving the right lobe of the liver that extends from the lateral surface to the hilar region indicative of a liver laceration (circled). There was a small amount of intermediate density fluid along the medial posterior surface of the liver indicative of a subcapsular hematoma. Also a trace amount of free fluid was noted along the right paracolic gutter and in the pelvis, which is of intermediate intensity, suggesting a small component of hemoperitoneum.

experience nausea, dizziness, and weakness. Vital signs were as follows: blood pressure, 118/76 mm Hg; heart rate, 68 beats per minute; respiration rate, 16 breaths per minute; tympanic temperature, 36.3°C. Physical examination findings included normal heart rate, rhythm, and sound; no respiratory distress; normal breath and bowel sounds; no organomegaly; and no abdominal distension. The athlete's neurovascular status was intact to her extremities, but she continued to display pale, cool skin with diaphoresis. For pain, she was given hydromorphone (1 mg diluted with normal saline via slow intravenous push).

The diagnostic tests indicated that plasma potassium concentration and bicarbonate were low (plasma potassium concentration = 3.1 mmol/L [normal = 3.5-5.3 mmol/L]; bicarbonate = 22 mmol/L [normal = 23-32 mmol/L]) and that plasma glucose concentration was high (132 mg/dL [normal = 70-100 mg/dL]). Additionally, the gallbladder, spleen, kidneys, pancreas, and adrenal glands were unremarkable; no obvious bowel wall thickening; lung bases were clear; and no rib fractures or other acute osseous abnormalities were identified. No liver enzyme tests were ordered. The computed tomography (CT) scan showed trace fluid along the posteromedial surface of the liver and in the right paracolic gutter indicating a small subcapsular hematoma and hemoperitoneum (Figure 1). The athlete was diagnosed with a grade III laceration on the right lobe of the liver. A grade III laceration is characterized by a laceration that is > 3 cm of parenchymal depth, a subcapsular hematoma that

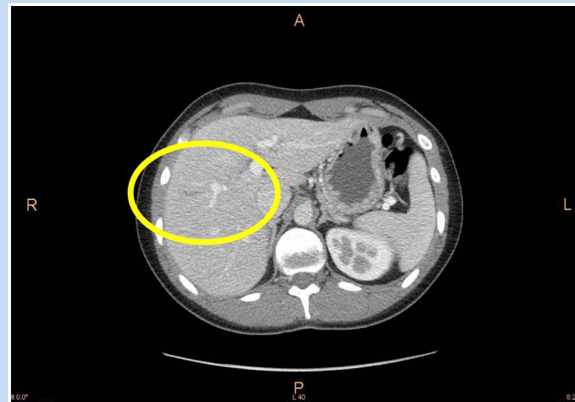


Figure 2. Transverse abdominal/pelvic computed tomography scan at 5 weeks postinjury. Note the absence of the hematoma and laceration in the circled region where the original laceration had occurred, demonstrating significant healing.

is > 50% surface area of ruptured subcapsular or parenchymal hematoma, and an intraparenchymal hematoma that is > 10 cm or expanding.¹³

The athlete was admitted into the intensive care unit for observation. The attending physician decided on a conservative, nonoperative management strategy because that grade of liver injury was not extensive enough to warrant surgery. Forty-eight hours postinjury, laboratory tests were repeated, and a second abdominal/pelvic CT scan was performed and showed no expanding hematoma to other lobes of the liver. The athlete remained hemodynamically stable, though she was admitted for an additional 2 days for observation. After being discharged from the hospital, she was prohibited from strenuous physical activity until a third abdominal/pelvic CT scan 5 weeks postinjury showed no residual damage to the liver (Figure 2).

The physician cleared the athlete to begin a progressive rehabilitation protocol focusing on cardiorespiratory and low-intensity sport-specific exercise at 5 weeks postinjury. The athlete returned to competition 6 weeks postinjury without complications.

DISCUSSION

This clinical case was unique for 2 reasons. First, liver lacerations occurring to athletes participating in noncollision/noncontact sports are particularly rare. Second, this athlete returned to competition after 6 weeks of conservative, nonoperative rehabilitation. The recommended recovery duration for liver lacerations is 12 to 24 weeks.^{6,11,12}

Volleyball is a noncontact sport, making the occurrence of a liver laceration or any abdominal injury unusual. There are no cases of liver lacerations in volleyball athletes. Liver lacerations have occurred in football,^{11,12} mountain biking,²

and bodyboarding/surfing⁷ because of direct blows to the abdomen. Athletes participating in contact and collision sports are more susceptible to abdominal blows since there is an increased risk of blows to that region (eg, tackling in football).¹⁰⁻¹² Recreational sports, such as mountain biking and bodyboarding, have an increased risk as well, due to the unpredictability of environmental factors involved with each sport.^{2,7}

Besides the liver, the most commonly injured abdominal organs in contact sports due to direct blows are the kidneys and spleen.^{2,7,11,12} A splenic injury was on the differential in this clinical case due to the athlete's point tenderness on the inferior costal margin on her left and right sides, even though the blow occurred to the right upper quadrant. Splenic injury can occur by a contrecoup mechanism.¹²

The American Association for the Surgery of Trauma has 6 classifications of liver injuries, with a grade I being the least severe to a grade VI being the most severe.¹³ Grade III injury has a 15.7% mortality rate because of its complexity.^{4,6,13}

A simple hepatic parenchymal laceration in the absence of active hemorrhage, diffuse peritoneal signs or other peritoneal injuries, a hemoperitoneum less than 500 mL, and no need for blood transfusions met the criteria for nonsurgical management.⁶ Most hemodynamically stable patients (70%-90%) with liver injuries do not require surgical intervention.^{3,4,6,8} Nonoperative management of hepatic injuries has become the standard of care in the pediatric and adult populations.^{3,5,6,9,12} Hepatic injuries treated nonoperatively yield good clinical outcomes with brief stays in the intensive care unit.^{4,6,8}

This athlete returned to play 6 weeks postinjury—about half the time than originally anticipated. Current guidelines on return to play following grade III liver injuries allows for approximately 8 weeks of recovery.⁶ Carrillo et al have suggested healing time of 12 to 24 weeks and avoidance of physical activity and contact sports for this entire duration.⁶ The athlete's follow-up CT scan at 5 weeks postinjury showed no residual damage to the liver, prompting the early return. Upon clearance, the athlete began a progressive rehabilitation protocol at 5 weeks postinjury and was able to return to full competition at 6 weeks without complications. The duration of an athlete's inactivity is predicated on the extent of liver

damage and the liver's ability to heal itself. Diagnostic imaging may be undertaken earlier than the recommended 12-week postinjury timeline to help in decision making.⁶ Although this athlete had a quick return to play, each case is unique and return-to-play decisions should be made using each athlete's case information.

CONCLUSION

Blunt abdominal injuries such as liver lacerations may occur in any sport. Abdominal injuries can be life threatening. Early recognition of the signs and symptoms of abdominal organ injuries and the administration of proper emergency care are critical to prevent catastrophic consequences. If the athlete is hemodynamically stable, conservative, nonoperative management following a grade III liver laceration may yield successful results and allow athletes to return to competition sooner.

REFERENCES

1. Agel J, Palmieri-Smith RM, Dick R, Wojtys EM, Marshall SW. Descriptive epidemiology of collegiate women's volleyball injuries: national collegiate athletic association injury surveillance system, 1988-1989 through 2003-2004. *J Athl Train.* 2007;42(2):295-302.
2. Aleman KB, Meyers MC. Mountain biking injuries in children and adolescents. *Sports Med.* 2010;40(1):77-90.
3. Becker CD, Mentha G, Terrier F. Blunt abdominal trauma in adults: role of CT in the diagnosis and management of visceral injuries. Part 1: liver and spleen. *Eur Radiol.* 1998;8(4):553-562.
4. Bochicchio GV. The management of complex liver injuries. *Trauma Q.* 2002;15(1):55-76.
5. Budinger JM. A patient education tool for nonoperative management of blunt abdominal trauma. *J Trauma Nurs.* 2007;14(1):19-23.
6. Carrillo EH, Platz A, Miller FB, Richardson JD, Polk HC. Non-operative management of blunt hepatic trauma. *Br J Surg.* 1998;85(4):461-468.
7. Choo KL, Hansen JB, Bailey DM. Beware the boogie board: blunt abdominal trauma from bodyboarding. *Med J Aust.* 2002;176(7):326-327.
8. Ochsner MG. Factors of failure for nonoperative management of blunt liver and splenic injuries. *World J Surg.* 2001;25(11):1393-1396.
9. Potoka DA, Saladino RA. Blunt abdominal trauma in the pediatric patient. *Clin Ped Emerg Med.* 2005;6(1):23-31.
10. Ralston DJ, Scherm MJ. Splenic artery avulsion in a high school football player: a case report. *J Athl Train.* 2004;39(2):201-205.
11. Ray R, Lemire JE. Liver laceration in an intercollegiate football player. *J Athl Train.* 1995;30(4):324-326.
12. Stricker PR, Hardin BH, Puffer JC. An unusual presentation of liver laceration in a 13-yr-old football player. *Med Sci Sports Exerc.* 1993;25(6):667-672.
13. Tinkoff G, Esposito TJ, Reed J, et al. American association for the surgery of trauma organ injury scale I: spleen, liver, and kidney, validation based on the national trauma data bank. *J Am Coll Surg.* 2008;207(5):646-655.