

Management of sizeable carotid body tumor: Case report and review of literature

Mohamed A Elsharawy, Hind Alsaif[†], Ayman Elsaid, Ali Kredees

Departments of Surgery, and [†]Radiology, University of Dammam, Al-Khobar, Kingdom of Saudi Arabia

Access this article online

Website: www.avicennajmed.com

DOI: 10.4103/2231-0770.120503

Quick Response Code:



ABSTRACT

Carotid body tumor is a paraganglioma derived from the neural crest. It arises from the carotid body which acts as a vascular chemoreceptors and is usually located at the carotid bifurcation. Sizeable (Shamblin III, >5 cm size) tumors are large and typically encase the carotid artery requiring vessel resection and replacement. Management of such tumors carries a high risk of postoperative mortality and morbidity rates specially with regards to neurovascular complications. We report a case of sizeable tumor which was surgically removed with minimal complications.

Key words: Carotid body tumor, paraganglioma, Shamblin

INTRODUCTION

CBT is a rare neck tumor that is derived from the neural crest.^[1] Management of sizeable (Shamblin III, >5 cm size) tumors carries a high risk of postoperative mortality and morbidity rates specially with regards to neurovascular complications.^[2] We report a case of sizeable tumor which was surgically removed with minimal blood loss, temporary neurological loss, and no cerebro vascular complications. No preoperative embolization was performed. Review of literature^[3] and our case reveals that proper surgical technique is the key to improve treatment outcome.

CASE REPORT

A 40-year-old Yemeni woman was admitted to King Fahd Hospital of University, Alkhobar, Saudi Arabia with a progressively growing mass in the left anterolateral side of her neck of 5 years duration. She presented with neck tenderness, dizziness, increasing number of fainting attacks, and shortness of breath. There was no history of hoarseness, dysphagia, or palpitation and no family history of a similar condition. Her left pupil was slightly more contracted than the right pupil (Horner's syndrome). The rest of her neurologic examination was unremarkable. Indirect laryngoscopy revealed slightly impaired

movement of left vocal cord. Contrast enhanced computed tomography (CECT) scan of the neck with subsequent CT angiograms of the carotids showed a $6.9 \times 5 \times 5.8$ cm hypervascular solid left carotid space mass encasing the common carotid artery (CCA) and both internal CA (ICA) and external CA (ECA) and splaying the carotid bifurcation with no luminal narrowing or thrombosis [Figures 1 and 2]. There was no contralateral tumor. The tumor was diagnosed as carotid body paraganglioma of Shamblin group III. Horner's syndrome was due to tumor encasement of the left sympathetic chain. No preoperative embolization was performed. The tumor was surgically removed under locoregional anesthesia and supplemented with intravenous propofol after reconstruction of the CA. The hypoglossal and vagus nerves were identified during surgery and preserved. Part of CCA, ICA, and ECA were removed with tumor and ICA was reconstructed with polytetrafluoroethylene (PTFE) graft [Figures 3 and 4]. Monitoring of the neurological status was achieved by simple clinical evaluation of the state of consciousness under local anesthesia, and by continuous regional oxygen saturation (rSO₂), measured with a cerebral oximeter (Somanetics InVivo cerebral oximeter). It was not necessary to place a shunt. Blood loss

The case was presented at the 7th annual meeting of the Gulf Vascular Society, Muscat, Oman, March 2013.

Address for correspondence: Dr. Mohamed A. Elsharawy, Professor Vascular Surgery, Al-Khobar - 31952, Eastern Province, Kingdom of Saudi Arabia. E-mail: elsharawya@yahoo.co.uk

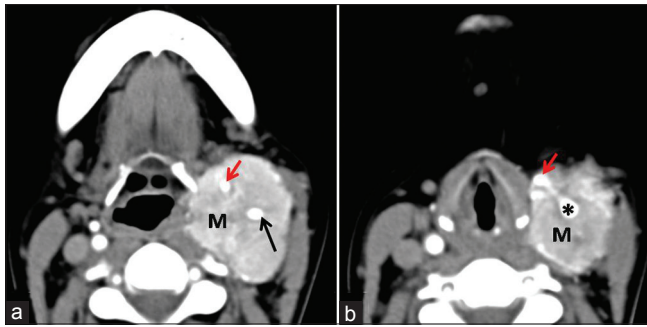


Figure 1: (a) Hypervascular left carotid space mass (M) splaying and encasing the internal carotid artery (ICA; long arrow) and the external CA (ECA; short arrow). (b) The common CA (CCA) was also encased (*), findings are in keeping with type III A1, A2, and A3 carotid body tumor. Hypertrophied left descending pharyngeal artery (arrow)

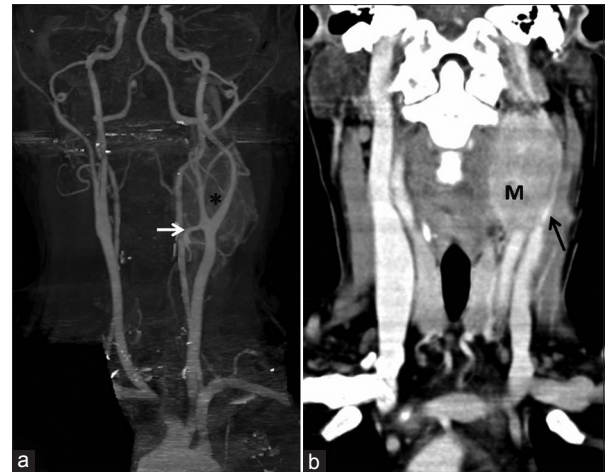

Figure 2: Computed tomography angiography (CTA) carotids (a) 3D: carotid body tumor with splaying of the carotid bifurcation (*). Note: Hypertrophied left descending pharyngeal artery (arrow). (b) Coronal reformats: Significant mass effect on the left internal jugular vein which appears markedly compressed

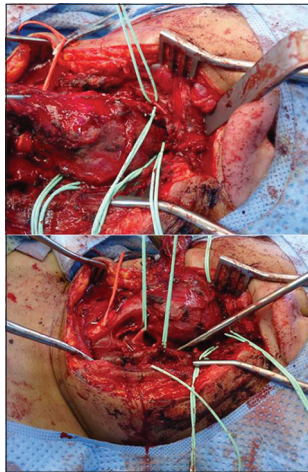


Figure 3: Perioperative finding of left side tumor. A huge hypervascular tumor surrounds the left common, internal, and external carotid arteries

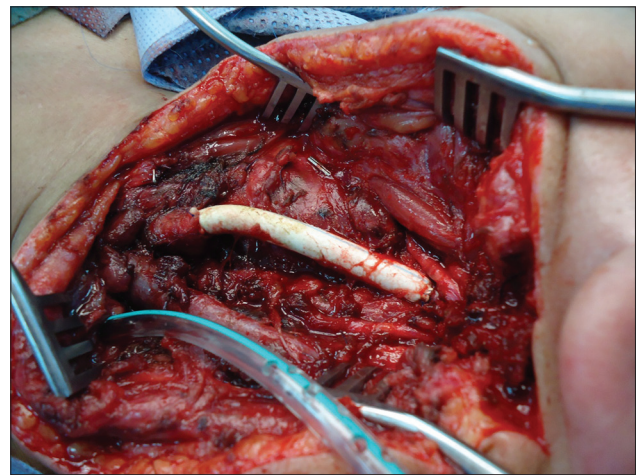


Figure 4: Internal carotid artery was reconstructed with polytetrafluoroethylene (PTFE) graft

was about 450 ml. Postoperatively, a transient swallowing difficulty and tongue deviation developed probably due to stretching of the hypoglossal nerve during the operation. On laryngoscopic examination, left-sided vocal cord paralysis was aggravated. There was no cerebrovascular event after surgery. Histopathology examination confirmed the preoperative diagnosis of paraganglioma [Figure 5]. Six months after surgery, the patient could speak and swallow normally and her tongue deviation disappeared. Graft surveillance at 9 months revealed a patent graft with normal flow.

DISCUSSION

CBT is a paraganglioma arising from the carotid body which acts as a vascular chemoreceptors and is usually located at the carotid bifurcation.^[2] Although most of CBT are benign and slow growing, early excision is recommended because of the unpredictable malignancy potential. Even if the tumor is not pathologically malignant, it will continue to grow and can cause various complications and will become too

difficult for a surgeon to remove without complications.^[4] In 1971, Shamblin *et al.*, introduced a classification system based on the size of the tumor into groups I, II, and III.^[5] Group III, like the present case, consists of tumors that are large and typically encase the CA requiring vessel resection and replacement. Most of the previous studies reported high rate of neurovascular complication (23-47%)^[2,6,7] with Shamblin III tumors. The risk seems to be more significant when the tumor size is more than 5 cm^[8] (similar to the present case). Therefore, early detection and prompt surgical resection of CBTs will decrease surgical morbidity.^[2] Nevertheless, early detection of the small tumor is difficult because of the limited clinical symptoms during its early stage.^[9]

In large tumors, neurovascular symptoms and signs, such as hoarseness, vocal cord paralysis, dysphasia, Horner's syndrome, carotid pulsations, thrill, and symptoms of

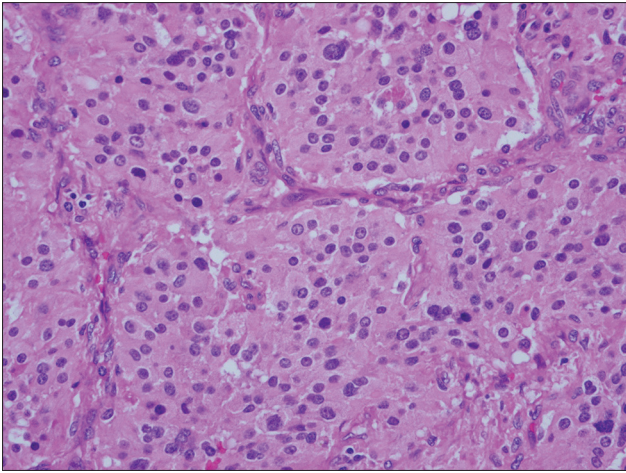


Figure 5: Well-defined nests of cuboidal cells (zellballen) are separated by highly vascularized fibrous septa (hematoxylin and eosin (H and E, x400)

cerebral ischemia or carotid sinus syndrome, are usually present.^[9] In this case, Horner's syndrome was detected.

Noninvasive imaging studies like CT scan with contrast and magnetic resonance imaging (MRI) are useful modalities to identify CBT.^[10] In our case, CT with contrast was enough for the diagnosis. CT demonstrated a solid mass that showed homogenous enhancement on intravenous contrast administration. The presence of uniform contrast enhancement and large feeding vessels into the tumor excludes enlarged lymph nodes and schwannomas. Carotid angiography can demonstrate the tumor hypervascularity and widening of the carotid bifurcation by a well-defined tumor blush ("Lyre sign"), which is a pathognomonic angiographic finding. Selective embolization can be used to reduce the size of tumor and bleeding complications during surgery.^[11] However, other studies showed that embolization has no significant effect on intraoperative blood loss or operation time^[2] and was not effective in reducing neurological complications.^[12] In our case there were multiple arteries supplying the tumor making super selective embolization very difficult. Fortunately, blood loss was not significant.

Cerebrovascular accidents are the most serious postoperative complication and have been reported to be up to 11%.^[13] The balloon test occlusion of the ICA was not performed in this case since its predictive value is low.^[14] We did not have to use carotid shunt since neurological status and rSO₂ were maintained normal during the whole procedure. There was no evidence of vascular insufficiency after surgery. Although autogenous vein graft has better patency rates than PTFE in peripheral arterial bypasses,^[15] this advantage was not confirmed for CA bypasses.^[3,16] The incidence of cranial nerve injury is reported as high as 40%.^[17] The hypoglossal and vagus nerves are the most vulnerable to

injury.^[2] Both nerves were identified and preserved in the present case.

In conclusion, despite the development of surgical and endovascular techniques, huge carotid body paraganglioma continue to have high incidence of pre- and postoperative complications. Carotid body paraganglioma should be removed immediately upon detection. Identification of the adjacent nerves during surgery is essential in reducing postoperative problems.

REFERENCES

1. Avgerinos ED, Moulakakis K, Broutzou E, Giannakopoulos TG, Lazaris AM, Koumariou A, *et al.* Advances in assessment and management of carotid body tumors. *Vascular* 2011;19:250-6.
2. Lim JY, Kim J, Kim SH, Lee S, Lim YC, Kim JW, *et al.* Surgical treatment of carotid body paragangliomas: Outcomes and complications according to the Shamblin classification. *Clin Exp Otorhinolaryngol* 2010;3:91-5.
3. Davidovic L, Ilic N, Dimitrijevic M, Dukic V, Dzodic R. Surgical management of cervical paragangliomas. *Am Surg* 2008;74:1171-6.
4. Dimakakos PB, Kotsis TE. Carotid body paraganglioma: Review and surgical management. *Eur J Plast Surg* 2001;24:58-65.
5. Shamblin WR, ReMine WH, Sheps SG, Harrison EG Jr. Carotid body tumor (chemodectoma). Clinicopathologic analysis of ninety cases. *Am J Surg* 1971;122:732-9.
6. Westerband A, Hunter GC, Cintora I, Coulthard SW, Hinni ML, Gentile AT, *et al.* Current trends in the detection and management of carotid body tumors. *J Vasc Surg* 1998;28:84-92.
7. Wang SJ, Wang MB, Barauskas TM, Calcaterra TC. Surgical management of carotid body tumors. *Otolaryngol Head Neck Surg* 2000;123:202-6.
8. Singh D, Pinjala RK, Reddy RC, Satya Vani PV. Management for carotid body paragangliomas. *Interact Cardiovasc Thorac Surg* 2006;5:692-5.
9. Park SJ, Kim YS, Cho HR, Kwon TW. Huge carotid body paraganglioma. *J Korean Surg Soc* 2011;81:291-4.
10. Carroll W, Stenson K, Stringer S. Malignant carotid body tumor. *Head Neck* 2004;26:301-6.
11. Persky MS, Setton A, Niimi Y, Hartman J, Frank D, Berenstein A. Combined endovascular and surgical treatment of head and neck paragangliomas: A team approach. *Head Neck* 2002;24:423-31.
12. Sen I, Stephen E, Malepathi K, Agarwal S, Shyamkumar NK, Mammen S. Neurological complications in carotid body tumors: A 6-year single-center experience. *J Vasc Surg* 2013;57:64-8S.
13. Sajid MS, Hamilton G, Baker DM. Joint Vascular Research Group. A multicenter review of carotid body tumor management. *Eur J Vasc Endovasc Surg* 2007;34:127-30.
14. Segal DH, Sen C, Bederson JB, Catalano P, Sacher M, Stollman AL, *et al.* Predictive value of Balloon test occlusion of the internal carotid artery. *Skull Base Surg* 1995;5:97-107.
15. Solaković E, Totić D, Solaković S. Femoro-popliteal bypass above knee with saphenous vein vs. synthetic graft. *Bosn J Basic Med Sci* 2008;8:367-72.
16. Miao B, Lu Y, Pan X, Liu D. Carotid artery resection and reconstruction with expanded polytetrafluoroethylene for head and neck cancer. *Laryngoscope* 2008;118:2135-8.
17. Por YC, Lim DT, Teoh MK, Soo KC. Surgical management and outcome of carotid body tumors. *Ann Acad Med Singapore* 2002;31:141-4.

Cite this article as: Elsharawy MA, Alsaif H, Elsaid A, Kredees A. Management of sizeable carotid body tumor: Case report and review of literature. *Avicenna J Med* 2013;3:106-8.

Source of Support: Nil, **Conflict of Interest:** None declared.