

Early anterior capsular fibrosis and formation of secondary cataract with in-the-bag intraocular lens decentration in a patient with retinitis pigmentosa

Madhu Bhoot, Suneeta Dubey

Key words: Capsular fibrosis, IOL decentration, retinitis pigmentosa, secondary cataract

A 53-year-old male with retinitis pigmentosa (RP) presented with decreased vision in the right eye. His BCVA was 20/40 in the right eye (RE) and 20/120 in the left eye (LE). On examination, there was posterior subcapsular cataract in the right eye and pseudophakia in the left eye. IOP as measured by Goldmann applanation tonometry was 19 mmHg in both the eyes. Gonioscopy showed open angles in both the eyes. Fundus examination showed a medium-size optic disc with cup disc ratio of 0.7:1 in the RE and 0.8:1 in the LE with inferior rim thinning and disc pallor in both the eyes.

He underwent uneventful phacoemulsification with in-the-bag IOL implantation (single piece foldable hydrophilic acrylic) in the RE.

One week postoperatively, his BCVA was 20/30. However, 3 weeks after surgery, he presented with diminution of vision in the RE to 20/60. There was a thick vertical band of secondary cataract seen on the anterior surface of intraocular lens (IOL) in the pupillary area with [Fig. 1a] severe bag contraction and nasal decentration of the IOL [Fig. 1b]. The haptics of the IOL were seen folded inside the bag. To prevent further zonular stress, the thick band of secondary cataract was disrupted with the help of Nd: YAG laser. Following Nd:YAG laser, his vision improved to 20/30 [Fig. 1c and d].

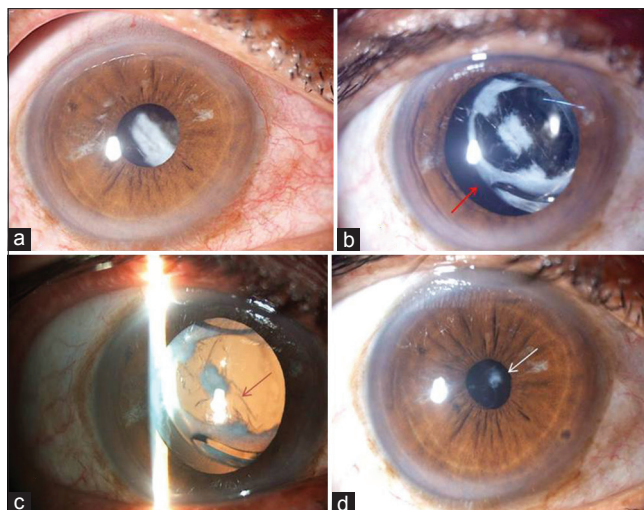


Figure 1: (a) Band of secondary cataract in the pupillary area. (b) Severe bag contraction with in-the-bag IOL decentration towards the nasal side (red arrows). (c and d) Dissolution of the band of secondary cataract following Nd:YAG laser (red and white arrows)

Late capsular bag contracture and IOL subluxation following RP has been reported^[1-3] but early contracture with secondary cataract and decentration has not been reported in the literature yet. Early and frequent follow-up is required following cataract surgery in patients with RP, and YAG laser can be done in these patients to interrupt the pathologic process. Polishing of the area under the anterior capsule and use of hydrophobic acrylic IOLs with a square edge design should be considered in patients with RP to prevent the formation of secondary cataract.

Declaration of patient consent

The authors certify that they have obtained all appropriate patient consent forms. In the form the patient(s) has/have given his/her/their consent for his/her/their images and other clinical information to be reported in the journal. The patients understand that their names and initials will not be published and due efforts will be made to conceal their identity, but anonymity cannot be guaranteed.

Financial support and sponsorship

Nil.

Conflicts of interest

There are no conflicts of interest.

This is an open access journal, and articles are distributed under the terms of the Creative Commons Attribution-NonCommercial-ShareAlike 4.0 License, which allows others to remix, tweak, and build upon the work non-commercially, as long as appropriate credit is given and the new creations are licensed under the identical terms.

For reprints contact: reprints@medknow.com

Cite this article as: Bhoot M, Dubey S. Early anterior capsular fibrosis and formation of secondary cataract with in-the-bag intraocular lens decentration in a patient with retinitis pigmentosa. Indian J Ophthalmol 2020;68:646-7.

Access this article online

Quick Response Code:



Website:

www.ijo.in

DOI:

10.4103/ijo.IJO_977_19

Department of Glaucoma, Dr. Shroff's Charity Eye Hospital, New Delhi, India

Correspondence to: Dr. Madhu Bhoot, Dr. Shroff's Charity Eye Hospital, 5027, Kedarnath Road, Daryaganj, New Delhi - 100 002, India. E-mail: drmadhubhoot@gmail.com

Received: 21-May-2019

Revision: 28-Aug-2019

Accepted: 20-Sep-2019

Published: 16-Mar-2020

References

1. Hayashi K, Hayashi H, Matsuo K, Nakao F, Hayashi F. Anterior capsule contraction and intraocular lens dislocation after implant surgery in eyes with retinitis pigmentosa. *Ophthalmology* 1998;105:1239-43.
 2. Rachipalli R, Srinivas K. Capsulorhexis phimosis in retinitis pigmentosa despite capsular tension ring implantation. *J Cataract Refract Surg* 2001;27:1691-964.
 3. Najjar DM, Igbre AO, Tsai FF. Late capsular bag contraction and intraocular lens subluxation in retinitis pigmentosa: A case report. *J Med Case Rep* 2011;5:65.
-