

## CASE REPORT

# Duration of immunotherapy in patients with advanced lung adenocarcinoma with negative driver genes: case report and literature review

Qinge Shan<sup>†</sup>, Haiyong Wang<sup>†</sup>, Xiao Han, Jun Guo & Zhehai Wang

Department of Internal Medicine-Oncology, Shandong Cancer Hospital and Institute, Shandong First Medical University and Shandong Academy of Medical Sciences, Jinan, China

**Keywords**

Case reports; immunotherapy; NSCLC.

**Correspondence**

Jun Guo and Zhehai Wang, Department of Internal Medicine-Oncology, Shandong Cancer Hospital and Institute, Jiyuan Road 440, Jinan, Shandong 250117, China.  
Tel: +86 531 6762 6332  
Fax: 86 531 8798 4079  
E-mail: jngj2005@126.com (Jun Guo); badgood007@126.com (Zhehai Wang)

<sup>†</sup>These authors are co-first authors of this manuscript.

Received: 30 June 2020;

Accepted: 15 July 2020.

doi: 10.1111/1759-7714.13600

Thoracic Cancer **11** (2020) 3001–3006**Abstract**

Here, we report two cases of advanced non-small cell lung cancer (NSCLC) in patients with negative driver genes who received ICI treatment for less than two years but continued to benefit from their administration after drug withdrawal. The first patient was diagnosed with left lung adenocarcinoma, cT1cN3M1c, stage IVb, and after four cycles achieved a completed response (CR). After 10 cycles of camrelizumab treatment, immunotherapy was discontinued because of hepatotoxicity. When the drug was discontinued, the curative effect was evaluated as CR. At the last follow-up, the drug withdrawal time had been more than 20 months, and the response was maintained at CR, with PFS of over 30 months. In the second case, the patient was diagnosed with left lung adenocarcinoma, cT1N3M1c, stage IVb. The patient was treated with sintilimab, and due to cardiac and skin toxicity, the patient withdrew from the trial after five cycles of immunotherapy. After drug withdrawal, the curative effect of the patients was maintained at PR. At the last follow-up, the drug withdrawal time was more than three months, and the curative effect was evaluated as PR. The PFS was more than nine months. In conclusion, whether the drug can be discontinued in advance after immune checkpoint inhibitor (ICI) therapy has been effective remains a concern, and at present there is no final conclusion in the medical profession. However, the results of this study indicate that early withdrawal of immunotherapy due to adverse reactions might also benefit patients with advanced lung adenocarcinoma with negative driver genes who achieve an early response to immunotherapy.

**Introduction**

The application of immune checkpoint inhibitors (ICIs) of anti-programmed cell death 1 (PD-1) or programmed death ligand 1 (PD-L1) antibodies in patients with non-small cell lung cancer (NSCLC) has been reported to improve the disease response rate, progression-free survival (PFS) and overall survival (OS).<sup>1–4</sup> It is worth noting that anti-PD-1 antibody has strong efficacy and manageable safety in a variety of tumor types, with a response rate of 40%–53%.<sup>1,5–12</sup> In the National Comprehensive Cancer Network (NCCN) guidelines, the recommendation for first-line treatment (category 1) of advanced lung

adenocarcinoma with negative driver genes is carboplatin or cisplatin + pemetrexed + pembrolizumab when PD-L1 expression  $\geq 1\%$ –49%; whereas carboplatin or cisplatin + pemetrexed + pembrolizumab or pembrolizumab is recommended when PD-L1 expression  $\geq 50\%$ .<sup>13</sup> The duration of immunotherapy is still an open question. For advanced NSCLC, the treatment time of pembrolizumab in the KEY-NOTE024 study<sup>14</sup> was 35 cycles, and nivolumab was used in the CheckMate078 study<sup>15</sup> until the tumor progressed or the patient became intolerant. For extensive stage small cell lung cancer (ES-SCLC), atezolizumab was maintained until the disease progressed or there was no clinical benefit in the IMpower133 study.<sup>16</sup>

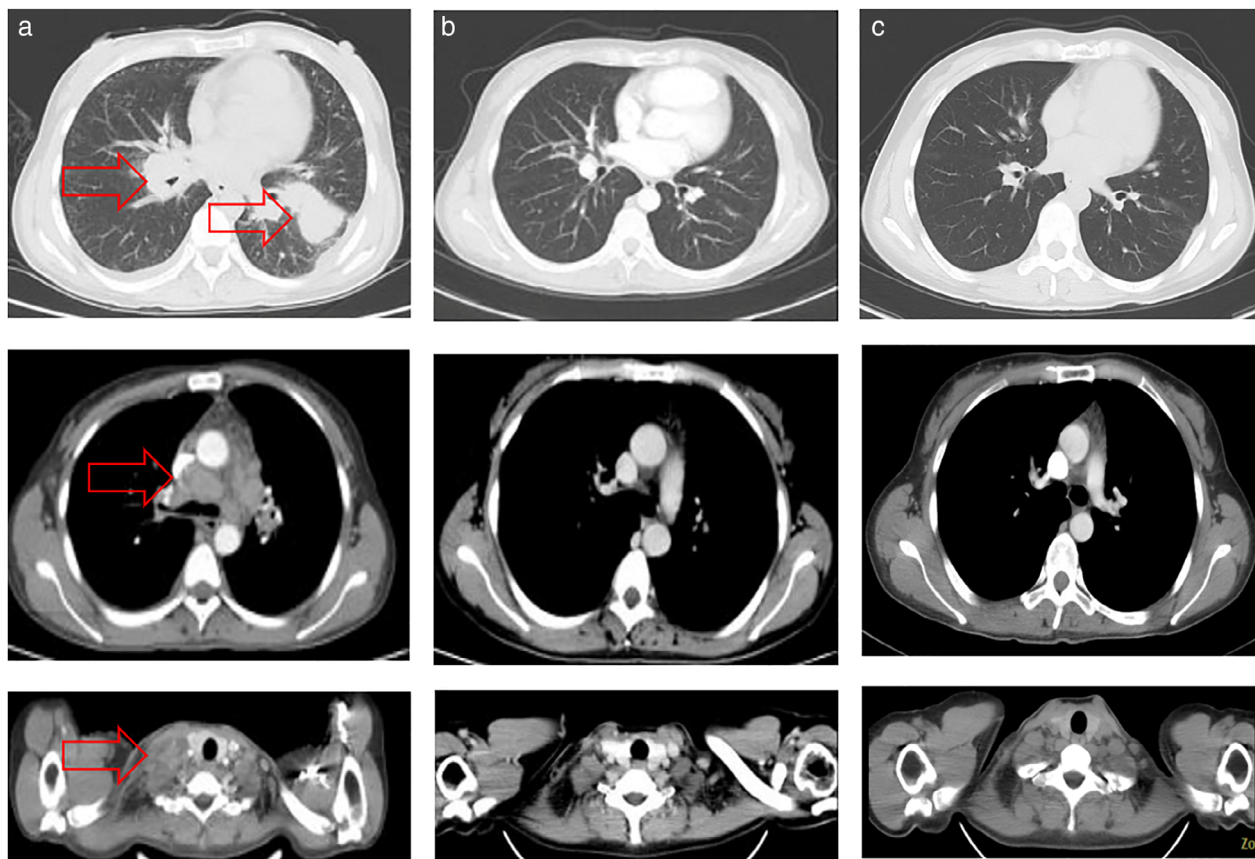
In recent years, the use of ICIs has changed the mode of tumor treatment. However, whether we can stop the drug in advance after effective treatment with immunotherapy is a concern, and there is no final conclusion in the medical profession at present. Here, we report two cases of advanced NSCLC patients with negative driver genes treated with ICIs for less than two years but who continued to benefit after drug withdrawal.

## Case reports

### Case 1

A 33-year-old female patient was admitted to Shandong Cancer Hospital. In August 2017, computed tomography (CT) scan showed a left lung mass, multiple enlarged lymph nodes in both hilum and mediastinum, enlarged right cervical lymph node and plumpness of the bilateral adrenal gland (Fig 1a). Following puncture biopsy, adenocarcinoma was confirmed by pathology. The expression of PD-L1 was 90%. The patient was diagnosed with left lung

adenocarcinoma, cT1cN3M1c, stage IVb. The results of gene detection showed that it was *EGFR* wild-type, and that *ALK* rearrangement and *ROS1* gene fusion were negative. After screening, the patient was enrolled into the clinical study and began immunotherapy in September 2017. The treatment regimen was camrelizumab combined with pemetrexed disodium plus carboplatin every three weeks. After four cycles of treatment, the curative effect reached complete remission (CR) (Fig 1b). After another two cycles of treatment, the patient entered the period of maintenance treatment, and the maintenance regimen was camrelizumab combined with pemetrexed every three weeks. During the period of regular follow-up and re-examination, the overall curative effect was CR. After four cycles of maintenance therapy, antitumor therapy was discontinued because of hepatotoxicity and the patient received hepatoprotective therapy. At the same time, the patient withdrew from the clinical trial. All antitumor treatments were terminated in June 2018 and the patient entered the stage of follow-up and observation. The patient was followed-up regularly and the last follow-up time was



**Figure 1** Case 1. (a) Prior to therapy, CT scan showed a left lung mass, multiple enlarged lymph nodes in both hilum and mediastinum and an enlarged right cervical lymph node (red arrow). (b) After four cycles of treatment, the CT scan showed that the curative effect reached CR. (c) At the last follow-up, CT scan showed that the curative effect was still CR. CT, computed tomography; CR, complete remission.

March 2020, and the efficacy evaluation still reached CR, as confirmed by the CT scan (Fig 1c). The PFS was more than 30 months, while the drug withdrawal time exceeded 20 months (Table 1).

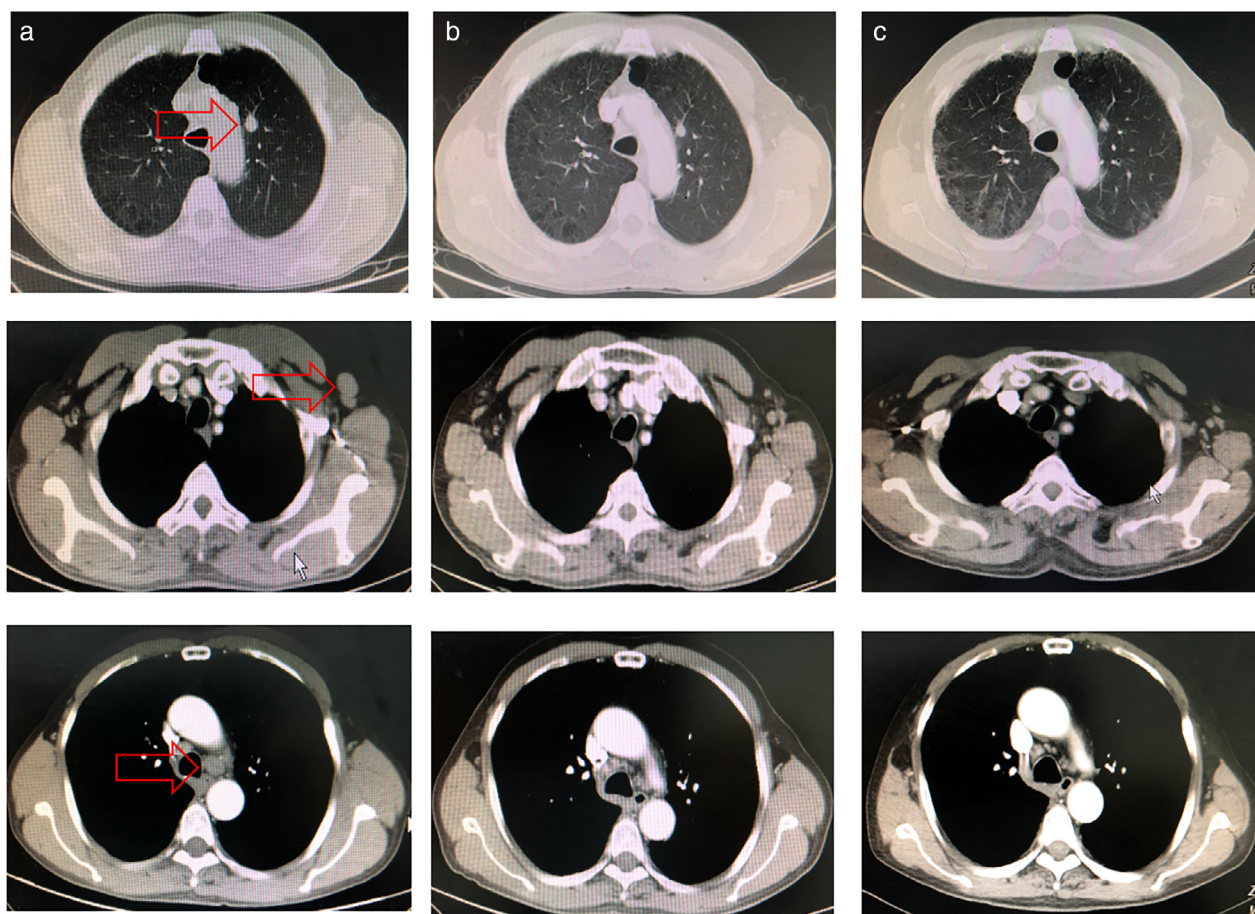
## Case 2

A 60-year-old man with a 40-year history of smoking was admitted to Shandong Cancer Hospital. A CT scan performed in December 2018 had shown left lung masses with left supraclavicular and mediastinal lymph node

enlargement (Fig 2a). A puncture biopsy had confirmed that the pathology of the tumor was adenocarcinoma. The expression of PD-L1 (SP142) was 3%–5%. The patient was diagnosed with left lung adenocarcinoma with left supraclavicular, hilar and mediastinal lymph node metastasis, cT1N3M1c, stage IVb. The results of gene detection showed that it was *EGFR* wild-type, and *ALK* rearrangement and *ROS1* gene fusion were both negative. After screening, the patient was enrolled in a phase III clinical trial and treated with sintilimab combined with pemetrexed plus carboplatin every three weeks. The patient commenced antineoplastic therapy in February 2019, and overall efficacy was evaluated as partial remission (PR) after four cycles (Fig 2b). After the end of the fifth cycle of treatment, the patient developed cardio- and skin toxicity. He was given symptomatic treatment, antitumor treatment was terminated, and the patient withdrew from the clinical trial and entered the follow-up observation stage. The last follow-up was November 2019, and as

**Table 1** Clinical information of patients during treatment

	Total cycles	Response	PFS (months)	Withdrawal time (months)
Case 1	10	CR	>30	>20
Case 2	5	PR	>9	>3



**Figure 2** Case 2. (a) Before treatment, the CT scan showed left lung masses with left supraclavicular and mediastinal lymph node enlargement (red arrow). (b) After four cycles of treatment, the CT scan showed that the curative effect reached PR. (c) At the last follow-up, CT scan showed that the curative effect was SD. CT, computed tomography; PR, partial remission; SD, stable disease.

shown in Fig 2c, the overall efficacy of the patient was evaluated as PR. The PFS of the patient was more than nine months and the withdrawal time was more than three months (Table 1).

## Discussion

The above two case reports demonstrate that early withdrawal of immunotherapy drugs due to adverse reactions might also benefit advanced lung adenocarcinoma patients with negative driver genes who have an early response to immunotherapy. The immunotherapy drugs involved in the case reports, camrelizumab and sintilimab, can bind to programmed cell death receptor-1 (PD-1) and block the interaction between PD-1 and its ligand to achieve an anti-tumor effect. Both drugs have been approved for the treatment of relapsed or refractory classical Hodgkin's lymphoma.<sup>17–19</sup>

In the CheckMate153 study (NCT02066636), patients with advanced NSCLC who responded effectively to nivolumab treatment were divided into a continuous medication group and interruption group. The results showed that the rates of PFS and OS in the continuous medication group were significantly higher than those in the interruption group. Through this study, it was found that nivolumab should be used continuously but not interrupted at will.<sup>20</sup> In addition, the CA209-003 study<sup>21</sup> showed that some pretreated advanced NSCLC patients could obtain long-term benefits from nivolumab treatment limited to two years, with an estimated five-year survival rate of 16%. Among the five-year survivors, the incidence of treatment-related adverse reactions was 68.8%. Treatment of four of five-year survivors were discontinued due to adverse reactions, including one within eight months of nivolumab treatment and three between 18 and 19 months after nivolumab treatment. The American Society for Clinical Oncology (ASCO) recommended permanent discontinuation of ICIs and intravenous injection of large doses of systemic steroids were recommended for patients with grade 3 and grade 4 immune-related adverse events (irAEs).<sup>22</sup> In the two cases reported here, immunotherapy was discontinued because of serious adverse events, but the patients continued to benefit after withdrawal. This made us consider the optimal duration of immunotherapy and the difference between forced and active withdrawal due to adverse reactions.

Cross-reactivity between tumor and normal tissue antigens, which leads to irAEs in immunotherapy, has been previously reported.<sup>23</sup> The relationship between the efficacy and toxicity of immunotherapy is interesting. A study<sup>24</sup> found that patients with advanced melanoma who had immune-related adverse events treated with anti-PD-1 had a higher response rate. In addition, the risk of irAEs in ICIs seemed

to be dose-dependent, but no cumulative toxicity of long-term exposure to anti-PD-1 was observed.<sup>25–27</sup> It has been previously reported that immunotherapy toxicity varies according to the type of tumor being treated, and in melanoma patients, vitiligo is more frequent during treatment.<sup>6</sup> Furthermore, one study<sup>28</sup> observed that the timing of immunotherapy patterns might affect irAEs and efficacy.

Long-term tumor response is a common feature in tumor histology. The persistence of this response has been explained by the theoretical basis that anti-PD-(L)-1 therapy could produce polyclonal and memory adaptive anti-tumor immunity, which could control the heterogeneity of the disease and reset the tumor-host immune interaction in response to cancer rejection.<sup>29,30</sup> In an exploratory study, 39 patients who responded effectively to immunotherapy discontinued immunotherapy without disease progression. Among them, nine cases stopped immunotherapy early due to adverse reactions, the rest stopped immunotherapy according to the regimen or because of prolonged effective time, and only 38% of the patients relapsed. It implied that patients could still achieve a lasting response after discontinuation of immunotherapy drugs due to irAEs or the termination of each clinical study.<sup>31</sup> Although the withdrawal time of Case 2 in our study was not as representative as that of Case 1, combined with the survival benefits of these two cases, to some extent, it might be possible to provide some experience on the optimal duration of anti-PD-1 treatment.

The long-term response to immunotherapy may be related to the duration of, or reaction to, treatment. Levra *et al.*<sup>32</sup> conducted a study of challenge immunotherapy after nivolumab therapy for advanced NSCLC in the real-world setting. The results indicated that patients with longer initial nivolumab treatment had a higher survival rate after retreatment. Another study<sup>31</sup> found that the duration of anti-PD-(L)-1 treatment less than 12 months was associated with a higher recurrence rate in patients who responded effectively to immunotherapy. The study<sup>31</sup> also revealed that there was a significant difference between complete and partial responders, with CR patients almost maintaining their response after discontinuation of treatment, while most stable disease (SD) or PR patients relapsed. Interestingly, these relapsed patients were again treated with immunotherapy, and some patients still achieved certain curative effects.

The treatment cycle of PD1/PD-L1 varied in the design of clinical studies on lung cancer. In the KEYNOTE 024 study,<sup>14</sup> the longest duration of pembrolizumab treatment was 35 cycles, and the study found that pembrolizumab monotherapy significantly prolonged overall survival of patients with PD-L1 proportion score  $\geq 50\%$ ,  $\geq 20\%$  or  $\geq 1\%$  compared with standard chemotherapy. The IMpower133 study<sup>16</sup> showed that standard chemotherapy

combined with atezolizumab could improve OS and PFS in patients with ES-SCLC. The duration of atezolizumab maintenance therapy in this study lasted until the disease progressed or there was no clinical benefit. In the Check-Mate078 study,<sup>15</sup> nivolumab, as a second-line treatment for advanced NSCLC, was used until the disease progressed, or discontinued because the patient was unable to tolerate it, and this study found that nivolumab improved OS compared with docetaxel.

A study<sup>33</sup> reported at the European Society for Medical Oncology (ESMO) Congress in 2019 found that patients who stopped taking immunotherapy drugs after one year of immunotherapy had a disease-free progression time of 266 days after withdrawal, suggesting that once PD-L1 treatment was effective, patients were able to maintain the benefit even after stopping the medication for a period of time. Interestingly, patients who responded effectively to PD-L1 relapsed after discontinuation of immunotherapy, and the reuse of immunotherapy could produce a secondary antitumor effect, achieving high disease control rate and lasting efficacy. Long-term use of immunotherapy is very expensive, and is certain to bring economic pressure on patients. If stopping immunotherapy for a certain period of time could also bring the same long-term treatment benefits, then early withdrawal of immunotherapy drugs is good news for patients. At present, such an optimal duration has not been found, and large-scale exploratory research is needed to solve this problem in the future.

In conclusion, the use of ICIs for advanced lung cancer was about two years, or until the disease progressed or patients became intolerant, which also meant that patients should take long-term drugs after choosing to use immunotherapy. However, the two cases reported here revealed that if immunotherapy is discontinued early due to adverse reactions, advanced lung adenocarcinoma patients with negative driver genes and early responses to immunotherapy might also benefit in the long term. This also reflected the theory that once immunotherapy has been shown to be effective, it remains effective for a long time. More clinical studies are needed to verify this finding in the future, and it is also important to screen the patients who can still benefit from early drug withdrawal for a long time.

## Disclosure

All the authors have no conflicts of interest to declare.

## Funding

This study was supported jointly by Special Funds for Taishan Scholars Project (grant no. tsqn201812149) and

Academic Promotion Programme of Shandong First Medical University (2019RC004).

## References

- 1 Brahmer J, Reckamp KL, Baas P *et al.* Nivolumab versus docetaxel in advanced squamous-cell non-small-cell lung cancer. *N Engl J Med* 2015; **373**: 123–35. <https://doi.org/10.1056/NEJMoa1504627>.
- 2 Herbst RS, Baas P, Kim DW *et al.* Pembrolizumab versus docetaxel for previously treated, PD-L1-positive, advanced non-small-cell lung cancer (KEYNOTE-010): A randomised controlled trial. *Lancet* 2016; **387**: 1540–50. [https://doi.org/10.1016/S0140-6736\(15\)01281-7](https://doi.org/10.1016/S0140-6736(15)01281-7).
- 3 Fehrenbacher L, Spira A, Ballinger M *et al.* Atezolizumab versus docetaxel for patients with previously treated non-small-cell lung cancer (POPLAR): A multicentre, open-label, phase 2 randomised controlled trial. *Lancet* 2016; **387**: 1837–46. [https://doi.org/10.1016/S0140-6736\(16\)00587-0](https://doi.org/10.1016/S0140-6736(16)00587-0).
- 4 Rittmeyer A, Barlesi F, Waterkamp D *et al.* Atezolizumab versus docetaxel in patients with previously treated non-small-cell lung cancer (OAK): A phase 3, open-label, multicentre randomised controlled trial. *Lancet* 2017; **389**: 255–65. [https://doi.org/10.1016/S0140-6736\(16\)32517-X](https://doi.org/10.1016/S0140-6736(16)32517-X).
- 5 Borghaei H, Paz-Ares L, Horn L *et al.* Nivolumab versus docetaxel in advanced nonsquamous non-small-cell lung cancer. *N Engl J Med* 2015; **373**: 1627–39. <https://doi.org/10.1056/NEJMoa1507643>.
- 6 Robert C, Long GV, Brady B *et al.* Nivolumab in previously untreated melanoma without BRAF mutation. *N Engl J Med* 2015; **372**: 320–30. <https://doi.org/10.1056/NEJMoa1412082>.
- 7 Motzer RJ, Escudier B, McDermott DF, *et al.* Nivolumab versus everolimus in advanced renal-cell carcinoma. *N Engl J Med* 2015; **373**: 1803–13. doi:<https://doi.org/10.1056/NEJMoa1510665>.
- 8 Ferris RL, Blumenschein G, Fayette J *et al.* Nivolumab for recurrent squamous-cell carcinoma of the head and neck. *N Engl J Med* 2016; **375**: 1856–67. <https://doi.org/10.1056/NEJMoa1602252>.
- 9 Ansell SM, Lesokhin AM, Borrello I *et al.* PD-1 blockade with nivolumab in relapsed or refractory Hodgkin's lymphoma. *N Engl J Med* 2015; **372**: 311–9. <https://doi.org/10.1056/NEJMoa1411087>.
- 10 Younes A, Santoro A, Shipp M *et al.* Nivolumab for classical Hodgkin's lymphoma after failure of both autologous stem-cell transplantation and brentuximab vedotin: A multicentre, multicohort, single-arm phase 2 trial. *Lancet Oncol* 2016; **17**: 1283–94. [https://doi.org/10.1016/S1470-2045\(16\)30167-X](https://doi.org/10.1016/S1470-2045(16)30167-X).
- 11 Le DT, Uram JN, Wang H *et al.* PD-1 blockade in tumors with mismatch-repair deficiency. *N Engl J Med* 2015; **372**: 2509–20. <https://doi.org/10.1056/NEJMoa1500596>.
- 12 Le DT, Durham JN, Smith KN *et al.* Mismatch repair deficiency predicts response of solid tumors to PD-1 blockade. *Science* 2017; **357**: 409–13. <https://doi.org/10.1126/science.aan6733>.

- 13 NCCN Clinical Practice Guidelines in Oncology: Non-Small Cell Lung Cancer. Version 3. 2020. [Cited 2 Nov 2020.]. Available from URL: <http://guide.medlive.cn/>
- 14 Mok TSK, Wu YL, Kudaba I *et al.* Pembrolizumab versus chemotherapy for previously untreated, PD-L1-expressing, locally advanced or metastatic non-small-cell lung cancer (KEYNOTE-042): A randomised, open-label, controlled, phase 3 trial. *Lancet* 2019; **393**: 1819–30. [https://doi.org/10.1016/S0140-6736\(18\)32409-7](https://doi.org/10.1016/S0140-6736(18)32409-7).
- 15 Wu YL, Lu S, Cheng Y *et al.* Nivolumab versus docetaxel in a predominantly Chinese patient population with previously treated advanced NSCLC: CheckMate 078 randomized phase III clinical trial. *J Thorac Oncol* 2019; **14**: 867–75. <https://doi.org/10.1016/j.jtho.2019.01.006>.
- 16 Mansfield AS, Kazarnowicz A, Karaseva N *et al.* Safety and patient-reported outcomes of atezolizumab, carboplatin, and etoposide in extensive-stage small-cell lung cancer (IMpower133): A randomized phase I/III trial. *Ann Oncol* 2020; **31**: 310–7. <https://doi.org/10.1016/j.annonc.2019.10.021>.
- 17 Mo H, Huang J, Xu J *et al.* Safety, anti-tumour activity, and pharmacokinetics of fixed-dose SHR-1210, an anti-PD-1 antibody in advanced solid tumours: A dose-escalation, phase 1 study. *Br J Cancer* 2018; **119**: 538–45. <https://doi.org/10.1038/s41416-018-0100-3>.
- 18 Markham A. Camrelizumab: First global approval. *Drugs* 2019; **79**: 1355–61. <https://doi.org/10.1007/s40265-019-01167-0>.
- 19 Hoy SM. Sintilimab: First global approval. *Drugs* 2019; **79**: 341–6. <https://doi.org/10.1007/s40265-019-1066-z>.
- 20 Spigel DR, McCleod M, Hussein MA *et al.* CheckMate 153: randomized results of continuous vs 1-year fixed duration nivolumab in patients with advanced non-small cell lung cancer. Oral presentation at: 42nd European Society for Medical Oncology (ESMO) Congress; 8–12 Sep 2017, Madrid, Spain, 1297O.
- 21 Gettinger S, Horn L, Jackman D *et al.* Five-year follow-up of Nivolumab in previously treated advanced non-small-cell lung cancer: Results from the CA209-003 study. *J Clin Oncol* 2018; **36** (17): 1675–84. <https://doi.org/10.1200/JCO.2017.77.0412>.
- 22 Sanchez K, Page DB. Immunotherapy toxicities. *Surg Oncol Clin N Am* 2019; **28**: 387–401. <https://doi.org/10.1016/j.soc.2019.02.009>.
- 23 Snyder A, Makarov V, Merghoub T *et al.* Genetic basis for clinical response to CTLA-4 blockade in melanoma. *N Engl J Med* 2014; **371** (23): 2189–99. [published correction appears in *N Engl J Med*. 2018 Nov 29;379(22):2185]. <https://doi.org/10.1056/NEJMoa1406498>.
- 24 Nanda VGY, Peng W, Hwu P *et al.* Melanoma and immunotherapy bridge 2015: Naples, Italy. 1–5 December 2015. *J Transl Med* 2016; **14** (1): 65. <https://doi.org/10.1186/s12967-016-0791-2>.
- 25 Topalian SL, Sznol M, McDermott DF *et al.* Survival, durable tumor remission, and long-term safety in patients with advanced melanoma receiving nivolumab. *J Clin Oncol* 2014; **32** (10): 1020–30. <https://doi.org/10.1200/JCO.2013.53.0105>.
- 26 Wolchok JD, Neyns B, Linette G *et al.* Ipilimumab monotherapy in patients with pretreated advanced melanoma: A randomised, double-blind, multicentre, phase 2, dose-ranging study. *Lancet Oncol* 2010; **11** (2): 155–64. [https://doi.org/10.1016/S1470-2045\(09\)70334-1](https://doi.org/10.1016/S1470-2045(09)70334-1).
- 27 Maker AV, Yang JC, Sherry RM *et al.* Inpatient dose escalation of anti-CTLA-4 antibody in patients with metastatic melanoma. *J Immunother* 2006; **29** (4): 455–63. <https://doi.org/10.1097/01.cji.0000208259.73167.58>.
- 28 Messenheimer DJ, Jensen SM, Afentoulis ME *et al.* Timing of PD-1 blockade is critical to effective combination immunotherapy with anti-OX40. *Clin Cancer Res* 2017; **23** (20): 6165–77. <https://doi.org/10.1158/1078-0432.CCR-16-2677>.
- 29 Anagnostou V, Smith KN, Forde PM *et al.* Evolution of neoantigen landscape during immune checkpoint blockade in non-small cell lung cancer. *Cancer Discov* 2017; **7**: 264–76. <https://doi.org/10.1158/2159-8290.CD-16-0828>.
- 30 Benci JL, Xu B, Qiu Y *et al.* Tumor interferon signaling regulates a multigenic resistance program to immune checkpoint blockade. *Cell* 2016; **167**: 1540–1554.e12. <https://doi.org/10.1016/j.cell.2016.11.022>.
- 31 Gauci ML, Lanoy E, Champiat S *et al.* Long-term survival in patients responding to anti-PD-1/PD-L1 therapy and disease outcome upon treatment discontinuation. *Clin Cancer Res* 2019; **25**: 946–56. <https://doi.org/10.1158/1078-0432.CCR-18-0793>.
- 32 Giaj Levra M, Cotté FE, Corre R *et al.* Immunotherapy rechallenge after nivolumab treatment in advanced non-small cell lung cancer in the real-world setting: A national data base analysis. *Lung Cancer* 2020; **140**: 99–106. <https://doi.org/10.1016/j.lungcan.2019.12.017>.
- 33 Sheth S, Gao C, Mueller N, Martinez P, Soria J. Durvalumab activity in previously treated patients who stopped durvalumab without disease progression. Oral presentation at: 44nd European Society for Medical Oncology (ESMO) Congress; 27 Sep–1 Oct, 2019; Fira Barcelona, Spain, 1175O.