

SCIENTIFIC REPORTS



OPEN

Experimental study on mandibular length and facial symmetry of low estrogen level and anterior disc displacement of temporomandibular joint

Zixian Jiao, Xiangyu Wang, Xiaohu Zhang & Chi Yang

This study was aimed at elucidating the changes of mandible symmetry in a rabbit model with low estrogen levels induced by ovariectomy (OVX) combined with temporomandibular joint (TMJ) anterior disc displacement without reduction (ADDWoR). 32 growing rabbits were randomly allocated into 4 groups; OVX group, ADDWoR group, OVX+ ADDWoR group and control group. In OVX and OVX+ ADDWoR groups, bilateral OVX was performed and then the serum level of 17β -estradiol was evaluated every week. In ADDWoR group and OVX+ ADDWoR group, the right TMJ was surgically opened and the disc was displaced anteriorly and the left TMJ was also surgically opened and closed without any manipulation of the disc. All rabbits had CT scan before and at the end of the study and the mandible measurements were performed on the 3D-reconstructed model. The mandible in ADDWoR group was consistently shorter on the right side resulting in a midline shift to the ipsilateral side. While in OVX+ ADDWoR group, the mandibular length of the right side was more shorter than in ADDWoR group, moreover, mandibular deviation was therefore more severe. In OVX group, there was no difference regarding the length of mandible compared to the control group. There was no difference regarding the mandibular length between left and right sides in the control group.

Anterior disc displacement (ADD) of the temporomandibular joint (TMJ) is one of the most common disorders of the maxillofacial region with a high prevalence in female adolescents. Based on different pathological changes, ADD can be divided into two types: ADD with reduction (ADDWR) and ADD without reduction (ADDWoR). It has been previously reported that unilateral ADDWoR in teenagers will lead to asymmetry of the condyle and mandible¹ and with the prolongation of the history, the mandible asymmetry will become more severe². The displaced TMJ disc might be reducing at an earlier stage, then progresses to non-reducing form later. TMJ DD is associated with altered condylar morphologies, such as decreased condylar height and distally inclined condyles. The altered condylar morphologies become more severe as TMJ DD progresses to nonreduction. Both qualitative and quantitative condylar changes are associated with TMJ DD. Osseous changes of the mandibular condyle is significantly influenced by TMJ DD and that altered condylar morphologies become more severe as TMJ DD progresses³. Furthermore, when ADDWoR is further developed, it will cause severe bone resorption, known as idiopathic condylar resorption (ICR). ICR is a well-documented however still unclearly identified disease. The typical clinical manifestations of ICR include mandibular retrusion, class II occlusal relationship, open bite of the anterior teeth, in addition to ADDWoR accompanied with a very small condyle evident on an MRI examination. ICR is a disease entity associated with a variety of factors including local factors, which produce compression such as internal derangement (ID) and systemic factors such as systemic arthritis and hyperparathyroidism. Due to the high occurrence of ICR in female adolescent patients, many scholars have assumed that the sex hormones might be related to ICR⁴. Evaluation of serum estrogen levels in ICR patients revealed a significant reduction of the 17β -estradiol level⁵. Whether it is the ADD or low serum estrogen level that plays a more important role in

Department of Oral Surgery, Shanghai Ninth People's Hospital, Shanghai Jiaotong University School of Medicine, Shanghai, 200011, China. Correspondence and requests for materials should be addressed to X.Z. (email: xiaohu1974@hotmail.com) or C.Y. (email: yangc_jzx@163.com)

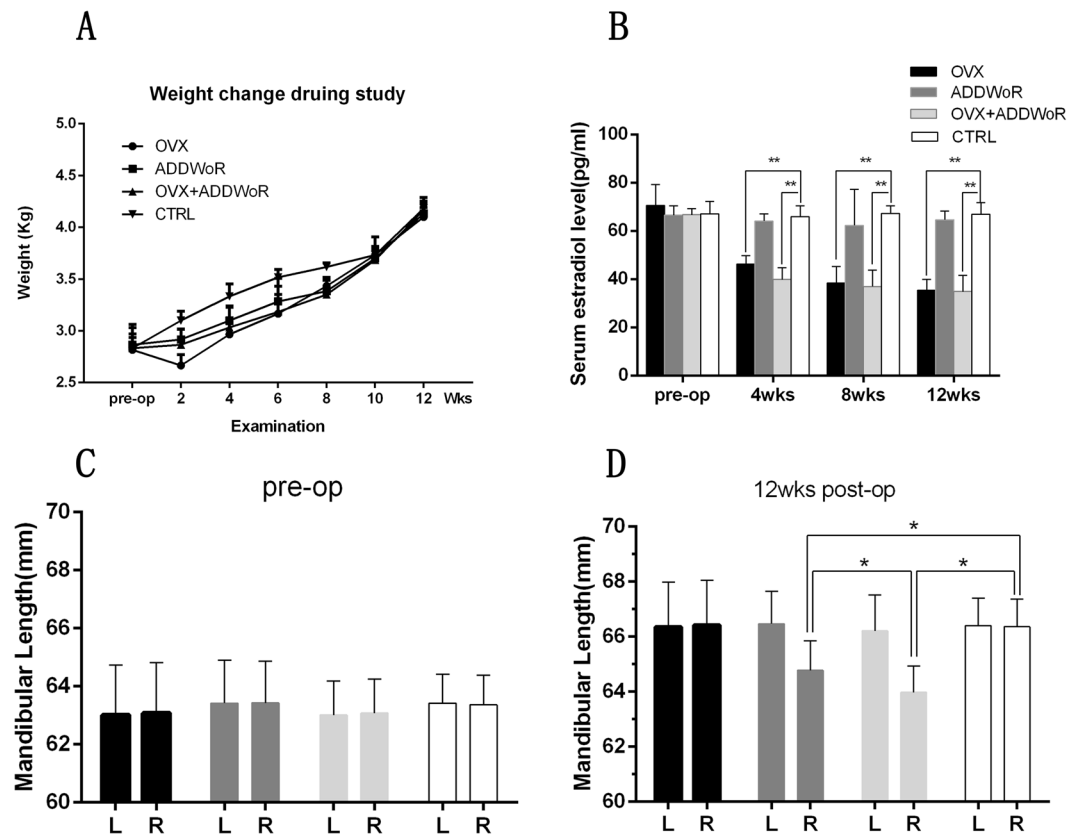


Figure 1. The changes of rabbits' body weight, serum estrogen level and mandible development throughout the study. **(A)** There was no significant difference of body weight between groups before and at the end of the study. **(B)** There was no significant difference of the serum estradiol level between groups at the beginning of the study. After OVX surgery, serum estradiol level in OVX and OVX+ ADDWoR group was significantly reduced compared to control group ($*p < 0.05$). No difference was found between ADDWoR group and control group. **(C)** No difference was found between groups of mandibular length before surgery. **(D)** There was significant difference ($*p < 0.05$) of mandibular length of right side between ADDWoR group and control group, and the mandibular length of right side in OVX+ ADDWoR group was significantly shorter than that of ADDWoR group.

the progression of ICR remains unclear and controversial. Thus, this study aimed at verifying the influence of a low serum estrogen level and ADDWoR on mandible length and asymmetry and discussing the probable initial cause of ICR.

Results

Changes in rabbit body weight throughout the experiment. The average body weight of 32 female New Zealand white rabbits before surgery was 2.84Kg (ranging from 2.5 to 3.2 Kg). As shown in Fig. 1A, statistical analysis was performed after randomization and no significant difference was found between the four groups ($p > 0.05$). 2 weeks postoperatively, the body weight of OVX group decreased slightly and then increased gradually till the end of the study, with the mean body weight increasing from 2.55 Kg (2 weeks) to 4.1 Kg (12 weeks). In the ADDWoR group and OVX+ ADDWoR group, almost no change of the body weight was found in the first 2 weeks, however, the mean body weight increased from 2.72 Kg (2 weeks) to 4.13 Kg (12 weeks) and 2.75 Kg (2 weeks) to 4.16 Kg (12 weeks), respectively. In the control group, the body weight increased steadily from 2.83 Kg (2 weeks) to 4.18 Kg (12 weeks). By the tenth week and beyond, there was no significant difference in body weight between the four groups ($p > 0.05$). No animal was lost during the study period.

Serum 17 β -estradiol assay. To verify whether the OVX model was created successfully, the serum 17- β -estradiol level was assessed at intervals. As shown in Fig. 1B, no significant difference was observed among the 4 groups before the operation of OVX. In OVX group and OVX+ ADDWoR group, the serum 17- β -estradiol level was significantly reduced ($p < 0.01$) from the 4th week till the end of the study, which means the model of OVX was successfully established. While in ADDWoR group, the 17 β -estradiol maintained at a steady level with no significant difference compared to the control group.

Mandibular length. All mandibles were well reconstructed with a smooth surface and the measurements were made directly on the 3D model. The mandibular length of all animals was measured and the results revealed

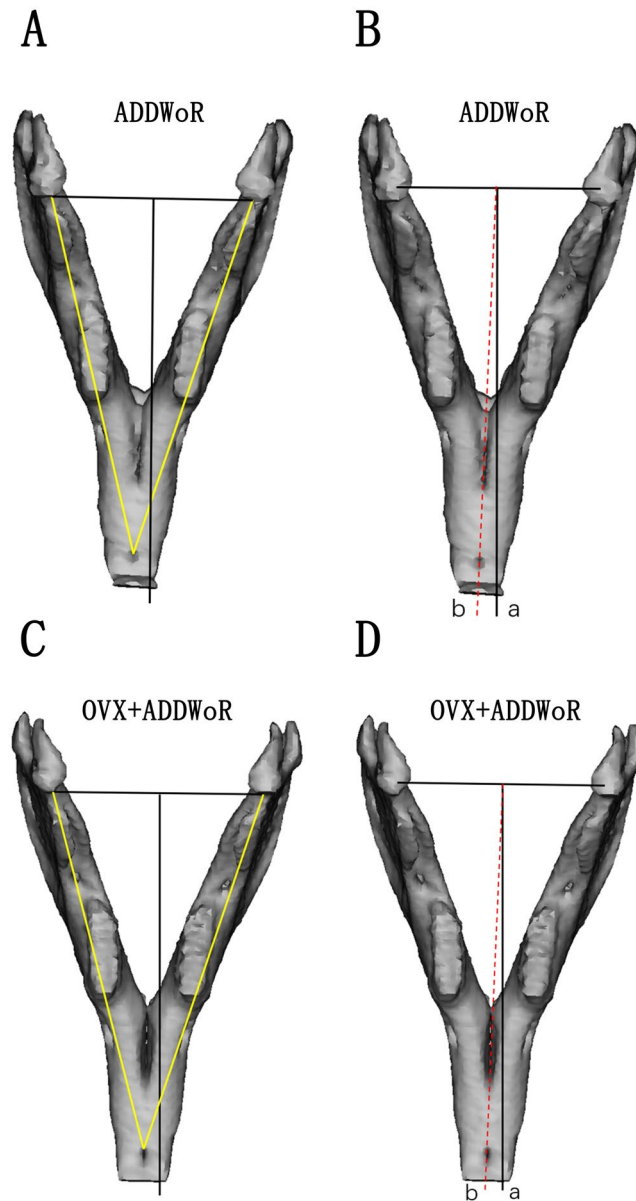


Figure 2. The mandibular length and midline asymmetry of the operated group. The mandibular length was considered as the distance from the end of jaw bone between the incisors to the anterior border of the condyle. The angle between line a and line b was identified as midline shift. (A,C) In ADDWoR and OVX+ ADDWoR group, the length of right mandible was significantly shorter than the left side. The length of right mandible in OVX+ ADDWoR group was even shorter than that in the ADDWoR group ($*p < 0.05$). (B,D) Mandible asymmetry was found both in ADDWoR and OVX+ ADDWoR group, the angle between line a and line b in OVX+ ADDWoR group was larger than that in the ADDWoR group ($*p < 0.05$).

good mandibular symmetry before surgery with no significant difference ($p > 0.05$) in mandibular length between the left and right sides (Fig. 1C), making the change of mandibular length between groups comparable. In control group, no difference was found between the left and right sides with a mandibular length of 66.41 mm and 66.36 mm, respectively, 3 months postoperatively. In OVX group, the mandibular length increased evenly, and the measurements revealed good facial symmetry with no significant difference of mandibular length between both sides ($p > 0.05$) and no difference was found between OVX group and the control group. While in ADDWoR group (Fig. 2A) and OVX+ ADDWoR group (Fig. 2C), the mandibular length of the right side was significantly shorter (Fig. 1D) than the left side ($p < 0.05$), and in the above two groups, no difference was observed in the mandibular length of the left side compared to control group. The mandibular length of the right side of OVX+ ADDWoR group was significantly shorter ($p < 0.05$) than that of ADDWoR group (Fig. 1D).

mandibular shift. The mandible in the control group and OVX group showed good symmetry with almost no midline shift. In ADDWoR and OVX+ ADDWoR group, the mandibular symphysis consistently shifted

toward the operated side (Fig. 2B,D). A statistically significant difference was found between ADDWoR group and control group ($p < 0.05$). The angles in the OVX+ ADDWoR group were larger than that in the ADDWoR group.

Discussion

Unilateral ADDWoR of the TMJ would impair condylar height, leading to facial asymmetry, which was verified both clinically and experimentally. In adolescent patients, ADDWoR was found to be accompanied with a decreased condylar height^{6,7} and with the prolongation of ADDWoR history, the condylar height tended to decrease more⁸. In animal models, an experimentally induced unilateral ADDWoR of the TMJ would impair the ipsilateral condylar growth^{9,10}. In the current study, the mandible growth of ADDWoR sides was also affected. In ADDWoR group, the mandibular length of right sides was significantly shorter than of the left sides, and the midline of the mandible was shifted towards the operated side, indicating that the ADDWoR animal model was built successfully. In OVX group, the mandible revealed good symmetry with no midline shift and no difference of mandibular length was found between OVX group and the control group. While in OVX+ ADDWoR group, the effects on mandibular growth were more severe, therefore, the mandibular length decreased more, and the midline was shifted more to the right side compared with ADDWoR group. The serum 17β -estradiol level in OVX group and OVX+ ADDWoR group was reduced by one-third, which mimicked the condition in young patients with a low serum estrogen level. Throughout this study, the animals' body weight gained gradually, and no difference was found among all groups at the end of the experiments, which can exclude the effect of malnutrition on mandibular growth. In this study, there was no difference of mandibular length between OVX group and the control group, indicating that although OVX was verified to influence the condylar cartilage proliferation and turnover in mice, OVX does not affect the development of the mandible, including mandibular length and facial symmetry.

Thus, the hypothesis of this study was that low levels of serum estrogen alone will not affect mandibular growth, while low levels of estrogen together with ADDWoR, will lead to more severe facial asymmetry compared to ADDWoR alone.

Since the association of estrogen deficiency and osteoporosis was first described by Fuller Albright¹¹, many studies has demonstrated that estrogen is the key regulator of bone metabolism¹². In human body, osteocytes have the ability to sense the mechanical strain and then developing microcracks, in addition to the response to hormonal changes such as estrogen deficiency. Also, osteocytes represent an important source of receptor activator of NF-kappaB ligand (RANKL)¹³, which is the key molecule needed for osteoclast formation and function¹⁴. Estrogen has direct effects on osteoclasts such as decreasing the activation of NF-kappaB and impairing RANKL-induced osteoclastogenesis¹⁵ and suppressing RANKL-induced osteoclast differentiation^{16,17}. Estrogen also induces osteoclast apoptosis, therefore, estrogen deficiency would lead to an increase in osteoclast lifespan due to reduced osteoclast apoptosis^{18,19}. Through 3D-finite elements analysis, the pressure on the condylar surface increased after ADDWoR, especially the posterior surface of the condylar head²⁰ and functional overloading, such as bruxism and prolonged clenching, may result in degenerative changes of the TMJ^{21,22}. Thus, we have reasons to believe that the increased mechanical overloading following ADDWoR might lead to microcracks of the cancellous bone of the condyle, resulting in an excessive osteoclast formation. Under normal circumstances, osteoclasts are eliminated through an estrogen induced osteoclast apoptosis and only causing mild facial asymmetry. While under the circumstances of low serum estrogen level, the inhibitory effect of estrogen on osteoclastogenesis was attenuated, and estrogen induced osteoclast apoptosis was also decreased, leading to severe facial asymmetry compared to ADDWoR. Ongoing further studies are advocated to demonstrate the possible mechanisms of osteoclasts in the development of ICR.

Materials and Methods

Animals. 32 3-month old female New Zealand rabbits were included in this study. These experiments were approved by the local ethics committee of Shanghai Jiao Tong University, School of Medicine and the guidelines for care and use of animals were followed. The rabbits were kept individually in cages and maintained on a "12-hour light/12-hour dark" cycle at room temperature with ad libitum access to water and a standard commercial rabbit chow.

After being acclimatized to the new conditions for 2 weeks, the rabbits were randomized into 4 groups: (1) Ovariectomy (OVX) group ($n = 8$): an experimental group in which OVX surgeries were performed combined with sham- ADDWoR operations of the TMJs. (2) ADDWoR group ($n = 8$): an experimental group in which ADDWoR of the TMJ was surgically created on the right side combined with sham-OVX operations. Sham-ADDWoR operations were performed on the left sides. (3) OVX+ ADDWoR group ($n = 8$): an experimental group in which ADDWoR of the TMJ was surgically created on the right side combined with the OVX surgery. sham- ADDWoR operations were performed on the left sides. (4) non-operated control group ($n = 8$). For the sham-OVX operation, the ovaries were held up and then returned to their original positions. For the sham-ADDWoR operation, the joint capsules were exposed without any manipulation of the TMJ disc.

All rabbits were 12 weeks old at the beginning of this study and were observed for 3 months, which is the rabbit's growing period, equivalent to the adolescent in human²³.

Computed Tomography scanning. All animals had computed tomography (CT) scanning under general anesthesia at the beginning of the study and again after sacrifice. CT scans were obtained using a GE Discovery Elite PET-CT(USA), with the parameters of 80 Kv, 120 Ma, and a thickness of 0.625 mm. Then the DICOM files were copied and imported into the mimics 19.0 software (Materialise, Belgium) and the rabbits' mandibles were 3D reconstructed for further analysis.

Weight gain. All experimental animals were weighed and recorded preoperatively. During the study period, the body weight of each individual animal was recorded every 2 weeks to detect signs of malnutrition that may affect the growth of the animal.

Surgery. *TMJ surgery.* Unilateral ADDWoR of the TMJ was created in each experimental animal as previously described²⁴. Briefly, after general anesthesia, a 4-cm anteroposterior incision was performed on the right TMJ from the skin overlying zygomatic arch to bone contact. Then a hole was drilled about 40 mm from the root of the zygomatic arch and a stain-less wire was pierced through to fix the two elastic bands. Following the exposure of the TMJ capsule, the anterior part of the disc was sutured and the suture was knotted to the elastic bands which was stretched to 14 mm to create a tension force of 1 N²⁴. When these procedures were completed, the wound was thoroughly irrigated by saline and closed in layers. The same procedure steps were performed for the ADDWoR sham-operated animals, except for the forward traction of the disc.

Antibiotics (penicillin, 0.1 g/kg/day, China) were administered 5 days after surgery to prevent postoperative infection of the tested animals.

OVX surgery. The OVX surgery was performed according to Pennypacker's method²⁵. Briefly, under general anesthesia, a 5-cm incision was made along the midline of the ventral abdomen extending caudally and ending 1 to 2 cm cranial to the pubis. The ovaries were exteriorized with caution, then the ovarian vessels and uterine tube were ligated and then the ovaries were removed. In the OVX sham-operated animals, the ovaries were exteriorized and returned again to its original position intact. The muscles and skin were sutured, and a light abdominal bandage was applied to protect the incision.

Antibiotics (penicillin, 0.1 g/kg/day, China) were administered 5 days after surgery to prevent postoperative infection.

Serum estrogen assay. At the beginning of this study, the serum 17 β -estradiol levels were measured for all rabbits at baseline. During the experiment process, blood samples were collected from each individual experimental animal to assess the serum level of 17 β -estradiol every 2 weeks. After centrifuge of the blood samples at 2000 \times g for 20 minutes, 2 ml serum sample was extracted from each blood sample and stored at -80°C for further analysis. 17 β -estradiol assessment was performed using an enzyme linked immunosorbent assay (ELISA), following the manufacturer's instructions (R&D System, Inc., Minneapolis, MN, USA)²⁶.

Mandible analysis. Following CT scan, the rabbits' DICOM files were imported into MIMICS 19.0 software (Materialise, Belgium) to reconstruct the 3D-model of the mandible. Thresholding was selected as min 326 and max 3071, then the mandible was separated from the skull and 3D-reconstructed. Each animal mandible was measured twice with an interval of 2 weeks.

mandibular length. The length of the mandible at each side was measured on the 3D model. The mandible length was considered as the distance from the end of the jaw bone between the lower incisors to the anterior border of the condyle²⁷.

Midline shift. The rabbit's facial symmetry was determined by the midline shift. The central point of each condyle was connected by a line and a perpendicular line was drawn from the midpoint to the frontal area of the mandible. Then another line was drawn from the midpoint of the inter-condyle line to the end of the jaw bone between the incisors. Then the angles between both lines were measured as illustrated in Fig. 2B⁹.

Statistical analysis. All data were expressed as the mean \pm SD. Results were analyzed with Analysis of Variance (ANOVA) using SPSS 13.0 software (SPSS Inc., USA). $P < 0.05$ indicated a significant difference between the groups.

Equipment and settings. Figures of statistical analysis including Fig. 1A–D were obtained using GraphPad Prism program version 6.01. Figure 2 showed mandibular growth and facial asymmetry, and CT scans were obtained using a GE Discovery Elite PET-CT(USA), with the parameters of 80Kv, 120 Ma, and a thickness 0.625 mm and 3D reconstructions were obtained using MIMICS 19.0 software (Materialise, Belgium).

References

- Xie, Q. *et al.* Will unilateral temporomandibular joint anterior disc displacement in teenagers lead to asymmetry of condyle and mandible? A longitudinal study. *Journal of crano-maxillo-facial surgery: official publication of the European Association for Cranio-Maxillo-Facial Surgery* **44**, 590–596, <https://doi.org/10.1016/j.jcms.2016.01.019> (2016).
- Xie, Q., Yang, C., He, D., Cai, X. & Ma, Z. Is mandibular asymmetry more frequent and severe with unilateral disc displacement? *Journal of crano-maxillo-facial surgery: official publication of the European Association for Cranio-Maxillo-Facial Surgery* **43**, 81–86, <https://doi.org/10.1016/j.jcms.2014.10.013> (2015).
- Ahn, S. J. *et al.* Relationships between temporomandibular joint disk displacements and condylar volume. *Oral Surgery Oral Medicine Oral Pathology & Oral Radiology* **125**, 192 (2018).
- Wolford, L. M. Idiopathic condylar resorption of the temporomandibular joint in teenage girls (cheerleaders syndrome). *Proceedings (Baylor University. Medical Center)* **14**, 246–252 (2001).
- Gunson, M. J. *et al.* Oral contraceptive pill use and abnormal menstrual cycles in women with severe condylar resorption: a case for low serum 17beta-estradiol as a major factor in progressive condylar resorption. *American journal of orthodontics and dentofacial orthopedics: official publication of the American Association of Orthodontists, its constituent societies, and the American Board of Orthodontics* **136**, 772–779, <https://doi.org/10.1016/j.ajodo.2009.07.011> (2009).
- Zhuo, Z., Cai, X. & Xie, Q. Is anterior disc displacement without reduction associated with temporomandibular joint condylar height in juvenile patients younger than 20 years? *Journal of oral and maxillofacial surgery: official journal of the American Association of Oral and Maxillofacial Surgeons* **73**, 843–849, <https://doi.org/10.1016/j.joms.2014.12.013> (2015).
- Cai, X. Y., Jin, J. M. & Yang, C. Changes in disc position, disc length, and condylar height in the temporomandibular joint with anterior disc displacement: a longitudinal retrospective magnetic resonance imaging study. *Journal of oral and maxillofacial surgery: official journal of the American Association of Oral and Maxillofacial Surgeons* **69**, e340–346, <https://doi.org/10.1016/j.joms.2011.02.038> (2011).

8. Hu, Y. K., Yang, C., Cai, X. Y. & Xie, Q. Y. Does condylar height decrease more in temporomandibular joint nonreducing disc displacement than reducing disc displacement?: A magnetic resonance imaging retrospective study. *Medicine* **95**, e4715, <https://doi.org/10.1097/MD.00000000000004715> (2016).
9. Legrell, P. E. & Isberg, A. Mandibular length and midline asymmetry after experimentally induced temporomandibular joint disk displacement in rabbits. *American journal of orthodontics and dentofacial orthopedics: official publication of the American Association of Orthodontists, its constituent societies, and the American Board of Orthodontics* **115**, 247–253 (1999).
10. Legrell, P. E. & Isberg, A. Mandibular height asymmetry following experimentally induced temporomandibular joint disk displacement in rabbits. *Oral surgery, oral medicine, oral pathology, oral radiology, and endodontics* **86**, 280–285 (1998).
11. Albright, F., Smith, P. H. & Richardson, A. M. Postmenopausal Osteoporosis. *British Journal of Hospital Medicine* **38**, 2465–2474 (1941).
12. Cauley, J. A. Estrogen and bone health in men and women. *Steroids* **99**, 11–15, <https://doi.org/10.1016/j.steroids.2014.12.010> (2015).
13. Nakashima, T. *et al.* Evidence for osteocyte regulation of bone homeostasis through RANKL expression. *Nature medicine* **17**, 1231–1234, <https://doi.org/10.1038/nm.2452> (2011).
14. Teitelbaum, S. L. Bone Resorption by Osteoclasts. *Science* **289**, 1504–1508, <https://doi.org/10.1126/science.289.5484.1504> (2000).
15. Robinson, L. J. *et al.* Estrogen inhibits RANKL-stimulated osteoclastic differentiation of human monocytes through estrogen and RANKL-regulated interaction of estrogen receptor- α with BCAR1 and Traf6. *Experimental cell research* **315**, 1287–1301, <https://doi.org/10.1016/j.yexcr.2009.01.014> (2009).
16. Shevde, N. K., Bendixen, A. C., Dienger, K. M. & Pike, J. W. Estrogens suppress RANK ligand-induced osteoclast differentiation via a stromal cell independent mechanism involving c-Jun repression. *Proceedings of the National Academy of Sciences of the United States of America* **97**, 7829–7834, <https://doi.org/10.1073/pnas.130200197> (2000).
17. Srivastava, S. *et al.* Estrogen decreases osteoclast formation by down-regulating receptor activator of NF- κ B ligand (RANKL)-induced JNK activation. *The Journal of biological chemistry* **276**, 8836–8840, <https://doi.org/10.1074/jbc.M010764200> (2001).
18. Garcia, A. J. *et al.* ER α signaling regulates MMP3 expression to induce FasL cleavage and osteoclast apoptosis. *Journal of bone and mineral research: the official journal of the American Society for Bone and Mineral Research* **28**, 283–290, <https://doi.org/10.1002/jbmr.1747> (2013).
19. Nakamura, T. *et al.* Estrogen prevents bone loss via estrogen receptor α and induction of Fas ligand in osteoclasts. *Cell* **130**, 811–823, <https://doi.org/10.1016/j.cell.2007.07.025> (2007).
20. Nishio, C. *et al.* Stress analysis in the mandibular condyle during prolonged clenching: a theoretical approach with the finite element method. *Proceedings of the Institution of Mechanical Engineers. Part H, Journal of engineering in medicine* **223**, 739–748, <https://doi.org/10.1243/09544119JEIM485> (2009).
21. Arnett, G. W., Milam, S. B. & Gottesman, L. Progressive mandibular retrusion-idiopathic condylar resorption. Part II. *American journal of orthodontics and dentofacial orthopedics: official publication of the American Association of Orthodontists, its constituent societies, and the American Board of Orthodontics* **110**, 117–127 (1996).
22. Perzer Del Palomar, A. & Doblare, M. Finite element analysis of the temporomandibular joint during lateral excursions of the mandible. *Journal of biomechanics* **39**, 2153–2163, <https://doi.org/10.1016/j.jbiomech.2005.06.020> (2006).
23. Bryndahl, F., Eriksson, L., Legrell, P. E. & Isberg, A. Bilateral TMJ disk displacement induces mandibular retrognathia. *Journal of dental research* **85**, 1118–1123, <https://doi.org/10.1177/154405910608501210> (2006).
24. Li, H. *et al.* Disc positions and condylar changes induced by different stretching forces in the model for anterior disc displacement of temporomandibular joint. *The Journal of craniofacial surgery* **25**, 2112–2116, <https://doi.org/10.1097/SCS.0000000000001065> (2014).
25. Pennypacker, B. L. *et al.* Cathepsin K inhibitors prevent bone loss in estrogen-deficient rabbits. *Journal of bone and mineral research: the official journal of the American Society for Bone and Mineral Research* **26**, 252–262, <https://doi.org/10.1002/jbmr.223> (2011).
26. Xia, L. U., He, H., Guo, H., Qing, Y. & He, C. Q. Effects of ultrasound on estradiol level, bone mineral density, bone biomechanics and matrix metalloproteinase-13 expression in ovariectomized rabbits. *Experimental and therapeutic medicine* **10**, 1429–1436, <https://doi.org/10.3892/etm.2015.2673> (2015).
27. Tuominen, M., Kantomaa, T. & Pirttiniemi, P. Effect of food consistency on the shape of the articular eminence and the mandible. An experimental study on the rabbit. *Acta odontologica Scandinavica* **51**, 65–72 (1993).

Acknowledgements

This study was supported by the Municipal hospital new frontier joint research project (SHDC12017101) and Shanghai professional technical service platform for diagnosis and treatment of temporomandibular joint disease and maxillofacial deformity (18DZ2291100). The funding sources had no role in the study design, collection, analysis, data interpretation, or the writing of the report.

Author Contributions

C.Y. and X.H.Z. designed most of the experiments. Z.X.J. and X.Y.W. were the primary person responsible for carrying out all experimental procedures. Z.X.J. and X.Y.W. performed animals' surgery. Z.X.J. and X.Y.W. contributes equally to this article. Z.X.J. analyzed the data and wrote the paper. X.H.Z. is one of the corresponding authors responsible for conception and design and critical revision of the article for important intellectual content. C.Y. is the person who made the final approval of the article.

Additional Information

Competing Interests: The authors declare no competing interests.

Publisher's note: Springer Nature remains neutral with regard to jurisdictional claims in published maps and institutional affiliations.



Open Access This article is licensed under a Creative Commons Attribution 4.0 International License, which permits use, sharing, adaptation, distribution and reproduction in any medium or format, as long as you give appropriate credit to the original author(s) and the source, provide a link to the Creative Commons license, and indicate if changes were made. The images or other third party material in this article are included in the article's Creative Commons license, unless indicated otherwise in a credit line to the material. If material is not included in the article's Creative Commons license and your intended use is not permitted by statutory regulation or exceeds the permitted use, you will need to obtain permission directly from the copyright holder. To view a copy of this license, visit <http://creativecommons.org/licenses/by/4.0/>.

© The Author(s) 2018