

Pinch-Off Syndrome, a Rare Complication of Totally Implantable Venous Access Device Implantation: A Case Series and Literature Review

Burak Mehmet Ilhan, M.D.¹, İsmail Cem Sormaz, M.D.¹, Rüştü Türkay, M.D.²

¹Department of General Surgery, Istanbul University, Istanbul Faculty of Medicine,

²Department of Radiology, Bakırköy Education and Research Hospital

Background: Pinch-off syndrome (POS) is a rare complication after totally implantable venous access device (TIVAD) implantation. In cancer patients, it is important to prevent this rare complication and to recognize it early if it does occur. We present a case series of POS after TIVAD implantation and the results of a literature search about this complication. **Methods:** From July 2006 to December 2015, 924 permanent implantable central venous catheter implantation procedures were performed. The most common indication was vascular access for chemotherapy. **Results:** POS occurred in 5 patients in our clinic. Two patients experienced POS within 2 weeks, and the other 3 patients were admitted to department of surgery, Istanbul Faculty of Medicine at 6 to 14 months following implantation. The catheters were found to be occluded during medication administration, and all patients complained of serious pain. The transected fragments of the catheters had migrated to the heart. They were successfully removed under angiography with a single-loop snare. **Conclusion:** POS is a serious complication after TIVAD implantation. It is important to be aware of this possibility and to make an early diagnosis in order to prevent complications such as drug extravasation and occlusion events.

Key words: 1. Totally implantable venous access device
2. Pinch off syndrome
3. Catheter fracture

Introduction

Venous device systems facilitate the safe administration of cytotoxic drugs, antibiotics, blood products, fluids, and parenteral nutrition, as well as the collection of blood samples. However, their use may be associated with several complications. Implantation of these devices is occasionally associated with immediate complications such as pneumothorax and arterial or venous injury, and late complications can include infections and catheter malfunction resulting

from venous thrombosis [1]. The right and left subclavian veins are the most common puncture sites. In the event of limited access to these veins, the cephalic, external jugular, brachial, and femoral veins can be used as other access points. Pinch-off syndrome (POS) occurs due to mechanical compression of the catheter between the clavicle and the first rib in subclavian vein catheterization [2,3].

In this study, 5 patients with POS after totally implantable venous access device (TIVAD) implantation via the right subclavian vein are presented, along

Received: February 8, 2018, Revised: July 31, 2018, Accepted: August 2, 2018, Published online: October 5, 2018

Corresponding author: Burak Mehmet Ilhan, Department of General Surgery, Istanbul Faculty of Medicine, Istanbul University, Millet Caddesi, 34093 Fatih, Istanbul, Turkey
(Tel) 90-212-414-2000 (Fax) 90-212-414-2222 (E-mail) burakmd@yahoo.com

© The Korean Society for Thoracic and Cardiovascular Surgery. 2018. All right reserved.

© This is an open access article distributed under the terms of the Creative Commons Attribution Non-Commercial License (<http://creativecommons.org/licenses/by-nc/4.0>) which permits unrestricted non-commercial use, distribution, and reproduction in any medium, provided the original work is properly cited.

Table 1. Primary diseases, number of cannulation attempts, and the interval before complications of cases

Serial no. of patients	Age (yr)	Primary disease	No. of puncture attempts	Localization of insertion	Localization of fractured part	Time to complication
1	66	Rectal cancer	4	Right SCV	Right atrium (Fig. 1)	2 wk
2	66	Breast cancer	3	Right SCV	Vena cava superior (Fig. 2)	3 wk
3	54	Breast cancer	1	Right SCV	Right ventricle (Fig. 3)	6 mo
4	61	Colon cancer	1	Right SCV	Right atrium (Fig. 4)	8 mo
5	52	Stomach cancer	2	Right SCV	Right ventricle (Fig. 5)	14 mo

SVC, subclavian vein.

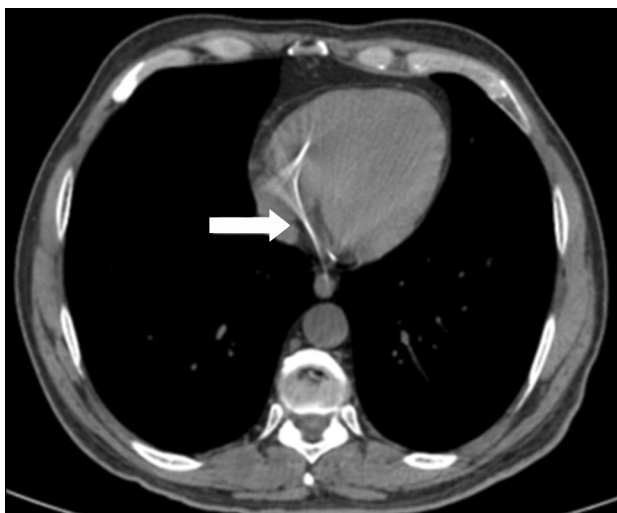

Fig. 1. Part of a fractured catheter is seen in the heart on a computed tomography scan (arrow).

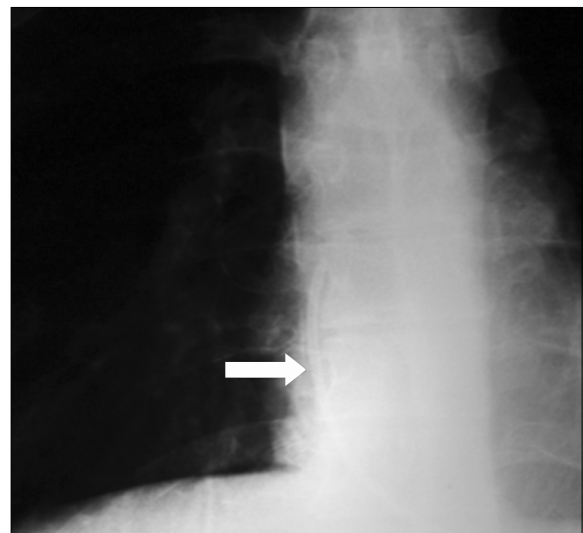


Fig. 2. Part of a fractured catheter is seen in the superior vena cava (X-ray imaging, arrow).

with a review of the relevant literature.

Methods

Between January 2006 and December 2015 at the Department of General Surgery, Istanbul Faculty of Medicine, Istanbul University, 924 TIVAD implantation procedures were performed to obtain vascular access for treatment. Two Port-a-Cath systems were used (Celsite, 8.5 F; B. Braun Medical Ltd., Sheffield, UK and SlimPort, 9.6 F; Bard Access Systems, Inc., Salt Lake City, UT, USA).

All procedures were initiated from the right subclavian vein under local anesthesia. If implantation was contraindicated or impossible on the right side due to lung or breast malignancies, the left subclavian vein was used. The permanent venous catheters were implanted using the Seldinger technique, between the clavicle and the first rib, into the sub-

clavian vein, with the cannula targeting the right atrium. After implantation, all patients underwent chest X-rays to check cannula placement and to rule out pneumothorax. All patients received prophylactic antibiotics and painkillers for a week.

Results

In this study, 5 patients experienced POS after a TIVAD was implanted because of their long-term medication needs. They ranged in age from 52 to 66 years old. All 5 patients were admitted to department of surgery, Istanbul Faculty of Medicine with symptoms of catheter occlusion or a complaint of shoulder pain. Their primary diseases, number of cannulation attempts, and the interval before complications occurred are shown in Table 1. Upon follow-up with X-ray or thoracic computed tomography (CT), catheter fracture was detected (Figs. 1-4).

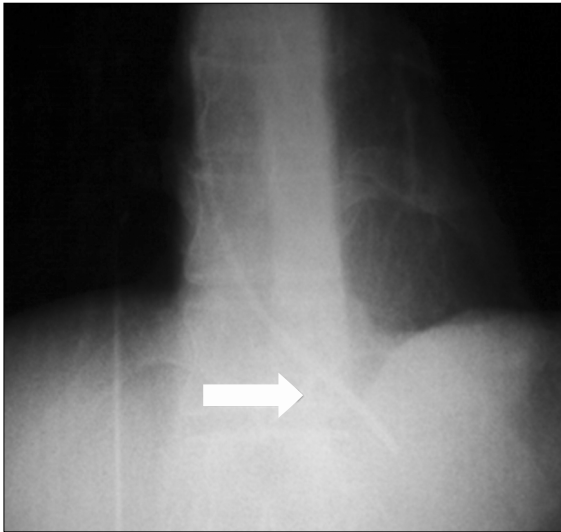


Fig. 3. Part of a fractured catheter that had migrated to the right ventricle (X-ray imaging, arrow).

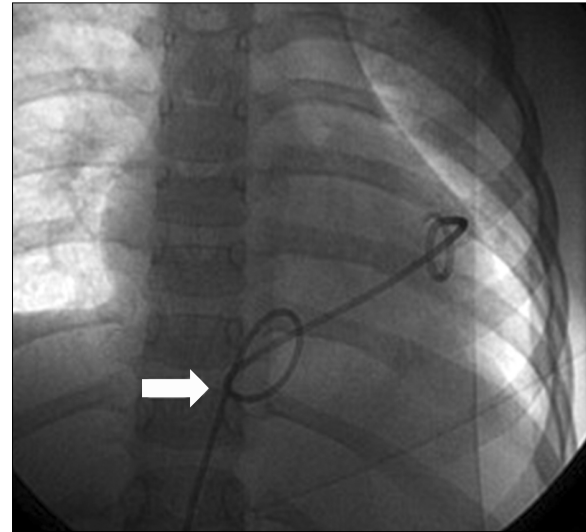


Fig. 5. Fractured part of a catheter removed under angiography from the right ventricle (arrow).

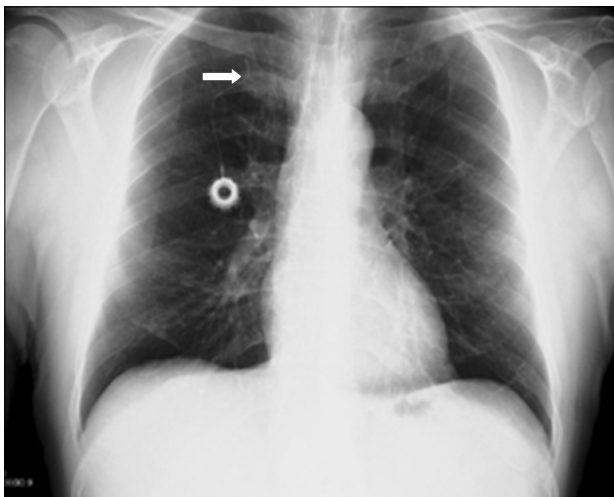


Fig. 4. Pinch-off syndrome due to chronic compression between the clavicle and the first rib (X-ray imaging, arrow).

Segments of the cannulas were situated in the right ventricle, atrium of the heart, or superior vena cava. The transected segments were successfully removed using a loop under angiography (Fig. 5), and the remaining parts of the catheters were also surgically removed from the body.

1) Follow-up

TIVAD insertion procedures were re-performed from the left side in all cases, and no further complications occurred during follow-up. The TIVADs were

re-implanted after a healing period, and the patients received their medication without any problems.

2) Literature review

The literature review was performed using the Medline and SCOPUS databases. “Venous access device” and “POS” were used as keywords for the literature search. The initial search resulted in 12 studies about POS or complications of TIVAD.

The most common sites of catheter fragment embolization were found to be the pulmonary artery (35%), right atrium (27.6%), right ventricle (22%), and superior vena cava or peripheral veins (15.4%).

In a study involving 215 cases of catheter fracture and embolization, the clinical signs were catheter malfunction (56.3%), arrhythmias (13%), pulmonary symptoms (4.7%), and sepsis (1.8%), but 24.2% of cases were asymptomatic [3].

POS is a serious complication of TIVAD implantation. The main cause of catheter transection is POS caused by chronic compression of the connective tissue surrounding the subclavian vein between the clavicle and the first rib. In most cases, the tip of the catheter is discovered in the heart cavities or pulmonary artery. The frequency of POS has been reported as 1% in the literature [3]. The rate was 0.5% in our study.

Most catheter fragments are extracted using percutaneous intervention techniques through the femoral

vein. Other systems involve multiple loops, such as the EN Snare endovascular loop system (Endovascular Snare System; Merit Medical Systems, South Jordan UT, USA), which is designed with 3 intertwined loops (made of nitinol, which confers resistance to folding and torque control) to extract foreign objects from the body and to manipulate them within the body, with a variety of sizes, ranging from 2 to 45 mm.

Twelve studies were analyzed in the final literature review, including 7 reviews, 3 randomized control trials, 1 case series, and 1 case report.

Discussion

If long-term treatment such as chemotherapy is necessary, permanent implantable venous catheters are safe and more comfortable than regular venous cannulation. However, this procedure has some potential complications, such as infection, hematoma, pneumothorax, catheter embolization, and POS [3].

Intermittent compression of the catheter between the clavicle and the first rib, defined as POS, may lead to catheter obstruction and fracture. Hinke et al. [4] described 4 radiographic grades of this complication: (1) grade 0, no narrowing in the catheter's course; (2) grade 1, no luminal catheter narrowing, but deviation; (3) grade 2, luminal narrowing as the catheter passes under the clavicle (true pinch-off sign); and (4) grade 3, catheter transection.

POS can be detected in up to 1.0%–1.5% of patients after all central venous catheter implantations, and catheter dislodgement can occur in 40% of those patients [5]. To avoid POS, theoretically, a catheter must be inserted into the subclavian vein as laterally as possible [6]. In our series, POS developed in 5 of the 924 patients and radiologic evaluation revealed grade 3 POS.

Patients with POS generally present with serious pain and/or catheter obstruction. Less common symptoms include cardiac palpitations and chest or abdominal pain [7]. The occurrence of POS can occur from as early as the time of insertion to weeks, months, or years later [8]. Our patients were admitted with catheter occlusion and serious shoulder pain from 2 weeks to 14 months after implantation.

In patients with POS, thoracotomy or other surgical interventions would seriously increase morbidity and mortality. The percutaneous transvenous ap-

proach is the safest method to remove intravascular foreign bodies; it has a high success rate and has become the technique of choice since it was first described by Thomas and colleagues [7-11]. In our patients, the transected segment was successfully removed using a loop under angiography and the remaining part of the catheter was also removed to avoid serious embolisms. Both procedures were performed under intensive care unit conditions, and preparations were made for surgery in case of an emergency.

The use of ultrasound when inserting a venous catheter into the subclavian vein was shown to have a higher success rate with fewer complications than the landmark method in a population of patients who were critically ill [12], but ultrasound-guided puncture is not possible at many centers. A previous study used CT to reveal that the ultrasonography-guided technique tended to result in a more lateral subclavian vein approach than the landmark technique ($p < 0.001$), with a lower risk of POS or pneumothorax than when the landmark venipuncture technique was used [13].

In conclusion, central venous catheters are useful for patients who require long-term treatment, but complications may arise as a result of this procedure. POS should not be overlooked as a possible complication.

Conflict of interest

No potential conflict of interest relevant to this article was reported.

References

1. Vescia S, Baumgartner AK, Jacobs VR, et al. *Management of venous port systems in oncology: a review of current evidence*. Ann Oncol 2008;19:9-15.
2. El Hammoumi M, El Ouazni M, Arsalane A, El Oueriachi F, Mansouri H, Kabiri el H. *Incidents and complications of permanent venous central access systems: a series of 1,460 cases*. Korean J Thorac Cardiovasc Surg 2014;47: 117-23.
3. Bow EJ, Kilpatrick MG, Clinch JJ. *Totally implantable venous access ports systems for patients receiving chemotherapy for solid tissue malignancies: a randomized controlled clinical trial examining the safety, efficacy, costs, and impact on quality of life*. J Clin Oncol 1999;17:1267.
4. Hinke DH, Zandt-Stastny DA, Goodman LR, Quebbeman EJ,

- Krzywda EA, Andris DA. *Pinch-off syndrome: a complication of implantable subclavian venous access devices*. Radiology 1990;177:353-6.
5. Fazeny-Dorner B, Wenzel C, Berzlanovich A, et al. *Central venous catheter pinch-off and fracture: recognition, prevention and management*. Bone Marrow Transplant 2003; 31:927-30.
 6. Magney JE, Flynn DM, Parsons JA, et al. *Anatomical mechanisms explaining damage to pacemaker leads, defibrillator leads, and failure of central venous catheters adjacent to the sternoclavicular joint*. Pacing Clin Electrophysiol 1993;16(3 Pt 1):445-57.
 7. Mirza B, Vanek VW, Kupensky DT. *Pinch-off syndrome: case report and collective review of the literature*. Am Surg 2004;70:635-44.
 8. Cho JB, Park IY, Sung KY, Baek JM, Lee JH, Lee DS. *Pinch-off syndrome*. J Korean Surg Soc 2013;85:139-44.
 9. Bessoud B, de Baere T, Kuoch V, et al. *Experience at a single institution with endovascular treatment of mechanical complications caused by implanted central venous access devices in pediatric and adult patients*. AJR Am J Roentgenol 2003;180:527-32.
 10. Fisher RG, Ferreyro R. *Evaluation of current techniques for nonsurgical removal of intravascular iatrogenic foreign bodies*. AJR Am J Roentgenol 1978;130:541-8.
 11. Gabelmann A, Kramer S, Gorich J. *Percutaneous retrieval of lost or misplaced intravascular objects*. AJR Am J Roentgenol 2001;176:1509-13.
 12. Fragou M, Gravvanis A, Dimitriou V, et al. *Real-time ultrasound-guided subclavian vein cannulation versus the landmark method in critical care patients: a prospective randomized study*. Crit Care Med 2011;39:1607-12.
 13. Tamura A, Sone M, Ehara S, et al. *Is ultrasound-guided central venous port placement effective to avoid pinch-off syndrome?* J Vasc Access 2014;15:311-6.