

This article is licensed under the Creative Commons Attribution-NonCommercial 4.0 International License (CC BY-NC) (<http://www.karger.com/Services/OpenAccessLicense>). Usage and distribution for commercial purposes requires written permission.

Case Report

Case Report of a Family Affected by Stickler Syndrome in Which Rhegmatogenous Retinal Detachment Occurred in Five Eyes of Three Siblings

Daisaku Kimura^{a, b} Takaki Sato^a Shou Oosuka^a Ryohsuke Kohmoto^a
Masanori Fukumoto^a Masashi Mimura^a Kensuke Tajiri^a
Takatoshi Kobayashi^a Teruyo Kida^a Tsunehiko Ikeda^a

^aDepartment of Ophthalmology, Osaka Medical College, Takatsuki-City, Japan;

^bDepartment of Ophthalmology, Takatsuki Red Cross Hospital, Takatsuki-City, Japan

Keywords

Stickler syndrome · Rhegmatogenous retinal detachment · Vitreous surgery · Scleral buckling procedure · Prophylactic treatment

Abstract

Purpose: Stickler syndrome is an autosomal dominant inherited disorder that is well known to be highly associated with the development of rhegmatogenous retinal detachment. In this study, we report the case of a family affected by Stickler syndrome in which rhegmatogenous retinal detachment developed in 5 eyes of 3 siblings. **Case Series:** For treatment, we performed vitreous surgery on 1 eye of the eldest son, and bilateral scleral buckling surgery on the 2 younger children. A good postoperative outcome was obtained on the 4 eyes that underwent scleral buckling surgery, yet the prognosis was poor on the 1 eye that underwent vitrectomy due to redetachment of the retina and corneal complication. Since vitreous surgery was quite difficult due to strong vitreoretinal adhesion, we created an artificial posterior vitreous detachment via the bimanual technique combined with encircling. For the scleral buckling surgery, broad scleral extrusion was needed to seal multiple retinal breaks. **Conclu-**

sions: The findings of this study showed a high prevalence of rhegmatogenous retinal detachment in a single family with Stickler syndrome. In these cases, scleral buckling surgery was effective for treating the detached retina, and some prophylactic treatment, such as laser photocoagulation to prevent the occurrence of rhegmatogenous retinal detachment, should be considered for such cases in the future.

© 2018 The Author(s)
Published by S. Karger AG, Basel

Introduction

First reported by Stickler et al. [1] in 1965, Stickler syndrome is an autosomal dominant inherited genetic disorder that causes abnormalities in connective tissues of the human body. Due to a mutation in the type II procollagen (COL2A1) gene, the locus is on the long arm of chromosome 12. Due to abundant expression of type II collagen in cartilage and vitreous gel, it causes characteristic joint symptoms and ocular symptoms [2]. In regard to the prevalence of this disorder, it reportedly affects approximately 1 in every 10,000 persons [3]. Ocular findings of Stickler syndrome include severe and progressive myopia, vitreous liquefaction and degeneration, and retinal breaks and detachment [4–6]. Previous studies have reported a high risk of rhegmatogenous retinal detachment in this syndrome [5–8]. The purpose of this present study was to report Stickler syndrome in one family in which rhegmatogenous retinal detachment developed in 5 eyes of 3 siblings.

Case Series

Case 1 (Eldest Son)

Case 1 involved a 22-year-old male who had undergone cleft palate surgery at the age of 1. In addition, his past history indicated a mild hearing loss, yet no joint degeneration. At the age of 12, a bullous rhegmatogenous retinal detachment developed from the upper to temporal quadrants of his left eye. In both eyes, we observed an avascular zone of the peripheral retina, remarkable vitreous liquefaction and membranous vitreous degeneration behind the crystalline lens as well as irregular multiple retinal tears in the peripheral portion of the upper to temporal quadrants of his left eye. Visual acuity (VA) was 0.05 (0.7 × –13 dpt) OD and 0.05 (noncorrigible) OS. We diagnosed this patient as having rhegmatogenous retinal detachment due to Stickler syndrome based on his history of a cleft palate as well as on the fact that there had been 2 previous cases of retinal detachment in his family history (i.e., his mother and his uncle).

For treatment, we performed pars plana vitrectomy and lensectomy on his left eye. The thickened posterior vitreous membrane adhered firmly to the retina from the mid-periphery toward the periphery and artificial posterior vitreous detachment was created via the bimanual technique. However, a number of iatrogenic retinal breaks occurred in the peripheral area. Pneumatic retinal replacement, endophotocoagulation, encircling buckling (#506 silicone sponge), and silicone oil tamponade were performed. The silicone oil was removed at 6 months after the initial operation; however, retinal redetachment occurred. Thus, we once again surgically treated the eye with a silicone oil tamponade. At present, the retina is almost attached under silicone oil. However, optic atrophy and corneal opacity occurred, and his VA decreased to light perception.

At the age of 20, the patient's right eye also developed bullous rhegmatogenous retinal detachment (Fig. 1a). A giant retinal tear of approximately 90° was observed from the nasal

to the lower quadrants of the fundus, and the retina was almost completely detached, except for the temporal-inferior side. The vitreous was remarkably liquefied and the upper retinal detachment was bullous. Vitreous surgery could be considered as one of the choices; however, since the prognosis of the left eye after vitreous surgery was poor, scleral buckling surgery was chosen as the initial treatment. The surgery was performed via the D-ACE sequence method, in which transscleral drainage of subretinal fluid and intravitreal 20% sulfur hexafluoride (SF₆) injection were performed. Next, transscleral cryocoagulation was performed around the retinal breaks and a #506 silicone sponge was used to perform an encircling buckling. Postoperatively, the retina was attached, and the corrected VA improved from 0.01 to 0.6 (Fig. 1b).

Case 2 (Second-Eldest Son)

Case 2 involved a 19-year-old male. His past history indicated a mild hearing loss and mild scoliosis, yet no cleft palate or joint degeneration. At 11 years, rhegmatogenous retinal detachment occurred in his right eye, and multiple retinal breaks were observed in the temporal peripheral area. Liquefaction and membranous vitreous degeneration were remarkable, and two quadrants on the temporal side had bullous retinal detachment (Fig. 2a). Perivascular retinal degeneration was also observed at the temporal mid-periphery. His VA was 0.04 (0.4 × sph – 8.0 = cyl – 1.5 axis 40°) OD and 0.04 (1.0 × sph – 7.0 = cyl – 1.75 axis 180°) OS. For treatment, scleral buckling surgery was performed, including transscleral cryocoagulation around the retinal breaks, followed by encircling with a #506 silicone sponge. Since the temporal retinal breaks were located on the slope of the buckle, a #501 silicone sponge was added circumferentially to the posterior pole side, approximately half-way around the temporal quadrants. Subretinal fluid drainage was performed at the temporal side, and a gas tamponade by 20% SF₆ was performed. Following surgery, the retina was attached and the corrected VA improved to 0.9 (Fig. 2b).

At the age of 13, the patient's left eye also developed rhegmatogenous retinal detachment. A large oral dialysis of approximately 70° was observed on the lower nasal side, and other small retinal breaks frequently occurred. The retinal detachment was from the nasal side to the lower two quadrants, but did not involve the macula. A thick vitreous veil was observed in the vitreous cavity. For treatment, scleral buckling was first performed, including transscleral cryocoagulation around the retinal breaks and oral dialysis, followed by encircling with a #506 silicone sponge and subretinal fluid drainage. A circumferential #501 silicone sponge was added in the nasal posterior pole in the same manner as performed on the right eye. Next, 1.0 ml of air was injected into the vitreous cavity. Following surgery, the retina was attached, and the corrected VA was maintained at 1.0.

Case 3 (Third-Eldest Son)

Case 3 involved a 17-year-old male who had undergone surgery for a cleft palate at the age of 1. Hearing loss and joint degeneration were not observed. At the age of 11, rhegmatogenous retinal detachment developed in his right eye. Bullous retinal detachment was observed from the upper temporal side to the lower side, and multiple slit-shaped retinal breaks were observed at the middle of the upper temporal area. An oval-shaped retinal hole had also formed in the lower part (Fig. 3a). Liquefaction and membranous vitreous degeneration were also observed. The patient's VA was 0.04 (0.15 × sph – 5.25 = cyl – 1.75 axis 180°) OD and 0.04 (0.7 × sph – 8.00 = cyl – 2.25 axis 180°) OS. After performing scleral buckling surgery, including transscleral cryopexy and subretinal fluid drainage, encircling with a #506 silicone sponge and a circumferential #501 silicone sponge was further placed

in parallel at the posterior pole from the temporal to upper side. Then, 1.0 ml of 20% SF₆ was injected into the vitreous cavity. Following surgery, his retina was attached, yet 2 years later, downward localized redetachment occurred and epiretinal membrane formation in the macular also developed and the corrected VA decreased to 0.4 (Fig. 3b). Thus, reoperation via vitreous surgery was performed. With the crystalline lens preserved, the vitreous gel was excised as near as possible to the periphery, and after peeling off the epiretinal membrane, pneumatic retinal replacement, endophotocoagulation, and gas tamponade with 20% SF₆ were performed. Following surgery, the retina was attached and the corrected VA improved to 0.7.

Discussion

The systemic symptoms of Stickler syndrome include hearing loss, a cleft palate, epiphyseal dysplasia, and degeneration, similar to arthritis [1]. Stickler syndrome is one of the vitreoretinal dystrophies that often complicates with rhegmatogenous retinal detachment [4–6]. The most important differential diagnosis includes Wagner disease, which is very similar to Stickler syndrome in regard to ocular findings. However, Wagner disease involves lack of systemic features such as flat nose, hearing loss, and joint degeneration. Familial exudative vitreoretinopathy is another important differential diagnosis, yet the dragged retina is not so popular in Stickler syndrome.

As described above, the cause of Stickler syndrome is considered to be abnormality of the collagen gene. However, in recent years, it has been classified as three types, based on the phenotype of the eye [9, 10]. Type I is accompanied by a vitreous membrane-like structure, type II is accompanied by a vitreous bead-like structure, and type III is not associated with ocular findings. In this current case series, we did not investigate the gene diagnosis; however, all 3 cases were considered to be type I due to the presence of a vitreous membrane-like structure.

It has been reported that in Stickler syndrome cases with the group of symptoms described above, the disorder is complicated with a high rate of rhegmatogenous retinal detachment [4–8]. In cases of rhegmatogenous retinal detachment associated with Stickler syndrome, there is a high degree of vitreous liquefaction and degeneration, so retinal detachment progresses faster with advancing age [6]. Moreover, since the vitreoretinal adhesion is highly advanced, there are many cases that are difficult to treat by scleral buckling surgery. The taut posterior vitreous membrane is firmly adhered to the retina over a wide range, thus making it extremely difficult to create an artificial posterior vitreous detachment, as in the case described above. In the previous study by Abeysiri et al. [11], the success rate of surgeries for rhegmatogenous retinal detachment associated with Stickler syndrome was found to be 84.2% for vitreous surgery, yet only 66.7% for scleral buckling surgery, thus illustrating the usefulness of vitreous surgery. However, even when vitreous surgery was performed, since the adhesion between the retina and the vitreous was extremely strong, the difficulty of performing vitreous surgery was quite high. In the left eye of case 1 in this study, making the artificial posterior vitreous detachment was extremely difficult and numerous iatrogenic retinal breaks occurred. Thus, it is preferable to create an artificial posterior vitreous detachment as near as possible to the periphery by using a bimanual technique, and if the vitreous gel remains, a peripheral encircling is also used to improve the reattachment rate, as this method is considered to be effective.

However, in the left eye in case 1, detachment reoccurred after the removal of the silicone oil and good VA ultimately could not be obtained. Based on our experience, we chose scleral buckling surgery as the initial surgical procedure for these 3 cases, including the right eye of case 1. Fortunately, since most of the retinal breaks were located on the peripheral side as opposed to the middle region, closure of the retinal breaks was successfully obtained by encircling using a #506 silicone sponge and partly adding a circumferential #501 silicone sponge to the subsequent pole. In case 3, the right-eye redetachment occurred at a late stage after scleral buckling surgery and after undergoing vitreous surgery, yet it was relatively easy to treat by removing the vitreous gel from the buckle protrusion.

Our findings in this case series study illustrate the necessity of performing prophylactic laser photocoagulation to prevent the occurrence of rhegmatogenous retinal detachment [12–14]. Leiba et al. [12] reported performing 360-degree prophylactic laser photocoagulation at the boundary between the healthy retinal region and the degenerated retinal region in 9 cases of Stickler syndrome with strong retinal vitreous degeneration. During the 1- to 15-year retrospective observation period in that study, rhegmatogenous retinal detachment reportedly occurred only in 1 eye, and the onset of retinal detachment was at a site unrelated to the prophylactic laser photocoagulation. If we had performed prophylactic laser photocoagulation over the entire circumference, similar to the method reported by Leiba et al. [12], we theorize that the development of retinal detachment could have been prevented in 5 of the 6 eyes in our 3 cases. However, since the 3 patients in this present study were of somewhat younger age to undergo laser photocoagulation, it was difficult to obtain permission to perform a wide range of laser photocoagulation. Moreover, fundus examinations in these 3 cases revealed no lesions, such as obvious retinal lattice degenerations. Based on these observations, we chose to follow the patients instead of administering any treatment. In the future, prophylactic treatments, such as laser photocoagulation and/or transconjunctival cryopexy, should probably be considered in such cases, even when performing the surgery under general anesthesia is necessary.

Acknowledgements

The authors wish to thank John Bush for editing the manuscript.

Statement of Ethics

This study was approved by the Ethics Committee of Osaka Medical College.

Disclosure Statement

There are no conflicts of interest to report for all authors.

References

- 1 Stickler GB, Belau PG, Farrell FJ, Jones JD, Pugh DG, Steinberg AG, Ward LE: Hereditary progressive arthro-ophthalmopathy. *Mayo Clinic Proc* 1965;40:433–455.
- 2 Francomano CA, Liberfarb RM, Hirose T, Maumenee IH, Streeten EA, Meyers DA, Pyeritz RE: The Stickler syndrome: evidence for close linkage to the structural gene for type II collagen. *Genomics* 1987;1:293–296.
- 3 Ahmad NN, Dimascio J, Knowlton RG, Tasman WS: Stickler syndrome. A mutation in the nonhelical 3' end of type II procollagen gene. *Arch Ophthalmol* 1995;113:1454–1457.
- 4 Donoso LA, Edwards AO, Frost AT, Ritter R 3rd, Ahmad N, Vrabec T, Rogers J, Meyer D, Parma S: Clinical variability of Stickler syndrome: role of exon 2 of the collagen COL2A1 gene. *Surv Ophthalmol* 2003;48:191–203.
- 5 Huang F, Kuo HK, Hsieh CH, Lai JP, Chen PK: Visual complications of Stickler syndrome in paediatric patients with Robin sequence. *J Craniomaxillofac Surg* 2007;35:76–80.
- 6 Parma ES, Korkko J, Hagler WS, Ala-Kokko L: Radial perivascular retinal degeneration: a key to the clinical diagnosis of an ocular variant of Stickler syndrome with minimal or no systemic manifestations. *Am J Ophthalmol* 2002;134:728–734.
- 7 Alshahrani ST, Ghazi NG, Al-Rashaed S: Rhegmatogenous retinal detachments associated to Stickler syndrome in a tertiary eye care center in Saudi Arabia. *Clin Ophthalmol* 2015;10:1–6.
- 8 Vilaplana F, Muinos SJ, Nadal J, Elizalde J, Mojal S: Stickler syndrome. *Epidemiology of retinal detachment. Arch Soc Esp Oftalmol* 2015;90:264–268.
- 9 Snead MP, Yates JR: Clinical and Molecular genetics of Stickler syndrome. *J Med Genet* 1999;36:353–359.
- 10 Richards AJ, Baguley DM, Yates JR, Lane C, Nicol M, Harper PS, Scott JD, Snead MP: Variation in the vitreous phenotype of Stickler syndrome can be caused by different amino acid substitutions in the X position of the type II collagen Gly-X-Y triple helix. *Am J Hum Genet* 2000;67:1083–1094.
- 11 Abeyesiri P, Bunce C, da Cruz L: Outcomes of surgery for retinal detachment in patients with Stickler syndrome: a comparison of two sequential 20-year cohorts. *Graefes Arch Clin Exp Ophthalmol* 2007;45:1633–1638.
- 12 Leiba H, Oliver M, Pollack A: Prophylactic laser photocoagulation in Stickler syndrome. *Eye (Lond)* 1996;10:701–708.
- 13 Pollack A, Milstein A, Oliver M, Zalish M: Circumferential argon laser photocoagulation for prevention of retinal detachment. *Eye (Lond)* 1994;8:419–422.
- 14 Carroll C, Papaioannou D, Rees A, Kaltenthaler E: The clinical effectiveness and safety of prophylactic retinal interventions to reduce the risk of retinal detachment and subsequent vision loss in adults and children with Stickler syndrome: a systematic review. *Health Technol Assess* 2011;15:iii–xiv, 1–62.

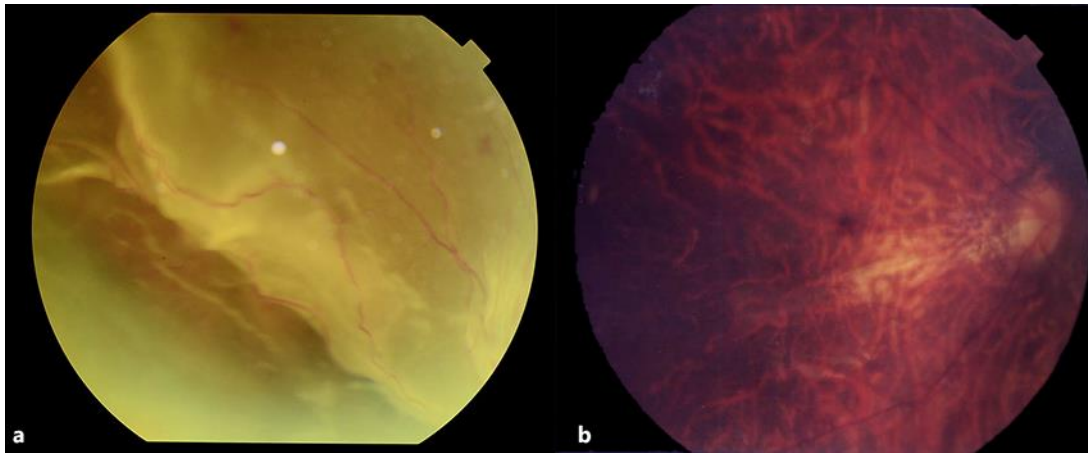


Fig. 1. Pre- and postoperative funduscopy images in the right eye of case 1. Bullous rhegmatogenous retinal detachment developed from the upper quadrants (a). Following scleral buckling surgery, the retina was well reattached and corrected visual acuity improved from 0.01 to 0.6 (b).

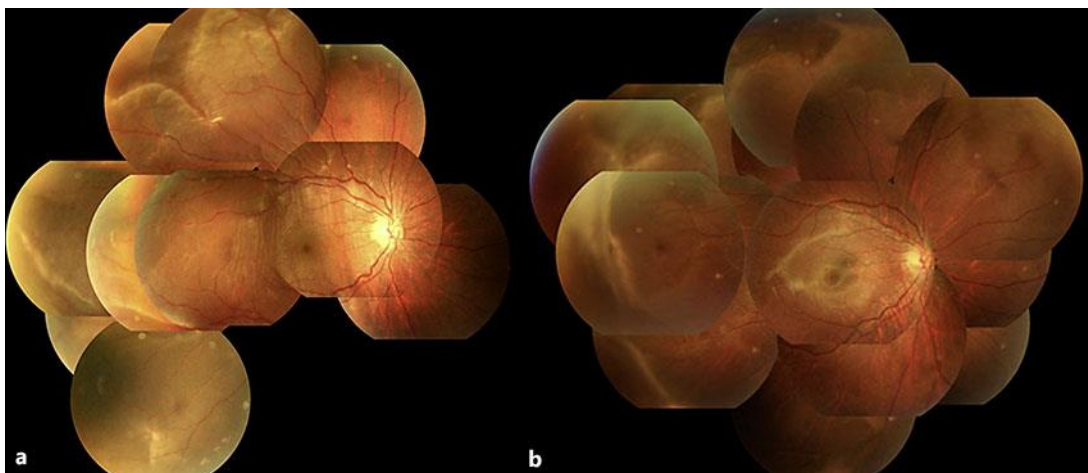


Fig. 2. Pre- and postoperative funduscopy images in the right eye of case 2. Bullous rhegmatogenous retinal detachment developed from the temporal two quadrants (a). Following scleral buckling surgery, the retina was well reattached and corrected visual acuity improved from 0.4 to 0.9 (b).

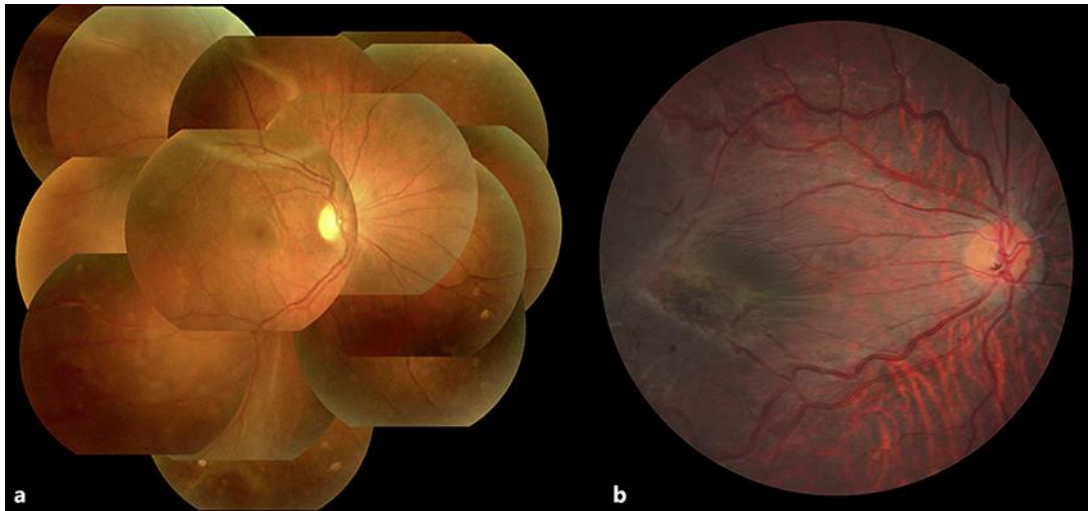


Fig. 3. Funduscopy images of case 3. Preoperative (a) and postoperative (b) funduscopy images of the patient's right eye. Retinal detachment developed from the upper temporal quadrants. Following scleral buckling surgery, the retina was reattached; however, localized downward redetachment occurred and epiretinal membrane formation in the macula also developed at a late stage. Thus, vitreous surgery was then performed. Following surgery, the retina was reattached and corrected visual acuity improved to 0.7.