


## ORIGINAL RESEARCH

## Imaging

# Point-of-care renal ultrasound: Are longitudinal views of the kidney alone sufficient to rule out hydronephrosis?

Piyachat Sasipattarapong MD<sup>1</sup>  | Talib Omer MD<sup>1</sup> | Dana Sajed MD<sup>1</sup> |  
Heeseop Shin MD<sup>2</sup> | Chun Nok Lam PhD, MPH<sup>1,3</sup> | Thomas Mailhot MD<sup>1</sup>

<sup>1</sup>Department of Emergency Medicine, Keck School of Medicine, University of Southern California, Los Angeles, California, USA

<sup>2</sup>Department of Radiology, Los Angeles County + University of Southern California, Los Angeles, California, USA

<sup>3</sup>Department of Preventive Medicine, Keck School of Medicine, University of Southern California, Los Angeles, California, USA

**Correspondence**

Piyachat Sasipattarapong, MD, Department of Emergency Medicine, Keck School of Medicine, University of Southern California, 1200 N State St, Room 1011, Los Angeles, CA 90033, USA.

Email: [p.sasipattarapong@gmail.com](mailto:p.sasipattarapong@gmail.com)

Present address: Piyachat Sasipattarapong, MD, Department of Emergency Medicine, Khon Kaen Hospital, 54, SriChan Road, Nai Mueang Subdistrict, Mueang District, Khon Kaen 40000, Thailand.

**Funding and support:** By *JACEP Open* policy, all authors are required to disclose any and all commercial, financial, and other relationships in any way related to the subject of this article as per ICMJE conflict of interest guidelines (see [www.icmje.org](http://www.icmje.org)). The authors have stated that no such relationships exist.

**Abstract**

**Objective:** Point-of-care ultrasound for the detection of hydronephrosis is frequently used by emergency physicians. The aim of this study was to assess the accuracy of longitudinal views of the kidney compared with a combination of longitudinal and transverse views of the kidney on emergency physician-performed renal point-of-care ultrasound to detect hydronephrosis.

**Methods:** This was a retrospective case-control study of patients who received a renal point-of-care ultrasound examination performed and interpreted as hydronephrosis in the emergency department (ED). These were then matched with a cohort of kidneys from different patients without hydronephrosis. Longitudinal ultrasound views and transverse ultrasound views were reviewed for the presence of hydronephrosis by ultrasound-trained emergency physicians. The gold standard of hydronephrosis was an overall interpretation based on the complete ultrasound examination consisting of both transverse and longitudinal views by ultrasound-trained emergency physicians.

**Results:** Renal point-of-care ultrasound exams from 140 kidneys performed in the ED were enrolled in the study. The sensitivity and specificity of longitudinal ultrasound views compared with a combination of longitudinal and transverse ultrasound views of the kidney as a gold standard were 84.3% (95% confidence interval [CI], 77.2–89.9) and 92.9% (95% CI, 87.3–96.5), the positive predictive value was 92.2% (95% CI, 86.1–96.2), and the negative predictive value was 85.5% (95% CI, 78.9–90.7). The positive and negative likelihood ratios were 11.8 (95% CI, 6.5–21.5) and 0.2 (95% CI, 0.1–0.2), respectively.

**Conclusions:** Longitudinal views of the kidney on ultrasound showed good sensitivity and specificity to detect the presence of hydronephrosis compared with a combination of longitudinal and transverse ultrasound views of the kidney. However, a combination of longitudinal and transverse ultrasound views may still be warranted in high-risk patients or in those with inadequate visualization of the upper pole of the kidney.

Supervising Editor: Lara Goldstein, MD, PhD.

This is an open access article under the terms of the [Creative Commons Attribution-NonCommercial-NoDerivs](https://creativecommons.org/licenses/by-nc-nd/4.0/) License, which permits use and distribution in any medium, provided the original work is properly cited, the use is non-commercial and no modifications or adaptations are made.

© 2022 The Authors. *JACEP Open* published by Wiley Periodicals LLC on behalf of American College of Emergency Physicians.

**KEYWORDS**

bedside ultrasonography, emergencies, emergency department, emergency ultrasonography, hydronephrosis, ultrasonography

## 1 | INTRODUCTION

### 1.1 | Background

Urolithiasis is common and recurrent, with a lifetime incidence of 12% and recurrence rates of up to 50%.<sup>1</sup> Many of these patients present to the emergency department (ED) for diagnosis and acute management, placing a significant burden on the healthcare system.<sup>2</sup> Ultrasound is non-invasive, can be performed quickly at the patient's bedside, and involves no radiation. In addition, there is increasing concern that computed tomography (CT) scans contribute to extra healthcare expenses and risk exposure to radiation.<sup>3</sup> Point-of-care ultrasound (POCUS) for the detection of hydronephrosis by emergency physicians is an established practice and is now integrated as a core emergency ultrasound application.<sup>4</sup> This examination has a sensitivity of 86% to 93% and a specificity of 81% to 82% in the hands of experienced emergency physicians when compared with CT.<sup>5,6</sup>

Hydronephrosis is a finding on renal POCUS that suggests obstruction of the urinary tract, most often from urolithiasis. Hydronephrosis develops centrally in the kidney, appearing as an anechoic (black) fluid collection that distends the renal collecting system. Hydronephrosis can be quantified as mild, moderate, or severe, depending on a subjective assessment of the degree of pelvicalyceal dilatation.<sup>7</sup> Because of its central location, hydronephrosis can be visualized in a longitudinal plane and can also be seen in a mid-transverse plane at the level of the renal hilum.

Detecting hydronephrosis by ultrasound can help clinicians quickly stratify their patients and expedite decisions regarding management and disposition from the ED.<sup>8</sup> Ultrasound identification of mild or moderate unilateral hydronephrosis can obviate further radiologic testing, whereas severe hydronephrosis predicts a high risk of stone passage failure warranting CT imaging and referral.<sup>9</sup>

### 1.2 | Importance

Many authors state unequivocally that imaging the kidneys in both longitudinal (coronal) and transverse (axial) planes is essential to the successful performance of renal POCUS.<sup>8,10</sup> In 2018, in the ultrasound section of the Emergency Ultrasound Standard Reporting Guidelines, the American College of Emergency Physicians (ACEP) described the longitudinal and transverse views of the kidneys as "core emergency ACEP views" for focused renal/urinary tract ultrasound examinations.<sup>11</sup> However, previous research has noted that 65% of physicians identified lack of time to perform POCUS as a barrier to using POCUS.<sup>12</sup> Another study reported that 37% of physicians identified time to perform POCUS as a barrier to the regular use of POCUS in

their practice.<sup>13</sup> The requirement of 2 views adds to the time required to perform and interpret the ultrasound examination, with a potential negative impact on clinical efficiency and a timely quality assurance (QA) process. Although it seems intuitive that more images should result in more accurate interpretation, there is no research assessing the benefit of acquiring 2 views of the kidney as opposed to 1 view.

### 1.3 | Goals of this investigation

The aim of this study was to assess the accuracy of longitudinal views of the kidney compared with a combination of longitudinal and transverse views (2 views) of the kidney on emergency physician-performed renal POCUS to detect hydronephrosis.

## 2 | METHODS

### 2.1 | Study design and setting

This was a 1:1 matched retrospective case-control study of patients who had received a renal POCUS examination performed in the ED at Los Angeles County + University of Southern California (LAC + USC) for diagnostic purposes. The study was given expedited approval by the institutional review board and was considered exempt from informed consent. LAC + USC ED is a tertiary urban county hospital ED with an average annual census of 150,000. The site is home to an emergency residency and an ultrasound fellowship program with ultrasound fellowship-trained emergency physicians.

### 2.2 | Selection of participants and methods of measurement

Stored renal POCUS examinations from adult patients ( $\geq 18$  years old) who visited the ED at LAC + USC between August 1, 2016, and December 31, 2017, were included in the study if they had received a renal POCUS while in the ED for any of the following indications: flank pain, back pain, abdominal pain, groin pain, hematuria, dysuria, acute kidney injury, urinary retention, or urinary tract infection. Indications for each study were determined based on the clinical suspicion of the clinician performing the ultrasound.

All renal POCUS examinations were performed by attending emergency physicians, emergency residents, or fourth-year medical students using a SonoSite (Bothell, WA) M-Turbo or Xporte device and phased array (5-1 MHz) or curvilinear (5-2 MHz) transducers. All examinations were recorded as 6-second video files in both longitudinal

(coronal) and transverse (axial) planes on an ED ultrasound database (QPath, Telexy Healthcare, Maple Ridge, British Columbia) as a standard scanning and storage protocol required by local ED policy. All renal POCUS examinations in QPath were reviewed for the presence or absence of hydronephrosis during regularly performed QA, as determined by an ultrasound-trained emergency physician reviewer with access to all associated renal POCUS images and the patient's chart. This preexisting overall interpretation of the complete ultrasound (CUS) examination consisting of both longitudinal and transverse views in QPath was used as the gold standard in this study.

Images in QPath from consecutive patients receiving renal POCUS were reviewed by a principal investigator to identify a cohort of kidneys demonstrating hydronephrosis based on the preexisting interpretation of CUS by ultrasound-trained emergency physician reviewers in QPath. These kidneys with hydronephrosis were then matched with a cohort of kidneys from different patients without hydronephrosis by the principal investigator and matched by age ( $\pm 1$  year), sex, and laterality (right vs left kidney).

Only complete renal POCUS examinations recorded in B-mode (2-dimensional) videos were included in the study by the principal investigator. A complete examination was defined as including at least 1 longitudinal and 1 transverse view per kidney. Exclusion criteria included examinations for which patient-identifying information was incomplete or when renal POCUS views were not recorded in both longitudinal and transverse views, when still images rather than videos were recorded, and when no videos were recorded in B-mode format (eg, only color Doppler format was recorded). A total of 140 kidneys with hydronephrosis from 121 patients and 140 kidneys without hydronephrosis from an additional 121 patients were identified in QPath. Representative videos of each kidney in both longitudinal and transverse views were abstracted from each examination, de-identified, and compiled into a file for viewing. The principal investigator showed the videos of longitudinal ultrasound (LngUS) views and transverse ultrasound (TUS) views of the kidney separately in random order to expert reviewers blinded to the interpretation of either the performing emergency physician or the overall interpretation in QPath (CUS) and blinded to any radiology imaging results. All 3 expert reviewers were emergency physicians in the emergency ultrasound division who had advanced training in emergency ultrasound, including completion of an ultrasound fellowship or registered diagnostic medical sonographer certification with extensive (>10 years) experience in POCUS QA and teaching. Each expert reviewer was asked to assess a random selection of LngUS and TUS views of the kidney separately for the presence or absence and degree of hydronephrosis as well as image quality according to the ACEP 5-point QA grading scale.<sup>11</sup> A grade 1 image is an image with no recognizable structures, and therefore no objective data can be gathered. A grade 2 image is an image with minimally recognizable structures but is insufficient for diagnosis. A grade 3 image is an image with the minimal criteria met for a diagnosis and recognizable structures but with some technical or other flaws. A grade 4 image is an image with all structures imaged well so that a diagnosis is easily supported, and a grade 5 image is an image with excellent quality with a diagnosis completely supported. Although not prospec-

### The Bottom Line

Longitudinal ultrasound views alone can adequately detect the presence of moderate to severe hydronephrosis compared with combined longitudinal and transverse views of the kidney. As a first-line screening tool, this may be helpful in a busy emergency department where time may be a barrier to performing renal point-of-care ultrasound.

tively validated, these guidelines represent a widely used set of criteria for establishing POCUS image quality.

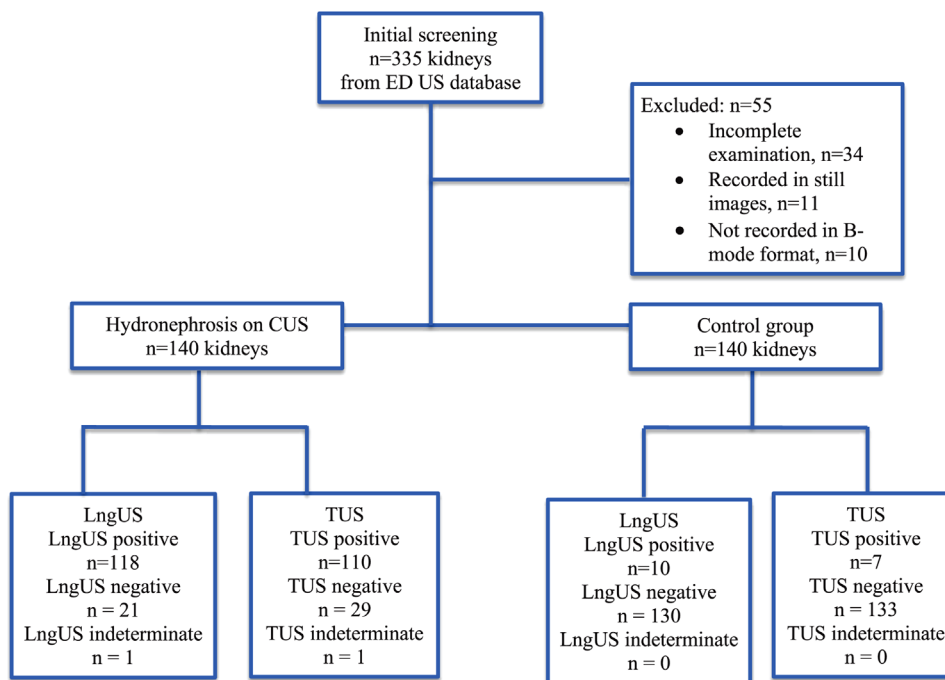
Hydronephrosis was defined as none, mild, moderate, or severe according to standard definitions.<sup>7</sup> Mild hydronephrosis was defined as mild renal pelvis dilation with no dilation of the calyces or parenchymal atrophy. Moderate hydronephrosis was considered to be present if the calyces were confluent, resulting in a "bear's paw" appearance, and severe hydronephrosis was considered to be present if the hydronephrosis was sufficiently extensive to cause effacement of the renal parenchyma.<sup>7</sup>

To ensure good interrater reliability, we independently reviewed a random sample of 14% of renal POCUS videos of LngUS and TUS views with 2 blinded expert reviewers and compared for the presence or absence and severity of hydronephrosis. Cases of disagreement were adjudicated by a third blinded expert reviewer. Any additional renal findings were also noted.

The gold standard was considered to be the preexisting overall interpretation of CUS images in identifying the presence of hydronephrosis by an ultrasound-trained emergency physician who had access to the patient's chart but other patient's investigation on the patient's chart was not used as a gold standard in this study. We determined the accuracy of LngUS and TUS views in identifying hydronephrosis using CUS as a gold standard. The patient's age, sex, and prior history of urolithiasis were obtained from chart review.

## 2.3 | Outcome and analysis

Sensitivity and specificity analyses were conducted to compare LngUS and TUS views versus CUS examination consisting of both transverse and longitudinal views in identifying the presence of hydronephrosis. We compared LngUS and TUS views with a CUS to detect the presence of hydronephrosis using the sensitivity, specificity, positive predictive value (PPV), negative predictive value (NPV), and area under the curve using the receiver operating characteristic (ROC) analysis. The result was given with the confidence interval (CI) of 95%. We performed Wilcoxon signed-rank tests to examine the median difference in the degree of hydronephrosis and image quality. Statistical analyses were performed using Stata 13 with an  $\alpha$  at 0.05. We performed a sample size calculation for sensitivity and specificity analysis. To detect a 90%



**FIGURE 1** Flowchart of participants. CUS, complete ultrasound; ED, emergency department; LngUS, longitudinal ultrasound; TUS, transverse ultrasound; US, ultrasound

sensitivity and a 90% specificity with an expected prevalence at 50% (1:1 matching), the study required 140 patients in the hydronephrosis group as well as the group without hydronephrosis.

### 3 | RESULTS

#### 3.1 | Characteristics of study subjects

Between August 1, 2016, and December 31, 2017, 140 kidneys from 121 preexisting renal POCUS exams performed in the ED with hydronephrosis on CUS were identified as seen in Figure 1. The control group consisted of 140 kidneys without hydronephrosis, which were match paired with the study subjects for kidney laterality, sex, and age (within 1 year). Hydronephrosis was rated on CUS as mild in 96 (34.3%), moderate in 25 (8.9%), and severe in 19 (6.8%) kidneys. There were 77 left kidneys (55%) in each group. Table 1 illustrates the demographic characteristics.

#### 3.2 | Main results

Our results show that LngUS views had a sensitivity of 84.3%, a specificity of 92.9%, a positive likelihood ratio (LR+) of 11.8, and a negative likelihood ratio (LR-) of 0.2, whereas TUS views had a sensitivity of 78.6%, a specificity of 95.0%, a LR+ of 15.7, and a LR- of 0.2 for detecting hydronephrosis compared with CUS as a gold standard (Table 2).

**TABLE 1** Baseline characteristics and radiology testing performed in patients with hydronephrosis identified on renal POCUS and patients in the control group

Characteristics	Hydronephrosis group (n = 140)	Control group (n = 140)
Demographics		
Mean age $\pm$ SD, years	50 $\pm$ 15	50 $\pm$ 14
Male, n (%)	80 (57)	80 (57)
Clinical indication, n (%)		
Abdominal pain	48 (34.3)	71 (50.7)
Flank pain	40 (28.6)	37 (26.4)
Hematuria	8 (5.7)	9 (6.4)
Dysuria	7 (5)	7 (5)
Acute kidney injury	9 (6.4)	3 (2.1)
Urinary retention	17 (12.1)	4 (2.9)
Anuria	1 (0.7)	0 (0)
Back pain	4 (2.9)	5 (3.6)
Urinary tract infection	5 (3.6)	4 (2.9)
Groin pain	1 (0.7)	0 (0)
Prior history of stone, n (%)	30 (21.4)	17 (12.1)
CT performed, n (%)	52 (37.1)	41 (29.3)
Radiology ultrasound performed, n (%)	21 (15.1)	15 (10.7)

Abbreviations: CT, computed tomography; POCUS, point-of-care ultrasound; SD, standard deviation.

**TABLE 2** Diagnostic performance of single-view ultrasound (LngUS, TUS) for the detection of hydronephrosis compared with CUS examination consisting of both transverse and longitudinal views

Parameter	LngUS views	TUS views
Sensitivity, % (95% CI)	84.3 (77.2–89.9)	78.6 (70.8–85.1)
Specificity, % (95% CI)	92.9 (87.3–96.5)	95.0 (90.0–98.0)
PPV, % (95% CI)	92.2 (86.1–96.2)	94.0 (88.1–97.6)
NPV, % (95% CI)	85.5 (78.9–90.7)	81.6 (74.8–87.2)
LR+ (95% CI)	11.8 (6.5–21.5)	15.7 (7.5–32.5)
LR– (95% CI)	0.2 (0.1–0.2)	0.2 (0.2–0.3)

Abbreviations: CI, confidence interval; CUS, complete ultrasound; LngUS, longitudinal ultrasound; LR+, positive likelihood ratio; LR–, negative likelihood ratio; NPV, negative predictive value; PPV, positive predictive value; TUS, transverse ultrasound.

There was 1 scan rated as indeterminate for the presence or absence of hydronephrosis on both LngUS and TUS views. In the subgroup of patients with moderate and severe hydronephrosis identified on CUS ( $n = 44$ ), the sensitivity of LngUS and TUS views for detecting hydronephrosis was 93.2% (95% CI, 81.3–98.6) and 88.6% (95% CI, 75.4–96.2), respectively.

There was a 78.1% interrater agreement of LngUS views between 2 expert reviewers. For discordant results, we required a tiebreaker review by a third expert reviewer (simple  $\kappa = 0.62$ ). The agreement of TUS views between 2 expert reviewers was 82.1% (simple  $\kappa = 0.66$ ). Overall interrater agreement was substantial for hydronephrosis detection in both LngUS and TUS views. Table 3 demonstrates image quality according to the ACEP 5-point QA grading scale. Overall renal POCUS videos were classified as grade 1 in 2.1% (12/560), grade 2 in 13.2% (74/560), grade 3 in 55.9% (313/560), grade 4 in 28.8% (161/560), and none of them were classified as grade 5.

The diagnostic accuracy of LngUS views together with TUS views from the same patient (LngUS + TUS) compared with the CUS from the same patient was calculated. The sensitivity of the combined single views (LngUS + TUS) was 92.1% (95% CI, 86.4–96.0) and the specificity was 88.6% (95% CI, 82.1–93.3) compared with CUS as the gold standard.

LngUS and TUS views can both detect the severity of hydronephrosis when compared with CUS (Spearman's  $\rho = 0.80$  and  $0.77$ , respectively). In comparing LngUS views with CUS in the detection of the severity of hydronephrosis, the area under the curve using ROC analysis was  $0.889$ . A Wilcoxon signed-rank test determined that there was no statistically significant median difference between LngUS views compared with CUS classifications of hydronephrosis ( $W = 0.629$ ,  $P = 0.529$ ), with LngUS underclassifying the severity of hydronephrosis in 14.3% of cases, overclassifying in 11.1%, and correctly classifying in 74.3%. In comparing TUS views to CUS in the detection of the severity of hydronephrosis, the area under the curve using ROC analysis was  $0.871$ . A Wilcoxon signed-rank test determined that there was a statistically significant median difference between TUS and CUS classifications of hydronephrosis ( $W = 1.767$ ,  $P = 0.077$ ), with TUS views

**TABLE 3** Image quality according to ACEP 5-point quality assurance grading scale<sup>a</sup>

Ultrasound view	Hydronephrosis group	Control group	Total
LngUS views			
Grade 1	1 (0.7)	2 (1.4)	3 (1.1)
Grade 2	9 (6.4)	21 (15.0)	30 (10.7)
Grade 3	69 (49.3)	80 (57.1)	149 (53.2)
Grade 4	61 (43.6)	37 (26.4)	98 (35.0)
Grade 5	0 (0)	0 (0)	0 (0)
Total	140	140	280
TUS views			
Grade 1	5 (3.6)	4 (2.9)	9 (3.2)
Grade 2	16 (11.4)	28 (20.0)	44 (15.7)
Grade 3	80 (57.1)	84 (60.0)	164 (58.6)
Grade 4	39 (27.9)	24 (17.1)	63 (22.5)
Grade 5	0 (0)	0 (0)	0 (0)
Total	140	140	280
LngUS + TUS			
Grade 1	6 (2.1)	6 (2.1)	12 (2.1)
Grade 2	25 (8.9)	49 (17.5)	74 (13.2)
Grade 3	149 (53.2)	164 (58.6)	313 (55.9)
Grade 4	100 (35.7)	61 (21.8)	161 (28.8)
Grade 5	0 (0)	0 (0)	0 (0)
Total video files	280	280	560

Note: Data are provided as n (%) or n.

Abbreviations: ACEP, American College of Emergency Physicians; LngUS, longitudinal ultrasound; TUS, transverse ultrasound.

<sup>a</sup>The ACEP 5-point quality assurance grading scale: a grade 1 image is an image with no recognizable structures and therefore no objective data can be gathered; a grade 2 image is an image with minimally recognizable structures but is insufficient for diagnosis; a grade 3 image is an image with the minimal criteria met for diagnosis and recognizable structures with some technical or other flaws; a grade 4 image is an image with all structures imaged well so that a diagnosis is easily supported; and a grade 5 image is an image with excellent quality with a diagnosis completely supported.<sup>11</sup>

underclassifying the severity in 16.8% of ultrasound records, overclassifying in 6.8%, and correctly classifying in 76.1%. The majority of misclassified degrees of hydronephrosis by both LngUS and TUS views were off by 1 degree of severity (Table 4).

The total number of kidneys in which LngUS or TUS interpretations differed from CUS interpretation was 56 (40 false negatives and 16 false positives). Among the false-negative cases, 21 were from LngUS views and 29 from TUS views, and it was of mild grade only on CUS in most cases. A total of 10 kidneys were false negatives in both LngUS and TUS views. Of the 21 false-negative LngUS videos, 14 were left kidneys (67%). Of the 21 false-negative LngUS videos, 7 were classified as having poor image quality (ACEP 5-point QA grading scale 1 or 2). In 1 false-negative case, the subject had emphysematous pyelonephritis

**TABLE 4** Comparison of single-view ultrasound and CUS in the detection of degree of hydronephrosis<sup>a</sup>

Single-view ultrasound classification	CUS examination (both transverse and longitudinal views)					Total
	None	Mild	Moderate	Severe	Indeterminate	
LngUS view ( $P = 0.529$ )						
None	130	18	2	1	0	151
Mild	10	58	11	1	0	80
Moderate	0	18	10	7	0	35
Severe	0	1	2	10	0	13
Indeterminate	0	1	0	0	0	1
Total	140	96	25	19	0	280
TUS view ( $P = 0.077$ )						
None	133	24	4	1	0	162
Mild	7	59	8	4	0	78
Moderate	0	12	13	6	0	31
Severe	0	0	0	8	0	8
Indeterminate	0	1	0	0	0	1
Total	140	96	25	19	0	280

Abbreviations: CUS, complete ultrasound; LngUS, longitudinal ultrasound; TUS, transverse ultrasound.

<sup>a</sup>Values in table represent frequency of correct, underclassification, and overclassification of single-view ultrasound (LngUS, TUS) compared with CUS. Spearman's  $\rho$  test was used for comparison of single-view ultrasound (LngUS, TUS) and 2-view ultrasound (CUS) in the detection of the severity of hydronephrosis and area under the curve using receiver operating characteristic analysis. A Wilcoxon signed-rank test was used for the median difference between LngUS and CUS classifications of hydronephrosis.

identified by CT scan, and the TUS view was also falsely negative in this case. Of 29 false-negative TUS videos, 15 were left kidneys (52%). In 29 false-negative TUS videos, 16 were interpreted as having poor image quality (ACEP 5-point QA grading scale 1 or 2). Of 16 false-positive kidneys, 10 were LngUS views and 7 were TUS views. One kidney was false-positive in both LngUS and TUS views.

#### 4 | LIMITATIONS

The current study has several limitations. Studies of diagnostic test accuracy are subject to multiple forms of diagnostic bias.<sup>14</sup> The gold standard in this study is internally determined, not based on other objective imaging. Although CT is the gold standard for diagnosing nephrolithiasis and hydronephrosis,<sup>15</sup> we used POCUS interpreted by expert reviewer on QA review as reference because two-thirds of the patients did not receive CT imaging; those who did may have had more severe clinical presentations and a greater degree of obstruction, and the time difference between POCUS and CT imaging was not optimal in the majority of patients. In addition, ultrasound-trained emergency physician reviewers who regularly interpreted CUS on QA review as a gold standard had access to the patients' charts. However, preexisting CUS image interpretations alone were our gold standard and not the other patients' information from the patients' chart.

We did not control for the multitude of variables that can influence the appearance of ultrasound images, including the ultrasound

machine, operator, hydration status, and bladder fullness. Images were primarily obtained by learners who may have had varying degrees of training in performing renal POCUS.<sup>6</sup> POCUS imaging is defined as being both performed and interpreted by the clinician; however, in this study we did not assess the skills required to acquire high-quality images. In addition, although the images were acquired by various levels of sonographer expertise, the images were interpreted by experts who may limit the generalizability.

Other limitations of our article include those inherent in any retrospective chart review performed at a single institution. Although we used strict criteria for our chart review, incomplete documentation, missing charts, and unrecorded information are all limitations. We chose a retrospective study design to avoid creating delays in patient care that would have resulted in separate prospective acquisitions of LngUS views, TUS views, and CUS examinations in the same patient. Because having emergency physicians perform LngUS, TUS, and CUS in the same patient separately in a prospective way would add more time in patient care, we could not assess how much longer a CUS took to perform in addition to obtaining a LngUS view. Although one could conclude that performing a single view of the kidney (LngUS view) resulted in a shorter time to image acquisition and interpretation compared with CUS, our study did not measure this. Further prospective research would be useful to assess whether a significant difference in time savings occurs with the performance of LngUS versus CUS.

Furthermore, given that ultrasound images were included in a selected time frame, we were not able to ensure an equal distribution

of hydronephrosis severity. Most patients in this study had mild hydronephrosis. Selection bias may also have been introduced because non-recognizable ultrasound images might have been defined as incomplete scans and thus excluded from the study. Finally, this is a study for the value of 1 versus 2 views for hydronephrosis only, not for other important or incidental findings that are beyond the scope of typical renal POCUS (eg, mass, abscess, cyst, emphysematous pyelonephritis).

## 5 | DISCUSSION

The diagnostic performance of bedside ultrasound performed by emergency physicians in the diagnosis of urolithiasis has been extensively studied.<sup>5,6</sup> Despite the widespread use of renal POCUS, no study has investigated the necessity of obtaining both LngUS and TUS views together. To our knowledge this is the first study to determine the test characteristics for LngUS and TUS views of the kidney to identify hydronephrosis in comparison with a CUS. We have found that both LngUS and TUS views have a high sensitivity and specificity for the detection of hydronephrosis when using CUS as a criterion standard. The sensitivity was higher in LngUS views than in TUS views. Overall interrater agreement was substantial for hydronephrosis detection between expert reviewers in both LngUS views and TUS views. Moreover, we found that the finding of moderate or greater hydronephrosis on LngUS views yielded higher sensitivity for the presence of moderate or greater hydronephrosis on CUS compared with all degrees of hydronephrosis. Previous studies have found that the finding of moderate or greater hydronephrosis yielded high specificities and high LR+ for the presence of a renal stone identified on CT.<sup>6,16</sup> In addition, an increasing degree of hydronephrosis on POCUS was significantly associated with an increasing likelihood of a stone greater than 5 mm and higher rates of urologic intervention.<sup>16,17</sup>

We found that any degree of hydronephrosis on LngUS views makes the presence of hydronephrosis on CUS views more likely (PPV, 92.2%; LR+, 11.8), and a lack of hydronephrosis on LngUS views can rule out hydronephrosis on CUS (NPV, 85.5%; LR-, 0.2). In addition, our study shows that LngUS views can detect the severity of hydronephrosis when compared with CUS as the gold standard. However, hydronephrosis grading systems are based on subjective parameters and are affected by many factors.<sup>18</sup>

We performed an analysis on cases with discordant results between any single axis view and CUS to look for a possible explanation. This analysis produced several interesting findings. First, most of the false negatives occurring from LngUS or TUS views were of the left kidney. The left kidney is typically more difficult to visualize because of overlying bowel gas in the stomach that reflects sound waves, the more superior position of the left kidney, and the absence of an acoustic window from the liver. Second, the most common reason for false negatives on both LngUS and TUS views was poor image quality. This was frequently attributed to inadequate visualization of the upper pole of the kidney because of prominent rib shadows from the lower ribs, a

known difficulty when performing ultrasound of the kidney.<sup>19</sup> Of the renal video clips, 15% were classified as grade 1 or 2 according to the ACEP 5-point QA grading scale (insufficient for diagnosis). However, we did not exclude these video clips in order to represent a real-life prospective study. Third, a few of the false negatives on LngUS views occurred in kidneys that appeared to have been imaged in a plane that was slightly oblique to the long axis of the kidney (although being much closer to the long axis than the short axis). This slight oblique positioning of the kidney can make the renal sinus more difficult to evaluate because the renal sinus will not be visualized in its entirety at the same moment on the image. Because the kidney is positioned obliquely in the body, it is necessary to orient the transducer along the true long axis of the kidney, which may actually be oblique to the body's coronal plane. Off-axis imaging of the kidney may decrease the ability to detect hydronephrosis when the central renal sinus of the kidney is incompletely visualized.<sup>8</sup> Given the high frequency at which errors appear to occur because of these factors, ultrasound educators should take heed to specifically target avoiding these errors. Finally, another pitfall for false negatives in LngUS view scans were mistaking hydronephrosis for dilated renal vasculature. This also appeared to be the most common reason that caused false positives in both LngUS and TUS views. The ultrasound appearance of the renal vasculature sometimes resembles that of hydronephrosis consistent with a prior report.<sup>20</sup> Our analysis supports that renal POCUS training should emphasize the means by which these conditions can be differentiated, such as by using color Doppler sonography.<sup>20-22</sup>

An interesting finding arose when we calculated the diagnostic accuracy of LngUS views together with TUS views from the same patient (LngUS + TUS) compared with the CUS from the same patient. Rather than perfect sensitivity and specificity as one might expect from a separate review of identical image sets, the sensitivity of the combined single views (LngUS + TUS) was 92.1% and the specificity was 88.6% compared with CUS as the gold standard. There are several possible reasons for this. First, some of preexisting overall interpretations of the renal POCUS (CUS) were interpreted on Qpath by ultrasound-trained emergency physician reviewers after CT or radiology ultrasound, potentially causing the ultrasound-trained emergency physician reviewers to look more closely for specific known findings. The ultrasound-trained emergency physician reviewers who interpreted the CUS images had access to the patient's clinical information (including radiologic imaging). This may influence the gold standard potentially in cases where the expert reviewers had the ability to look at any radiology imaging to know if the patient had hydronephrosis or a renal stone, and based on this they may have looked harder for hydronephrosis on the CUS images, introducing bias. However, CUS images alone were our gold standard and not other patients' investigation information from the patients' chart. Second, the diagnosis of hydronephrosis on ultrasound is subjective, with different sensitivities reported between physicians, potentially resulting in disparate interpretations of the same ultrasound finding.<sup>6,23</sup> Third, in some exams, there were several ultrasound videos for each view comprising the CUS exam, including some recorded with color Doppler mode, giving

CUS exams more information than either the single best LngUS view or TUS views derived from these cases despite our attempts to select the LngUS and TUS videos that best represented each case. Finally, there might be benefit to being able to compare the contralateral kidney on CUS that an expert reviewer of a single ultrasound view did not have. A complete bilateral renal system assessment including the bladder can provide significant amounts of information, and POCUS for hydronephrosis should be used with a history and clinical prediction tool to improve the diagnostic accuracy.<sup>7,16</sup> It is possible that the diagnostic accuracy may have been lowered because of all these reasons. Nonetheless, further studies are advised to determine whether the accuracy of single-view ultrasound (LngUS or TUS) versus CUS differs without these advantages.

In conclusion, the results of our study suggest that longitudinal views of the kidney on ultrasound showed good sensitivity and specificity to detect the presence or absence and severity of hydronephrosis compared with a combination of LngUS and TUS views of the kidney. In particular, the presence of moderate or greater hydronephrosis on LngUS views significantly increased the sensitivity for the presence of moderate or greater hydronephrosis on CUS. The lack of hydronephrosis on longitudinal views of the kidney on ultrasound could be used to rule out the presence of hydronephrosis on a combination of LngUS and TUS views of the kidney. This may be helpful in a busy ED where time spent on performing ultrasound is a barrier to renal POCUS. Although LngUS view ultrasound is a reasonable first-line screening tool in suspected renal colic, a 2-view ultrasound may still be warranted in high-risk patients, especially with the left kidney, in those with inadequate visualization of the upper pole of the kidney due to prominent rib shadows from the lower ribs or in those with suspicion for an alternate diagnosis. In addition, color Doppler ultrasound is necessary to differentiate between hydronephrosis and dilated renal vasculature. Larger multicentered prospective studies, however, are needed to better define the test characteristics of single-view ultrasound in the emergency management of patients with suspected hydronephrosis.

## CONFLICT OF INTEREST

The authors declare no conflict of interest.

## AUTHOR CONTRIBUTIONS

Piyachat Sasipattarapong and Thomas Mailhot conceived the study and designed the trial. Thomas Mailhot and Piyachat Sasipattarapong supervised the conduct of the trial and data collection. Piyachat Sasipattarapong undertook recruitment of participating centers and patients and managed the data, including quality control. Chun Nok Lam provided statistical advice on the study design and analyzed the data. Piyachat Sasipattarapong, Talib Omer, Dana Sajed, Heeseop Shin, and Thomas Mailhot chaired the data oversight committee. Piyachat Sasipattarapong drafted the manuscript, and all authors contributed substantially to its revision. Piyachat Sasipattarapong takes responsibility for the article as a whole.

## ORCID

Piyachat Sasipattarapong MD  <https://orcid.org/0000-0002-8566-4433>

## REFERENCES

- Teichman JM. Clinical practice. Acute renal colic from ureteral calculus. *N Engl J Med*. 2004;350:684-693.
- Hyams ES, Korley FK, Pham JC, et al. Trends in imaging use during the emergency department evaluation of flank pain. *J Urol*. 2011;186:2270-2274.
- Westphalen AC, Hsia RY, Maselli JH, et al. Radiological imaging of patients with suspected urinary tract stones: national trends, diagnoses, and predictors. *Acad Emerg Med*. 2011;18:699-707.
- 2011 EM Model Review Task Force, Perina DG, Brunett CP, et al. The 2011 model of the clinical practice of emergency medicine. *Acad Emerg Med*. 2012;19(7):e19-e40. doi:10.1111/j.1553-2712.2012.01385.x
- Gaspari RJ, Horst K. Emergency ultrasound and urinalysis in the evaluation of flank pain. *Acad Emerg Med*. 2005;12:1180-1184.
- Herbst MK, Rosenberg G, Daniels B, et al. Effect of provider experience on clinician-performed ultrasonography for hydronephrosis in patients with suspected renal colic. *Ann Emerg Med*. 2014;64(3):269-276. doi:10.1016/j.annemergmed.2014.01.012
- American College of Emergency Physicians, Emergency Ultrasound Section. *Emergency Ultrasound Imaging Criteria Compendium*. ACEP Policy Statement. Approved October 2021. Available at: <https://www.acep.org/globalassets/new-pdfs/policy-statements/emergency-ultrasound-imaging-criteria-compendium.pdf>. Accessed March 10, 2021.
- Noble VE, Nelson BP. Renal and bladder ultrasound. In: Noble VE, Nelson BP, eds. *Manual of Emergency and Critical Care Ultrasound*. 2nd ed. New York: Cambridge University Press; 2011:136-137.
- Innes GD, Scheuermeyer FX, McRae AD, et al. Hydronephrosis severity clarifies prognosis and guides management for emergency department patients with acute ureteral colic. *Can J Emerg Med*. 2021;23:687-695. doi:10.1007/s43678-021-00168-x
- Blaivas M. Kidneys. In: Cosby KS, Kendall JL. *Practical Guide to Emergency Ultrasound*. 2nd ed. Philadelphia: Lippincott Williams and Wilkins; 2014:173-175.
- American College of Emergency Physicians, Emergency Ultrasound Section. *Emergency Ultrasound Standard Reporting Guidelines*. American College of Emergency Physicians, Emergency Ultrasound Section. Approved June 2018. Available at: <https://www.acep.org/globalassets/uploads/uploaded-files/acep/clinical-and-practice-management/policy-statements/information-papers/emergency-ultrasound-standard-reporting-guidelines-2018.pdf>. Accessed March 13, 2021.
- Wong J, Montague S, Wallace P, et al. Barriers to learning and using point-of-care ultrasound: a survey of practicing internists in six North American institutions. *Ultrasound J*. 2020;12(1):19. doi:10.1186/s13089-020-00167-6
- Bellows B, Totten J, Shah S, et al. Perceived barriers in the use of point of care ultrasound in the WWAMI region. *J Emerg Med Crit Care*. 2015;1(1):4.
- Kohn MA, Carpenter CR, Newman TB. Understanding the direction of bias in studies of diagnostic test accuracy. *Acad Emerg Med*. 2013;20(11):1194-1206.
- Brisbane W, Bailey M, Sorensen M. An overview of kidney stone imaging techniques. *Nat Rev Urol*. 2016;13:654-662. doi:10.1038/nrurol.2016.154
- Daniels B, Gross CP, Molinaro A, et al. STONE PLUS: evaluation of emergency department patients with suspected renal colic, using a clinical prediction tool combined with point-of-care limited



- ultrasonography. *Ann Emerg Med.* 2016;67:439-448. doi:[10.1016/j.annemergmed.2015.10.020](https://doi.org/10.1016/j.annemergmed.2015.10.020)
17. Goertz JK, Lotterman S. Can the degree of hydronephrosis on ultrasound predict kidney stone size? *Am J Emerg Med.* 2010;28:813-816.
  18. Onen A. Grading of hydronephrosis: an ongoing challenge. *Front Pediatr.* 2020;8:458. doi:[10.3389/fped.2020.00458](https://doi.org/10.3389/fped.2020.00458)
  19. Hansen KL, Nielsen MB, Ewertsen C. Ultrasonography of the kidney: a pictorial review. *Diagnostics.* 2016;6(1):2.
  20. Lusenti T, Fiorini F, Barozzi L. Renal arteriovenous fistula simulating hydronephrosis: a case report. *J Ultrasound.* 2011;14(4):233-236.
  21. Chean CS, Kuah JY, Stopa M, et al. Renal arteriovenous malformation mimicking hydronephrosis—Hidden danger. *BJR Case Rep.* 2019;5(4):20190034.
  22. Koratala A, Bhattacharya D, Chamarthi G. Point-of-care renal ultrasound: interpret with care. *Clin Case Rep.* 2018;7(1):233-235. doi:[10.1002/ccr3.1934](https://doi.org/10.1002/ccr3.1934)
  23. Keays MA, Guerra LA, Mihill J, et al. Reliability assessment of society for fetal urology ultrasound grading system for hydronephrosis. *J Urol.* 2008;180:1680-1683.

**AUTHOR BIOGRAPHY**

Piyachat Sasipattarapong, MD, is an emergency physician in the Department of Emergency Medicine at Khon Kaen Hospital, Thailand. She completed a fellowship in International Emergency Ultrasound at University of Southern California in Los Angeles, California.

**How to cite this article:** Sasipattarapong P, Omer T, Sajed D, Shin H, Lam CN, Mailhot T. Point-of-care renal ultrasound: Are longitudinal views of the kidney alone sufficient to rule out hydronephrosis? *JACEP Open.* 2022;3:e12794. <https://doi.org/10.1002/emp2.12794>