



Original Article

Posterior cruciate ligament reconstruction by means of tibial tunnel: anatomical study on cadavers for tunnel positioning^{☆,☆☆}

Antônio Altenor Bessa de Queiroz, César Janovsky*,
Carlos Eduardo da Silveira Franciozi, Leonardo Addêo Ramos,
Geraldo Sérgio Mello Granata Junior, Marcos Vinicius Malheiros Luzo, Moises Cohen

Universidade Federal de São Paulo, São Paulo, SP, Brazil

ARTICLE INFO

Article history:

Received 13 April 2012

Accepted 10 October 2013

Available online 5 May 2014

Keywords:

Posterior cruciate ligament

Cadaver

Reconstruction

ABSTRACT

Objective: to determine the reference points for the exit of the tibial guidewire in relation to the posterior cortical bone of the tibia.

Methods: sixteen knees from fresh cadavers were used for this study. Using a viewing device and a guide marked out in millimeters, three guidewires were passed through the tibia at 0, 10 and 15 mm distally in relation to the posterior crest of the tibia. Dissections were performed and the region of the center of the tibial insertion of the posterior cruciate ligament (PCL) was determined in each knee. The distances between the center of the tibial insertion of the PCL and the posterior tibial border (CB) and between the center of the tibial insertion of the PCL and wires 1, 2 and 3 (CW1, CW2 and CW3) were measured.

Results: in the dissected knees, we found the center of the tibial insertion of the PCL at 1.09 ± 0.06 cm from the posterior tibial border. The distances between the wires 1, 2 and 3 and the center of the tibial insertion of the PCL were respectively 1.01 ± 0.08 , 0.09 ± 0.05 and 0.5 ± 0.05 cm.

Conclusion: the guidewire exit point 10 mm distal in relation to the posterior crest of the tibia was the best position for attempting to reproduce the anatomical center of the PCL.

© 2014 Sociedade Brasileira de Ortopedia e Traumatologia. Published by Elsevier Editora

Ltda. Este é um artigo Open Access sob a licença de [CC BY-NC-ND](#)

Reconstrução transtúnel tibial do ligamento cruzado posterior: estudo anatômico em cadáveres para a feitura do túnel tibial

RESUMO

Objetivo: determinar os pontos de referência para a saída do fio-guia tibial em relação à cortical posterior da tibia.

Métodos: foram usados para este estudo 16 joelhos de cadáveres frescos. Através de uma escopia e com um guia milimetrado, foi feita a passagem de três fios-guias a 0, 10 e 15 mm

Palavras-chave:

Ligamento cruzado posterior

Cadáver

Reconstrução

* Please cite this article as: de Queiroz AAB, Janovsky C, da Silveira Franciozi CE, Ramos LA, Granata Junior GSM, Luzo MVM, et al. Reconstrução transtúnel tibial do ligamento cruzado posterior: estudo anatômico em cadáveres para a feitura do túnel tibial. Rev Bras Ortop. 2014;49:370-373.

☆☆ Work performed in the Department of Orthopedics and Traumatology, Escola Paulista de Medicina, Universidade Federal de São Paulo, São Paulo, SP, Brazil.

* Corresponding author.

E-mail: cesar.janovsky@gmail.com (C. Janovsky).

2255-4971 © 2014 Sociedade Brasileira de Ortopedia e Traumatologia. Published by Elsevier Editora Ltda.

Este é um artigo Open Access sob a licença de [CC BY-NC-ND](#) <http://dx.doi.org/10.1016/j.rboe.2014.04.016>

distalmente em relação à crista posterior da tibia. Foram feitas dissecções e foi determinada a região do centro da inserção tibial do ligamento cruzado posterior (LCP) em cada joelho. Foram medidas as distâncias entre o centro da inserção tibial do LCP e a borda tibial posterior (CB) e entre o centro da inserção tibial do LCP e os fios 1-2 e 3 (CF1-CF2-CF3).

Resultados: nos joelhos dissecados, encontramos o centro da inserção tibial do LCP a $1,09\text{ cm} \pm 0,06$ da borda tibial posterior. As distâncias entre os fios 1,2 e 3 e o centro da inserção tibial do LCP foram respectivamente $1,01 \pm 0,08$; $0,09 \pm 0,05$ e $0,5 \pm 0,05$.

Conclusão: a saída do fio-guia a 10 mm distalmente em relação à crista posterior da tibia representa a melhor posição para tentar reproduzir o centro anatômico do LCP.

© 2014 Sociedade Brasileira de Ortopedia e Traumatologia. Publicado por Elsevier Editora Ltda. Este é um artigo Open Access sob a licença de [CC BY-NC-ND](#)

Introduction

Ligament injuries of the posterior region of the knee are a difficult topic for knee surgeons and orthopedists in general. Posterior cruciate ligament (PCL) injuries are among the most challenging of these, because there is no uniformly defined approach to their treatment and because of different evolutionary features that they present.^{1,2}

The PCL is the strongest ligament of the knee and crosses the medial femoral condyle to the posterior region of the tibia. It presents two functional bands: the anterolateral and the posteromedial. In addition, grade III PCL injuries that present instability, pain and associated injuries are indicated for surgical treatment and therefore it is extremely important to understand their anatomy.^{3,4}

Correctly positioning the tunnels during the ligament reconstructions is the determining factor for success in this procedure. Some studies have demonstrated that the center of insertion of the PCL in the tibia is intra-articularly anterior to the posterior border of the tibia.^{5,6} Others have shown that it is in the region known as the posterior facet, or even distal to this structure.^{6,7}

The aim of this study was to determine the reference points for the exit of the tibial guidewire, so that it would become possible to establish a secure basis for the reconstruction technique, taking the reference point of the posterior cortical bone of the tibia.

Materials and methods

For this study, 16 knees from fresh cadavers were used (eight right and eight left knees). The mean age of the donors was 60 ± 7.3 years (range: 55-70 years); they were all male and their mean height was 167 ± 4.45 cm. The dissections were performed at the death investigation service of the city of São Paulo and the study was approved by the institution's ethics committee. The cadavers used were not more than seven days *post mortem*, had not been claimed by their relatives; and were sent for study and burial. The knees were dissected by means of a posterior access route. Individuals who did not present any signs of ligament injury or fracturing of the tibial plateau were excluded from the study.

The cadaveric specimens were prepared and the dissections were guided toward simulating the usual surgical procedure for PCL reconstruction. The cadaver was positioned

in horizontal dorsal decubitus and the lower limb that was studied was flexed. Using a viewer and with the aid of a PCL reconstruction guide marked out in millimeters, three 2.5-mm Kirschner guidewires were passed through at 0, 10 and 15 mm distal to the posterior crest of the tibia (Figs. 1 and 2). These wires were passed through anterolaterally to posteromedially. Dissection was performed immediately afterwards,

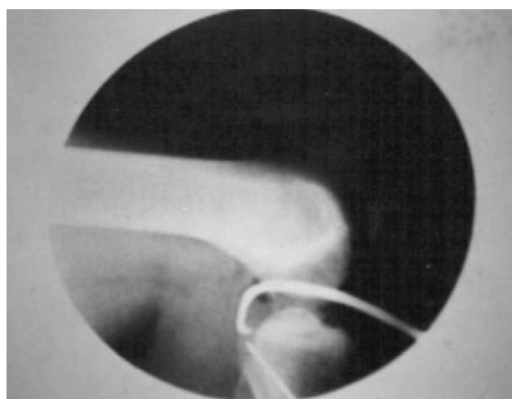


Fig. 1 – Passage of the 2.5-mm Kirschner guidewire using a guide marked out in millimeters.

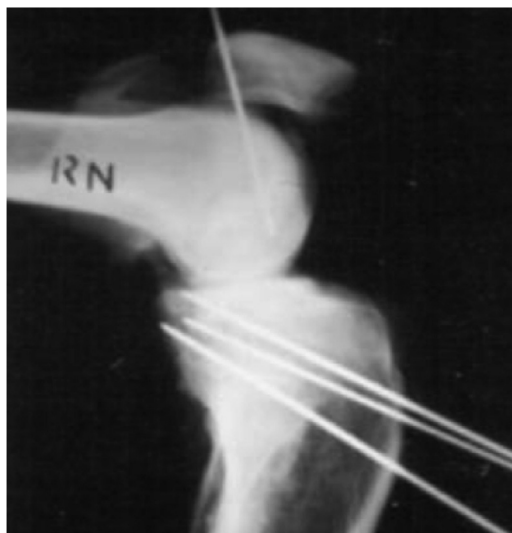

Fig. 2 – Positioning of the three Kirschner guidewires, respectively at 0, 10 and 15 mm distal to the posterior crest of the tibia.

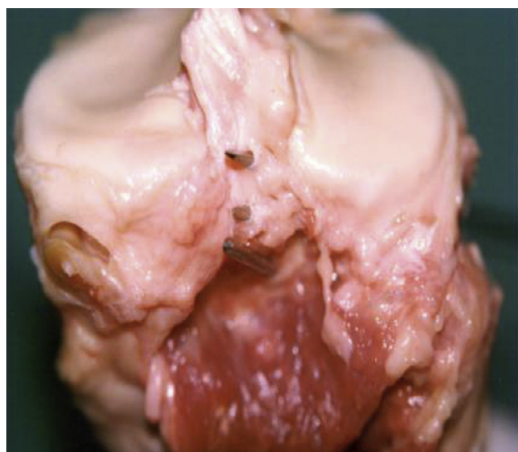

Fig. 3 – Image of the posterior region of the knee after dissection, which shows the exit point of the guidewires.




Fig. 4 – Measurement using a pachymeter between the center of tibial insertion of the PCL and the guidewires.

with removal of the anatomical specimen, and the location of the center of tibial insertion of the PCL was determined (Fig. 3).

The distances between the center of tibial insertion of the PCL and the posterior border of the tibia (CB) and between the center of tibial insertion of the PCL and the wires 1, 2 and 3 were measured using a pachymeter (CF1-CF2-CF3) (Fig. 4).

Results

In the dissected knees, we found the center of tibial insertion of the PCL at a distance of 1.09 ± 0.06 cm from the posterior border of the tibia. The distances between the PCL and the wires 1, 2 and 3 and the center or tibial insertion of the PCL were respectively 1.01 ± 0.08 , 0.09 ± 0.05 and 0.5 ± 0.05 cm (Table 1).

Discussion

Reconstruction of the PCL continues to be one of the major difficulties in knee surgery, and the surgical technique has gone through many modifications over the years.⁸ The traditional reconstruction method using an anteromedial tunnel results in a “killer turn” curvature of the graft that often gives rise to tearing or laxity.⁹ To reduce this angular phenomenon, some authors have used an inlay reconstruction technique or

Table 1 – Measurements using the technique shown in Fig. 4.

(CB) Distance between the center of tibial insertion of the PCL and the posterior border of the tibia.

(CF1-CF2-CF3) Distance between the center of tibial insertion of the PCL and the wires 1, 2 and 3

CB	1.09 ± 0.06 (1.19–0.98)
CF1	1.01 ± 0.08 (1.24–0.89)
CF2	0.09 ± 0.05 (0–0.15)
CF3	0.53 ± 0.05 (0.45–0.62)

anterolateral tunnels.^{10–12} There is no consensus regarding the center of tibial insertion in published papers on the anatomy of the PCL. Some have described its location as 1 cm from the joint surface, others as 1–1.5 cm along the posterior border of the tibia¹³ and yet others as 2–3 mm from the joint surface.¹⁴ In the reconstruction technique, with the aim of reproducing the anatomy of the tibial insertion of the PCL in the best way possible, some authors have indicated that the tibial guide should be positioned 7 mm from the posterior tip of the facet of the PCL.¹⁵ Other authors have advocated using a point between the joint surface and a point 4.6 mm distal to this because of the presence of several ligament bands in this area.¹⁶ Some studies have recommended using a tibial insertion point for the PCL that is immediately above the upper border of the tendon of the popliteal muscle.¹⁷ Another parameter for the exit location of the guidewire, which we found, was the intersection of the posterior cortical bone and the surface of the tibial plateau, in lateral-view radiographic evaluations of the knee, which has been shown to be a safe point.¹⁰

Our study aimed to investigate two fundamental points in constructing the tunnel for tibial reconstruction: anterolateral positioning, so as to diminish the “killer turn”; and positioning of the tibial guide such that the guidewire would reach a point 1 cm distal to the posterior border of the tibia. This was the location at which we found the center of tibial insertion of the PCL.

Conclusion

A guidewire exit point 10 mm distal to the posterior crest of the tibia was the best position for attempting to reproduce the anatomical center of the PCL.

Conflicts of interest

The authors declare no conflicts of interest.

REFERENCES

1. Veltri DM, Warren RF, Silver G. Complications in posterior cruciate ligament surgery. *Oper Tech Sports Med.* 1993;1(2):154–8.
2. Voos JE, Mauro CS, Wentz T, Warren RF, Wickiewicz TL. Posterior cruciate ligament: anatomy, biomechanics, and outcomes. *Am J Sports Med.* 2012;40(1):222–31.

3. Sherlock MF, Otto D. Antegrade tibial tunnel technique for posterior cruciate ligament reconstruction. *Arthroscopy*. 2008;24(11):1301-5.
4. Osti M, Tschann P, Künzel KH, Benedetto KP. Anatomic characteristics and radiographic references of the anterolateral and posteromedial bundles of the posterior cruciate ligament. *Am J Sports Med*. 2012;40(7):1558-63.
5. Ramos LA, de Carvalho RT, Cohen M, Abdalla RJ. Anatomic relation between the posterior cruciate ligament and the joint capsule. *Arthroscopy*. 2008;24(12):1367-72.
6. Moorman 3rd CT, Murphy Zane MS, Bansai S, Cina SJ, Wickiewicz TL, Warren RF, et al. Tibial insertion of the posterior cruciate ligament: a sagittal plane analysis using gross, histologic, and radiographic methods. *Arthroscopy*. 2008;24(3):269-75.
7. Ramos LA, Astur D, Novaretti JV, Ribeiro LM, Carvalho RT, Cohen M, et al. An anatomic study of the posterior septum of the knee. *Arthroscopy*. 2012;28(1):100-4.
8. Matava MJ, Sethi NS, Totty WG. Proximity of the posterior cruciate ligament insertion to the popliteal artery as a function of the knee flexion angle: implications for posterior cruciate ligament reconstruction. *Arthroscopy*. 2000;16(8):796-804.
9. Huang TW, Wang CJ, Weng LH, Chan YS. Reducing the "killer turn" in posterior cruciate ligament reconstruction. *Arthroscopy*. 2003;19(7):712-6.
10. Sekiya JK, West RV, Ong BC, Irgang JJ, Fu FH, Harner CD. Clinical outcomes after isolated arthroscopic single-bundle posterior cruciate ligament reconstruction. *Arthroscopy*. 2005;21(9):1042-50.
11. Dunlop DG, Woodnutt DJ, Nutton RW. A new method to determine graft angles after knee ligament reconstruction. *Knee*. 2004;11(1):19-24.
12. Abdalla RJ, Pacagnan AV, Loyola HA, Cohen M, Camanho GL, Forgas A. A proposal for a new tibial guide system for posterior cruciate ligament reconstruction. *Arthroscopy*. 2007;23(7):e1-4, 793.
13. Giron F, Cuomo P, Edwards A, Bull AM, Amis AA, Aglietti P. Double-bundle "anatomic" anterior cruciate ligament reconstruction: a cadaveric study of tunnel positioning with a transtibial technique. *Arthroscopy*. 2007;23(1):7-13.
14. Inderster A, Benedetto KP, Klestil T, Künzel KH, Gaber O. Fiber orientation of posterior cruciate ligament: an experimental morphological and functional study. Part 2. *Clin Anat*. 1995;8(5):315-22.
15. Harner CD, Xerogeanes JW, Livesay GA, Carlin GJ, Smith BA, Kusayama T, et al. The human posterior cruciate ligament complex: an interdisciplinary study. Ligament morphology and biomechanical evaluation. *Am J Sports Med*. 1995;23(6):736-45.
16. Takahashi M, Matsubara T, Doi M, Suzuki D, Nagano A. Anatomical study of the femoral and tibial insertions of the anterolateral and posteromedial bundles of human posterior cruciate ligament. *Knee Surg Sports Traumatol Arthrosc*. 2006;14(11):1055-9.
17. Racanelli JA, Drez Jr D. Posterior cruciate ligament tibial attachment anatomy and radiographic landmarks for tibial tunnel placement in PCL reconstruction. *Arthroscopy*. 1994;10(5):546-9.