


Bilateral Levofloxacin-Induced Achilles Tendon Rupture: An Uncommon Case Report and Review of the Literature

Marcos Edgar Fernández-Cuadros^{1,2} , Luz Otilia Casique-Bocanegra³, María Jesús Albaladejo-Florín¹, Sheila Gómez-Dueñas², Carmen Ramos-Gonzalez² and Olga Susana Pérez-Moro¹

¹Physical Medicine and Rehabilitation Department, Hospital Universitario Santa Cristina, Madrid, Spain. ²Physical Medicine and Rehabilitation Department, Fundación Hospital General de la Santísima Trinidad, Salamanca, Spain. ³Familiar Medicine, Gabinete Clínico Santa Clara, Zamora, Spain

Clinical Medicine Insights: Arthritis and Musculoskeletal Disorders
Volume 12: 1–5
© The Author(s) 2019
Article reuse guidelines:
sagepub.com/journals-permissions
DOI: 10.1177/1179544119835222



ABSTRACT: Since the introduction of Fluoroquinolones (FQ) in 1960s, these antibiotics have been used in airway and urinary tract infections, due to absorption, biodisponibility, posology and long half-life time properties. However, several reports state that FQ can cause tendinopathy and rupture. These adverse effects can occur within hours after initial treatment to up to 6 months after withdrawal. FQ-induced tendinopathy was first reported in 1983; since then more than 100 cases have been published. FQ usage can lead to complete tendon rupture and no more than 8 to 15 cases are reported worldwide. Most of rupture cases have been associated to corticoid use and rheumatic, vascular or renal disease. The purpose of this case report is to present the challenging diagnosis of a bilateral rupture of Achilles tendon in an old patient, because of the uncommon of the presentation and to review the current literature on such a debilitating condition.

KEYWORDS: Fluoroquinolones, achilles tendon, tendinopathy, rupture

RECEIVED: December 20, 2018. **ACCEPTED:** January 28, 2019.

TYPE: Case Report

FUNDING: The author(s) received no financial support for the research, authorship, and/or publication of this article.

DECLARATION OF CONFLICTING INTERESTS: The author(s) declared no potential conflicts of interest with respect to the research, authorship, and/or publication of this article.

CORRESPONDING AUTHOR: Marcos Edgar Fernández-Cuadros, Physical Medicine and Rehabilitation Department, Hospital Universitario Santa Cristina, Madrid 28009, Spain. Email: marcosefc@hotmail.com

Introduction

Since the introduction of fluoroquinolones (FQ) during the 1960s, these antibiotics have been used for several decades as effective antimicrobials in a great variety of infections.^{1,2} Fluoroquinolones absorption, biodisponibility, long half-life time properties, and its posology (once or twice a day) make them easy to use.³ Most FQ, mainly ciprofloxacin and levofloxacin are indicated for the treatment of airway and urinary tract infections.³

Despite their usefulness as antibiotics, several reports state that FQ can cause pathologic lesions in tendon tissue from tendinopathy to rupture.¹ These adverse effects can occur within hours after initial treatment to up to 6 months after discontinuing the use of the drugs.¹ Fluoroquinolones-induced tendinopathy was first reported in 1983,⁴ and since then, more than 100 cases have been reported in literature.⁵ In some cases, FQ usage can lead to complete rupture of the tendon and important disability with no more than 8 (secondary to FQ usage) to 15 cases (secondary to corticosteroids usage) reported worldwide.^{5–7} Most of the rupture cases have been associated with other risk factors such as corticoid use and rheumatic, vascular, or renal disease.^{2,5,6} Patient's age, male patient, and being an athlete are also considered predisposing risk factors for Achilles tendinopathy and rupture.^{2,5,6}

The purpose of this case report is to present the challenging diagnosis of a bilateral rupture of Achilles tendon in an old patient because of the uncommon nature of the presentation and to review the current literature on the diagnosis and management of such a debilitating condition.

Case Report

A 91-year-old man with a good past health condition went through 2 weeks of cough and sore throat, white sputum, and no fever. He was assisted to his general practitioner who, because of the symptoms, prescribed levofloxacin, 500 mg once a day for 10 days for a possible upper respiratory tract infection. By the seventh day of treatment, suddenly, the patient presented instability and impairment in walking. He visited the emergency room at the hospital, and due to such symptoms, he went under magnetic resonance imaging (MRI) evaluation, to discard stroke, although no other neurological symptoms were observed. The MRI showed no radiological signs of stroke; for that reason, a transient ischemic attack (TIA) was suspected, and only hyper-intensity of white substance at the protuberance probably secondary to small vessel disease was observed (Figure 1). After a 24-hour observation, the patient was discarded home only with walking instability. The patient continued stable from the neurological point of view, but he did not improve on gait, so in the first month follow-up evaluation, the neurologist referred him to a rehabilitation department.

In our evaluation at the rehabilitation department, the patient argued that suddenly, after 7 days of levofloxacin treatment, he was not be able to walk properly, although he did not feel any sharp pain. He was asked to walk over heels and toes, but he was not able to walk on toes. When we examined the feet, a gap sign was observed in both heels (Figure 2). He was asked to knee over a chair and the Thompson's test was performed, being positive in both feet (Figure 3). With the suspicion of bilateral Achilles tendon rupture, an ultrasound (US)



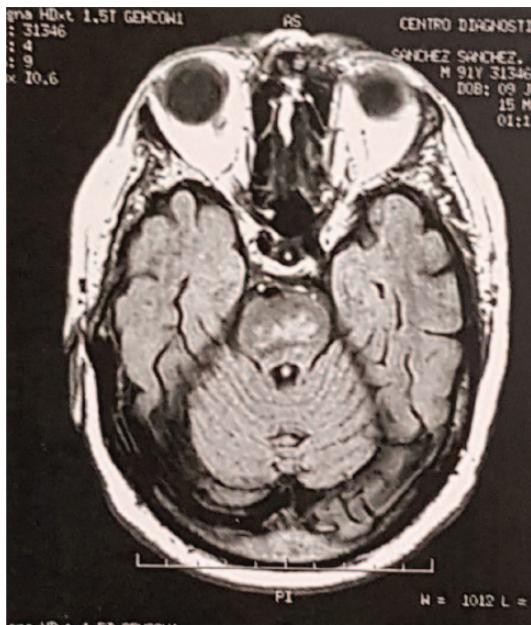

Figure 1. Magnetic resonance imaging performed at emergency room showed small hyper-intensity images on white substance at protuberance, probably of vascular origin due to small vessel disease. Sub-cortical and cortical atrophy of the brain were also observed. No signs of acute hemorrhagic or ischemic attack were observed.

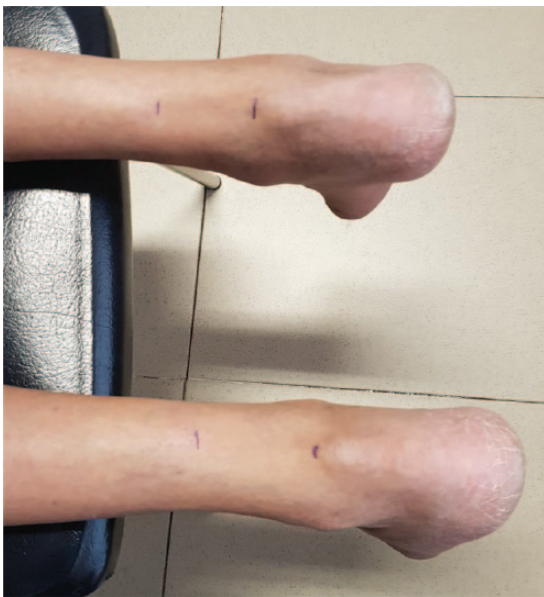


Figure 2. On clinical evaluation of the feet and ankles, a bilateral gap sign is observed on our patient (see blue marks on the skin).

scan was ordered immediately, and the results confirmed a total rupture of 5 cm of separation in the left heel and a 4.4 cm total gap in the right heel (Figure 4).

Because of patient's age and onset of symptoms (actually 4 months after rupture), surgical treatment was discarded, and a rehabilitation programme was started, consisting of active and assisted exercises to maintain range of movement, isometric exercises to increase strength of ankle's muscles other

than triceps sural, prescription of high heel shoes to retrain and to maintain gait with canes and progressive unassisted gait. After 4 weeks of treatment, the patient was able to walk just with the assistance of a cane and without any ankle-foot orthosis (Figure 5).

Discussion

Fluoroquinolones are a group of antibiotics with a broad spectrum of activity; they are therefore used more and more frequently in the management of infections.⁸ Levofloxacin is recommended for the management of community-acquired pneumonia, in doses of 500 mg, once or twice a day for up to 7 to 10 days,^{2,9,10} as it was prescribed in our case report.

The most common side effects produced by FQ are gastrointestinal (1%-5%), dermatological alterations (maculopapular reactions or skin rashes), photosensitivity (less than 2.5%) and neurological effects (headache and dizziness in 1%-2%).^{1,2} Tendinopathy can be a complication of treatment with FQ, and usually, it is linked with one or more synergistic factors.¹ Fluoroquinolones-induced tendinopathy is a very rare complication.^{5,9,10} Achilles tendinopathy and tendon rupture are adverse side effects of levofloxacin treatment well recognised in the literature, but its presentation is very uncommon.⁹ The incidence rate for tendinopathy is 0.1% to 0.01%, and the incidence rate for tendon rupture is less than 0.01%.⁹

Fluoroquinolones-induced tendinopathy was first reported in 1983, and since then, more than 100 cases have been reported in literature,⁵ Achilles tendon the being most affected. To date, there have been only a few cases of bilateral Achilles tendon rupture reported in literature (8 cases secondary to FQ usage and 15 cases secondary to corticosteroid usage), and they have been clearly associated with an identifiable cause, such as the use of corticosteroids (15 cases) or the use of levofloxacin (8 cases).^{2,5-7}

To the best of our knowledge, this is the first reported case of US-confirmed bilateral complete Achilles tendon rupture in a patient on levofloxacin treatment without exposure to corticosteroids.

Risk factors for tendinopathy include old age (older than 60 years), long-term lung disease, steroid treatment, and impaired renal function.^{5,8,9,11,12} Some reviews state that men are more likely to develop this side effect.^{5,13} Lado Lado et al¹⁰ state that the men/women ratio is 3:1 for FQ-induced tendinopathy.

Fluoroquinolones-induced tendinopathy can be presented in the form of tendinitis (inflammatory) or tendinosis (micro-tears) with an incidence of 2.4 per 10000 patients. Partial Achilles tendon rupture is still rarer, at a ratio of 1.2 per 10000 patients. However, neither complete tendon rupture nor bilateral tendon rupture occurs often enough to have an incidence in FQ-treated patients. More uncommon are the two conditions occurring together.^{6,14} Few published cases of tendon disorders have implicated levofloxacin, and tendon rupture has been described to occur in less than 4 per million levofloxacin prescriptions.^{15,16} There subsides the importance of this case report.

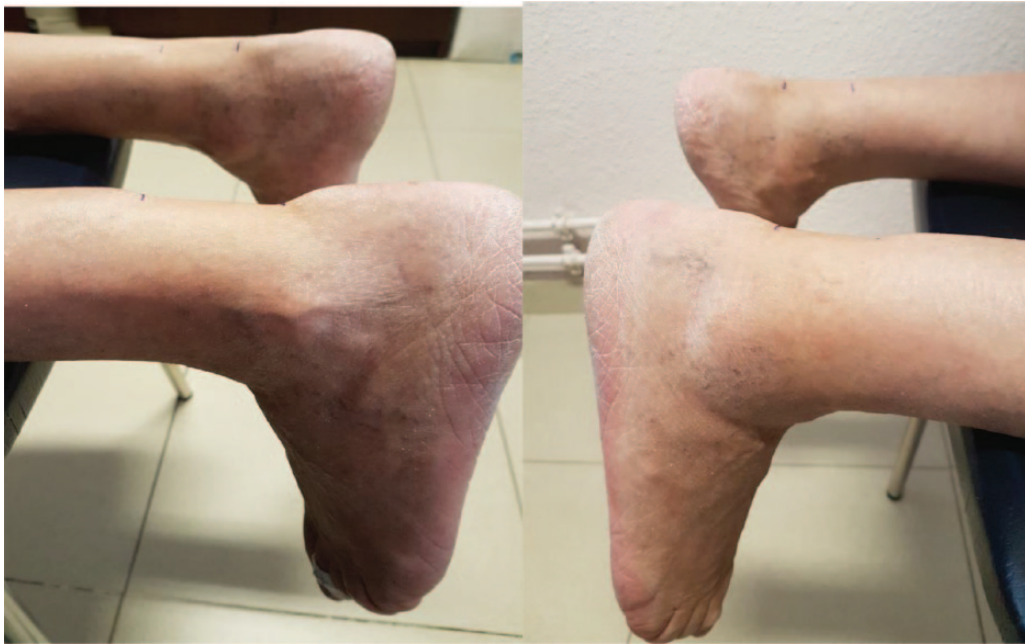

Figure 3. On clinical evaluation of Thompson's test, failure of plantar flexion after compression of the gastrocnemius muscle corresponds to a positive test, confirming tendon rupture, on both sides.

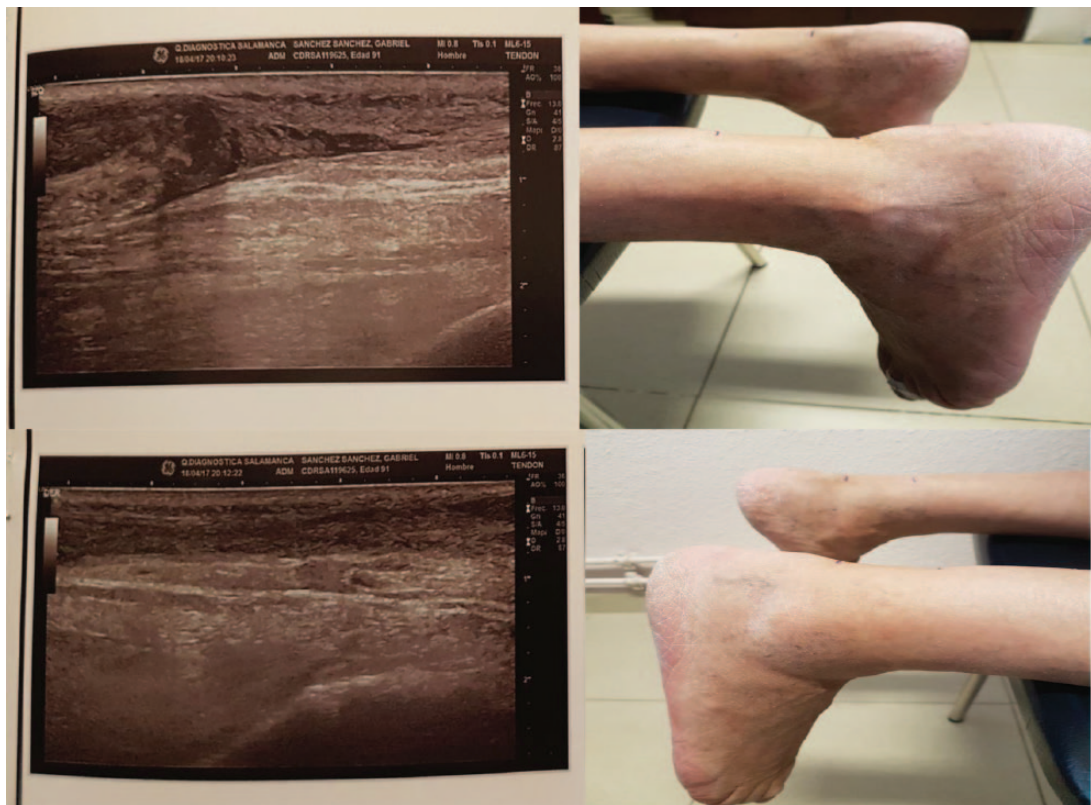


Figure 4. On ultrasound evaluation of Achilles tendon, a discontinuity of 5 cm on calcaneal insertion of left tendon (upper image), and a 4.4-cm discontinuity (lower image) on calcaneal insertion of right tendon confirms bilateral rupture. Ultrasound images show correlation with gap sign.

The most common FQ involved in induced Achilles tendinopathy compromises ciprofloxacin and pefloxacin; however, all commonly used FQ such as levofloxacin, ofloxacin, and

norfloxacin have been associated with this adverse event.⁵ Connelly et al⁸ argues that older FQ (norfloxacin, ofloxacin, and ciprofloxacin) are implicated in Achilles tendinopathy, and



Figure 5. After 4 weeks of rehabilitation programme, patient was able to walk unassisted, only with the help of a cane.

there are few reports on newer FQ, such as levofloxacin, as it was the case in our case report. It is believed that the different chemical structure of newer FQ (levofloxacin, ofloxacin and pefloxacin) makes them more toxic on cartilages and tendons than older FQ (norfloxacin, ciprofloxacin and enoxacin).^{10,17}

The most common tendon affected by FQ-induced tendinopathy and rupture is the Achilles tendon (90%-95% of cases)^{1,5} and almost 50% were bilateral.⁸ The weight-bearing role of the Achilles tendon is thought to be the reason for high preponderance of injury in this structure.^{8,18} Researchers have also reported adverse effects in other tendons, such as quadriceps, rotator cuff, peroneus brevis, adductor longus, triceps brachii, finger and thumb flexor tendons, to date some of them.^{1,5,8,16} In the case of Achilles tendinopathy, the injury may be bilateral, partial, or complete; and it is usually located 2 to 3 cm above a poorly vascularised area;¹⁶ however, in our case report, rupture occurred near calcaneal insertion, as it was observed by US. It has been postulated that 2% to 6% of Achilles tendon ruptures in patients over 60 years of age may be attributed to the use of FQ.^{2,19} Moreover, patients taking FQ have a four-fold increase of Achilles tendon rupture than general population, as based on a case-control study.²⁰

The underlying pathophysiology of FQ-induced tendinopathy is not entirely known,^{1,2,5,9,15} but it seems to be multifactorial.^{5,16} Studies have implicated ischaemic,⁷ toxic,^{1,15} and matrix-degrading processes as responsible for

this pathology.¹⁶ The chelating properties of FQ may disturb the integrity of the tendon,^{2,15} but it is also possible that mitochondria represent a biological target.²¹ Animal studies suggest that FQ induces toxic effect on collagen due to chelation of magnesium and free radicals formation with subsequent oxidative stress.⁹ Histological studies identified ultra-structural abnormalities in tenocytes and the presence of giant cells, similarly as in overuse injuries.⁹

Fluoroquinolones-induced tendinopathies occur at normal doses and treatment duration.⁸ However, the severity of tendinopathy appears to be proportional to the treatment duration.⁸ Ramirez et al⁷ state that the effect of FQ on tendons does not seem to be dose dependant, and Lewis and Cook¹ supports that although concentration of FQ on tendon tissue after standard dosing is unknown, FQ-induced tendinopathy was observed with daily doses ranging from 400 to 1200 mg.

Most researchers agree that the onset of symptoms may vary from 2 hours after FQ-intake to as far as 6 months. The mean time of symptom onset is about 2 weeks, and in 50% of cases, symptoms started within 6 to 7 days after drug intake,^{1,2,5,7,8,10,15,16} as it was in our case report. Fluoroquinolones-induced Achilles tendinopathy shows a direct cause-effect relationship, and tendinopathy usually appears during the first week of treatment, and rupture usually occurs during the next week, that is, 2 weeks after treatment.¹⁰ The major risk for tendon rupture on patients under FQ treatment is after 3 weeks.⁸ In our case report, rupture occurred at the seventh day of FQ treatment.

The most common symptom of FQ-associated tendinopathy is pain. This pain is usually of a sudden onset, and may be accompanied by acute signs of inflammation and swelling.¹ Achilles tendon rupture may be preceded by pain,¹ but half of tendon ruptures have been reported to occur without warning,¹³ as was in our case report. Then, the diagnosis is made by acute/sub-acute onset of pain and swelling over the tendon, together with a history of recent consumption of FQ and the absence of other obvious causes of tendinopathy.⁵ On clinical evaluation, at acute phase, a gap sign can be observed and palpated. After a time, however, edema can obliterate the gap sign, and palpation becomes unreliable.⁷ Several clinical tests include Simmonds' test, Matler's test,²² Thompson's test,²³ and Copeland's sphygmomanometer test.⁷ Thompson's test is the easiest to perform in the clinical setting, for it does not require special equipment and is non-invasive. Patients lie prone on the examination table while the physician squeezes the gastrocnemius muscle on the affected side. Failure of plantar flexion after compression is a positive test, confirming tendon rupture.⁷

If not suspected, FQ-induced tendon rupture may stay undiagnosed,⁷ since patients are treated by internal physicians (neurologist in our case report) rather than orthopaedic surgeons or rehabilitation specialists. It is very important to alert patients of FQ-induced complications such as tendinopathy and/or tendon rupture.⁵⁻⁷

Imaging diagnosis is not mandatory, but it can help in diagnosis, especially for visualising deep structures.⁵ Ultrasound is well described, but it is not widely used, since its results are operator dependant, and hardware is not readily available.⁷ Typical US findings of tendinopathy include thickened tendon with increased flow on colour Doppler examination.⁵ Magnetic resonance imaging can be clinically helpful in the presence of questionable diagnosis or for tear localisation during preoperative planning.⁷

In the case of levofloxacin-induced tendinopathy/rupture, treatment consists on immediately discontinuing FQ, resting the affected tendon and pain control.^{1,5,7,8} With mild tendinopathy, non-weight-bearing activity for 2 to 6 weeks may be adequate.⁸ In case of tendon rupture, patient should be referred to an orthopaedic surgeon, and the treatment options include immobilisation with casting or surgery for operative repair.^{1,5,7} For surgical solution, open reconstruction is the preferred technique. The effectiveness of minimal-invasive techniques are controversial to an extent that some authors consider that such techniques have no real place on surgical treatment.^{5,7}

Even with early diagnosis and appropriate management, tendinopathy heals slowly.⁸ Non-steroidal anti-inflammatory drugs, therapeutic US, and eccentric loading are the recommended methods for Achilles tendinopathy recovery.^{1,5,24} The mean recovery time for tendinopathy ranges from 3 weeks to 3 months, and complete recovery can be anticipated if the tendon is not ruptured. If a tendon rupture occurs, the mean recovery time ranges from 4.5 weeks to 6 months.⁸

Early and prolonged physical therapy is frequently required, particularly for elderly patients (over 60 years).⁸ Rehabilitation should involve a two-phase approach consisting of an initial phase of bracing and support to allow the tendon to recover from the chemical injury caused by FQ; and a second phase of progressive loading.¹

In our case report, due to age (91 years), time from onset of symptoms (4 months after tendon rupture), and a relative moderate level of physical activity, a non-operative approach was elected, placing the patient on walker boots. After a month of rehabilitation, patient was discharged with complete gait recovery and a use of a cane only for walking long distances.


Conclusions

Levofloxacin-induced tendinopathy and/or rupture are an uncommon complication associated usually to age and sex, as was in our case report. Initial treatment involves discontinuing the drug immediately. In the absence of pain, neurological pathologies may mimic the symptoms, making diagnosis a challenge. Recovery from FQ-induced tendinopathy/rupture is slow and may require longer and less-aggressive approach to success on the rehabilitation process. Prevention should include no concomitant use of FQ and steroids in older male patients; and, if these antibiotics are needed, adverse effects should be explained.

Author Contributions

MEF-C participated in the drafting of the manuscript, collection of medical history, physical examination, and prescription of rehabilitation protocol, review of the literature, discussion and translation of the article. SG-D and CR-G performed physical treatment. LOC-B, MJA-F and OSP-M participated in the review and approval of the manuscript.

ORCID iD

Marcos Edgar Fernández-Cuadros  <https://orcid.org/0000-0001-6153-9075>

REFERENCES

- Lewis T, Cook J. Fluoroquinolones and tendinopathy: a guide for athletes and sports clinicians and a systematic review of the literature. *J Athlet Train.* 2014;49:422-427.
- Morandé SC, de Rada Lorente PD, Clemente JD, Muñoz LR, Quetglas EG. Bilateral Achilles tendon rupture secondary to levofloxacin. *Rev Esp Cir Ortop Traumatol (English Edition).* 2010;54:238-240.
- Olyphant CM, Green GM. Quinolones: a comprehensive review. *Am Fam Phys.* 2002;65:455-464.
- Bailey RR, Kirk JA, Peddie BA. Norfloxacin-induced rheumatic disease. *N Z Med J.* 1983;96:590
- Tam PK, Ho CT. Fluoroquinolone-induced Achilles tendinitis. *Hong Kong Med J.* 2014;20:545-547.
- Garg S, Thilagarajah M. Bilateral rupture of Achilles tendon (bilrat) without predisposing systemic disease or steroid use: a case report and review of the literature. *Int J Orthop Surg.* 2008;13:1-3.
- Ramirez MA, Richardson LC. Pulmonary embolism associated with spontaneous bilateral Achilles tendon rupture. *J Foot Ankle Surg.* 2007;46:283-287.
- Connelly S, Bayliff C, Mehta S. Levofloxacin-induced bilateral Achilles tendinopathy. *Canad J Hosp Pharm.* 2002;55:575.
- Haddow LJ, Chandra Sekhar M, Hajela V, Gopal Rao G. Spontaneous Achilles tendon rupture in patients treated with levofloxacin. *J Antimicrob Chemother.* 2003;51:747-748.
- Lado Lado FL, Rodríguez Moreno C, Velasco González M, Durán Parrondo C, Moar Calvo B. Rotura parcial bilateral aquilea asociada a levofloxacino. *An Med Interna.* 2005;22:28-30.
- Lewis JR, Gums JG, Dickensheets DL. Levofloxacin-induced bilateral Achilles tendonitis. *Ann Pharmacother.* 1999;33:792-795.
- Harrell RM. Fluoroquinolone-induced tendinopathy: what do we know? *South Med J.* 1999;92:622-625.
- Khalilq Y, Zhanel GG. Fluoroquinolone-associated tendinopathy: a critical review of the literature. *Clin Infect Dis.* 2003;36:1404-1410.
- Gottschalk AW, Bachman JW. Death following bilateral complete Achilles tendon rupture in a patient on fluoroquinolone therapy: a case report. *J Med Case Repor.* 2009;3:1.
- Melhus Å, Apelqvist J, Larsson J, Eneroth M. Levofloxacin-associated Achilles tendon rupture and tendinopathy. *Scand J Infect Dis.* 2003;35:768-770.
- Gold L, Igra H. Levofloxacin-induced tendon rupture: a case report and review of the literature. *J Am Board Fam Pract.* 2003;16:458-460.
- Mng D. Meyler's side effects of drugs. *Ann.* 1996;3:1898-1901.
- Greene BL. Physical therapist management of fluoroquinolone-induced Achilles tendinopathy. *Phys Ther.* 2002;82:1224-1231.
- Medrano San Ildefonso M, Mauri Llerda JA, Bruscas Izu C. Tendinopatías por fluoroquinolonas. *An Med Interna.* 2007;24:227-230.
- Corrao G, Zambon A, Bertù L, et al. Evidence of tendinitis provoked by fluoroquinolone treatment. *Drug Safte.* 2006;29:889-896.
- Bernard-Beaubois K, Hecquet C, Hayem G, Rat P, Adolphe M. In vitro study of cytotoxicity of quinolones on rabbit tenocytes. *Cell Biol Toxicol.* 1998;14:283-292.
- Cruz M, Jordan S, Bolgla L. Achilles tendón ruptura. *J Orthopaed Sport Phys Ther.* 2013;43:105.
- Metz R, Verleisdonk EJM, van der Heijden GJMG, Clevers GJ, Hammacher ER, Verhofstad MH, et al. Acute Achilles tendon rupture: minimally invasive surgery versus nonoperative treatment with immediate full weightbearing – a randomized controlled trial. *Ame J Spor Med.* 2008;36:1688-1694.
- Carmont MR, Maffulli N. Achilles tendon rupture following surgical management for tendinopathy: a case report. *BMC Musculoskel Dis.* 2007;8:19.