

CASE REPORT

Rare cause of acute neck hematoma

Doaa Alfraidy¹ | Hadeel Helmi¹  | Maha Alamodi Alghamdi^{1,2} | Areej Bokhari¹ | Abdulaziz Alsaif¹

¹Department of Surgery, King Khalid University Hospital, King Saud University, Riyadh, Saudi Arabia

²King Khalid University, Abha, Saudi Arabia

Correspondence

Hadeel Helmi, Department of Surgery, King Khalid University Hospital, King Saud University, Riyadh, Saudi Arabia.
Email: hadeelhelmi@gmail.com

Abstract

Emergencies in endocrine surgery are rare. Acute neck hematoma may result from recent surgery or spontaneous as with ruptured thyroidal cyst, thyroidal vessel, or parathyroid adenoma. We are reporting a case of acute neck hematoma caused by a ruptured of parathyroid adenoma, which required urgent surgical intervention.

KEYWORDS

endocrine emergencies, neck hematoma, parathyroid adenoma

1 | INTRODUCTION

Emergencies in endocrine surgery are rare, particularly in patients without a recent surgical history. These emergencies may include hypercalcemic crisis, thyroid storm, and neck hematoma. Neck hematomas occur more frequently following surgery for thyroid disorders. In the literature, case reports exist involving patients with spontaneous hematoma that develop due to rupture of thyroidal vessels, rupture of thyroid cyst, or ruptured parathyroid adenoma.¹ This paper describes a case of spontaneous rupture of a parathyroid adenoma presenting with acute neck hematoma.

2 | CASE PRESENTATION

The patient is a 59-year-old gentleman, known to have type two diabetes mellitus, hypertension, and chronic kidney disease (not on dialysis), who was referred to our clinic in December 2018 as a case of asymptomatic hyperparathyroidism after being found to have hypercalcemia on routine laboratory work. His corrected calcium level was 2.66 mmol/L (normal range 2.10-2.55 mmol/L). He was sent for further investigations with follow-up appointment. Ultrasound (US) at that time revealed a large well-defined hypoechoic nodular lesions seen related inferior to the lower

pole of the left thyroid lobe with internal vascularity traced by color Doppler, measuring about $2.2 \times 1.9 \times 5$ cm in its maximum dimensions, most likely representing enlarged left inferior parathyroid gland (Figure 1). This parathyroid adenoma appeared entirely solid on US, and there was no cystic component. His serum parathyroid hormone level was 95.690 pmol/L (normal range 1.600-6.900 pmol/L).

Prior to his outpatient clinic visit, he presented to the ER with sudden-onset neck pain of 12-hour duration, associated with enlarging neck swelling, odynophagia, and hoarseness of voice. The patient denied any history of recent neck trauma, sudden neck movement, or strain before developing these symptoms. He remained vitally stable throughout initial assessment and was able to maintain his airway. On physical examination, there was a large, diffuse, tense neck hematoma, with ecchymosis extending from the angle of the mandible to the mid-chest (Figure 2). The swelling was mildly tender to palpation and, with repeated examinations, found to be increasing in size. No thrill or bruits could be appreciated over the swelling. X-rays were done and showed soft tissue swelling and deviation of the trachea to the right side (Figure 3). Bedside carotid duplex was done which revealed intact carotid arteries and internal jugular vein bilaterally, with no communication with the hematoma ruling out vascular origin of this hematoma. Computed tomography (CT) scan of neck and upper chest

FIGURE 1 Ultrasound image showing enlarged parathyroid gland inferior to the left thyroid lobe

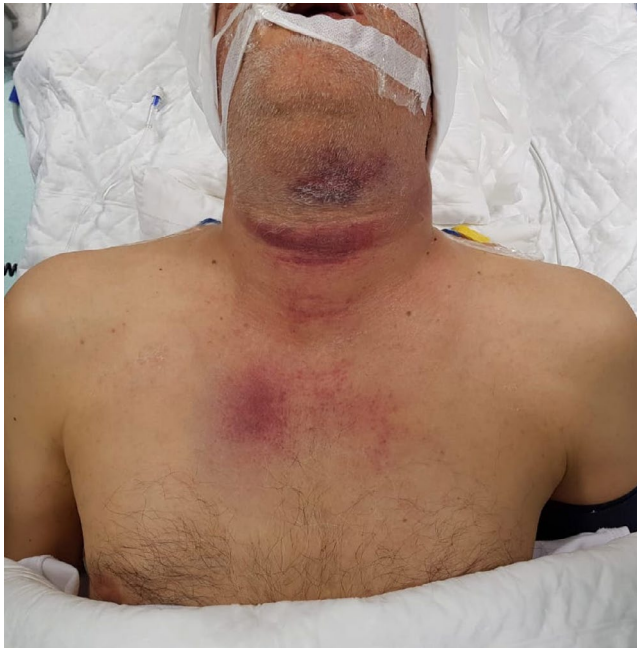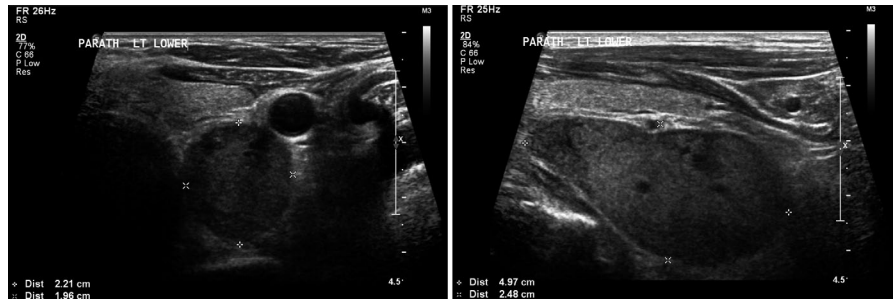


FIGURE 2 Physical examination findings including neck swelling and ecchymosis

with intra-venous contrast was done for better assessment and showed “a large hyperechoic hypervascular left paratracheal mass measuring 4 × 4 × 3 cm posterior to the

thyroid consistent in location to the parathyroid adenoma previously seen on US during clinic investigation” (Figure 4). Moreover, this lesion showed “a small area of hypodensities with mild superior indistinct margin surrounded by hyperdense fluid collection and fat stranding occupying the retropharyngeal, left carotid, and visceral spaces with extension into the superior mediastinum. It caused mass effect and shifting of the trachea to the right side. Aortic arch, visualized part of the descending aorta, common carotid, and internal carotid were patent with no signs of dissection.” These findings were suggestive of ruptured parathyroid adenoma with neck hematoma.

It was decided to take the patient to the operating room, and under general anesthesia, the patient underwent urgent neck exploration. Upon exploring the neck, a large amount of blood was found. Active bleeding was evident, and approximately 150 cc of blood with organized clots was evacuated. It was soon realized that the source of bleeding was coming from a ruptured left lower parathyroid adenoma.

The bleeding was controlled, the left lower parathyroid gland was dissected, and the pedicle was clipped and cut, delivering the parathyroid gland out. After removing the bleeding gland, the recurrent laryngeal nerve was seen intact throughout all of its course. Gross examination of the specimen showed a soft tissue mass ~5 cm in size, blue in color (diseased parathyroid adenoma) (Figure 5). Before closure,

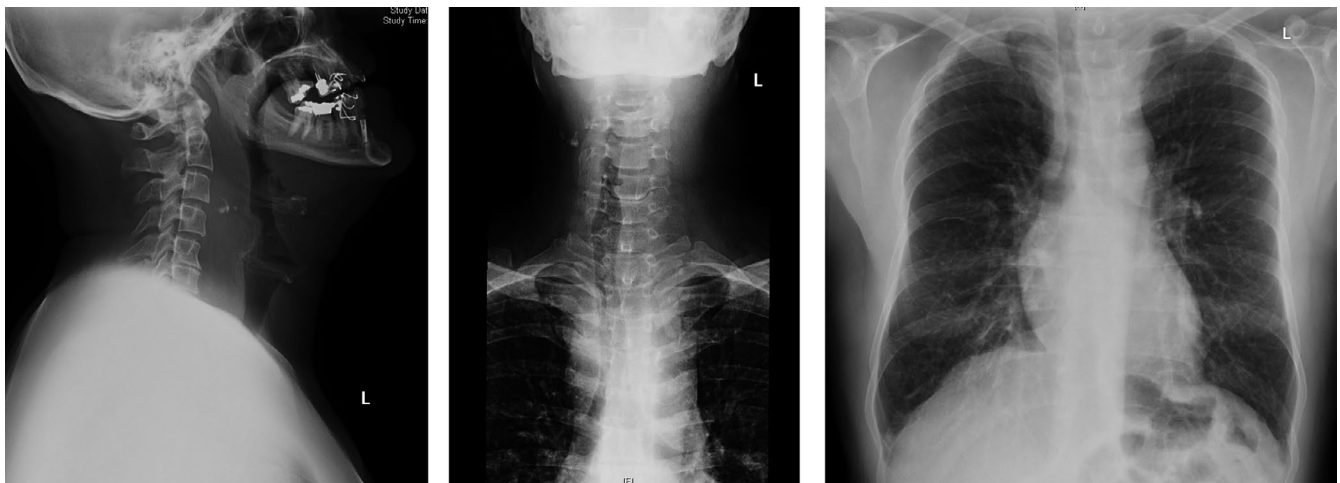


FIGURE 3 X-ray findings. A, Soft tissue swelling on lateral neck x-ray. B, AP view of neck x-ray. C, AP view of chest x-ray showing tracheal deviation

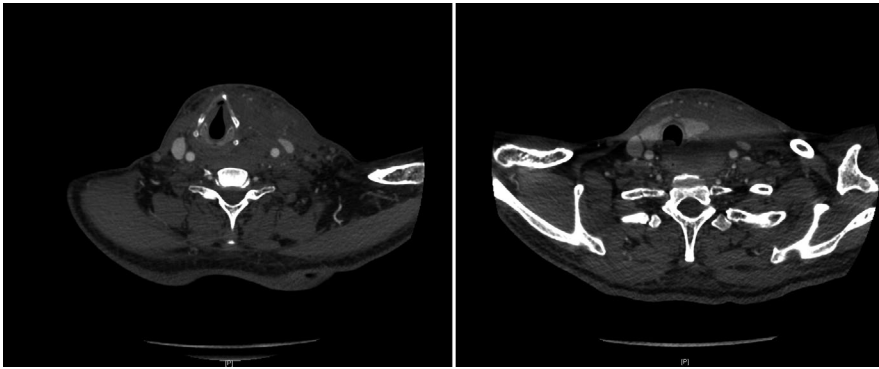


FIGURE 4 CT scan showing massive neck hematoma

it was clear to us that the blood managed to trickle between muscle planes laterally forming a diffuse hematoma between the muscle planes.

The patient was successfully extubated after the procedure and was transferred to the intensive care unit for close observation of the airway and correction of electrolyte imbalances. Postoperatively, the patient tolerated the procedure well and was started on diet with no dysphagia or hoarseness. Parathyroid hormone and serum calcium levels normalized after the surgery, and histopathology confirmed the presence of tissue consistent with parathyroid adenoma with focal ischemic necrotic areas.

3 | DISCUSSION

Parathyroid adenoma is the most common cause of primary hyperparathyroidism. Patients can present with generalized fatigue, bone pain, and recurrent kidney stones, although they are most commonly diagnosed on routine investigations in

asymptomatic patients. To date, around 35 cases of ruptured parathyroid adenomas are found in the literature, dating back to the 1900s.²⁻⁸ These cases include rupture into both the neck or/and chest in cases of mediastinal ectopic parathyroid glands.^{1,3,9} Although rare, this condition can be lethal with risk of developing airway compromise requiring immediate intervention. Hemodynamic instability may ensue due to massive bleeding or compression of the airway. In the absence of compromised airway or hemodynamic instability, cases have been successfully treated conservatively.² Surgical excision was postponed to avoid recurrence and complications associated with emergency intervention. Although the optimal time for surgery has not been clearly determined, in the literature it ranges from several days to few months⁴, with one paper claiming the ideal timing for surgical intervention to be 3 months from the acute insult. In their approach, they compared numerous patients who presented with ruptured parathyroid adenoma and were operated at various stages: 3 days, 1 month, 3 months, and 4 months from time of presentation. In their experience, delayed surgical intervention was associated with improved outcome. One patient with early intervention was complicated by injury to the recurrent laryngeal nerve while the other had incomplete resection of the affected parathyroid gland leading to recurrent hypercalcemia years later.² Recurrent hyperparathyroidism can occur following surgery for another reason. Due to rupture, dissemination of the tumor cells in the neck or mediastinum may be followed by growth and development of parathyroid nodules. This phenomenon has been referred to as parathyromatosis.¹⁰ For this reasons, it has been advised that patients should be followed up for prolonged duration in time.

Although our patient was recently diagnosed with parathyroid adenoma, the majority of cases reported in the literature are of patients who presented with acute neck or mediastinal hematoma in the absence of known or diagnosed parathyroid disease. Hence, a high index of suspicion is needed for proper and rapid identification of this condition. Ruptured parathyroid adenoma should be one of the differential diagnoses in patients presenting with acute neck pain, neck swelling, and hoarseness, especially in the presence the following clinical triad of acute neck swelling, chest, or neck ecchymosis and hypercalcemia.⁵

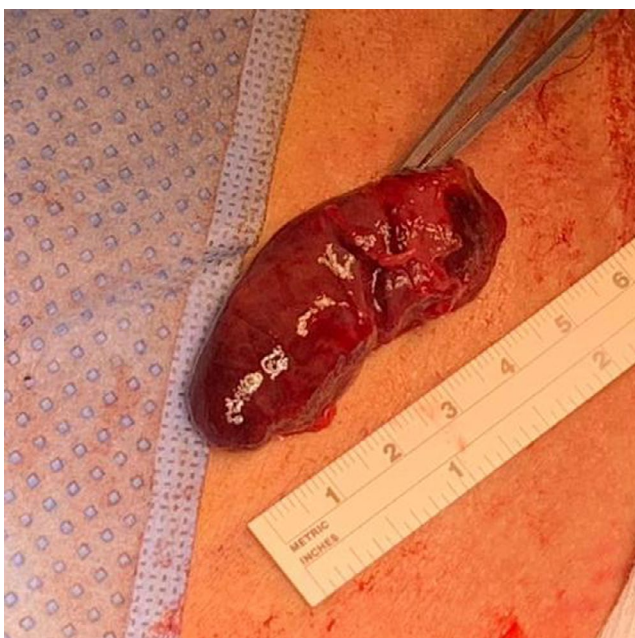

FIGURE 5 Excised parathyroid adenoma

CONFLICT OF INTEREST

None declared.

AUTHOR CONTRIBUTION

All authors contributed significantly and equally to the preparation of this case report.

ORCID

Hadeel Helmi  <https://orcid.org/0000-0001-7459-6861>

REFERENCES

1. Tonerini M, Orsitto E, Fratini L, et al. Cervical and mediastinal hematoma: presentation of an asymptomatic cervical parathyroid adenoma: case report and literature review. *Emerg Radiol.* 2004;10(4):213-215.
2. Chaffanjon PCJ, Chavanis N, Chabre O, Brichon PY. Extracapsular Hematoma of the Parathyroid Glands. *World J Surg.* 2003;27:14-17.
3. Yoshimura N, Mukaida H, Mimura T, et al. A case of an acute cervicomedastinal hematoma secondary to the spontaneous rupture of a parathyroid adenoma. *Ann Thorac Cardiovasc Surg.* 2014;20(Supplement):816-820.
4. An L, Ji T, Li L. Diffuse hematoma caused by spontaneous rupture of a parathyroid adenoma: a case report. *Braz J Otorhinolaryngol.* 2017; <https://doi.org/10.1016/j.bjorl.2017.06.006> [Epub ahead of print]
5. Merante-Boschin I, Fassan M, Pelizzo MR, Ide EC, Rugge M. Neck emergency due to parathyroid adenoma bleeding: a case report. *J Med Case Rep.* 2009;3:7404.
6. Shinomiya H, Otsuki N, Takahara S-I, et al. Parathyroid adenoma causing spontaneous cervical hematoma: two case reports. *BMC Res Notes.* 2015;8:726.
7. Rehman HU, Markovski M, Khalifa A. Spontaneous cervical hematoma associated with parathyroid adenoma. *CMAJ.* 2010;182(13):E632.
8. Kihara M, Yokomise H, Yamauchi A, Irie A, Matsusaka K, Miyauchi A. Spontaneous rupture of a parathyroid adenoma presenting as a massive cervical hemorrhage: report of a case. *Surg Today.* 2001;31(3):222-224.
9. Whitson BA, Heckmann R, Manivel C, Anne Lassig A, D'Cunha J. Acute airway compromise from a hemorrhagic posterior cervical-mediastinal mass: rare presentation of a parathyroid adenoma. *J Thorac Dis.* 2011;3(1):68-70.
10. Sim I-W, Farrell S, Grodski S, Jung C, Ng KW. Parathyromatosis following spontaneous rupture of a parathyroid adenoma: natural history and the challenge of management. *Intern Med J.* 2013;43(7):819-822.

How to cite this article: Alfraidy D, Helmi H, Alamodi Alghamdi M, Bokhari A, Alsaif A. Rare cause of acute neck hematoma. *Clin Case Rep.* 2019;7:1378–1381. <https://doi.org/10.1002/ccr3.2248>