

Trauma and reconstruction

## Two-staged anterior urethroplasty using skin flap outside the scrotum: A case report

Ryosuke Suda, Takahiko Mitsui<sup>\*</sup>, Masanari Fukasawa, Satoru Kira, Norifumi Sawada, Masayuki Takeda

Department of Urology, University of Yamanashi Graduate School of Medical Sciences, Chuo-city, Yamanashi, Japan

### ARTICLE INFO

#### Keywords:

Urethroplasty  
Skin flap  
Urethral stricture  
Staged

### ABSTRACT

A thirty-eight-year-old man presented with acute urinary retention due to a long complicated strictures between the meatus and the bulbar urethra. During the first surgery, in addition to the penile skin flap, the flap of the incised skin at 10mm outside the scrotum strip-like tissue was moved medially and sutured onto the incised urethra. After 12 months of the first surgery, we performed the urethroplasty from the bulbar urethra to the meatus. Postoperatively, the patient voided without complications. Thus, this technique using a skin flap outside the scrotum is effective in long complicated urethral strictures.

### Introduction

Urethroplasty using oral mucosal graft is performed to treat complicated urethral strictures.<sup>1</sup> However, the management of extremely long urethral strictures has not been established yet, and several surgical procedures using tools, techniques, and grafts are performed widely.<sup>2</sup> We report a case of two-staged urethroplasty using a skin flap outside the scrotum strip-like tissue, in addition to penile skin flap, instead of oral mucosa grafts.

#### Case presentation

A thirty-eight-year-old man with acute urinary retention was referred to our hospital. Since a severe urethral stricture was identified, a catheter was placed by suprapubic cystostomy. The patient had a medical history of untreated sexually transmitted disease (STD) several years back. Physical examination revealed induration and discharge of pus from the right side of the scrotum. Abdominal computed tomography (CT) and pelvic magnetic resonance imaging (MRI) indicated broad inflammation at the perineum including the right testis to the scrotum. The urine culture was negative for *Neisseria gonorrhoea* and *Chlamydia trachomatis*. Based on these findings, we diagnosed that the urethral stricture was caused by infections including STD, and antibiotic therapy using ceftriaxone was initiated. After 6 months of treatment, a retrograde urethrography revealed severe urethral strictures between the

meatus and the bulbar urethra (Fig. 1). Considering the long complicated stenosis, we planned staged urethroplasty using a skin flap at 10 mm outside the scrotum as a strip-like tissue instead of the oral mucosa (Fig. 2A).

In the first stage, the skin was incised on the ventral side of the penis, and the scrotum and urethra were opened from the meatus to the bulbar urethra. Then, we incised 10 mm on the outer sides of the scrotum as a pedicled flap of strip-like tissue with blood supply from the ventral and dorsal skin for urethroplasty. The flaps were moved medially to the urethral side (Fig. 2B). Both sides of the opened urethra were sutured to the end of the flap (Fig. 2C).

At 12 months after the first surgery, identifying good condition of the grafts (Fig. 2D), the second-staged procedure was performed. We performed urethroplasty with tubularization around 24 Fr urethral catheter in two layers using absorbable monofilament sutures. After urethroplasty, skin was closed with subcutaneous and cutaneous sutures (Fig. 3A and B) and catheter by suprapubic cystostomy was finally placed. At 9 days after the surgery, the catheter was removed, and the patient started to void without any complication.

At 8 months after urethroplasty, the appearance of the surgical site was found to be favorable (Fig. 3C). Uroflowmetry showed a good flow rate without any significant residual urine volume. Also, the patient did not complain of any lower urinary tract symptoms. At 18 months after the surgery, intraurethral hair growth was not identified under urethroscopy (Fig. 3D) and the patient voided without any complaints.

<sup>\*</sup> Corresponding author. Department of Urology, University of Yamanashi Graduate School of Medical Sciences, 1110 Shimokato, Chuo-city, Yamanashi, 409-3898, Japan.

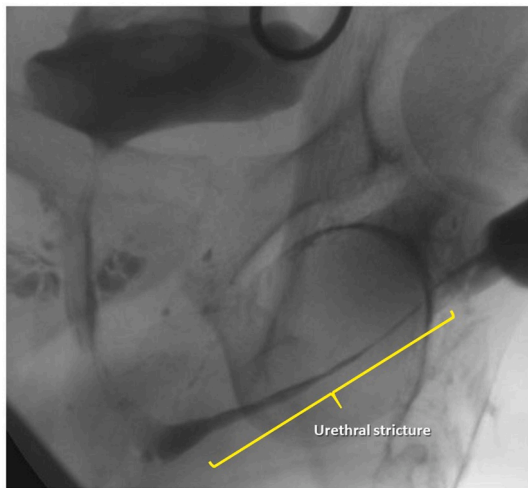
E-mail address: [tmitsui@yamanashi.ac.jp](mailto:tmitsui@yamanashi.ac.jp) (T. Mitsui).

<https://doi.org/10.1016/j.eucr.2020.101227>

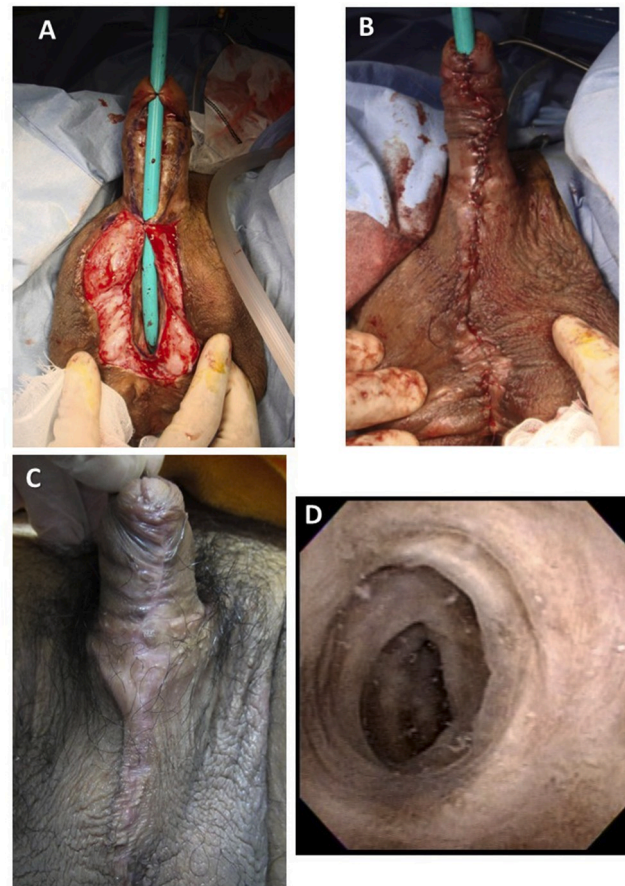
Received 21 April 2020; Received in revised form 22 April 2020; Accepted 23 April 2020

Available online 24 April 2020

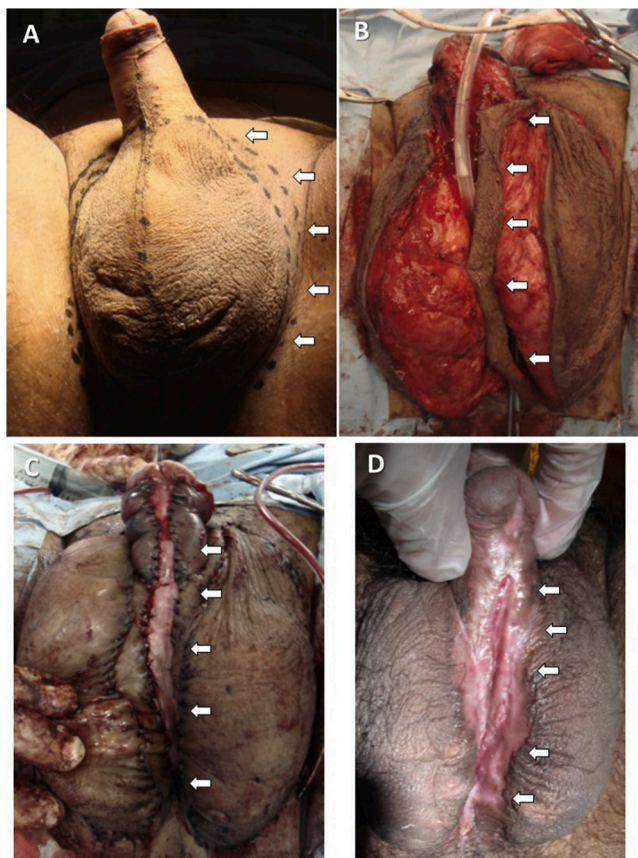
2214-4420/© 2020 Published by Elsevier Inc. This is an open access article under the CC BY-NC-ND license (<http://creativecommons.org/licenses/by-nc-nd/4.0/>).



**Fig. 1.** Retrograde urethrography. There was a severe urethral stricture between the meatus and the bulbar urethra.



**Fig. 3.** The second-staged urethroplasty. (a)Urethroplasty to wrap around the 24Fr urethral catheter. (b)Appearance just after urethroplasty. (c)Appearance of the surgical site was favorable at 8 months after urethroplasty. (d)Appearance of urethroscopy at 18 months after urethroplasty.



**Fig. 2.** The first-staged urethroplasty. (a) The dashed line represents the incision line. The white arrows show skin flaps. (b) The skin flap (white arrows) at 10 mm outside of the scrotum was moved medially to the urethral side as shown by the arrow. (c) Both sides of the opened urethra were sutured to the end of the flap (penile skin flap and the flap of the incised skin at 10 mm outside the scrotum). (d) Good condition of the grafts after the first-stage surgery.

**Discussion**

Urethroplasty for complicated urethral strictures with stenosis at multiple sites is a difficult and challenging procedure for most urologists because of a meager experiences.<sup>2</sup> Recently, urethroplasty using buccal mucosa or penile skin flaps as grafts has been widely adopted in clinical settings and it has proven to be successful.<sup>3</sup> Although several cases of urethroplasty using these grafts have been reported, most urologists have experienced heterogeneity among a large number of urethroplasties.<sup>2</sup> In our case, involving complicated urethral strictures with long and multiple sites of stenosis, we succeeded in performing two-staged urethroplasty using a skin flap outside the scrotum as a strip-like tissue in addition to the penile skin flap.

In general, grafts used for urethroplasty include skin, bladder mucosa, and oral mucosa. Among these, the oral mucosa is relatively easy to prepare and is cosmetically excellent. There are several other advantages, such as the absence of hair growth and ease of engrafting because of a thin submucosa layer.<sup>4</sup> However, in the presence of long stenosis, oral mucosa cannot be used because of the limitation in the graft size. We were also concerned about the survival of free grafts because of the extremely long urethral strictures. Considering the length for replacement of the urethral mucosal defect in our case, we considered that pedicled skin flaps could be of good choices. Furthermore, pedicled flaps have a blood supply to the grafts which could induce better engraftment rate than the free flaps. However, in the case of urethroplasty using skin flap, although it is easy to harvest grafts and they show a good survival,

there is a risk of hair growth leading to problems of the lower urinary tract later. Considering this issue, we used hairless skin, which was located outside the scrotum as pedicled skin flaps for urethroplasty. Therefore, we decided to use pedicled flaps of skin at 10 mm outside the scrotum in addition to the penile skin. Fortunately, we did not find hair growth after the first-stage surgery (Fig. 2D) or under cystoscopy after urethroplasty (Fig. 3D). For hair growth after urethroplasty, we plan to perform laser ablation of the hairs under cystoscopy.<sup>4</sup>

In a systematic review of various surgical procedures, it was reported that the success rate of a one-staged urethroplasty was less than that of the two-staged procedure.<sup>5</sup> In our case, we were concerned about the condition of the grafts for urethroplasty because of the long flaps of urethral strictures with multiple sites of stenosis. In fact, we confirmed a favorable condition of the grafts after the first-stage surgery (Fig. 2D). Furthermore, after one and a half years of flow-up, neither the patient complained of any difficulty in voiding nor could we identify urethral stricture under cystoscopy and uroflowmetry.

### Conclusion

We have succeeded in performing a two-staged urethroplasty procedure using a skin flap outside the scrotum in addition to the penile skin. This technique using a skin flap outside the scrotum was feasible for the management of long complicated urethral strictures.

### Funding

This research did not receive any specific grant from funding

agencies in the public, commercial, or not-for-profit sectors.

### Consent

Consent has been obtained for publication in Japanese language.

### Declaration of competing interest

No competing financial interests exist.

### Acknowledgment

None.

### References

1. Mangera A, Patterson JM, Chapple CR. A systematic review of graft augmentation urethroplasty techniques for the treatment of anterior urethral strictures. *Eur Urol.* 2011;59:797–814.
2. Zimmerman WB, Santucci RA. A simplified and unified approach to anterior urethroplasty. *Nat Rev Urol.* 2010;7:386–391.
3. Horiguchi A. Substitution urethroplasty using oral mucosa graft for male anterior urethral stricture disease: current topics and reviews. *Int J Urol.* 2017;24:493–503.
4. Beiko D, Pierre SA, Leonard MP. Urethroscopic holmium:YAG laser epilation of urethral diverticular hair follicles following hypospadias repair. *J Pediatr Urol.* 2011;7:231–232.
5. Cheng L, Li S, Wang Z, Huang B, Lin J. A brief review on anterior urethral strictures. *Asian J Urol.* 2018;5:88–93.