

Mutated *CTSF* in adult-onset neuronal ceroid lipofuscinosis and FTD

OPEN

Julie van der Zee, PhD*
Peter Mariën, MD, PhD*
Roeland Crols, MD*
Sara Van Mossevelde,
MD
Lubina Dillen, PhD
Federica Perrone, MSc
Sebastiaan Engelborghs,
MD, PhD
Jo Verhoeven, MD, PhD
Tine D'aes, MA
Chantal Ceuterick-De
Groote, PhD
Anne Sieben, MD
Jan Versijpt, MD, PhD
Patrick Cras, MD, PhD
Jean-Jacques Martin,
MD, PhD
Christine Van
Broeckhoven, PhD,
DSc

ABSTRACT

Objective: To investigate the molecular basis of a Belgian family with autosomal recessive adult-onset neuronal ceroid lipofuscinosis (ANCL or Kufs disease [KD]) with pronounced frontal lobe involvement and to expand the findings to a cohort of unrelated Belgian patients with frontotemporal dementia (FTD).

Methods: Genetic screening in the ANCL family and FTD cohort (n = 461) was performed using exome sequencing and targeted massive parallel resequencing.

Results: We identified a homozygous mutation (p.Ile404Thr) in the Cathepsin F (*CTSF*) gene cosegregating in the ANCL family. No other mutations were found that could explain the disease in this family. All 4 affected sibs developed motor symptoms and early-onset dementia with prominent frontal features. Two of them evolved to akinetic mutism. Disease presentation showed marked phenotypic variation with the onset ranging from 26 to 50 years. Myoclonic epilepsy in one of the sibs was suggestive for KD type A, while epilepsy was not present in the other sibs who presented with clinical features of KD type B. In a Belgian cohort of unrelated patients with FTD, the same heterozygous p.Arg245His mutation was identified in 2 patients who shared a common haplotype.

Conclusions: A homozygous *CTSF* mutation was identified in a recessive ANCL pedigree. In contrast to the previous associations of *CTSF* with KD type B, our findings suggest that *CTSF* genetic testing should also be considered in patients with KD type A as well as in early-onset dementia with prominent frontal lobe and motor symptoms. *Neurol Genet* 2016;2:e102; doi:10.1212/NXG.000000000000102

GLOSSARY

ANCL = adult-onset neuronal ceroid lipofuscinosis; **bv** = behavioral variant; **CTSF** = cathepsin F; **FTD** = frontotemporal dementia; **KD** = Kufs disease; **NCL** = neuronal ceroid lipofuscinosis; **PSP** = progressive supranuclear palsy; **STR** = short tandem repeat.

Neuronal ceroid lipofuscinoses (NCLs) are inherited, progressive, neurodegenerative, lysosomal storage diseases. Adult-onset NCLs (ANCLs), also known as Kufs disease (KD), are rare and challenging to diagnose. In contrast to the childhood forms, which are all recessive diseases, both recessive and dominant inherited forms occur in adults. Recessive ANCL has been divided into 2 overlapping clinical subtypes presenting predominantly as (1) progressive myoclonus epilepsy with dementia, ataxia, and late-onset pyramidal and extrapyramidal signs (type A, CLN6 disease) or (2) progressive behavioral abnormalities and dementia which may be associated with motor dysfunction, ataxia, extrapyramidal signs, and suprabulbar signs (type B).¹ Some ANCL families with autosomal dominant inheritance are referred to as Parry disease.

Correspondence to
Prof. Dr. Van Broeckhoven:
christine.vanbroeckhoven@
molgen.vib-ua.be

Supplemental data
at Neurology.org/ng

*These authors contributed equally to the article.

From the Neurodegenerative Brain Diseases Group (J.v.d.Z., S.V.M., L.D., F.P., A.S., C.V.B.), Department of Molecular Genetics, VIB, Antwerp; Institute Born-Bunge (J.v.d.Z., S.V.M., L.D., F.P., S.E., C.C.-D.G., A.S., P.C., J.-J.M., C.V.B.), CLIPS, Computational Linguistics and Psycholinguistics (J. Verhoeven), University of Antwerp; Department of Neurology and Memory Clinic (P.M., R.C., S.V.M., S.E.), ZNA Middelheim and Hoge Beuken, Antwerp; Clinical and Experimental Neurolinguistics (P.M., T.D.), Vrije Universiteit Brussel, Belgium; Department of Language and Communication Science (J. Verhoeven), City University, London, UK; Department of Neurology (A.S.), University Hospital Ghent and University of Ghent; Department of Neurology (S.V.M., P.C.), Antwerp University Hospital; and Department of Neurology (J. Versijpt), University Hospital Brussels, Belgium.

Funding information and disclosures are provided at the end of the article. Go to Neurology.org/ng for full disclosure forms. The Article Processing Charge was paid by Flemish Government-initiated Flanders Impulse Program on Networks for Dementia Research (VIND).

This is an open access article distributed under the terms of the Creative Commons Attribution-NonCommercial-NoDerivatives License 4.0 (CC BY-NC-ND), which permits downloading and sharing the work provided it is properly cited. The work cannot be changed in any way or used commercially.

Molecular genetic studies have started to unravel the underlying genetic defects in ANCL. The first genes were reported in 2011, with the identification of mutations in the *CLN6* gene (*CLN6*)² in KD type A and mutations in *DNAJC5* in some cases of Parry disease (*CLN4*).^{1,3} Next, mutations in cathepsin F (*CTSF*) were linked to KD type B (*CLN13*).^{4,5} Still, several families and patients with ANCL remain unresolved, indicating that other genes are yet to be identified.

This study describes a Belgian ANCL family with 4 affected sibs and unaffected parents. Exome sequencing was used to pursue the causal genetic defect, and case descriptions of the clinical and neuropathologic features are provided. Because of the overlap in clinical symptoms with frontotemporal dementia (FTD), we additionally

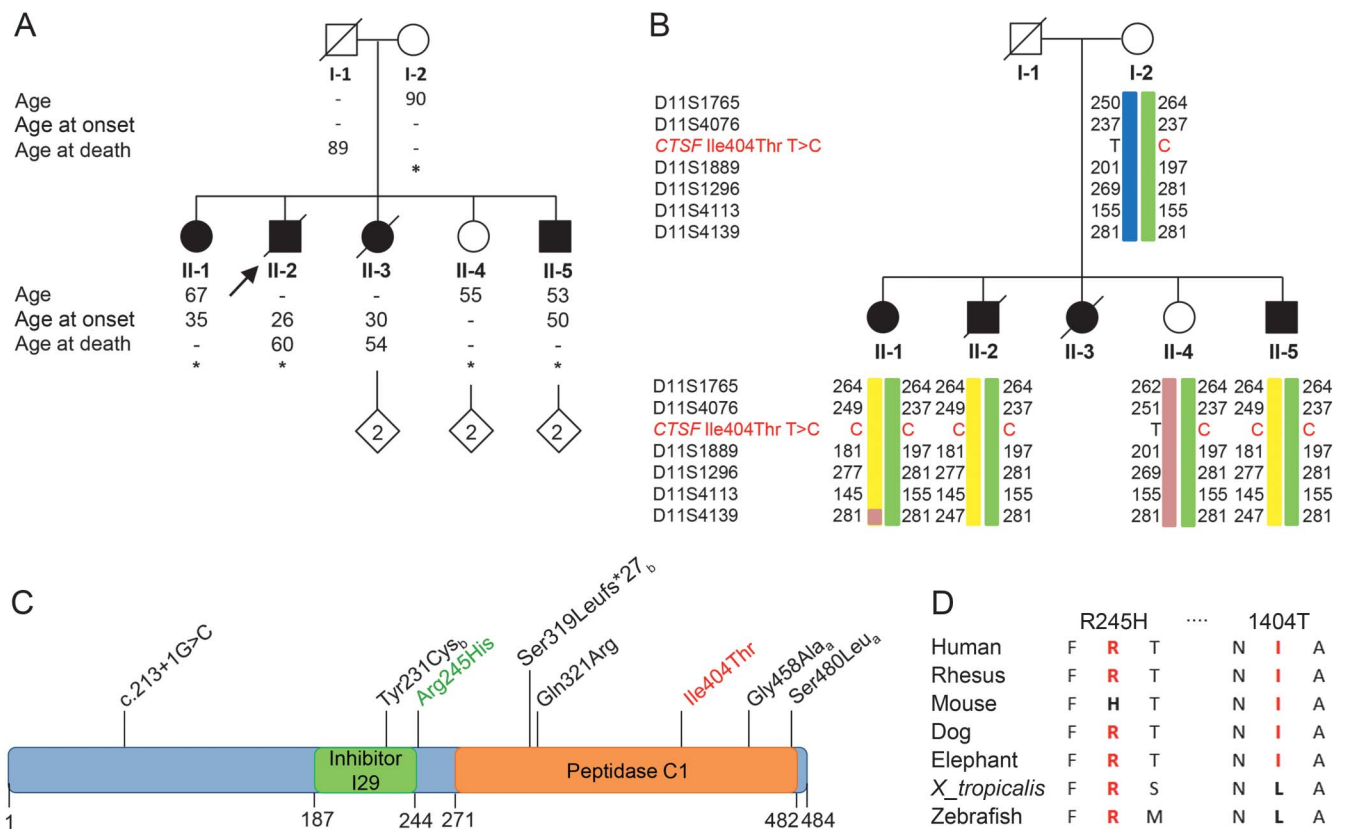
examined a Belgian cohort of unrelated patients with FTD for mutations in *CTSF*.

METHODS Study populations. The Belgian ANCL family consisted of 5 sibs, 3 women, and 2 men, born to nonconsanguineous parents (figure 1A). A group of 1,177 neurologically healthy Belgian research participants (mean age at inclusion: 66.4 ± 13 years) was used as control cohort in the genetic screen of the *CTSF* mutation identified in the ANCL family. A total of 461 unrelated Belgian patients with FTD (mean onset age: 61.7 ± 10.3 years) and a subset of 607 controls (mean age at inclusion: 70.9 ± 9.3 years) were used in the mutation screening of all coding exons of *CTSF*.

Standard protocol approvals, registrations, and patient consents. The clinical and genetic studies were approved by the ethics committee of the respective hospitals and by the ethical committee of the Antwerp University Hospital and University of Antwerp, Belgium. Informed consent was obtained from all participants.

Neuropathology and electron microscopy. The autopsied brain of index patient II-2 was inspected by macroscopic and

Figure 1 Mutated *CTSF* in adult-onset neuronal ceroid lipofuscinosis and patients with frontotemporal dementia



(A) Pedigree of the recessive adult-onset neuronal ceroid lipofuscinosis (ANCL) Belgian family. The index patient or proband (case II-2) is indicated by an arrow. Participants whose exomes were sequenced are indicated with an asterisk. Current age, age at onset in case of patients, and age at death are indicated in years. (B) Haplotype segregation in the ANCL pedigree. *CTSF* p.Ile404Thr carrier status and phased haplotypes using *CTSF* flanking short tandem repeat (STR) markers are shown. The green haplotype indicates the maternal disease haplotype; yellow haplotype indicates the paternal inherited disease haplotype. The blue and pink haplotypes carry the wild-type allele. (C) Cathepsin F (*CTSF*) protein with present and reported^{4,5} *CTSF* mutations associated with recessive ANCL. Mutations are mapped to the primary structure of the *CTSF* protein indicating known functional domains. *CTSF* p.Ile404Thr homozygous mutation identified in the Belgian family is indicated in red. *CTSF* p.Arg245His heterozygote mutation identified in 2 Belgian patients with frontotemporal dementia (FTD) is indicated in green. Reported mutations are in black. Subscripts a and b indicate reported compound heterozygous mutation pairs. (D) Sequence alignment of identified *CTSF* p.Arg245His and p.Ile404Thr mutations showing evolutionary conservation across species.

microscopic examinations (figure 2) as well as by electron microscopy (figure 3). Skin biopsies of patient II-2 and of his affected brother II-5 (figure 3F) were also examined by electron microscopy, respectively in 1993 and 2013.

Exome sequencing. Whole exome sequencing was performed in patients II-1, II-2, II-5, the unaffected mother (I-2), and the unaffected sib (II-4), using the SureSelect Human All Exon V5+UTR kit (Agilent Technologies, Santa Clara, CA) and sequencing on a HiSeq 2000 (Illumina, San Diego, CA). Variants with a predicted protein-modifying effect and genotypes consistent with a recessive inheritance model were selected.

For mutation validation, segregation analysis, and testing of controls, exon 10 of *CTSF*, comprising the p.Ile404Thr mutation, was analyzed using Sanger sequencing in the family members and in 1,177 Belgian control individuals.

In the ANCL family, the disease haplotype was determined using a panel of 6 short tandem repeats (STRs) flanking *CTSF* on both sides. In addition, allele sharing with 2 heterozygous control carriers of the mutation found in the ANCL family was analyzed.

Mutation screening of *CTSF* in patients with FTD and control individuals. The 13 coding exons of *CTSF* were amplified in multiplex PCRs using the MASTR technology (<http://www.multiplicom.com>) and sequenced on a MiSeq platform

(Illumina). Identified variants were validated by Sanger sequencing.

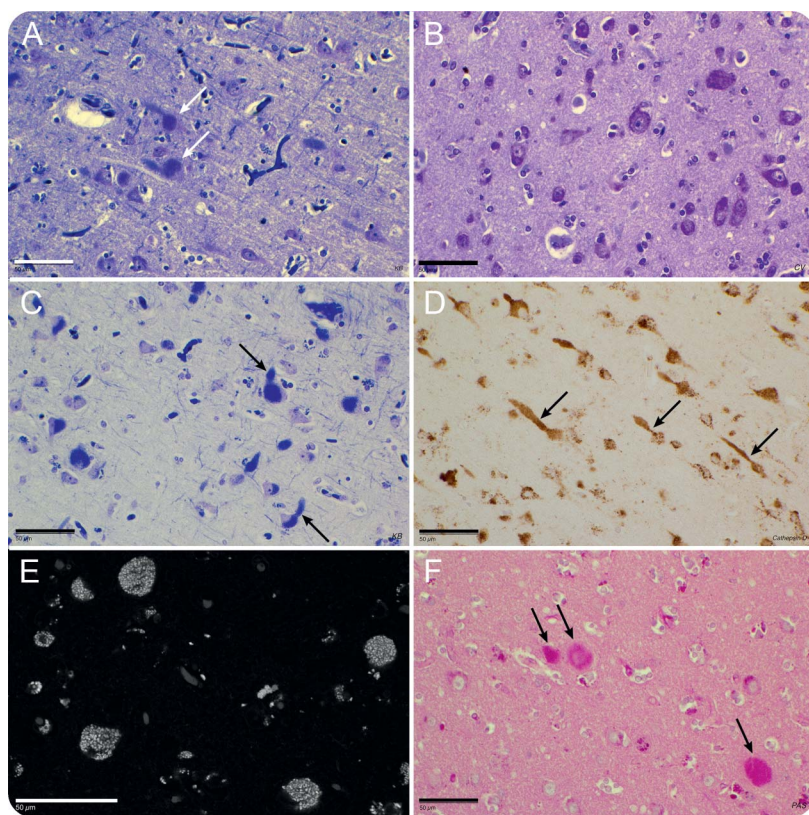
In the 2 FTD patients with a heterozygous *CTSF* mutation, allele sharing was analyzed using the same STR panel as in the ANCL family.

Procedures. Procedures are detailed in the supplemental data (appendix e-1 at Neurology.org/ng).

RESULTS The Belgian ANCL family. In this family with unaffected parents, 4 of the 5 sibs developed ANCL (figure 1A). The eldest sister (II-1), born in 1948, is still alive and has no children. She developed generalized myoclonic epileptic seizures at the age of 35 years, followed by extrapyramidal symptoms and cognitive disturbances 7 and 15 years later, respectively. CT scan of the brain at the age of 35 revealed moderate cortical and subcortical atrophy, too pronounced for her age. Brain MRI at the age of 62 showed generalized cortical-subcortical atrophy. In-depth neuropsychological investigations were consistent with a diagnosis of behavioral variant (bv) FTD. The eldest brother (II-2; proband) was born in 1952 and remained childless. At the age of 26 years, he had developed progressive motor speech problems. MRI of the brain revealed mild generalized cortical-subcortical atrophy. At the age of 54, his condition progressively worsened, with severe motor, cognitive, and behavioral decline, consistent with a diagnosis of bvFTD. Repeat MRI of brain demonstrated generalized cortical-subcortical atrophy. In the final stage, he developed akinetic mutism and died in 2012 at the age of 60. The second daughter (II-3) was born in 1953. At the age of 30 years, she presented with progressive apathy and behavioral, cognitive, and affective disturbances. Brain CT disclosed severe generalized cortical-subcortical atrophy. She died in 2007 at the age of 54, after a long period of progressive behavioral and cognitive disturbances resulting in severe dementia (bvFTD) and akinetic mutism. She was the mother of 2 healthy children. The youngest daughter (II-4), born in 1960, is healthy and the mother of 2 healthy children. The youngest brother (II-5) was born in 1962 and has 2 healthy children. At the age of 50, he developed right-sided tremor, motor speech problems, general slowness, and feelings of anxiety. Neuropsychological testing disclosed a general cognitive decline, with prominent frontal lobe involvement. MRI of the brain showed marked generalized cortical-subcortical atrophy and a cyst of the choroid plexus in the left lateral ventricle. The mother of the 5 sibs was born in 1925 and is still alive at age 90. Their father, born in 1921, died at the age of 89.

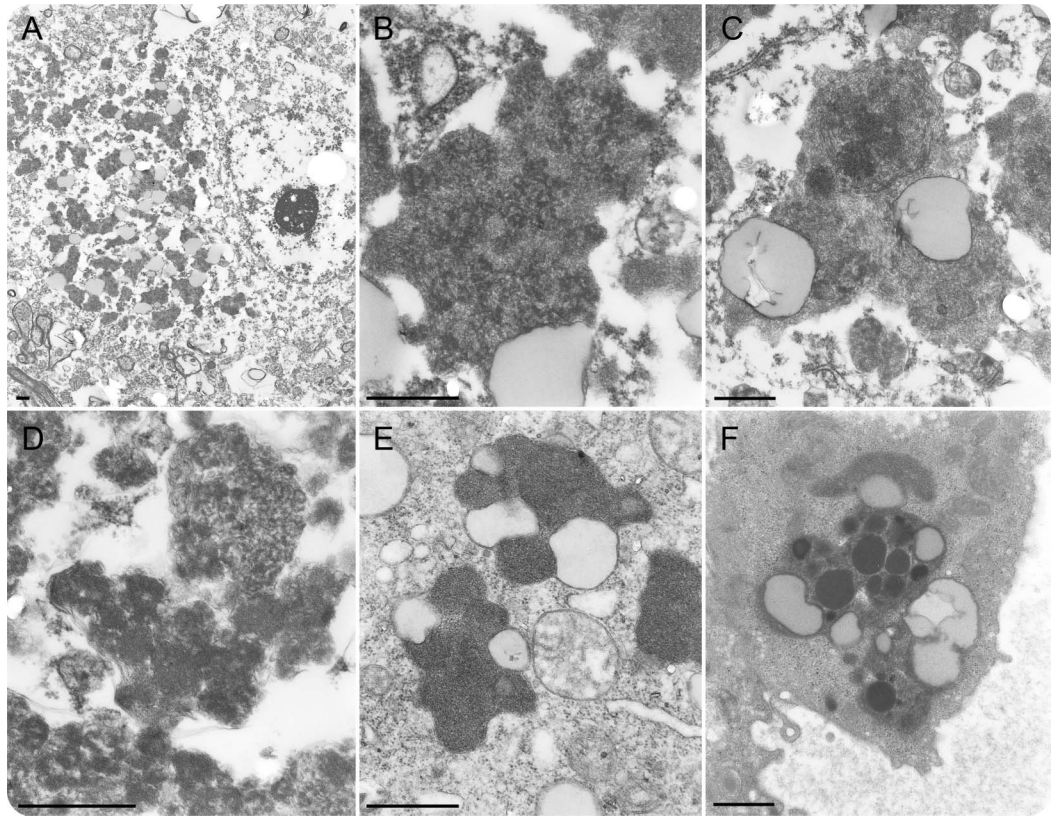
Neuropathology and electron microscopy of the ANCL family. Autopsy was performed on the brain of patient II-2, which weighed 956 g. Macroscopic examination revealed atrophy of the different lobes and

Figure 2 Light microscopy images of brain autopsy case II-2



Frontal cortex (area 8). (A) Swollen neuronal perikarya and the proximal part of the axons (arrows). (B) Age-matched control case. (C) Dilated proximal axons filled with lipopigmentary granules (arrows). (D) Similar picture showing immunoreactivity for cathepsin D (arrows). (E) Autofluorescence of the lipopigmentary granules. (F) Periodic acid-Schiff positivity of the stored granules (arrows). Paraffin sections; A and C: Klüver-Barrera staining, B: cresyl violet, D: antibody against cathepsin D, E: autofluorescence, F: Periodic acid-Schiff method; scale = 50 μ m.

Figure 3 Electron microscopy images of brain autopsy case II-2



(A) Frontal cortex. Intraneuronal storage of lipofuscin-like inclusions. Magnification: $\times 5,750$. (B) Occipital cortex. Neuronal inclusion showing a granular pattern and densely packed short lamellar profiles, coarser granular compounds, and lipid droplets. Magnification: $\times 41,000$. (C) Nucleus dorsomedialis of the thalamus. Intraneuronal intermingled granular and lamellar complexes. Magnification: $\times 27,000$. (D) Temporal cortex. Predominance of fingerprints in a neuronal inclusion. Magnification: $\times 52,500$. (E) Brain biopsy of a 34-year-old female patient without neuronal ceroid lipofuscinosis (control). Intraneuronal classical lipofuscin. Magnification: $\times 41,000$. (F) Electron microscopic examination of skin biopsy case II-5. Lipofuscin-like inclusion with an uncommon heterogeneous pattern in an endothelial cell of a blood vessel. Magnification: $\times 27,000$. Scale = 1 μm .

dilation of the ventricular system. Microscopic examination of the frontal, parietal, temporal, and occipital neocortices showed generalized signs of neuronal storage of a yellowish pigment, more evident in the large pyramidal cells of the third cortical layer but also in the Betz neurons of the fifth cortical layer at the level of the precentral gyrus. The granular storage was noted in the perikaryon and could be followed in the proximal part of the axon (figure 2, A and C). Sometimes, the axon was enlarged after the axonal hillock. The storage material was autofluorescent (figure 2E), yellowish on cresyl violet and hematoxylin and eosin stains, deep blue on Klüver-Barrera stain, and strongly periodic acid-Schiff positive (figure 2F). AT8 (against hyperphosphorylated tau) elicited a moderate amount of neurofibrillary tangles and sparse neuritic threads in the hippocampus and parahippocampal structures. The presence of these findings had no clinical relevance. TDP-43 immunohistochemistry did

not show any abnormalities. Cathepsin D staining showed lipopigmentary granules (figure 2D). Other immunohistochemical stains were negative.

Electron microscopic examination of the brain of patient II-2 confirmed the intraneuronal storage of polymorphic lipofuscin-like inclusions (diameter: 1–2 μm) with granular components displaying distinctive features (figure 3A). At higher magnifications, densely packed short lamellar profiles, coarser granular components (figure 3B), and lipid droplets as well as lamellar complexes (figure 3C) and few fingerprints (figure 3D) were seen. These inclusions were mostly different from the classical lipofuscin (figure 3E). Similar but large coalescing inclusions were present in glial and microglial cells. Numerous polymorphic inclusions revealing coarse and densified granular subunits associated with lipid droplets were observed in Golgi- or basket-like cells. Glial cells and granule cells showed compound lipofuscin-like deposits with granular subunits.

Sporadic granular lipopigments with osmiophilic granules in Schwann cells as well as unmyelinated

dystrophic axons were observed in the skin biopsy of patient II-2, while lipofuscin-like inclusions with an uncommon heterogeneous pattern were detected in eccrine sweat glands and blood vessels (figure 3F) of patient II-5.

A more detailed description of the neuropathology and electron microscopic examination can be found in the supplemental data.

Identification of the causal gene defect in the ANCL family. Analysis of the exomes identified only one rare coding variant that was consistent with a recessive mode of inheritance. The variant predicted a missense mutation p.Ile404Thr in the *CTSF* gene and was found homozygous in all affected sibs and heterozygous in the unaffected mother and unaffected daughter (figure 1B). Segregation analysis with a panel of flanking STR markers demonstrated that the *CTSF* p.Ile404Thr mutation was inherited on 2 different haplotypes and, as such, confirmed that the parents were not consanguineous (figure 1B). The presence of the p.Ile404Thr mutation was tested in an extended cohort of 1,177 Belgian control persons. No homozygous carriers were found; however, p.Ile404Thr was identified in the heterozygous state in 2 control individuals, a 76-year-old man and a 67-year-old woman. Inspection of their STR genotypes was suggestive of a common haplotype with the paternal-inherited disease haplotype (figure 1B, yellow haplotype) of the ANCL family.

Genetic screening of *CTSF* in patients with FTD. Because the neurocognitive profile of the ANCL family was marked by prominent frontal lobe features evolving to severe FTD with akinetic mutism at the end stage of the disease in 2 sibs, the identified causal *CTSF* gene was further tested for mutations in 461 unrelated Belgian patients with FTD. We detected 1 heterozygote mutation, p.Arg245His, in 2 patients (0.4%), which was absent in the control cohort (figure 1C).

Mapping of the mutations on the *CTSF* protein. The *CTSF* gene encodes a lysosomal cysteine protease, CTSE, that belongs to the peptidase C1 family and is believed to participate in the intracellular degradation and turnover of proteins. CTSE is a 484 amino acid protein with 2 known functional domains: a peptidase inhibitor I29 domain and a peptidase C1 domain (figure 1C). In line with the majority of the reported *CTSF* mutations, the p.Ile404Thr missense mutation maps to the peptidase C1 domain near the C-terminal end of the protein. In contrast, the p.Arg245His mutations fall outside the known functional domains, yet flanking to the inhibitor I29 domain. Both the p.Ile404Thr and the p.Arg245His mutations affect conserved residues, although for the latter, in mice, a His-residue is present at the homologous position (figure 1D).

Clinical presentation of the FTD carriers of *CTSF* p.Arg245His. One of the FTD patients with the heterozygote p.Arg245His mutation developed signs of bvFTD at the age of 65 years, marked by irritability, socially inappropriate behavior, and verbal disinhibition. He also suffered from severe balance problems causing repetitive falling, nocturnal myoclonus, dysarthria, mild word-finding difficulties, and a mild asymmetrical extrapyramidal syndrome. At age 67, he had developed constructional apraxia, dysphagia, and impaired vertical eye movements. MRI of the brain showed atrophy of the midbrain with a hummingbird sign, compatible with progressive supranuclear palsy (PSP). No clear family history was reported.

The second carrier developed memory problems at the age of 76. She had 1 sister with unspecified dementia, developed at the age of 75. The patient later developed slowness, balance problems with repeated falling, inappropriate and compulsive behavior, incontinence, echolalia, dysarthria, and extrapyramidal signs with a vertical gaze palsy. At the age of 81, she evolved to a state of akinetic mutism with swallowing problems. Her MRI results also showed a hummingbird sign, as in PSP, and a presynaptic dopaminergic degeneration on dopamine transporter imaging.

There was no direct evidence for relatedness between the two p.Arg245His carriers; however, STR genotyping flanking the mutation was indicative of a common disease haplotype, suggesting a common founder.

DISCUSSION The present study investigated a recessive kindred with a complex neurobehavioral syndrome characterized by progressive adult-onset bvFTD, motor disturbances, and in 1 patient, myoclonic epilepsy. Close clinical follow-up over many years and neuropathologic examination of the proband (case II-2) ultimately pointed to the diagnosis of recessive ANCL or KD.

Exome sequencing identified a cosegregating missense mutation in the *CTSF* gene, p.Ile404Thr. This variant was the only homozygous variant shared between all affected sibs and was heterozygote in the unaffected relatives. Although all patients in the family were homozygous for the same gene defect, there was a remarkable variability in their phenotypic expression, particularly early in the disease course, with onset ages of presenting symptoms ranging from 26 years in case II-2 to 50 years in case II-5. In cases II-2, II-3, and II-5, clinical features were most consistent with KD type B and epilepsy was absent. However, myoclonic epilepsy in case II-1 was suggestive of KD type A. This observation is of interest because *CTSF* homozygous mutations have, thus far, been exclusively linked to KD type B. Alternatively, the epilepsy phenotype in case II-1 might be unrelated to the *CTSF* mutation and concurred by

coincidence. Contrary to expectations, there was no evidence for consanguinity in the parents who were both of Belgian origin. Indeed, haplotype segregation analysis confirmed that *CTSF* p.Ile404Thr mutation occurred at least twice on 2 different haplotypes. This is in line with the observation of the same mutation in the heterozygote state in 2 unrelated Belgian control persons (2/1,177, or 0.2%). In the 2 controls, allele-sharing analysis was suggestive of a common haplotype with the paternal haplotype observed in the family, indicating that this *CTSF* disease haplotype is relatively more common in the Belgian population.

Because of a constellation of pronounced behavioral, cognitive, and motor features in the patients of the KD family, it was hypothesized that mutations in *CTSF* may mimic an FTD phenotype. Analyses of a large set of unrelated Belgian patients with FTD did not reveal the same p.Ile404Thr mutation. However, another mutation, p.Arg245His, was found in the heterozygous state in 2 patients with FTD. It is not clear how heterozygous mutations in a recessive gene such as *CTSF* may lead to disease, although this may be explained by clinical heterogeneity or pleiotropy where homozygous mutations lead to a more severe phenotype with earlier onset and heterozygous mutations of the same gene lead to another (related) phenotype with later onset. Indeed, the homozygous p.Ile404Thr carriers in the KD family developed first symptoms in their 30s, whereas the 2 heterozygous p.Arg245His FTD carriers were diagnosed at ages 65 and 76 years, respectively. Furthermore, it is remarkable that both patients with FTD developed a PSP phenotype with typical hummingbird sign on brain MRI and, in addition to showing comparable disease presentations, also showed interesting commonalities with the patients of the KD family, including balance problems, dysarthria, and extrapyramidal symptoms. Also the patients with FTD carried the heterozygous p.Arg245His on the same haplotype, further favoring a role in disease causation. Nevertheless, this observation will need confirmation in independent FTD cohorts before we can decide that heterozygous *CTSF* mutations are causally associated with FTD.

AUTHOR CONTRIBUTIONS

Julie van der Zee: study design, genetic data collection, data analysis, data interpretation, literature search, writing, and figures. Peter Mariën and Roeland Crols: study design, patient samples collection, clinical follow-up of patients, clinical data collection, clinical data analysis, data interpretation, and writing. Sara Van Mossevelde: clinical data collection, clinical data analysis, data interpretation, and writing. Lubina Dillen: genetic data generation, data analysis, and data interpretation. Federica Perrone: genetic data generation, data analysis, and data interpretation. Sebastiaan Engelborghs and Jo Verhoeven: patient samples collection, clinical data collection, clinical data analysis, data interpretation, and writing. Tine D'aes: patient samples collection and clinical data collection. Chantal Ceuterick-De Groote: electron microscopy data collection, data analysis, data interpretation, writing, and figures. Anne Sieben: neuropathology data collection, data analysis, data interpretation, writing, and figures. Jean-Jacques Martin: study design, neuropathology data collection, data

analysis, data interpretation, writing, and figures. Jan Versijpt and Patrick Cras: patient samples collection, clinical data collection, data interpretation, and writing. Christine Van Broeckhoven: study design, genetic data collection, genealogy data collection, data analysis, data interpretation, literature search, writing, and figures.

ACKNOWLEDGMENT

The authors thank the staff of the Genetic Service Facility for their contribution to the genetic analyses; the staff of the Antwerp Biobank of the Institute Born-Bunge for their contribution to the neuropathologic studies and expert support; neurologist Luk Dejaegher for the medical records of case II-1; neurologist Goedele Malfruid and general practitioner Ludo Draulans for the medical records of case II-3; and neurologists Patrick Santens, Jan De Bleeker, Rik Vandenberghe, and Mathieu Vandembulcke for patient samples collection and clinical data collection of the FTD cohort.

STUDY FUNDING

The sponsors of the study had no role in study design, data collection, data analysis, data interpretation, or writing of the report. The data presented in this paper was in part funded by the Belgian Science Policy Office (BELSPO) Interuniversity Attraction Poles program; the Flemish Government-initiated Methusalem excellence program; the Flemish Government-initiated Flanders Impulse Program on Networks for Dementia Research (VIND); the University of Antwerp Research Fund; and the Strategic Research Program (SPR15) awarded by the University of Brussel (VUB).

DISCLOSURE

Julie van der Zee, Peter Mariën, Roeland Crols, Sara Van Mossevelde, Lubina Dillen, and Federica Perrone report no disclosures. Sebastiaan Engelborghs has served on the scientific advisory boards of Innogenetics/Fujirebio Europe, Novartis, UCB, Roche Diagnostics, Nutricia/Danone, and Eli Lilly; has served on the editorial boards of the *Journal of Alzheimer's Disease* and *Clinical Neurology and Neurosurgery*; and has received research support from Janssen Pharmaceutica NV, ADx Neurosciences, the Research Foundation Flanders (FWO-Vlaanderen), the Agency for Innovation by Science and Technology (IWT), the Special Research Fund (BOF) of the University of Antwerp, and the Alzheimer Research Foundation (SAO-FRA). Jo Verhoeven, Tine D'aes, Chantal Ceuterick-De Groote, and Anne Sieben report no disclosures. Jan Versijpt has served on the editorial board of *Acta Neurologica Belgica*. Patrick Cras reports no disclosures. Jean-Jacques Martin has served on the editorial board of *Clinical Neurology and Neurosurgery*. Christine Van Broeckhoven has served on the editorial boards of *Genes, Brain and Behavior*, *NeuroMolecular Medicine*, and the *New England Journal of Medicine*; and has received research support from the University of Antwerp (salary) and VIB. Go to Neurology.org/ng for full disclosure forms.

Received May 9, 2016. Accepted in final form August 8, 2016.

REFERENCES

1. Mole SE, Williams RE. Neuronal ceroid-lipofuscinoses. Pagon RA, Adam MP, Ardinger HH, et al, editors. GeneReviews. Seattle: Seattle University; 1993–2014.
2. Arsov T, Smith KR, Damiano J, et al. Kufs disease, the major adult form of neuronal ceroid lipofuscinosis, caused by mutations in CLN6. *Am J Hum Genet* 2011;88:566–573.
3. Nosková L, Stránecký V, Hartmannová H, et al. Mutations in DNAJC5, encoding cysteine-string protein alpha, cause autosomal-dominant adult-onset neuronal ceroid lipofuscinosis. *Am J Hum Genet* 2011;89:241–252.
4. Smith KR, Dahl HHM, Canafoglia L, et al. Cathepsin F mutations cause type B Kufs disease, an adult-onset neuronal ceroid lipofuscinosis. *Hum Mol Genet* 2013;22:1417–1423.
5. Di Fabio R, Moro F, Pestillo L, et al. Pseudo-dominant inheritance of a novel *CTSF* mutation associated with type B Kufs disease. *Neurology* 2014;83:1769–1770.