



Carina Pinz¹, Letícia Tramontin Mendes¹, Renata Cristina Teixeira Pinto Viana^{1,2}, Luiz Eduardo de Oliveira Viana², Luiz Gustavo Teixeira Pinto^{1,2}, Daniel Cury Ogata^{1,2}



cacapinz@hotmail.com



¹Universidade do Vale do Itajaí, Itajaí, Brazil.

²Unimed Litoral Balneário Camboriú, Balneário Camboriú, Brazil.

Puerpera with back pain and intermittent fever

Case report

Cite as: Pinz C, Mendes LT, Viana RCTP, *et al.* Puerpera with back pain and intermittent fever. *Breathe* 2018; 14: e48–e54.

A 25-year-old female presented, reporting back pain and intermittent fever for 3 months. At the time, she was at the end of the third trimester of pregnancy; therefore, an imaging examination could not be carried out.

Task 1

What is the most likely diagnosis?

- a) Pyelonephritis
- b) Community-acquired pneumonia
- c) Abscess of the psoas muscle
- d) Pott's disease
- e) Chorioamnionitis



© ERS 2018



@ERSpublications

Can you diagnose this case of puerpera with back pain and intermittent fever?

<http://ow.ly/AC0U30k20kF>

Answer 1

b) Community-acquired pneumonia

Antibiotic treatment for a presumed community-acquired pneumonia was commenced by the attending obstetrician, but it was not successful. She underwent a Caesarean delivery without complications. During puerperium, the patient developed high fever and back pain.

Task 2

What simple imaging examination could be requested to assist in the diagnosis?

- a) Bronchoscopy
- b) Magnetic resonance imaging
- c) Chest radiography
- d) Arteriography of the thorax
- e) Scintigraphy

Answer 2

c) Chest radiography

Chest radiography was performed (figure 1).

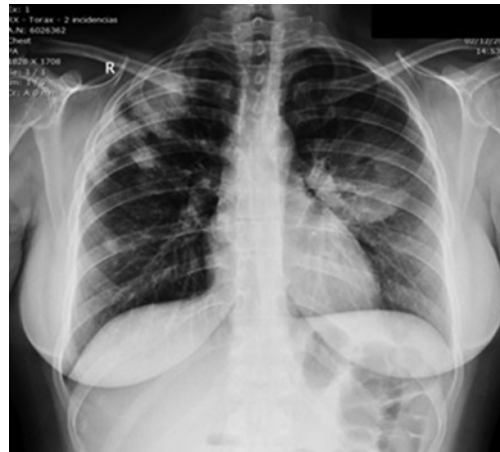

Figure 1 Chest radiograph.

Task 3

On the chest radiograph in figure 1, what can be seen?

- a) Bilateral intraparenchymal pulmonary consolidations
- b) A very prominent wedge-shaped area of airspace consolidation in the right lung, characteristic of acute bacterial lobar pneumonia
- c) Hyperinflation and predominantly upper lobe bronchiectasis
- d) Left lower lobe opacity with pleural effusion
- e) A left lung abscess

Answer 3

- a) Bilateral intraparenchymal pulmonary consolidations

A new course of antibiotics was commenced without any clinical improvement. In view of this, the patient was hospitalised under the general medical team.

Task 4

Given the radiograph and the patient's clinical symptoms, which imaging examination could be requested now?

- a) Computed tomography (CT) scan of the chest
- b) Magnetic resonance of the chest
- c) Bronchoscopy
- d) Scintigraphy
- e) Repeat chest radiography

Answer 4

a) Computed tomography (CT) scan of the chest

Task 5

Describe the general features of the chest CT scan image in figure 2a, as well as those highlighted by green arrows and red asterisks.

A chest CT scan was requested.

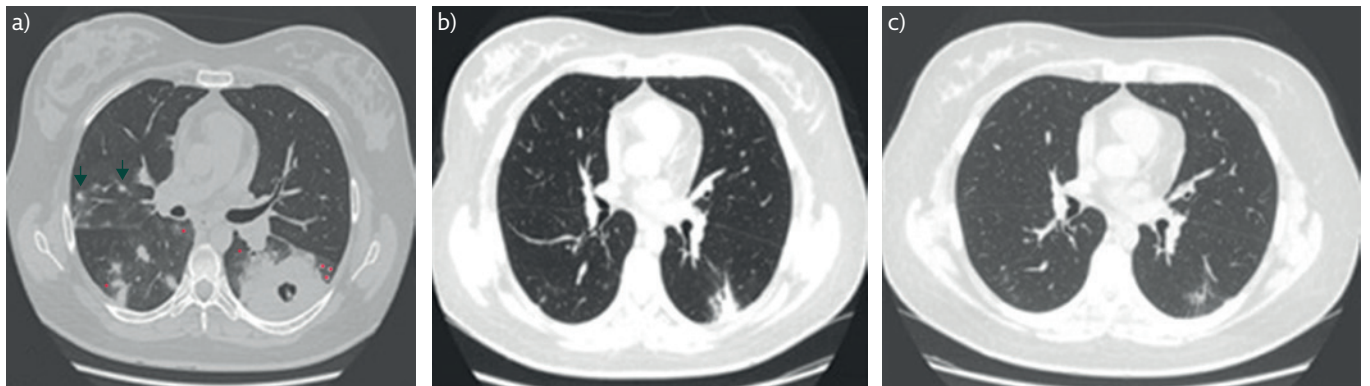


Figure 2 Axial CT scans of the chest. a) Before treatment. b) Significant regression of the lesions after 3 months of treatment. c) Almost complete regression of the lesions after 18 months of treatment.

Answer 5

There are multiple consolidated parenchymal lesions, the largest of which is 6.7 cm, in the apical segment of the lower lobe of the left lung with central cavitation. The red asterisks highlight areas of ground glass and green arrows indicate small solid pulmonary nodules in the apical segment of the lower lobe and lateral segment of the middle lobe of the right lung.

Following the CT scan results, the patient underwent bronchoscopy with bronchoalveolar lavage, but the findings did not reveal a cause for her symptoms or the radiological findings. Consequently, she underwent CT-guided biopsy, which resulted in the diagnosis of pulmonary cryptococcosis (figure 3).

Lumbar puncture was performed to assess for any central nervous system involvement. She was negative for HIV 1 and 2 antibodies, as well as for hepatitis B and C. Antifungal treatment was commenced.

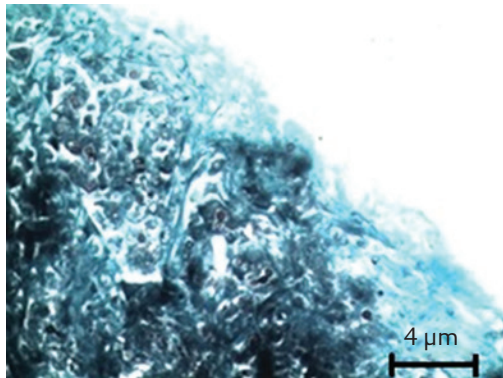


Figure 3 Anatomopathological lung examination. Grocott staining at 400× magnification, demonstrating oval fungal structures sometimes surrounded by a clear halo.

Task 6

What constitutes first-line anti-cryptococcal therapy?

- Cephalosporin
- A nonsteroidal anti-inflammatory agent
- Corticosteroids alone
- Fluconazole or amphotericin B
- Metronidazole

Answer 6

d) Fluconazole or amphotericin B

Fluconazole was started at a dose of 400 mg once daily, with remission of the febrile episodes and back pain.

After the diagnosis was made, large quantities of pigeon faeces and nests were discovered on top of the air conditioning units used to cool the closed room of the call centre where the patient worked.

After 3 months, the patient was asymptomatic. A chest CT scan was requested, which showed a significant improvement in the lesions (figure 2b). A pulmonary function test showed no changes. Antifungal therapy was maintained for 18 months, until complete disappearance of the chest lesions shown in the CT scan, and complete resolution of the infection (figure 2c).

Discussion

Cryptococcus sp. infection is common in immunocompromised patients. In this group, it is most commonly related to the use of immunosuppressant drugs (41%), systemic lupus erythematosus (16%), malignant pathologies (16%) and diabetes mellitus (14%) [1]. However, in this case, pulmonary cryptococcosis was diagnosed in a previously healthy, immunocompetent puerperal patient.

The incidence of pulmonary cryptococcosis among patients with negative serology for HIV is low, around 0.2–0.9 per 100 000 inhabitants [2]. For this pathology to become established, it requires some degree of cellular immune deficiency, represented by changes in the in T-cells, natural killer cells, polymorphonuclear leukocytes, macrophages and specific antibodies [3]. Changes in the immune system peak in the third trimester of pregnancy, only returning to normal 3–5 months *post partum* [4]. Another possible risk factor for the spread of fungal infection is increased levels of sex hormones (progesterone and oestrogen) [5]. However, although gestation is described as a potential immunosuppressant factor, there is still no clear evidence that this period is an isolated risk factor for this infection [6].

In the present case, the patient's pulmonary symptoms started during the third trimester of pregnancy and, without successful treatment, evolved with worsening of the condition in the puerperal period.

The presence of back pain and fever during pregnancy suggests several differential diagnoses, including abdominal pathologies and cholecystitis, or an infectious pulmonary pathology such as tuberculosis, community-acquired pneumonia or endemic mycoses [7]. Conversely, the presentation of the lung disease may be isolated or disseminated.

In a third of non-AIDS cases with pulmonary cryptococcosis, acute respiratory failure developed [8].

When a pulmonary cryptococcal infection is suspected, a number of different diagnostic procedures may be relevant. A sputum sample should be sent for cytological analysis, as this can lead to an immediate diagnosis. Bronchoscopy is the most accurate method of diagnosis, especially when combined with transbronchial biopsy [9]. In patients with isolated pulmonary infection, serum cryptococcal antigen is positive in 25–56% of cases. This antigen is considered a marker of local disease severity or increased spread of infection [10]. Another complementary examination is a CT scan of the chest, which may show the extent of disease involvement in the thorax and the presence of pleural or mediastinal lesions [11]. Diagnosis is often attained through biopsy of the lesion or material obtained from bronchoalveolar lavage [12].

In the case presented here, the absence of diagnostic findings on bronchoalveolar lavage made CT-guided core biopsy necessary. The finding was of the spherical or oval yeast forms of the fungus in this material. The pathology may also identify necrotising or non-necrotising granulomas in the infected tissue and, in chronic inflammation, the presence of lymphocytic infiltrate [13].

Most cases reported in the literature have been treated with amphotericin B and have shown good results for both the infant and the mother [4]. For limited and stable pulmonary cryptococcosis, regular monitoring and administration of fluconazole after delivery should be performed. For the patient in question, there was remission of symptoms and significant radiological improvement with the use of fluconazole 400 mg once daily for 18 months. Fluconazole therapy is also well established; the difference lies in the duration of drug use [14]. Amphotericin B is the preferred initial treatment for cryptococcal meningoencephalitis, disseminated disease or severe pulmonary cryptococcosis in pregnant patients. This drug is classified by the US Food and Drug Administration as a category B drug for use during pregnancy. Data from clinical use of amphotericin B for coccidioidomycosis have not shown teratogenicity or toxicity related to renal dysfunction in the mother or fetus. Switching to fluconazole is appropriate after childbirth [15].

In conclusion, cryptococcosis should be considered in the differential diagnosis of infectious pulmonary diseases in pregnant and *post partum* women whose initial presentation is chest pain and fever.

Task 7

In pregnant patients, what are the main risk factors involved in infection with *Cryptococcus sp.*?

- a) Changes in maternal cellular immunity and weight gain
- b) Changes in thyroid hormones and anaemia
- c) Changes in humoral immunity and decreased proliferation of T-lymphocytes
- d) Increase in sex hormones and change in cellular immunity
- e) Increased polymorphonuclear leukocytes and decreased oestrogen

Task 8

With respect to the diagnosis of pulmonary cryptococcosis, which of the following is correct?

- a) Immediate diagnosis is made from the chest CT scan
- b) Confirmatory examination is obtained by biopsy of the lesion or material obtained by bronchoalveolar lavage
- c) Bronchoscopy is the most sensitive method for the diagnosis of pulmonary cryptococcosis
- d) Biopsy is a highly specific exam, but it is not indicated because it is difficult to perform
- e) Serum screening for cryptococcal antigen does not help in staging the disease or monitoring response to therapy

Answer 7

d) The altered activity of natural killer cells, maternal T-cells, macrophages, polymorphonuclear leukocytes, specific antibodies and the increase in sex hormones may contribute to the development of cryptococcosis.

Answer 8

b) The most frequently applied and reliable diagnostic procedure is CT-guided percutaneous biopsy.

Conflict of interest

None declared.

References

1. Kiertiburanakul S, Wirojtananugoon S, Prachartam R, *et al.* Cryptococcosis in human immunodeficiency virus-negative patients. *Int J Infect Dis* 2006; 10: 72–78.
2. Barbosa AT, Colares FA, Gusmão ES, *et al.* Criptococose pulmonar isolada em paciente imunocompetente [Isolated pulmonary cryptococcosis in an immunocompetent patient]. *J Bras Pneumol* 2006; 32: 476–480.
3. Costa ML, Souza JP, Oliveira Neto AF, *et al.* Cryptococcal meningitis in HIV negative pregnant women: case report and review of literature. *Rev Inst Med Trop Sao Paulo* 2009; 51: 289–294.
4. Nakamura S, Izumikawa K, Seki M, *et al.* Pulmonary cryptococcosis in late pregnancy and review of published literature. *Mycopathologia* 2009; 167: 125–131.
5. LaGatta MA, Jordan C, Khan W, *et al.* Isolated pulmonary cryptococcosis in pregnancy. *Obstet Gynecol* 1998; 92: 682–684.
6. Lachhab L, Rasmouni K, Ait Ben Haddou EH, *et al.* Cryptococcosis in an immunocompetent pregnant woman. *Rev Neurol* 2013; 169: 92–93.
7. Ely EW, Peacock JE Jr, Haponik EF, *et al.* Cryptococcal pneumonia complicating pregnancy. *Medicine* 1998; 77: 153–167.
8. Vilchez RA, Linden P, Lacomis J, *et al.* Acute respiratory failure associated with pulmonary cryptococcosis in non-AIDS patients. *Chest* 2001; 119: 1865–1869.
9. Powell BL, Drutz DJ, Huppert M, *et al.* Relationship of progesterone- and estradiol-binding proteins in *Coccidioides immitis* to coccidioidal dissemination in pregnancy. *Infect Immun* 1983; 40: 478–485.
10. Lee YJ, Ko YK. Pulmonary cryptococcosis in pregnancy: 2 cases report and review of the literature. *J Intern Med Taiwan* 2013; 24: 212–219.
11. Silva ACG, Marchiori E, Souza AS, *et al.* Criptococose pulmonar: aspectos na tomografia computadorizada [Pulmonary cryptococcosis: computed tomography findings]. *Radiol Bras* 2003; 36: 277–282.
12. Liu K, Ding H, Xu B, *et al.* Clinical analysis of non-AIDS patients pathologically diagnosed with pulmonary cryptococcosis. *J Thorac Dis* 2016; 8: 2813–2821.
13. Kaplan A, Berntson DG, Ferrieri P. Postpartum cryptococcal pulmonary lesion incidentally discovered during a pulmonary-embolism evaluation of a 28-year-old Caucasian woman. *Lab Med* 2015; 46: 69–73.
14. Gharabaghi MA, Allameh SF. Primary pulmonary cryptococcosis. *BMJ Case Rep* 2014 [http://doi.org/10.1136/bcr-2014-203821].
15. Perfect JR, Dismukes WE, Dromer F, *et al.* Clinical practice guidelines for the management of cryptococcal disease: 2010 update by the Infectious Diseases Society of America. *Clin Infect Dis* 2010; 50: 291–322.