

Keystone Flap: Overcoming Paradigms

Oswaldo J. Gómez, MD
Oscar I. Barón, MD
Martha L. Peñarredonda, MD

Background: The physiology and geometry of the keystone flap (KF) are the main factors that support its development. This study reports our experience using the KF and proposes the concept of pedicular area.

Methods: A prospective cohort study was conducted from October 2014 to December 2016, in which 112 KF procedures were performed with an average follow-up time of 10 months. The conclusions drawn from clinical observations were compared with the findings of a literature review.

Results: One hundred twelve flaps were performed in 89 patients (45 men and 44 women) with an average age of 64 years (range, 3–89 years). The flap survival rate was 100%. The term pedicular area (PA) was coined to describe a flap segment that remains attached to its bed without vascular detriment and whose location can be randomly selected. In this study, the PA could be reduced up to a 10%, which means that over 90% of each flap was dissected without any harm.

Conclusions: The KF is a safe, cost-effective technique with better results when compared with other reconstructive procedures. Although research is still needed to better understand the physiological adaptations of KF, the clinical evidence supports its use in many reconstructive scenarios. (*Plast Reconstr Surg Glob Open* 2019;7:e2126; doi: 10.1097/GOX.0000000000002126; Published online 14 March 2019.)

INTRODUCTION

In the 1970s, Behan and Wilson¹ coined the concept of angiotome, which refers to the 3-dimensional tissue unit supplied by a dynamic vascular network. This idea and the geometry of its design support the development of the keystone flap (KF). The KF procedure was first described in 2003.² Since then, several series have been published in an effort to understand its physiology.

Many authors highlight the KF's versatility, reliability, and efficiency in multiple reconstructive scenarios and raise questions about its successful perfusion. The clinical evidence that claims the efficiency of this reconstructive strategy is overwhelming. However, KF is barely addressed in specialized literature and is still far from becoming a first-line tool in clinical practice. This study reports our experience using KF and proposes the concept of *pedicular area*.

MATERIALS AND METHODS

A prospective study was developed from October 2014 to December 2016 (26 months) at Fundación Hospital de

From the Division of Plastic Surgery, Department of Surgery, School of Medicine, Universidad Nacional de Colombia, Bogotá, Colombia.

Received for publication October 10, 2018; accepted December 12, 2018.

Copyright © 2019 The Authors. Published by Wolters Kluwer Health, Inc. on behalf of The American Society of Plastic Surgeons. This is an open-access article distributed under the terms of the Creative Commons Attribution-Non Commercial-No Derivatives License 4.0 (CCBY-NC-ND), where it is permissible to download and share the work provided it is properly cited. The work cannot be changed in any way or used commercially without permission from the journal.

DOI: 10.1097/GOX.0000000000002126

la Misericordia and during the main author's private practice. The following information was gathered: demographic data, diagnosis, location and size of defect and flap, area of the flap attached to the bed (pedicular area), type of flap according to Behan's classification,² surgical time, hospitalization time, and complications. Doppler marking in search of perforators was not performed in any of the cases. The average follow-up time was 10 months, and in all cases, preoperative and postoperative photographic records were taken. A series of uncontrolled cases is presented along with a description of the surgical technique applied.

RESULTS

A total of 112 flaps were performed in 89 patients (45 men and 44 women) with an average age of 64 years, 14 of whom were diabetic, 12 smokers and 2 had prior radiotherapy (Table 1). Of the 112 flaps, 51 (46.36%) were facial and followed oncological resections mainly (type I: 23, type IIa: 4, and type IV: 24); 16 (14.54%) were made to correct early and late posttraumatic defects in the upper limb (type IIa: 9, type III: 1, and type IV: 6); 30 (27.27%) were made to reconstruct traumatic and tumoral defects in the lower limb (type I: 3, type IIa: 15, type IIb: 1, and type IV: 11); 7 (6.36%) were made to cover defects in the perineum, Fournier's gangrene being the most frequent cause (type II: 3, type III: 2, and type IV: 2); and 8 (7.27%) were made to correct

Disclosure: The authors have no financial interest to declare in relation to the content of this article.

Table 1. Participants' Demographics

Data	Value
Total number of patients	89
Age (range), years	64 (3–89)
Hypertension	28/89
Diabetes	14/89
Radiotherapy	2/89
Smokers	12/89

Table 2. Anatomical Distribution of Keystone Flaps

Anatomical Location	Keystone Flap	I	IIA	IIB	III	IV
Face						
Cheeks	19	10				9
Eye lid	8	7				1
Nose	13	3	1			9
Forehead	8	3	3			2
Scalp	1					1
Neck and parotid	1					1
Ear	1					1
Upper limb						
Hand	10		7		1	2
Forearm	3		2			1
Elbow	3					3
Lower limb						
Leg	7		3	1		3
Foot	14	2	6			6
Thigh	9	1	6			2
Perineum	7		3		2	2
Chest						
Anterior	3		3			
Posterior	5	1	3			1
Total	112	27	37	1	3	44

tumor lesions in the chest (type I: 1, type IIA: 6, and type IV: 1; Table 2).

The average size of the defects was 14.5 cm × 12.5 cm (181.25 cm²), ranging from 3 to 595 cm². Defects in the lower limb and perineum were larger and required extensive flaps (Table 3). Large flaps were made with ratios of up to 6:1 regarding the defect area (Fig. 2). Type I or II flaps were initially designed. However, in some cases, progressive dissection was required to achieve adequate defect coverage, and so, the initial design was transformed into types III or IV as needed. The area remaining attached to the bed in each flap (non-dissected) was called *pedicular area* (range, 10%–90%). The average hospitalization time was 4.54 days. No patient was excluded from the sample.

Complications were defined as major (partial or total flap loss) and minor (dehiscence, cellulitis, and need for reoperation). The complication rate was 10.9%, and there were no major complications, and minor complications included 6 cases of dehiscence, 3 cases of reoperation, and 3 cases of cellulitis. Half of the dehiscence cases were managed with closure by secondary intention and the rest using delayed primary closure. Patients with cellulitis had previous infections, ie, osteomyelitis (n = 2) and urinary tract infection (n = 1), and required specific antibiotic treatment according to culture results (Table 4). In all cases, the reconstructive objectives were achieved. Sutures were removed after 21 days on average. The surgical time range was 15.8 to 204.6 minutes, with an average of 49.3 minutes.

Table 3. Keystone Flap and Resection Size for All Defects

Location	Flap Size (cm ²), Mean (Range)	Mean Defect, Size (cm ²)
All	223 (6–595)	142.7
Face	85 (6–192)	56.7
Torso	393 (203–460)	258.6
Perineum	150 (75–222)	108.6
Upper extremity	106 (12–140)	92.3
Lower extremity	302 (28–595)	205.1

Why Does a Keystone Flap Work?

Design and Biomechanics

Developed for closing elliptical defects,² this flap entails a highly efficient geometry that recalls the apical, trapezoidal, and curvilinear stones of the Roman arches. The KF should be designed on the defect's edge of greater cutaneous laxity. Classical marking draws a line at the ends of the primary defect with average angles of 90 degrees, reaching a 1:1 ratio with the amplitude of the initial defect and ending with a curvilinear line that joins these 2 lines at the outer edge of the KF.^{3–10} This design optimizes the available tissue and equates to 2 or even 3 V-Y island flaps^{3,10} (Fig. 1).

The location of the KF—with its major axis parallel to the defect^{5,8}—favors recruitment of tissue laxity in the flap center.^{6,11} This changes a soft-tissue primary defect without surrounding laxity for a secondary one with enough laxity in all margins, which allows to distribute the tension required for closure throughout the periphery.^{7,8} (See video, Supplemental Digital Content 1 which displays the initial defect changed to a secondary defect in the entire periphery. This video is available in the “Related Videos”

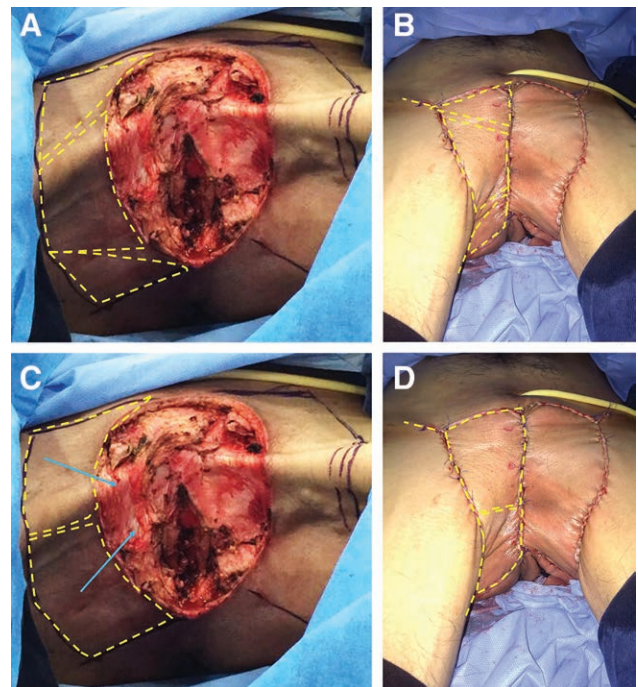


Fig. 1. Patient subjected to emasculation due to penis squamous cell carcinoma. A and C, Two keystone flaps are designed in a mirror fashion. B and D, Note how each flap equates 2 or 3 V-Y flaps.

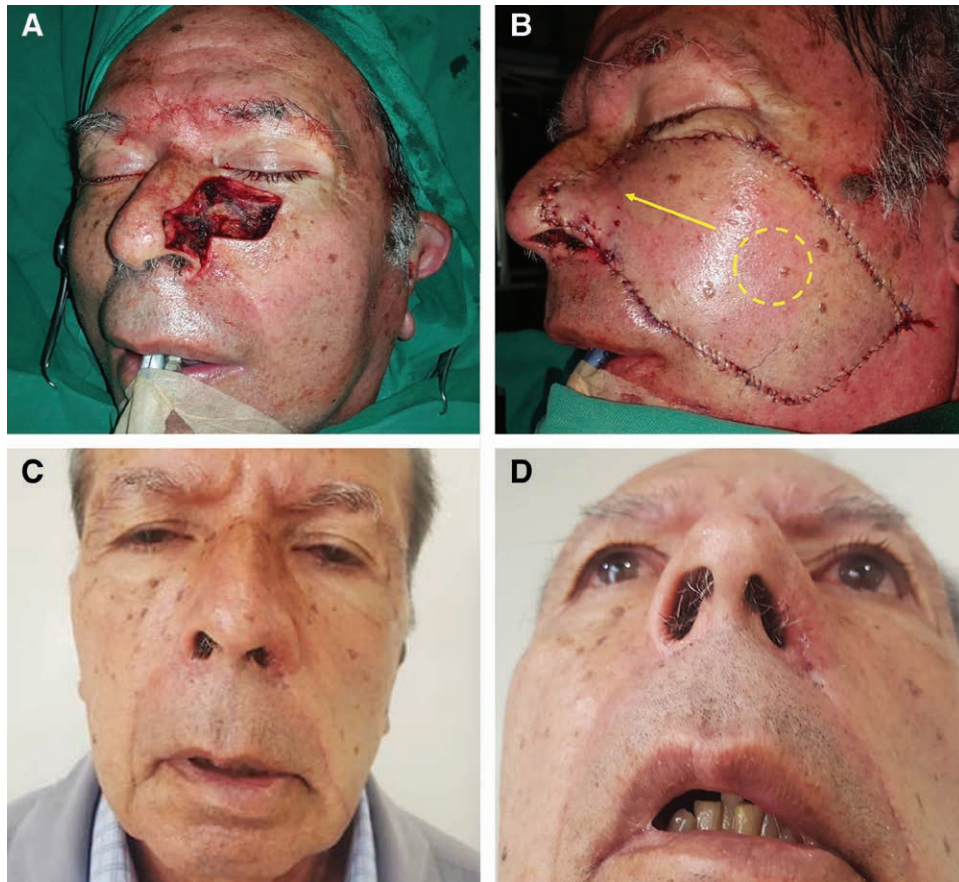

Fig. 2. A, Sixty-eight-year-old patient with basal cell carcinoma of the left sidewall, with a resection of the left nasal ala, sidewall, and lower eyelid. B, A flap with a 6:1 size ratio in relation to the defect is designed. It progresses after an 85% resection of the total flap area. The pedicular area is marked with a circle. The arrow indicates the direction of the advance. Its medial segment is carved to fit the contours and densities of the nasal ala, sidewall, and lower eyelid. An ear cartilage graft was used to support the ala. C and D, Reconstruction of the 3 aesthetic subunits was achieved without any harm and barely visible scars.

section of the Full-Text article on PRSGlobalOpen.com or at <http://links.lww.com/PRSGO/B13>.)

Besides cutaneous redistribution and closure tension, skin viscoelastic properties and many biomechanical aspects are important to prove the KF efficiency.^{7,12} However, none of these can be tested *in vivo* or *in vitro*. Theories to unveil their changes, interactions, and repercussions mutate frequently.¹³ Anyway, having successfully achieved the reconstructive objective in 100% of our series confirms the KF efficiency and clinical safety despite the absence of incontrovertible explanations.¹⁴

Physiology

Cutaneous circulation has been well documented. A wide network of blood vessels with intradermal, subdermal, and subcutaneous anastomotic connections^{15,16} is supplied from the deep tissues with the help of perforators of varied course and size that guarantee their perfusion. Based on the studies by Manchot¹⁷ and Salmon,¹⁸ Taylor and Palmer¹⁹ described around 400 perforators throughout the entire body that facilitate flap design on constant vascular zones. In our series, all KFs were ran-

domly designed on areas lacking perforators identifiable with Doppler, considering that any body part may contain perforators²⁰ capable of supplying cutaneous segments that overflow described borders of known angiosomes. This occurred due to the intervention of adjacent vascular systems through the opening of anastomotic networks^{21,22} in accordance with the concept of angiotoma.

The physiological changes described in the KF include hyperemic flare, red dot signs, and pain-free postoperative period.² In local flaps, an initial noradrenergic period has been documented that can extend up to 48 hours, until local catecholamines are depleted.²³ This phenomenon explains the initial vasoconstriction observed in these flaps. In contrast, the hyperemic flare—or immediate vasodilation—described in the KF has been compared with the effect of lumbar sympathectomy on the limbs.²⁴ It is then speculated that the perforators sustaining the subdermal plexus that nourishes the KF^{4,25,26} are immune to such vasoconstrictor effect and/or that, by dividing the subdermal plexus up to the fascia, a hydrostatic advantage is established in the perforator's flow.²³ This resembles the behavior of classic perforator flaps such as the anterolateral thigh.²⁷

Table 4. Major and Minor Complications

Complications	Value, n (%)
Major	
Total necrosis	0
Partial necrosis	0
Minor	
Wound dehiscence	6 (5.45)
Cellulitis	3 (2.72)
Second surgical procedure	3 (2.72)
Total	9 (10.9)

SURGICAL TECHNIQUE

Changes in the KF original design have been described in different studies.^{28,29} In this series, the trapezoidal design was always the first step. Based on this, the axes and edges were adapted to the donor area, maintaining, as much as possible, the major axis of the flap parallel to the defect and, at least in 1 end, the V-Y closure design to optimize the advance (Fig. 2).

Whenever possible, the major axis of the flap should be parallel to the cutaneous nerves and/or known perforators to include them^{4,12,30–33} or over the so-called hot spots.^{8,34} However, although presurgical perforator marking is strongly suggested,^{4,5,33,35–39} it was unnecessary in this series. Some studies have proposed an increase in the flap area in relation to the defect size to “recruit more perforators,” obtaining defect-size ratios of up to 5:1.^{4,8,40} In this series, it was found that larger flaps are not only possible but also ideal not for vascular safety but to replace the entire aesthetic subunits^{21,26,41} and make the scar less conspicuous. Besides, this could prevent the transgression of natural folds or the location of scars in the area of excessive pressure (Figs. 2 and 4).

Since Behan’s first description, it has been recommended to preserve superficial and tributary veins or even repair them to avoid venous stasis.³⁰ However, the present series proved that major advances cannot be made without circumferential incision of the flaps up to the fascia.^{8,36,42} This never caused persistent venous congestion or arterial damage that compromised flap viability; therefore, repair of a sacrificed vein was never considered.

A variation of the classic design is to preserve a cutaneous bridge as an additional source of vascularization.^{5,31,33,37,43} Cutaneous pedicles are unnecessary and even harmful^{38,44} since they generate flow resistance at the flap edges.³⁸ A design without dermal bridges prevents a hemodynamic arrest³⁹ and redirects the preferential vascular flow to the flap periphery.^{45,46} All present cases were carved as island flaps. There were no partial or total flap losses, significant incidence of lymphedema, or healing problems. In agreement with other studies,^{9,10} we consider that such variation limits KF mobilization and is more valued for treating the surgeon’s anxiety^{47,48} than for KF vascular safety. (See video, Supplemental Digital Content 2 which displays the advancement of a complete islanded Keystone flap. This video is available in the “Related Videos” section of the Full-Text article on PRSGlobalOpen.com or at <http://links.lww.com/PRSGO/B14>.)

Unlike typical perforator flaps, KF surgical technique does not require identification and skeletonization of

source vessel or specific perforator. This eliminates the risks, complexity, morbidity, and surgical time implied in these procedures.^{49,50} Preservation of cutaneous nerves is recommended to exploit neurocutaneous circulation^{22,51} and to preserve KF sensitivity.^{4,6} Interestingly, many of this series flaps exhibited sensitivity in the postoperative period despite the sectioning of the superficial nerves and small anchorage areas. The reason for this is still unknown.

The vascular safety of KF is undoubtedly the greatest surgical concern since the area that remains attached to the bed guarantees perfusion. However, the greater the anchoring area, the smaller the flap advance potential.^{6,30,37,46,52} Based on this, gradually larger dissections have been reported, for example, Behan et al.^{28,53} and Kostopoulos et al.⁴¹ have dissected up to two-third of the island in the subfascial plane.

In the present series, subfascial dissection became gradually more aggressive. It was first used in larger flaps (area >10 cm²) and then became applicable to any KF. Dissection starts from the periphery and progresses as needed, narrowing the flap attaching area to its bed, which has been called *pedicular area* (PA). In this area, no specific vessel or perforator was isolated or previously identified, but it clearly fulfilled the flap vascular requirements. It can be inferred that this area contains ubiquitous perforators or microperforators²⁰ with the same flow enhancement observed in isolated perforators of classical flaps.²⁷ The PA could be reduced to near 10%; in other words, up to 90% of the flap was dissected without harm, far exceeding the ranges recommended by Behan himself (Fig. 3; see Video, Supplemental Digital Content 2).

The PA narrowing is only the result of the tissue mobilization needs, regardless of the flap size or the anatomical area in which it is designed. In this series, dissections >90% (PA < 10%) were successfully performed on the face, back, thorax, arms, hands, and legs. Whenever possible, the PA should be located on the so-called hot spots. KFs with narrow PAs presented a different behavior. Initially, they showed a period of variable duration with evident venous congestion followed by a vasoconstriction or “white phase,” which was always sorted without compromising the KF vitality (Fig. 3). In the authors’ experience, the progress achieved with these flaps is proportional to the depth of the tissues affected and the amount of tissue lifted from its bed. Therefore, according to each clinical requirement, the advance can be sequentially increased via 3 ways:

1. To design (if possible) flaps larger than the defect, especially if the tissue has been irradiated or presents burns sequelae, as fibrosis secondary to these injuries can hinder tissue mobility.
2. To intervene the underlying fascia on the entire perimeter of the flap.
3. To dissect the KF in a subfascial plane from the flap periphery to the chosen pedicular area, which progressively narrows from a wide central area to a smaller one, distal to the edge of the defect.

4. To choose a not necessarily central pedicular area when designing the omega variant.⁵³ The sum of the central zone axial advance and that achieved by the rotation and advance of the lateral segments allows covering more extensive and distant defects (Fig. 3).

The vascular safety of these flaps is such that, within the same KF, it was possible to carve different densities ranging from thick fasciocutaneous segments to delicate dermofat segments of a few millimeters thick. This allowed reconstructing complex defects with variable contours, filling dead spaces, and covering sensitive areas such as the perineum or the eyelids^{8,28} (Figs. 2 and 4).

During the closure, it is not necessary to dissect the tissues adjacent to the defect.³⁶ Only in exceptional cases, a second flap is required to facilitate closure.⁸ Depending on the flap thickness or if points of above average tension are perceived, closure by planes is preferred. A Hemming suture is used in cases of considerable tension; otherwise,

a continuous suture is made with absorbable material for children and polypropylene for adults.

DISCUSSION

The advantages of locoregional reconstruction have been widely discussed in the existent literature.⁸ The aesthetic results of stable coverage with tissues adjacent to the initial defect are extremely superior to those of techniques that transport distant tissues, which lack the desired “like to like” effect⁵¹ and require nerve repair to obtain protective sensitivity.⁵⁴

Short surgical times^{36,37,42,50,55} without complex intra-surgical or postsurgical monitoring, a single operative field, and a more “stable” perfusion⁵⁰ are some of the additional advantages of KF that reduce morbidity, mortality, and intrahospital stay.^{31,33} This differs from the microvascular options that require a wide learning curve and large resources for its execution.^{30,56}

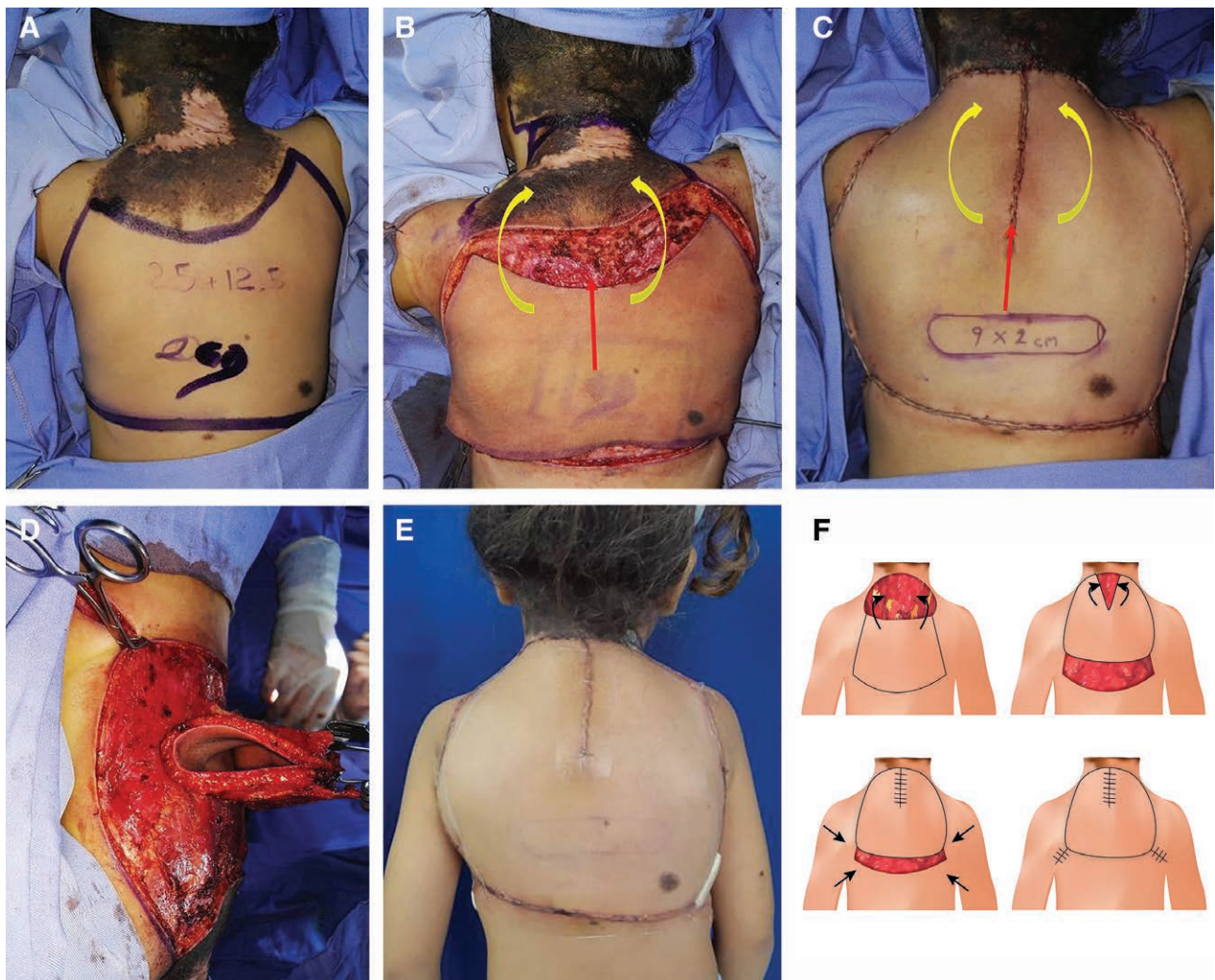


Fig. 3. A and B, Four-year-old patient with giant congenital melanocytic nevus, 70% of which is resected at the cervico-dorsal portion. An omega KF is elevated at 312.52 cm. The arrows point the direction of the closure achieved by axial advance of the central portion (red arrow) and the rotation and advance of the lateral portions (yellow arrows). C, Marking of the pedicular area (18 cm²). Note the flap pale color at the time of closure. D, Details of the pedicular area after lifting almost 95% of the KF. E, Fifth postoperative day, without complications. F, Geometrical outline of the flap and its omega closure.

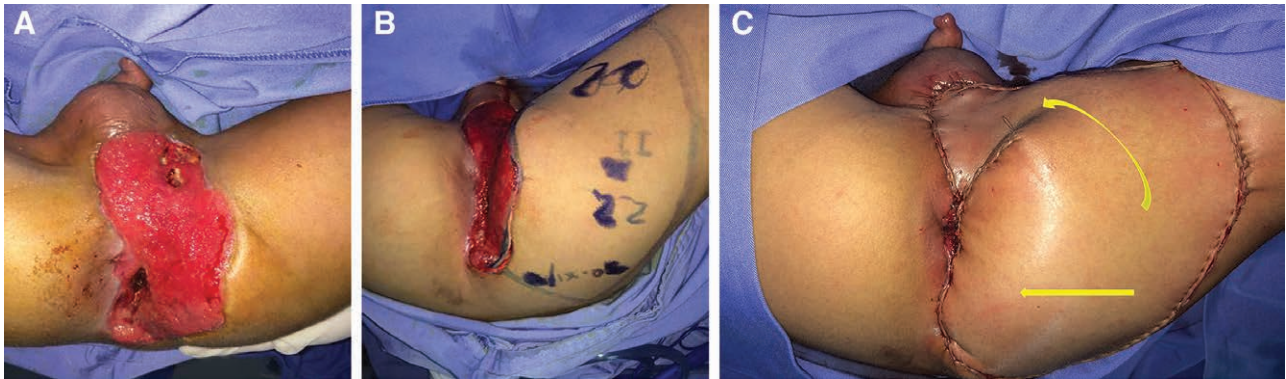


Fig. 4. A, Eight-year-old patient diagnosed with acute lymphoid leukemia. Details of a large perineal and left gluteal defect secondary to surgical debridement due to Fournier gangrene. B, Design of a single KF with a 70% resection, sculpted with different densities. C, The anterior portion has been elevated as a thin dermocutaneous segment that advances and rotates for perineal reconstruction. The posterior portion is a thick dermal and fat cushion for reconstruction of the gluteus without damage on tissue perfusion. Note the transition among the scrotum, perineum, and gluteus, which maintains the previous anatomical geography because of the freestyle sculpting. A, The design of a larger island also locates the scars away from pressure zones such as the ischial area.

Due to its versatility, the KF has been used in defects of varied etiology and in all age groups.^{4,6,8,37,28,57-59} They have allowed coverage that, given their extension, would require free flaps or classic perforator flaps.^{36,37,40,42,51,28,60-64} (See video, Supplemental Digital Content 3 which displays the defect secondary to parotid oncological resection covered with a Keystone flap. This video is available in the “Related Videos” section of the Full-Text article on PRSGlobalOpen.com or at <http://links.lww.com/PRSGO/B15>.)

Narrowing the PA provides wider movement arcs and, contrary to some opinions,^{37,61} allows advances over 20 cm,⁵¹ and rotations of up to 180 degree.²⁸ These are similar to the helical flap results, without the technical difficulties, poor cosmetic results,^{8,31} and morbidity that it entails. Unlike some literature findings,^{6,63} we consider the KF as a great alternative for the complete reconstruction

of entire facial subunits, the recruitment of muscle components (orbicularis oris, orbicularis oculi,⁶⁵ and platysma²²), and the successful mobilization of innervated tissues. Compared with skin grafts, KFs are not only more efficient but also lack their undesirable effects such as retraction, pigmentation, lack of volume, and donor area morbidity (Fig. 5).

The concept of pedicular area contributes to the KF biomechanical efficiency. The fact that extensive tissue areas, supplied in tiny random pedicles and supported by ubiquitous microperforators, survive without any vascular damage breaks the anatomical paradigms of local flaps and raises questions about the dynamics of tissue perfusion.

Of course, the KF technique has limitations. Its efficiency in intraoral and intranasal coverage has not been sufficiently proven. Its fasciocutaneous and musculocutaneous nature lacking bone components⁶³ excludes them

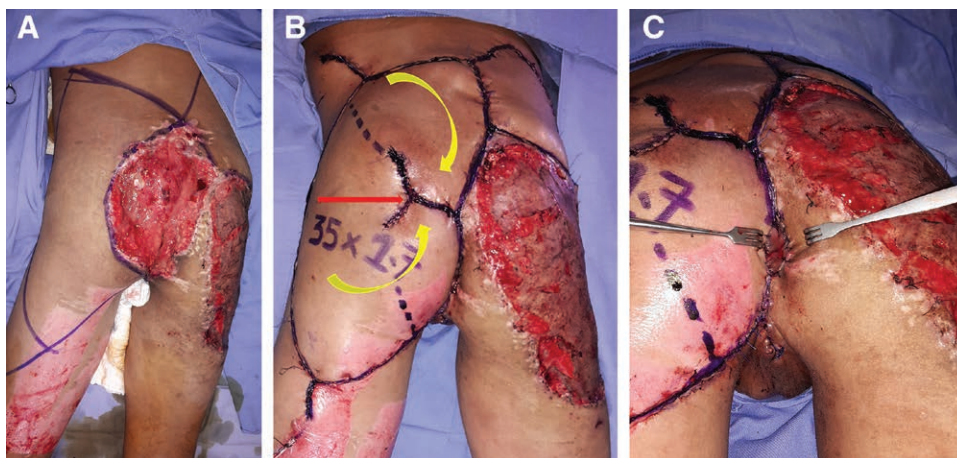


Fig. 5. A, Twelve-year-old patient who had a traffic accident and a Morel–Lavallée lesion with a defect in the lumbar and gluteal regions. The defect compromised half of the anus circumference. A 595-cm² KF on the left side with a 30% pedicular area and a second KF on the right side to close the cephalic portion of the defect are designed. B, Details of rotation and advancement of omega flap, adapting the segments needed to surround the anus. C, Detail of attachment to anus and “like to like” effect compared to the contralateral area that had been previously grafted by another surgeon.

from scenarios with these specific requirements. Besides, due to its vascular dependence on perforators, caution should be exercised in areas surgically or traumatically dissected. As in any other technique, the design of the island must be careful to avoid transgression of natural folds or scar location on areas of excessive pressure. To do so, it is recommended to design larger islands as previously mentioned.

In sum, KF's versatility, functional and aesthetic results, and low complication rate (3%–4.6%)^{5,36} have far exceeded the expectations of any random perforator or flap. The KF allows reconstruction in a single surgical time^{5,36} and is a relatively easy and fast technique²⁸ for the beginner and the experienced surgeon. Economic considerations are not a minor issue in a context of financial sustainability of the health system of countries such as Colombia. Nowadays, there is an underestimation of techniques such as the one discussed here.

CONCLUSIONS

Plastic surgeons have come a long way to find a reconstructive strategy that (1) provides similar tissues in terms of function, texture, color, and sensitivity; (2) is versatile for any reconstructive requirement; (3) provokes minimal or no aesthetic or functional morbidity of donor areas; (4) entails short surgical times; and (5) is replicable, with short learning curves and without large infrastructure requirements.

Without ignoring the abovementioned limitations, the KF satisfies practically all of these requirements. The concept of ubiquitous microperforators, not detectable by conventional techniques and capable of supplying extensive segments of soft tissues, breaks the paradigm of fixed, anatomically identifiable pedicles. It opens the way to what we might call “freestyle pedicles” or “random pedicular area,” free of the complex and expensive technical requirements of the perforator or free flaps.

However, given the heterogeneity of the age groups, comorbidities, and anatomical areas considered adverse to flap perfusion, new cohorts with a larger number of patients and more strict inclusion criteria are necessary to validate our conclusions.

We believe that the development of microsurgery is an elegant and sophisticated response to previously insoluble problems. However, it is no less true that there is a current increasing overindication of these procedures with a parallel disdain for techniques with better cost-effectiveness.

In short, more studies are needed to better understand the physiological adaptations of KF. However, the clinical evidence is irrefutable and supports its use in many reconstructive scenarios, which undoubtedly allows the decentralization of health care and provides an invaluable tool with superior results.

Oswaldo J. Gómez, MD
Edificio Altos del Bosque
Calle 134 # 7-83, Consultorio 232
Bogotá, Colombia
E-mail: oswaldogomez@me.com

REFERENCES

- Behan F, Wilson I. The principle of the angiotome, a system of linked axial pattern flaps. Paper presented at the *Sixth International Congress of Plastic and Reconstructive Surgery*; 1975; Paris.
- Behan FC. The keystone design perforator island flap in reconstructive surgery. *ANZ J Surg*. 2003;73:112–120.
- Behan FC, Rozen WM, Kapila S, et al. Two for the price of one: a keystone design equals two conjoined V-Y flaps. *ANZ J Surg*. 2011;81:405–406.
- Pelissier P, Gardet H, Pinsolle V, et al. The keystone design perforator island flap. Part II: clinical applications. *J Plast Reconstr Aesthet Surg*. 2007;60:888–891.
- Moncrieff MD, Bowen F, Thompson JF, et al. Keystone flap reconstruction of primary melanoma excision defects of the leg—the end of the skin graft? *Ann Surg Oncol*. 2008;15:2867–2873.
- Hu M, Bordeaux JS. The keystone flap for lower extremity defects. *Dermatol Surg*. 2012;38:490–493.
- Shayan R, Behan FC. Re: the “keystone concept”: time for some science. *ANZ J Surg*. 2013;83:499–500.
- Mohan AT, Rammos CK, Akhavan AA, et al. Evolving concepts of keystone perforator island flaps (KPIF): principles of perforator anatomy, design modifications, and extended clinical applications. *Plast Reconstr Surg*. 2016;137:1909–1920.
- Douglas CD, Low NC, Seitz MJ. The keystone flap: not an advance, just a stretch. *Ann Surg Oncol*. 2013;20:973–980.
- Pauchot J, Chambert J, Remache D, et al. Geometrical analysis of the V-Y advancement flap applied to a keystone flap. *J Plast Reconstr Aesthet Surg*. 2012;65:1087–1095.
- Hessam S, Sand M, Bechara FG. The keystone flap: expanding the dermatologic surgeon's armamentarium. *J Dtsch Dermatol Ges*. 2015;13:70–72.
- Douglas C, Morris O. The ‘keystone concept’: time for some science. *ANZ J Surg*. 2013;83:498–499.
- Penington T. Science and the keystone flap. *ANZ J Surg*. 2013;83:496–497.
- Findlay MW, Kleid S. The keystone concept: a time for good science. *ANZ J Surg*. 2014;84:194–195.
- Saint-Cyr M, Wong C, Schaverien M, et al. The perforasome theory: vascular anatomy and clinical implications. *Plast Reconstr Surg*. 2009;124:1529–1544.
- Braverman IM. The cutaneous microcirculation. *J Investig Dermatol Symp Proc*. 2000;5:3–9.
- Manchot C. *The Cutaneous Arteries of the Human Body*. 1st ed. New York: Springer-Verlag; 1983.
- Salmon M. *Arteries of the Skin*. 1st ed. London: Livingstone, Churchill; 1988.
- Taylor GI, Palmer JH. The vascular territories (angiosomes) of the body: experimental study and clinical applications. *Br J Plast Surg*. 1987;40:113–141.
- Sinna R, Bolorchi A, Mahajan AL, et al. What should define a “perforator flap”? *Plast Reconstr Surg*. 2010;126:2258–2263.
- Kostopoulos E, Casoli V, Agiannidis C, et al. The keystone perforator island flap in nasal reconstruction: an alternative reconstructive option for soft tissue defects up to 2cm. *J Craniofac Surg*. 2015;26:1374–1377.
- Behan FC, Rozen WM, Wilson J, et al. The cervico-submental keystone island flap for locoregional head and neck reconstruction. *J Plast Reconstr Aesthet Surg*. 2013;66:23–28.
- Behan FC, Lo CH, Sizeland A. The interpretation of vascular changes observed in keystone island flaps: a hypothesis. *J Plast Reconstr Aesthet Surg*. 2010;63:e215–e216.
- Behan FC, Lo CH. Vascular dynamics of the keystone island flap: ongoing observations similar to sympathectomy. *ANZ J Surg*. 2009;79:861.

25. Pelissier P, Santoul M, Pinsolle V, et al. The keystone design perforator island flap. Part I: anatomic study. *J Plast Reconstr Aesthet Surg*. 2007;60:883–887.
26. Chaput B, de Bonnecaze G, Lopez R, et al. Modified keystone island flap design for lateral nasal defect: aesthetic subunit consideration. *Plast Reconstr Surg Glob Open*. 2014;2:e213.
27. Rubino C, Coscia V, Cavazzuti AM, et al. Haemodynamic enhancement in perforator flaps: the inversion phenomenon and its clinical significance. A study of the relation of blood velocity and flow between pedicle and perforator vessels in perforator flaps. *J Plast Reconstr Aesthet Surg*. 2006;59:636–643.
28. Behan FC, Lo CH, Sizeland A, et al. Keystone island flap reconstruction of parotid defects. *Plast Reconstr Surg*. 2012;130:36e–41e.
29. Behan FC, Rozen WM, Azer S, et al. 'Perineal keystone design perforator island flap' for perineal and vulval reconstruction. *ANZ J Surg*. 2012;82:381–382.
30. Behan F, Sizeland A, Porcedu S, et al. Keystone island flap: an alternative reconstructive option to free flaps in irradiated tissue. *ANZ J Surg*. 2006;76:407–413.
31. Moncrieff MD, Thompson JF, Stretch JR. Extended experience and modifications in the design and concepts of the keystone design island flap. *J Plast Reconstr Aesthet Surg*. 2010;63:1359–1363.
32. Pikturnaite J, Mashhadi S. Enhanced robustness and mobility of the keystone flap. *Dermatol Surg*. 2014;40:1054–1056.
33. Stone JP, Webb C, McKinnon JG, et al. Avoiding skin grafts: the keystone flap in cutaneous defects. *Plast Reconstr Surg*. 2015;136:404–408.
34. Abraham JT, Saint-Cyr M. Keystone and pedicle perforator flaps in reconstructive surgery: new modifications and applications. *Clin Plast Surg*. 2017;44:385–402.
35. Mohan AT, Sur YJ, Zhu L, et al. The concepts of propeller, perforator, keystone, and other local flaps and their role in the evolution of reconstruction. *Plast Reconstr Surg*. 2016;138:710e–729e.
36. Khouri JS, Egeland BM, Daily SD, et al. The keystone island flap: use in large defects of the trunk and extremities in soft-tissue reconstruction. *Plast Reconstr Surg*. 2011;127:1212–1221.
37. Rao AL, Janna RK. Keystone flap: versatile flap for reconstruction of limb defects. *J Clin Diagn Res*. 2015;9:PC05–PC07.
38. Behan FC. The fasciocutaneous island flap: an extension of the angiotome concept. *Aust N Z J Surg*. 1992;62:874–886.
39. Mešić H, Kirkebøen KA, Bains R. The importance of a skin bridge in peripheral tissue perfusion in perforator flaps. *Plast Reconstr Surg*. 2012;129:428e–434e.
40. Gutman MJ, Goldschlager T, Fahardieh RD, et al. Keystone design perforator island flap for closure of myelomeningocele. *Childs Nerv Syst*. 2011;27:1459–1463.
41. Kostopoulos E, Agiannidis C, Konofaos P, et al. Keystone perforator island flap as an alternative reconstructive option for partial thickness alar defects up to 1.5 centimeters. *J Craniofac Surg*. 2016;27:1256–1260.
42. Aguilera-Sáez J, Sanz-Gil F, Palao-Domènech R, et al. Reconstrucción de defectos amplios en tronco mediante colgajo de perforante en piedra clave. *Rev Latinoam Cir Plast*. 2014;40:403–411.
43. Shipkov CD, Mojallal A. The keystone island and pedicle flap: a handy local flap for soft tissue reconstruction. *Ann Surg Oncol*. 2008;15:3625.
44. Milton SH. Experimental studies on island flaps. 1. The surviving length. *Plast Reconstr Surg*. 1971;48:574–578.
45. Lo CH, Menezes H, Behan F. The island perforator flap design augments vascularity. *Plast Reconstr Surg*. 2013;132:468e–469e.
46. Behan FC, Sizeland A. Reiteration of core principles of the keystone island flap. *ANZ J Surg*. 2006;76:1127–1129.
47. Lo CH, Nottle T, Mills J. Keystone island flap: effects of islanding on vascularity. *Plast Reconstr Surg Glob Open*. 2016;4:e617.
48. Behan FC, Lo CH, Shayan R. Perforator territory of the keystone flap—use of the dermatomal roadmap. *J Plast Reconstr Aesthet Surg*. 2009;62:551–553.
49. Behan FC, Lo CH, Findlay M. Anatomical basis for the keystone island flap in the upper thigh. *Plast Reconstr Surg*. 2010;125:421–423.
50. Hamahata A, Saitou T, Ishikawa M, et al. Usefulness of keystone island flap for circumferential defect around a urostomy. *Int Cancer Conf J*. 2013;2:188–190.
51. Behan FC, Paddle A, Rozen WM, et al. Quadriceps keystone island flap for radical inguinal lymphadenectomy: a reliable locoregional island flap for large groin defects. *ANZ J Surg*. 2013;83:942–947.
52. Jackson IT. The keystone design perforator island flap in reconstructive surgery. *ANZ J Surg*. 2003;73:261.
53. Behan FC, Rozen WM, Lo CH, et al. The omega - Ω - variant designs (types A and B) of the keystone perforator island flap. *ANZ J Surg*. 2011;81:650–652.
54. Behan F. Evolution of the fasciocutaneous island flap leading to the keystone flap principle in lower limb reconstruction. *ANZ J Surg*. 2008;78:116–117.
55. Sliesarenko SV, Badiul PO, Sliesarenko KS. Extensive mine-shrapnel and gunshot wound closure using keystone island perforator flaps. *Plast Reconstr Surg Glob Open*. 2016;4:e723.
56. Findlay MW, Sinha S, Rotman A, et al. The keystone perforator island flap in head and neck reconstruction : indications and outcomes from 200 flaps. *Plast Reconstr Surg*. 2013;132:8–9.
57. Taleb M, Choi L, Kim S. Safety and efficacy of the keystone and rhomboid flaps for immediate reconstruction after wide local excision of non-head and neck melanomas. *World J Surg Oncol*. 2016;14:269.
58. Wong C. Review: the keystone perforator island flap concept. *Plast Reconstr Surg*. 2013;131:427.
59. Al-Busaidi AA, Semalesan N, Al-Busaidi SS. Keystone design sliding skin flap for the management of small full thickness burns. *Sultan Qaboos Univ Med J*. 2011;11:412–414.
60. Behan FC, Findlay M, Lo CH. *The Keystone Perforator Island Flap Concept*. Sydney: Churchill Livingstone; 2012.
61. Magliano J, Falco S, Agorio C, et al. Modified keystone flap for extremity defects after Mohs surgery. *Int J Dermatol*. 2016;55:1391–1395.
62. Sinha S, Yip MJ, Gill S, et al. A giant fungating metastatic basal cell carcinoma of the back and novel reconstruction using two large keystone design island perforator flaps. *J Plast Reconstr Aesthet Surg*. 2013;66:1015–1018.
63. Chen HC. Precautions in using keystone flap. *J Plast Reconstr Aesthet Surg*. 2010;63:720.
64. Behan FC, Rozen WM, Tan S. Yin-Yang flaps: the mathematics of two keystone island flaps for reconstructing increasingly large defects. *ANZ J Surg*. 2011;81:574–575.
65. Loh IW, Rozen WM, Behan FC, et al. Eyelid reconstruction: expanding the applications of the keystone perforator island flap concept. *ANZ J Surg*. 2012;82:763–764.