

A transseptal puncture hazard that was close!



Mehdi Taherpour, MD,^{*} Zahra Emkanjoo, MD[†]

From the ^{*}Department of Electrophysiology, Razavi Hospital, Mashhad, Iran, and [†]Department of Electrophysiology, Rajaie Cardiovascular Research and Medical Center, Iran University of Medical Sciences, Tehran, Iran.

Introduction

The possible complications of transseptal puncture occur in approximately 1% of procedures. In the electrophysiology setting, increased pericardial effusion or tamponade risk is associated with left-sided arrhythmia ablations. Reported complications relate to aortic puncture or left/right atrial free wall perforation.¹ There is much anatomical variation in the intra-atrial septum and subsequently the transseptal needle may not always fall into the fossa ovalis. The presence of previous interventions on the atrial septum, dilated atria, dextrocardia, or prior heart surgery have varying degrees of anatomic atrial distortion, resulting in fossa ovalis displacement² and representing a challenge to transseptal puncture owing to movable traditional landmarks.

Case report

A 58-year-old man with a history of coronary artery bypass graft and aortic valve replacement and implanted by a cardiac resynchronization therapy device presented with recurrent episodes of ventricular tachycardia necessitating device interventions. The patient was referred for ablation.

Transseptal puncture using a Brockenbrough needle was guided by fluoroscopy. According to fluoroscopy, the transseptal needle had a correct position, but the contrast injection revealed that it was actually pointing toward the aortic root and, most importantly, that it was impossible to stabilize the fossa itself (Figure 1).

In order to guide the transseptal needle, a transesophageal echocardiogram probe was inserted and revealed a small fossa abutting to a dilated aorta anteriorly. It also revealed a dilated and tortuous ascending aorta (Supplemental Material, available online).

KEYWORDS Transseptal puncture; Inadvertent puncture; Catheter ablation; Ventricular tachycardia; Aortic root
(Heart Rhythm Case Reports 2016;2:484–485)

Address reprint requests and correspondence: Dr Zahra Emkanjoo, Department of Electrophysiology, Rajaie Cardiovascular Research and Medical Center, Iran University of Medical Sciences, Vali-asr Ave., Adj. to Mellat Park, 1996911151, Tehran, Iran. E-mail address: Zahra.emkanjoo@gmail.com.

Based on transesophageal echocardiogram guidance, the needle was pointed toward the septum and pushed through to the left atrium; however, on advancing the sheath and ablation catheter, a resistance was felt during catheter manipulation. By contrast injection to confirm the position of the catheter, it became evident that it had entered the left coronary artery (Figure 2).

The procedure was stopped. In the presence of a cardiac surgeon, a stiff guide wire was passed across the puncture site and the whole assembly was withdrawn. The sheath removal was uneventful. Serial echocardiography showed no pericardial effusion. Aortic root injection, performed 30 minutes after the patient's condition become stable, showed a very dilated aorta (Figure 3).

Subsequent echocardiography demonstrated no evidence of pericardial effusion or perforation of aortic cusps causing aortoatrial shunt.

Discussion

Our interesting finding was that there was occurrence of neither pericardial effusion nor aorta–right atrial shunt after sheath removal from the aorta. This absence might be related to a flap that closed up the connection between the aorta and right atrium owing to higher aortic pressure. Another

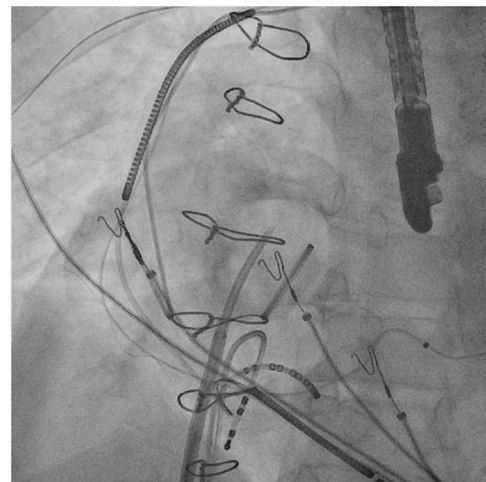


Figure 1 Emission of contrast material into the pericardial cavity, delineating the aortic root.

KEY TEACHING POINTS

- In the case of difficult anatomies as well as prior aortic root surgery, adjuncts to fluoroscopic visualization, such as intracardiac or transesophageal echocardiography, are most useful and aid in the safety of transseptal catheterization. Transthoracic echocardiography has limited utility, but transesophageal echocardiography and intracardiac echocardiography are more useful.
- The key to a successful procedure is a thorough understanding of the anatomy of the fossa ovalis and the surrounding landmarks.
- Puncture into the left atrium should be confirmed by pressure transduction through the needle.
- The existence of pericardial adherence following cardiac surgery could prevent the occurrence of tamponade after inadvertent insertion of the ablation catheter into the aorta.

possible reason is that the existence of pericardial adherence following previous cardiac surgery prevents the occurrence of pericardial effusion.

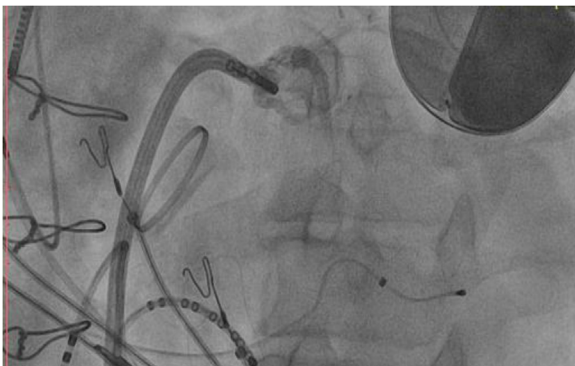

Figure 2 Fluoroscopic left anterior oblique view of the transseptal sheath across the aorta with contrast in left coronary arteries.

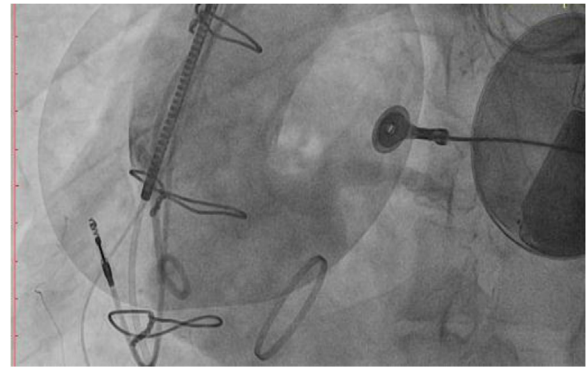


Figure 3 Aortic root injection shows a very dilated aorta.

A covered stent as a nonsurgical alternative may be considered after puncture of aortic root during transseptal puncture. A free rupture mandates the use of a covered stent to seal off the perforation.

As this case highlights, a comprehensive understanding of patient anatomy is critically important for performing transseptal puncture. It is recommended that intracardiac echocardiography be used in addition to fluoroscopy when performing transseptal puncture.

The pressure transduction helps to determine whether the needle has punctured into the left atrium or the aorta. In this case, we did not use a pressure transduction. Pressure monitoring could have mitigated this inadvertent aortic puncture.

Appendix

Supplementary data

Supplementary data associated with this article can be found in the online version at <http://dx.doi.org/10.1016/j.hrcr.2016.06.011>.

References

1. De Ponti R, Cappato R, Curnis A, Della Bella P, Padeletti L, Raviele A, Santini M, Salerno-Uriarte J. Trans-septal catheterization in the electrophysiology laboratory: data from a multicenter survey spanning 12 years. *J Am Coll Cardiol* 2006;47:1037–1042.
2. Ho SY, Cabrera JA, Sanchez-Quintana D. Left atrial anatomy revisited. *Circ Arrhythm Electrophysiol* 2012;5:220–228.