



Review

Three-dimensional Computerized Tomography and Multiplanar Imaging of Developmental Hip Dysplasia

Müjdat Bankaoğlu

Department of Radiology, Sisli Hamidiye Etfal Training and Research Hospital, Istanbul, Turkey

Abstract

Developmental dysplasia of the hip (DDH) is still one of the biggest orthopedic problems in the world. Global poverty and refugee crises have led to it becoming a greater issue even in developed nations. Early diagnosis and effective treatment of DDH are required to prevent the possibility of arthrosis, limb shortening, pelvic asymmetry, and vertebral scoliosis. In late cases, surgery is the only choice for correction. Direct radiography has been used for many years and continues to have an important role, though ultrasonography is the primary source for early postnatal screening. Although magnetic resonance imaging (MRI) has become an important modality to provide sectional imaging in many cases, in late-period dysplasia, computed tomography (CT) and three-dimensional (3D) CT are preferred because it can more effectively demonstrate the cortical bony structures. The aim of this review was to demonstrate the effectiveness of 3D CT and multiplanar reconstruction based on previous studies.

Keywords: Developmental hip dysplasia; imaging; multiplanar imaging; three-dimensional computerized tomography.

Please cite this article as "Bankaoğlu M. Three-dimensional Computerized Tomography and Multiplanar Imaging of Developmental Hip Dysplasia. Med Bull Sisli Etfal Hosp 2019;53(2):103-109".

Examination, early diagnosis, follow-up, and treatment of infants at risk for developmental dysplasia of the hip (DDH) remains an orthopedic problem with vital importance both in our country and the world.

Low-dose multislice computed tomography (MSCT) is already the most commonly used modality in cases of trauma, and provides an alternative to cardiac coronary imaging and cranial angiography applications with the aid of a multiprocessor computer support system.

In skeletal system imaging, computer-assisted high-speed volume examination followed by multiplanar imaging and 3-dimensional (3D) reconstruction provides excellent visualization of bone structures.

The thesis that congenital hip dislocation and acetabular dysplasia are independent entities is no longer seen as valid. Most researchers now accept that acetabular dysplasia

develops secondary to hip dislocation.

Surgical intervention is the only treatment option in late-term hip dysplasia and imaging is important in both surgery and follow-up.

Ultrasonographic (US) examination is used to detect hip dysplasia within the first 3 months of life. However, the femoral epiphyses become ossified 3 to 6 months post partum and US images can no longer provide complete information. Classic radiographs-anteroposterior (AP) radiograms can demonstrate hip dysplasia in patients aged less than months.^[1,2]

Hip dysplasia in advanced age may include pathological iliac bone flattening, femoral head hypoplasia, and the formation of pseudoarticulation or arthrosis between the gluteal muscles caused by the femoral head leaning against high-lying wing of the iliac bone.

Address for correspondence: Müjdat Bankaoğlu, MD. Sisli Hamidiye Etfal Egitim ve Arastirma Hastanesi, Radyoloji Anabilim Dalı, Istanbul, Turkey

Phone: +90 212 373 50 00-4623 **E-mail:** mujdatbank@yahoo.com

Submitted Date: January 29, 2019 **Accepted Date:** February 18, 2019 **Available Online Date:** April 25, 2019

©Copyright 2019 by The Medical Bulletin of Sisli Etfal Hospital - Available online at www.sislietfaltip.org

OPEN ACCESS This is an open access article under the CC BY-NC license (<http://creativecommons.org/licenses/by-nc/4.0/>).



Uncorrected hip dysplasia is also associated with shortness of the ipsilateral extremity, rotation anomaly of the atrophic femur, pelvic deformation, and lumbar scoliosis.

Correction of hip dysplasia in advanced-age patients should be performed surgically. Depending on the level and severity of the pathology, as well as patient age and any presence of arthrosis, several surgical methods may be applied.

This review examines the contribution of 3D hip tomography images to the visualization of the bony pelvis and the selection of the type of operation in cases of delayed dysplasia requiring operative intervention.

Pathology of DDH

The incidence of congenital hip dysplasia, now known as developmental dysplasia of the hip (DDH), is approximately 0.13% and the ratio of girls to boys is approximately 8:1. It is frequently seen in twins as a result of poor fetal location. In infants with a breech presentation, in combination with neuromuscular pathology, in patients with a foot deformity, and in cases of oligohydramnios. Premature infants are also considered at risk because they do not complete their full intrauterine development. Though there is no definitive association, there is a greater probability of DDH occurring in children with family history of the condition. It has been suggested that the risk increases for infants born in winter due to improper swaddling. The left hip is involved 3 times more than the right, and the incidence of bilateral DDH is greater than that of the right side alone (1, 2, 3).

In hip dysplasia, the joint capsule and ligamentum teres are strained. The capsule may develop an hourglass shape. Fibrocartilage may enter the labrum joint and further deteriorate joint stability. Contracture develops in the iliopsoas and gluteal muscles. In the untreated hip, the probability of femoral and acetabular anteversion increases and the femoral head loses its roundness. Femoral anteversion can sometimes reach up to 60° to 90°. The bony acetabular roof flattens further, and a false acetabulum is often observed in the upper posterior aspect of the iliac wing. The femoral head migrates to the upper segment of iliac wing.

In late cases, serious orthopedic problems occur and the ipsilateral leg cannot complete its development, which typically leads to limping.

Algorithmic Approach to the Diagnosis

A newborn with risk factors for DDH should be examined by a clinician. The child is laid on their back and the Ortolani and Barlow tests are performed. If an abduction limitation in the leg or asymmetry in the hip or folds is observed, or if the Ortolani or Barlow test results are positive, an AP pelvic X-ray image may be obtained in the neutral position to exclude any other anomalies after this stage.

Sometimes, the hip joint may appear normal on an X-ray though there are pathological findings during the examination.^[4] Many abnormal findings detected in newborns may be normal a week later.

If in the first examination of the newborn, hip dislocation suspected, generally, an US is performed. US image quality deteriorates as the femoral epiphyses begin to ossify after 3 months. Ossification is easily monitored using a classic X-ray examination, which may also be used for follow-up (Fig. 1).

In advanced stages, when complete epiphyseal ossification occurs, CT and magnetic resonance (MR) images are used.

Usually, newborns with suspected DDH undergo US 1 week after the examination. If there is a serious dislocation, emergency treatment and fixation are performed. Borderline cases are checked with US at 1-month intervals until the epiphyseal ossifications are fully formed. The bone and cartilage structures of the iliac bone are measured and followed up, as described by Graf in 1984 (Fig. 2).

Follow-up is achieved with AP pelvic radiograms taken in a classic neutral position as the ossifications of the femoral

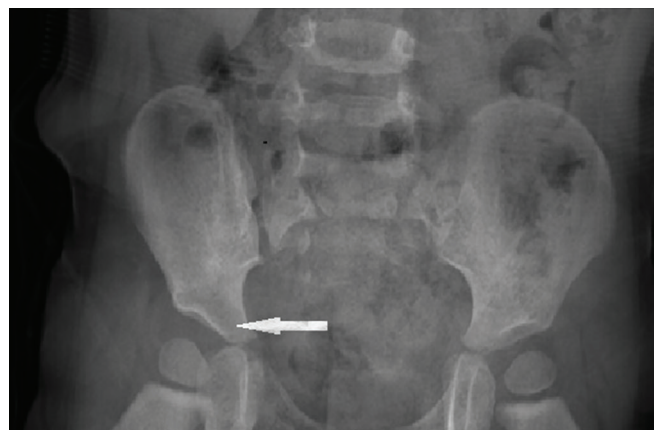


Figure 1. An enlarged acetabular angle with a shallow acetabular cavity on the right side is visible in a 6-month-old girl.

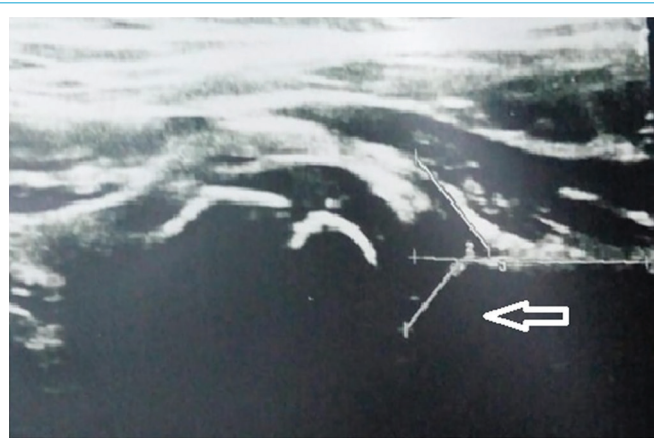


Figure 2. Ultrasonography image of the same pediatric patient showing narrowed iliac drift angle (Graf's alpha angle) on coronal plane.

heads become apparent.

Today, noninvasive methods, (especially MRI) are preferred in order to better understand the structure of the capsule (Fig. 3, 4).

Treatment

In pathological cases detected using US in the neonatal period, if a significant dislocation is observed (antenatal dislocations), the Ortolani maneuver and closed reduction are attempted. Then, in borderline cases of dislocation or subluxation, a thick diaper is usually used until the fourth month. A Pavlik bandage is applied on hips that do not improve after

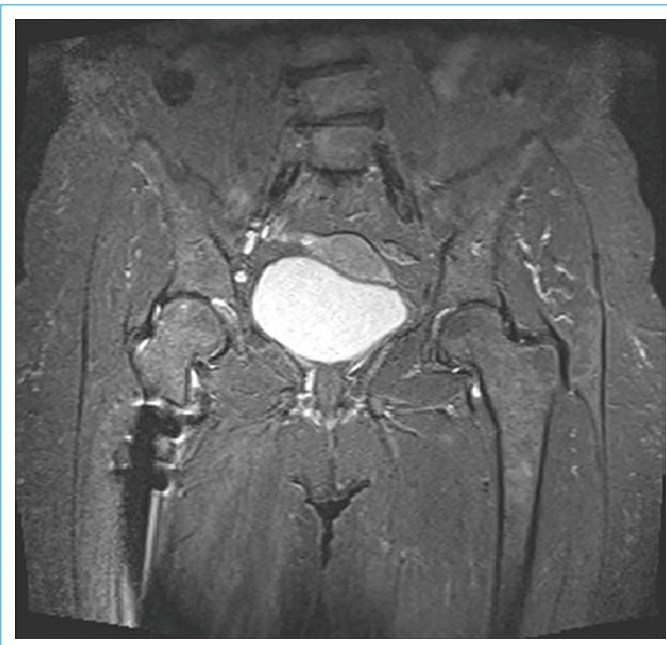


Figure 3. Coronal T2-weighted magnetic resonance image of a 29-year-old female patient with slight right hip dysplasia, lumbar scoliosis, and metallic artifact secondary to derotation osteotomy in the right femur.

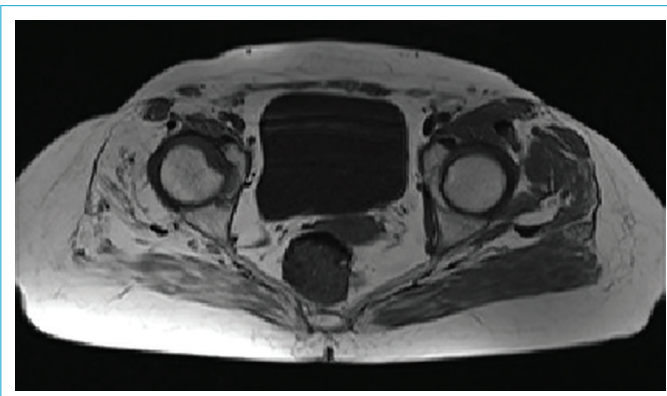


Figure 4. Axial T1-weighted image demonstrating right hip dysplasia and increased femoral head anteversion in a 29-year-old female patient.

the fourth month so that the legs remain in abduction and external flexion positions and the knees in flexion.

This application may be sustained until the 10th month. Fixation of the legs in an exaggerated frog-leg position using a bandage should not be performed, as it may cause aseptic femoral head necrosis. A plaster cast application is sometimes considered for post-reduction fixation.

In addition, in children older than 3 months, closed reduction should be performed under general anesthesia after complete relaxation of the muscles and ligaments is ensured. When successful results are achieved, the plaster cast is removed and a Pavlik bandage or other recommended orthosis is applied.

The radiological diagnosis, follow-up, and treatment modalities described are no longer used when the child starts to walk. Children with DDH typically begin to walk relatively late and limping is frequently observed.

Computed Tomography and Three-Dimensional Computed Tomography

CT performed in patients diagnosed with DDH is important in the radiological algorithm because of the advantages as of the axial imaging feature, its capability to investigate the conformity of the femoral head to the acetabular cavity, the lack of any deterioration in image quality in cases of plaster cast fixation, and the ability to measure rotation angles.

Although there are measurement and calculation capabilities in classic CT, it has disadvantages, such as exposure to ionizing radiation, and also the inability to clearly distinguish the cartilage epiphysis from surrounding tissues. However, in patients who have entered the treatment period, CT is still widely used in the process of fixation with a plaster cast and during the follow-up period after correction surgery.

CT is not so successful in visualization of the iliopsoas tendon, coxofemoral joint capsule, ligamentum teres and fibroadipose tissues around the joint, so arthrography or MRI may be performed.

CT has the advantage of detecting femoral and acetabular torsion, as well as providing more detailed images of regions masked by a cast, compared with MRI.

Femoral torsion in the newborn period may be as much as 40°; however, this measurement generally decreases to about 16° in adulthood. In untreated or poorly treated cases, this angle gradually increases. Anteversion angles up to 60° to 80° have been reported.

Conventional CT can also reveal atrophy of the soft tissue, intracapsular fluid and decreases in the bone osteoid matrix can be noticed.

Open reduction may be applied once the patient is of walking age if closed reduction and other fixation attempts have failed. Multiplanar and 3D imaging can provide an important contribution to the clinician in further clarifying the bone anatomy and determining the type and extent of a subsequent operation.

Surgical procedures are used to correct capsular and muscular pathologies in advanced hip dysplasia with a delayed diagnosis or detected at walking age, or significant femoral and iliac deformations. The common purpose of these procedures is to expand the bone surface, which forms the roof of the femur.

CT images demonstrating the femoral-iliac joint on an axial plane can be valuable to indicate the most appropriate surgeries:

The surgical procedures generally applied are:

1. Varus and derotation osteotomies to correct femoral instabilities,
2. Salter operations, in which acetabulum rotations are corrected,
3. Pemberton operations, in which the acetabular cavity is expanded, double osteotomies (Sutherland technique),
4. Chiari operations, where the femoral head is medialized,
5. Acetabular roof surgeries, which can be classified as shelf operations, and
6. Total hip arthroplasty applications in cases of advanced arthrosis.

In addition to postoperative surgical complications, ischiadic nerve compression and osteoarthritis due to hip immobilization may emerge following these operations (Fig. 5).^[3]

The axial imaging feature of CT is the indispensable imaging modality in cases of advanced- age hip dysplasia, particularly due to the fact that the associations of the joint can be observed clearly, it can be quickly and easily applied, and femoral and acetabular torsion can be determined despite the presence of a plaster cast.

Multiplanar imaging and 3D reconstructions may be most helpful to clinicians in determining the planning for roof osteotomies, derotation procedures, or evaluating hip dynamics in elderly patients.

In the first study of this subject performed at our hospital, CT images of 40 coxofemoral joints of 20 patients who were referred from and diagnosed in the clinics of orthopedics and pediatrics were obtained using a Hitachi W950 SR helical CT device (Hitachi Ltd., Tokyo, Japan). Multiplanar reconstruction (MPR), 3D reconstruction, post-processing, and coxofemoral disarticulation were performed for 28 hip joints of 14 patients in the eligible age group.^[4]

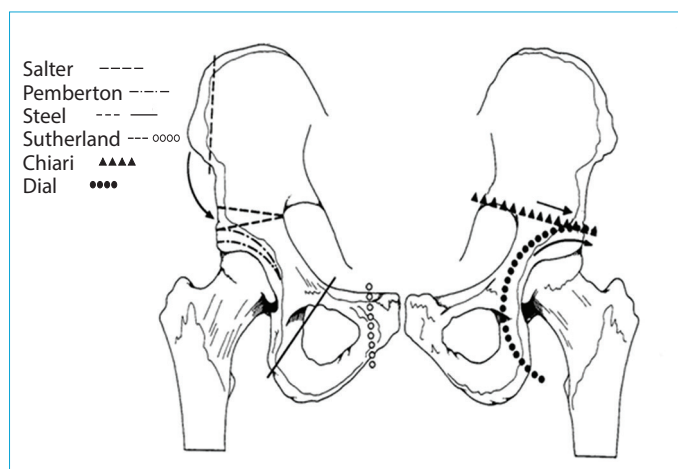


Figure 5. Pelvic osteotomies performed for correction of pelvic asymmetry in late dysplasia.

In addition to the axial sections, images of the femoral distal sections were obtained and femoral anteversion angles were measured. Three-dimensional reconstruction was performed using the WW 2000-1600 HU and WL 200-196 HU windows.

New images were acquired using the retouch function in the indicated window of the axial sections formed. These images were reconstructed and the acetabular ceiling and femoral head structures were separately made traceable (Fig. 6, 7a and b).

Since 3D images show bone structure and coxofemoral relationships, they can be used to determine the part of the femoral head covered by anterior, posterior, and superior acetabular protuberances and what kind of operation should be performed first to provide the joint with load-bearing capacity (Fig. 8).

Three-dimensional reconstruction images and MPR as a supplement to CT sections give the clinician more detailed information in preparation for DDH surgery.

Due to the limited number of patients, statistically significant data could not be obtained about age, family history, pathological status, or gender of the patients. The report offers a highlight of innovative imaging modality techniques and new developments.

Discussion

Congenital hip dislocation is a frequently encountered condition in our country and around the world. The incidence is approximately 0.13%.^[1, 2, 4]

US is used as the main method in diagnosis and follow-up during the first 3 months of life.^[4, 5]

Static hip US, first described by Graf in 1981, is now combined with dynamic examination, as described by Harcke and Rosendahl.^[6]

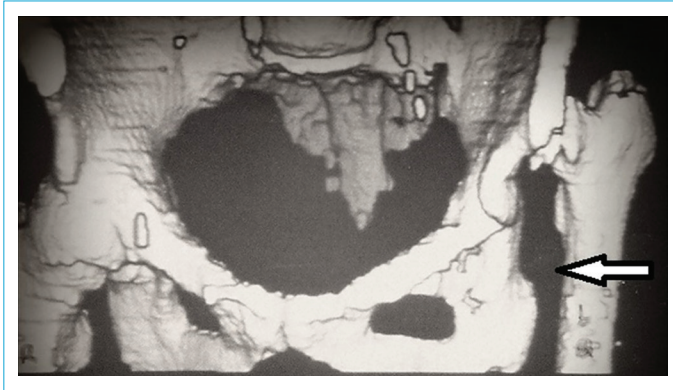

Figure 6. Three-dimensional computed tomography reconstruction performed in our clinic for a 35-year-old female patient. Visible are a hypoplastic shallow acetabulum and a high-lying femoral head on the left side.

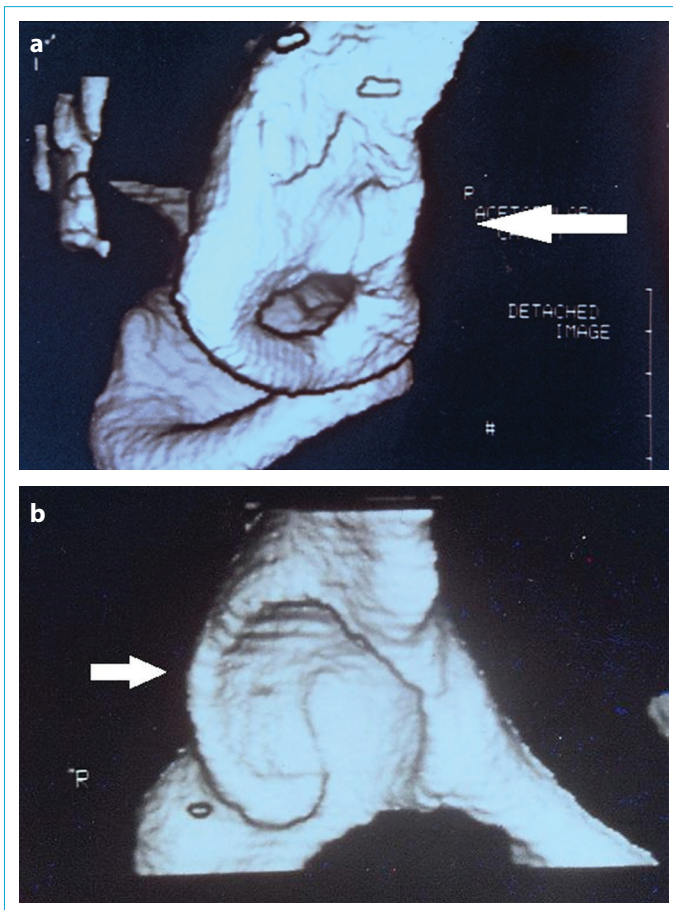


Figure 7. Retained surface images of hypoplastic hip (a) and normal (b) surfaces of the same 35-year-old female patient reconstructed using the retouch technique.

Hips sonographically determined to be unstable or subluxated in patients who are not yet walking often return to normal, but clinicroadiological follow-up may be applied until the age of walking.^[6, 7] Dislocated hips that are manifest, usually visible in the antenatal period, are treated with

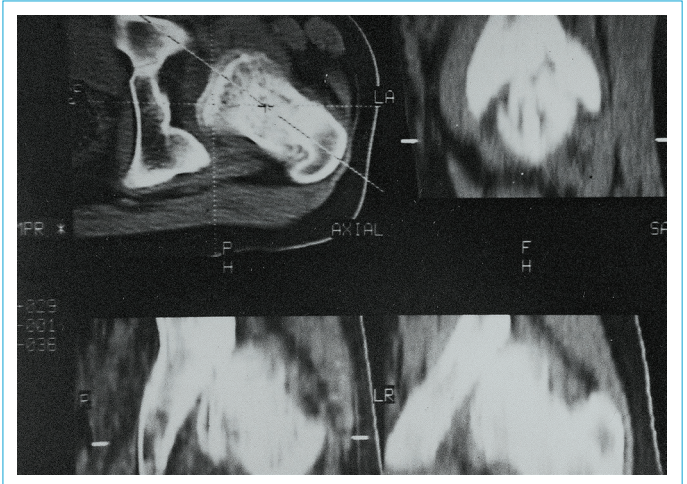


Figure 8. Multiplanar image generated in 4 planes of the 35-year-old female patient.

closed reduction and fixation.^[7, 8]

The main difficulty in the treatment occurs in subluxated or slightly unstable hips. The use of Pavlik bandages or similar fixators is tested until the age of walking.

Since ossified femoral heads manifest at 3 to 6 months of life, standard radiograms are also used. This method is preferred in many centers since it eliminates concerns about artifacts related to metal fixation materials in postoperative follow-up.^[8, 9]

MRI is useful in showing complex pelvis structure in cases where the patient is of walking age or in conditions of previous treatment failures. Although MRI demonstrates bone and muscular planes in more detail than CT, it is not preferred because it is expensive and requires sedation.^[10]

In advanced age with evident femoral head ossification, CT imaging can add great convenience to the clinical approach by demonstrating relationships to the coxofemoral joint, periarticular soft tissue pathologies, and femoral and acetabular torsion rates.^[11]

A postoperative CT can reveal what lies beneath a plaster cast, making it a very valuable tool for clinical practice.^[11, 12]

Three-dimensional CT images and reconstruction of the sagittal and coronal plane are also necessary for patients of advanced age in view of the increasing importance of the pelvic bone morphology.

Azuma et al.^[12] demonstrated the hip dysplasia in 6 patients using 3D CT. Both pre- and postoperative images were taken to discern the details of the operation.

In their study of 3D evaluation of acetabular coverage of the femoral head, Mieno et al.^[13] have suggested that rotational acetabular osteotomy is a beneficial procedure when there is the risk of coxarthrosis.

If MPR, sagittal, and coronal plane images can be obtained by scanning and measuring volume with helical CT, images close to MR soft-tissue quality can be created at the coxofemoral joint. This allows for the condition of the acetabular roof to be monitored more clearly. In addition, disarticulated 3D images obtained in postprocessing provide important detail and clarifying the view of the acetabular cavity.

In addition to clinical data, 3D CT and MPR images added to classic CT will help to create clearer surgical criteria.

Some of the advantages of CT in the visualization of the coxofemoral joint in DDH are clear monitoring of the anterior and posterior bony protuberances of the acetabulum, preservation of image quality of pathologies enclosed in plaster casts, and measurement of femoral-acetabular rotation degrees.^[14]

Although the effects of radiation and postoperative metallic fixator artifacts can be reduced with narrow collimation, these factors should still be considered disadvantages of CT.^[13–15]

It has been reported that helical CT has better soft tissue resolution than conventional CT when appropriate filters are selected.^[15]

In particular, for CT scans in delayed cases of DDH where the patient is over 6 years of age, sagittal and coronal images generated using 3D reconstruction should be used with well-known preoperative anteversion measurements and soft tissue images.

Even though MR imaging provides excellent soft tissue resolution, since it does not demonstrate the cortex clearly and cannot reconstruct better 3D bone images, it has not been introduced into widespread use in DDH.^[10, 16]

In MPR, it has been emphasized that coronal plane images eliminate the superiority of MRI over CT to some extent, especially on a static basis, and display disarticulated 3D images of the bony acetabulum and femoral in more detail.

Radiation Safety-Dose Adjustment

The radiation that occurs during an X-ray directly exerts biological damage on the cells in the tissue, although not as much as nuclear release.

In the long term, the most frequently seen side effect is DNA damage and cancer that develops with a mutation. The relationship between cancer risk and radiation dose is linear and there is no threshold value. The higher the dose, the higher the risk. The necessity of applying the principles of ALARA (as low as reasonably achievable) to the radiation dose is accepted by almost all institutions.

The measure of the effect of radiation in biological tissue is known as the Sievert (Sv) unit equivalent dose. The normal

annual permitted dose that does not create a biological effect in the whole body has been determined to be 50 mSv, and no more than 20 mSv in successive 5-year periods in normal individuals.

Direct radiography produces a dose of approximately 0.02m Sv, while it may be approximately 4 to 6 mSv for CT, which uses collimated rays with high penetration.

A lower yet still effective dose can be achieved by adjusting the penetration current, examination interval, and table speed, and narrowing the range of view. This is especially useful in the pediatric age group.^[17]

With the help of new computer-aided multislice devices, the dose can be measured in advance and possible reductions can be planned before the operation.

Conclusion

DDH continues to be an important orthopedic problem. Since early diagnosis can ensure a completely uneventful recovery, US screening and follow-up is important. When complications and arthrosis develop in the late period, surgery is unavoidable, typically total arthroplasty, before correction techniques can be considered.^[17–19] Helical CT and 3D imaging should be preferred for evaluation once the patient has reached walking age when ossification of femoral head becomes prominent.^[20–22]

Multiplanar sagittal and coronal images should be added after CT sections in older patients with DDH, as well as 3D reconstructions that can better illustrate the coxofemoral joint with respect to all bone components and articular connections than classic axial CT sections.

Disclosures

Peer-review: Externally peer-reviewed.

Conflict of Interest: I certify that there is no conflict of interest with any financial organization regarding the material discussed in the manuscript.

References

1. Dahnert W. Radiology Review Manual. Baltimore: Williams and Wilkins; 2011. p. 67–9.
2. Swarup I, Penny CL, Dodwell ER. Developmental dysplasia of the hip: an update on diagnosis and management from birth to 6 months. *Curr Opin Pediatr.* 2018;30:84–92.
3. Gandhi V. Slideshare Seminars on Osteotomies Around Hip. Available at: <https://www.slideshare.net/PritiMunot/gandhi-ortho-finalppt-20>. Accessed March 20, 2019.
4. Bankaoğlu M. Doğumsal Kalça Çıkığının Bilgisayarlı Tomografi(BT) ile Üç Boyutlu ve Multiplanar Görüntülenmesi. *Uzmanlık Tezi. İstanbul: Sağlık Bakanlığı Şişli Etfal Hastanesi; 1996.*
5. Tachdjian MO. *Pediatric Orthopedics.* Philadelphia: Saunders;

1990. p. 297–526
6. Graf R. Hip sonography--how reliable? Sector scanning versus linear scanning? Dynamic versus static examination? *Clin Orthop Relat Res* 1992;18–21.
 7. Demirhan M, Şar C, Aydınok Ç, Çakmak M, Çoban A. Doğumsal Kalça Çıkığının Tanısında Ultrasonografi. *Acta Orthop Traumatol Turc* 1994;28:8–14.
 8. İşgüven H. Doğuştan Kalça Çıkıklarının Teşhis ve Takibinde Ultrasonografinin rolü. *Uzmanlık Tezi*; 1989.
 9. Harcke HT, Grissom LE. Performing dynamic sonography of the infant hip. *AJR Am J Roentgenol* 1990;155:837–44.
 10. Bos CF, Bloem JL, Verbout AJ. Magnetic resonance imaging in acetabular residual dysplasia. *Clin Orthop Relat Res* 1991;207–17.
 11. Atar D, Lehman WB, Grant AD. 2-D and 3-D computed tomography and magnetic resonance imaging in developmental dysplasia of the hip. *Orthop Rev* 1992;21:1189–97.
 12. Azuma H, Taneda H, Igarashi H, Fujioka M. Preoperative and postoperative assessment of rotational acetabular osteotomy for dysplastic hips in children by three-dimensional surface reconstruction computed tomography imaging. *J Pediatr Orthop* 1990;10:33–8.
 13. Mieno T, Konishi N, Hasegawa Y, Genda E. Three-dimensional evaluation of acetabular coverage of the femoral head in normal hip joints and hip joints with acetabular dysplasia. *Nihon Seikeigeka Gakkai Zasshi* 1992;66:11–22.
 14. Chiari K. Medial displacement osteotomy of the pelvis. *Clin Orthop Relat Res* 1974;55–71.
 15. Haas SL. Pin Fixation in Dislocation at the Hip Joint. *J Bone Joint Surg* 1932;14:346.
 16. Lee DY, Choi IH, Lee CK, Cho TJ. Assessment of complex hip deformity using three-dimensional CT image. *J Pediatr Orthop* 1991;11:13–9.
 17. Tap NHM, Sidek MAJ, Ridzwan SFM, Selvarajah SE, Zaki FM, Hamid HA. Computed Tomography Dose in Paediatric Care: Simple Dose Estimation Using Dose Length Product Conversion Coefficients. *Malays J Med Sci*. 2018;25:82–91.
 18. Metaizeau JP, Prévot J, Piechoki M. Pemberton's pelvic osteotomy in the management of residual dysplasias of the socket. [Article in French]. *Chir Pediatr* 1980;21:225–30.
 19. Anda S. Acetabular dysplasia in the adolescent and young adult. *Clin Orthop Relat Res* 1993;308–10.
 20. Anda S, Terjesen T, Kvistad KA, Svenningsen S. Acetabular angles and femoral anteversion in dysplastic hips in adults: CT investigation. *J Comput Assist Tomogr* 1991;15:115–20.
 21. Salter RB. Innominate Osteotomy. In: *The Hip: Proceedings of the Fourth Meeting of the Hip Society*. St. Lois: Mosby; 1976. p. 40.
 22. Yan K, Xi Y, Sasiponganan C, Zerr J, Wells JE, Chhabra A. Does 3DMR provide equivalent information as 3DCT for the pre-operative evaluation of adult Hip pain conditions of femoroacetabular impingement and Hip dysplasia? *Br J Radiol*. 2018;91:20180474.