

Case report

Bilateral diaphragmatic paralysis after an unusual physical effort

Cora Legarreta^{a,*}, Javier Brea Folco^a, Diego Burgos^a, Santiago Arce^b, Carlos Luna^a^a División Neumonología, Hospital de Clínicas José de San Martín, Córdoba Av. 2351, Buenos Aires, C1120AAR, Argentina^b Instituto de Investigaciones Médicas Alfredo Lanari, Combatientes de Malvinas 3150, Buenos Aires, C1427ARN, Argentina

ARTICLE INFO

Keywords:

Diaphragmatic paralysis
Phrenic nerve injury

ABSTRACT

Diaphragmatic paralysis is an uncommon cause of pulmonary dysfunction and can occur after traumatic phrenic nerve injury. Penetrating and blunt trauma to the neck is the most recognized mechanism of injury being stretching of the nerves very uncommon. We report a case of a 39-year-old man with bilateral diaphragmatic paralysis due to violent stretching of the phrenic nerves. Clinical features and diagnosis methods are also reviewed.

1. Introduction

Diaphragmatic paralysis is an uncommon cause of pulmonary dysfunction which may lead to severe morbidity. It can cause dyspnea, reduced exercise performance, sleep hypoventilation, atelectasis and respiratory failure [1]. We report a case of phrenic nerve injury and bilateral diaphragmatic paralysis resulting from stretch trauma after lifting a weight with the neck. Traumatic phrenic nerve injury can result from both penetrating and blunt trauma to the neck but also from stretch injury, although this later mechanism has been seldom reported [2].

2. Case report

A 39-year-old healthy nonsmoking man was referred with a four-week history of exertional dyspnea and orthopnea. The patient was a butcher and he experienced severe pain in the neck and shoulders with left arm paraesthesia after trying to move a very heavy iron grill while working. For this purpose, he placed himself a thick rope around his neck and pulled strongly with his arms and neck backward. Forty-eight hours later, he developed shortness of breath and he was unable to lay in the supine position. He also complained of not sleeping well at night and having frequent nocturnal awakenings. A chest radiograph done at that time was interpreted as normal.

Treatment with nonsteroidal anti-inflammatory drugs slowly relieved his cervical pain although mild left arm paraesthesia persisted. A cardiology consultation done one week before ruled out heart failure and arrhythmias.

At physical examination, the patient was tachypneic and had diminished breath sounds bilaterally. In the supine position, he

experienced severe dyspnea and paradoxical movement of the abdomen during inspiration was observed. Neurologic examination did not disclose any findings. Laboratory findings, ECG and echocardiogram were normal. Arterial blood gases breathing room air and in the sitting position were pH 7.43 p_aCO₂ 34.9 mmHg p_aO₂ 78.7 mmHg HCO₃⁻ 22.5 mmol/L SaO₂ 93%. The chest X-ray showed an elevation of both hemidiaphragms (Fig. 1). A CT scan of the thorax revealed atelectasis at the lung bases. Magnetic resonance imaging of the cervical spine revealed mild bulging of the C4-C5 and C5-C6 discs without protrusions that were not considered to be clinically significant; other abnormalities were not seen.

Pulmonary function tests performed in the sitting position indicated a severe restrictive pattern with a forced vital capacity of 1,99 L (44% of predicted) and reduced maximal static inspiratory pressure. When the patient was turned to the supine position, FVC was reduced by 80%, to 0.39 L. Maximal static expiratory pressure was normal (Table 1). The changes of the flow-volume curve from the sitting position to the supine position can be seen in Fig. 2. Electromyographic evaluation of the four extremities didn't reveal any signs of radicular, plexual or neurophatic injury. Transdiaphragmatic pressure (Pdi) was measured placing balloon catheters in the lower esophagus and stomach through the nose; maximal sniffs maneuvers (Sniff Pdi) were performed at functional residual capacity without a noseclip in the sitting position. Sniffs were repeated until a reproducible value of peak Sniff Pdi was attained and then ten additional maneuvers were performed. Measurements were done with visual feedback [3]. The maximum value recorded was 10 cm of water.

His dyspnea and orthopnea improved dramatically when he was administered noninvasive positive pressure ventilation especially during the night.

* Corresponding author.

E-mail addresses: clegarreta@yahoo.com.ar (C. Legarreta), jbreafolco@fibertel.com.ar (J. Brea Folco), drdiegoburgos@gmail.com (D. Burgos), arcesantiago@fibertel.com.ar (S. Arce), dr.cm.luna@gmail.com (C. Luna).<https://doi.org/10.1016/j.rmcr.2018.02.003>

Received 22 December 2017; Received in revised form 16 February 2018; Accepted 17 February 2018

2213-0071/© 2018 The Authors. Published by Elsevier Ltd. This is an open access article under the CC BY-NC-ND license (<http://creativecommons.org/licenses/by-nc-nd/4.0/>).

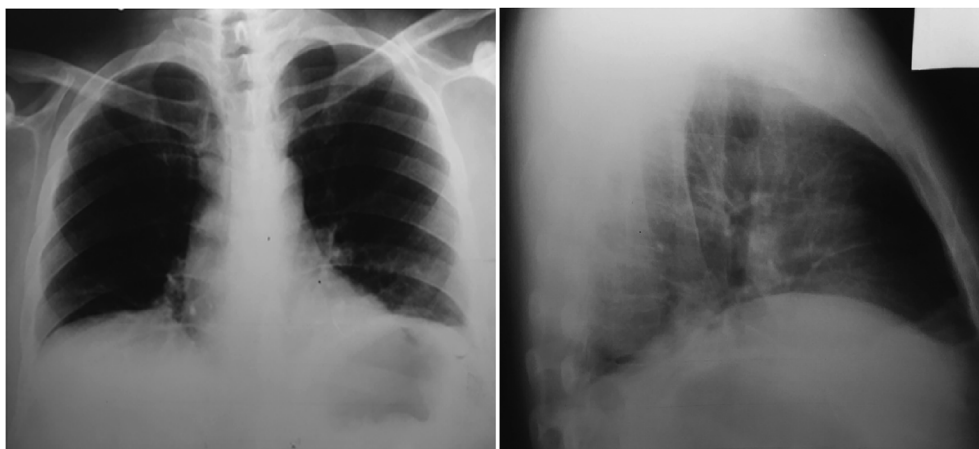


Fig. 1. Chest radiograph showing elevation of both hemidiaphragms and reduced lung volumes.

Table 1
Pulmonary function tests.

Lung function test	In sitting position	% Predicted	In supine position
Forced vital capacity (FVC)	1.99 L	44	0.39 L
Forced expiratory volume in 1 second (FEV1)	1.63 L	45	0.28 L
FEV1/FVC	0.82		0.71
Maximal static inspiratory pressure	63 cm of water	49 ^a	
Maximal static expiratory pressure	137 cm of water	101 ^a	
Total lung capacity	3.48 L	58	
Inspiratory capacity	1.65 L	55	
Expiratory reserve volume	0.26 L	18	

^a Predicted normal values from Black and Hyatt. Am Rev Respir Dis 1969; 99:696–702.

Twelve months later, his symptoms had got better and a new spirometry showed that forced vital capacity had increased to 2,58 L (59% of predicted). In the supine position, it was reduced to 1,28 L (29% of predicted) which represented 50% decrease.

3. Discussion

The phrenic nerves originate from the third to fifth cervical roots and then follow a downward course in the neck in front of the scalenus anterior before entering the thorax; their anatomic position, therefore, explains why they can be injured after a cervical trauma. The most recognized mechanism of phrenic damage is that produced by penetrating and blunt injuries of the neck which accounts for the majority of the cases; to the contrary, stretching of the nerves is very uncommon and has been seldom reported [2,4–6]. The latter has been observed

after traffic accidents where extreme displacement of the cervical spine with or without joint dislocation or fracture, causes the injury. In some curious reports, however, it has been observed following cervical chiropractic manipulation, where only minor trauma is expected [5,7]. Forcefully movements of the neck in these cases, specially forced flexion or rotation of the occiput toward a fixed depressed shoulder, has been described as the mechanism of traction injury [4,5]. The most striking feature of this case is the unexpected mechanism of diaphragmatic paralysis after an unusual way of neck stretching. When trying to move an unusually heavy weight with the help of a rope placed around his neck, our patient suffered a violent cervical hyperextension which caused severe stretching of the nerves and the subsequent diaphragmatic paralysis.

Bilateral diaphragmatic paralysis usually causes severe symptoms; patients generally have shortness of breath with exertion, at rest or in the supine position. Hypoventilation during sleep may also cause hypersomnia and morning headaches. Atelectasis and respiratory failure are other associated complications [1,8].

Diagnosis may be suspected when the patient has abdominal paradox, that is, the paradoxical inward movement of the abdomen as the rib cage expands during inspiration, which is specially seen in the supine position. This breathing pattern results from the contraction of the accessory inspiratory muscles of the rib cage and neck. When these muscles contract during inspiration, they lower pleural pressure and the paralyzed diaphragm moves upward as the abdominal wall moves inward [1]. Patients typically present with elevated diaphragms in the chest X-ray and pulmonary function tests with a restrictive pattern, which worsen in the supine position. A postural fall in vital capacity more than 30% supports the diagnosis of bilateral diaphragmatic paralysis. Maximal static inspiratory pressure is also severely reduced in patients with bilateral diaphragmatic paralysis; to the contrary, maximal expiratory pressure is preserved because the expiratory muscles

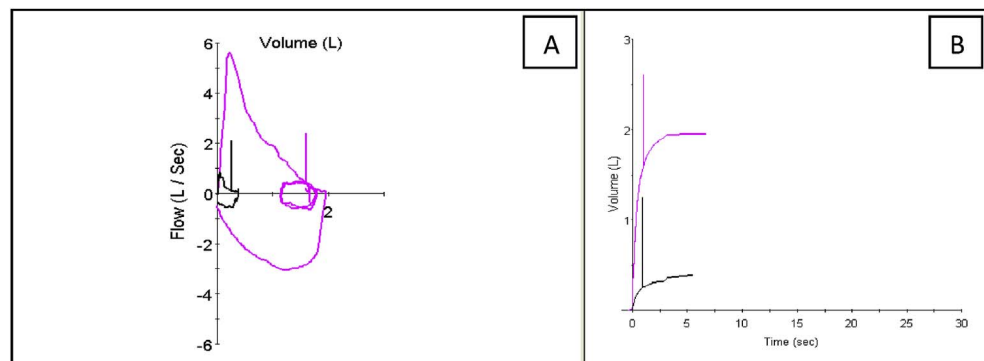


Fig. 2. A. Flow-volume curve in sitting position (in pink) and in supine position (in black). B. Volume-time curve in sitting position (in pink) and in supine position (in black) *Note that tidal volume loop is very closed to residual volume; this could happen because the paralyzed diaphragm, without tone, can be pulled upwards by the intrathoracic negative pressure leaving very little left to exhale (see Table 1 for lung volumes).

are not affected [9–11]. Though invasive, measurement of Pdi is a direct estimation of diaphragmatic function and is considered the standard for the diagnosis. The test is invasive and requires the transnasal placement of balloon catheters in the lower esophagus and stomach. Pdi is calculated as the difference between the gastric and the esophageal pressures. Different maneuvers have been used to measure Pdi. Measurements can be taken during tidal breathing, maximal sniff maneuvers, maximal inspiratory efforts against a closed airway or during electrical or magnetic stimulation of the phrenic nerves [9–11]. Sniff Pdi is performed at functional residual capacity during maximal short sharp sniffs. This technique can be easily performed by patients and is highly reproducible [3]. Maximal sniff Pdi greater than 80 cm of water is usually found in normal subjects [3].

Although not performed in this case, special tests like ultrasonography, must be also mentioned. It can measure diaphragmatic function with the advantage, over transdiaphragmatic pressure, of being a noninvasive method comfortable for patients. This technique detects changes in the thickness of the diaphragm during inspiration so that absence of inspiratory thickening can diagnose paralysis of this muscle [12]. Electromyography studies are another method of assessing diaphragmatic function; phrenic nerve stimulation with evaluation of the electromyographic or Pdi responses and phrenic nerve conduction time, may be helpful for distinguishing between neuropathic and myopathic mechanisms of dysfunction [8]. These tests were not performed in our patient as the cause of the paralysis was clearly of neuropathic origin. Recovery from phrenic nerve injury is unpredictable and may take place over months to years so along observation period of 1.5–3 years is recommended. There is no specific therapy available; the same management as other neuromuscular diseases can apply to these patients. Use of noninvasive positive pressure ventilation may be indicated particularly during sleep in symptomatic patients. In conclusion, traumatic stretching of the phrenic nerves is an unusual cause of diaphragmatic paralysis. Forced displacement of the neck may be eventually complicated with this condition. The combination of severe orthopnea, abdominal paradox in the supine position and a significant postural fall in vital capacity supports the diagnosis of bilateral diaphragmatic paralysis. Transdiaphragmatic pressure is considered the standard for the diagnosis and may be measured for confirmation if

necessary. If the cause of the paralysis is uncertain, electrophysiological tests may be useful to determine whether the lesion is of neurological or muscular origin. Gradual recovery of diaphragmatic function may be expected over months to years.

Conflict-of-interest statement

All authors declare no conflict of interest.

Acknowledgments

The authors wish to thank the physiotherapist Sergio Monteiro for his participation in the assessment of transdiaphragmatic pressure.

References

- [1] F.D. McCool, G.E. Tzelepis, Dysfunction of the diaphragm, *N. Engl. J. Med.* 366 (2012) 932–942.
- [2] L.I.G. Iverson, A. Mittal, D.J. Dugan, P.C. Samson, Injuries to the phrenic nerve resulting in diaphragmatic paralysis with special reference to stretch trauma, *Am. J. Surg.* 132 (1976) 263–269.
- [3] J.M. Miller, J. Moxham, M. Green, The maximal sniff in the assessment of diaphragm function in man, *Clin. Sci.* 69 (1985) 91–96.
- [4] R.W. Snyder, J.S. Kukora, W.N. Bothwell, G.R. Torres, Phrenic nerve injury following stretch trauma: case reports, *J. Trauma* 36 (1994) 734–736.
- [5] D.J. Schram, W. Vosik, D. Cantral, Diaphragmatic paralysis following cervical chiropractic manipulation, case report and review, *Chest* 119 (2001) 638–639.
- [6] D. Bell, A. Siriwardena, Phrenic nerve injury following blunt trauma, *J. Accid. Emerg. Med.* 17 (2000) 419–420.
- [7] A. Pandit, S. Kalra, A. Woodcock, An unusual cause of bilateral diaphragmatic Paralysis, *Thorax* 47 (1992) 201.
- [8] G.J. Gibson, Diaphragmatic paresis: pathophysiology, clinical features, and investigation, *Thorax* 44 (1989) 960–970.
- [9] M.I. Polkey, M. Green, J. Moxham, Measurement of respiratory muscle strength, *Thorax* 50 (1995) 1131–1135.
- [10] J. Steier, S. Kaul, J. Seymour, et al., The value of multiple tests of respiratory muscle strength, *Thorax* 62 (2007) 975–980.
- [11] E.L. De Vito, A. Grassino, Respiratory muscle fatigue: rationale for diagnostic tests, in: C. Roussos (Ed.), *The Thorax*, second ed., Marcel Dekker Inc, New York, 1995, pp. 1857–1880.
- [12] E. Gottesman, F.D. McCool, Ultrasound evaluation of the paralyzed diaphragm, *Am. J. Respir. Crit. Care Med.* 155 (1997) 1570–1574.