

# Cardiogenic shock following balloon post-dilatation in transcatheter aortic valve implantation: first case report of all three stuck leaflets

**Kazuaki Okuyama\*, Masaki Izumo, and Yoshihiro J. Akashi**

Division of Cardiology, Department of Internal Medicine, St. Marianna University School of Medicine, 2-16-1 Sugao, Miyamae-ku, Kawasaki 216-8511, Japan

Received 30 December 2017; accepted 5 June 2018; online publish-ahead-of-print 2 July 2018

## Background

A stuck leaflet and frozen cusp are reported complications following transcatheter aortic valve implantation (TAVI). These complications are rare but can drastically change haemodynamics and be potentially life-threatening; thus, their awareness during TAVI is indispensable. Leaflet malfunction generally presents in one of the three leaflets of a prosthetic valve; however, we encountered a case where all three leaflets were simultaneously stuck.

## Case Summary

A 94-year-old woman was referred to our cardiology department with severe aortic stenosis. She underwent transfemoral TAVI. After a 20 mm balloon was inflated, a 23 mm Sapien 3 valve was deployed. Since the delivery balloon slipped into the ventricle, the valve top was not fully expanded. Post-dilatation using a 23 mm balloon was performed, which led to cardiogenic shock. Immediate cardiopulmonary resuscitation and venoarterial extracorporeal membrane oxygenation were provided. Since aortography and haemodynamics indicated severe aortic regurgitation and transoesophageal echocardiography depicted no leaflets inside the Sapien 3, we confirmed that all leaflets were stuck. The valve-in-valve procedure using the second 23 mm valve was successfully performed, and her haemodynamics dramatically improved. The patient was discharged 20 days later.

## Discussion

Only a handful of cases have been reported on a stuck leaflet following post-dilatation. Root rupture is a major concern of the abrupt change after post-dilatation, but a stuck leaflet should also be considered even when the new-generation balloon-expandable valve, Sapien 3, is used. Here we report the first case in which all three leaflets were stuck.

## Keywords

Transcatheter aortic valve implantation • Balloon-expandable valve • Aortic regurgitation • Case report

## Learning points

- A stuck leaflet has been reported as a complication following transcatheter aortic valve implantation. This phenomenon is rare but can drastically change haemodynamics and be life-threatening; thus, its awareness is indispensable while performing transcatheter aortic valve replacement.
- We encountered a case that all three leaflets were simultaneously stuck just after post-dilatation. A leaflet structure of the valve may potentially have a mechanical factor for becoming stuck following post-dilatation, particularly in the deformed stent. In addition to rupture, a stuck leaflet should be considered as one of the major complications after post-dilatation even when using a new-generation balloon-expandable valve.

\* Corresponding author. Tel: +81 44 977 8111, Fax: +81 44 9976 7093, Email: kazu-823@hotmail.co.jp. This case report was reviewed by Timothy C. Tan, Marco De Carlo and Mark Philip Cassar.

© The Author(s) 2018. Published by Oxford University Press on behalf of the European Society of Cardiology.

This is an Open Access article distributed under the terms of the Creative Commons Attribution Non-Commercial License (<http://creativecommons.org/licenses/by-nc/4.0/>), which permits non-commercial re-use, distribution, and reproduction in any medium, provided the original work is properly cited. For commercial re-use, please contact [journals.permissions@oup.com](mailto:journals.permissions@oup.com)

## Introduction

A stuck leaflet and frozen cusp have been reported as one of complications following transcatheter aortic valve implantation (TAVI).<sup>1–4</sup> These complications are rare but can drastically change the patient's haemodynamics and be life-threatening; thus, awareness of its possibility during TAVI is crucial. Leaflet malfunction generally presents in one of the three leaflets of a prosthetic valve. Here, we report a case in which all three leaflets were stuck in a newly developed prosthetic valve, the Sapien 3 (Edwards Lifesciences, Irvine, CA, USA). To our knowledge, this is the first reported case of all three leaflets becoming stuck simultaneously.

## Timeline

Day	Events
1st day	A 94-year-old woman presented with right inguinal pain and diagnosed with an inguinal hernia. She was referred to the cardiology department due to a comorbidity of severe aortic stenosis; aortic valve area of 0.4 cm <sup>2</sup> , peak velocity of 4.4 m/s, and mean gradient of 47.0 mmHg.
4th day	She underwent transcatheter aortic valve implantation. During the procedure, she became hypotensive secondary to aortic regurgitation; immediate cardiopulmonary resuscitation and venoarterial extracorporeal membrane oxygenation were provided. The valve-in-valve procedure was emergently performed; the patient recovered well after all.
23rd day	The patient was discharged in a stable condition.
4 months later	The patient underwent right inguinal hernia surgery.
1 year later	She was asymptomatic and stable in the 1 year follow-up period.

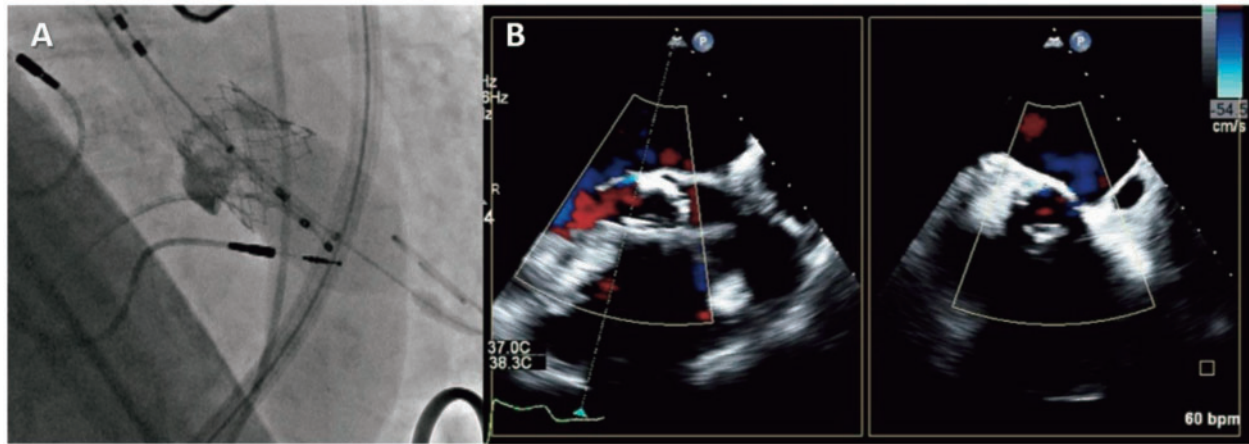
## Case presentation

A 94-year-old woman was transferred to our emergency room because of sudden right inguinal pain. There was swelling in her right groin and computed tomography revealed a right inguinal hernia which required surgical repair. She was previously diagnosed with severe aortic stenosis but initially declined to undergo TAVI; however, surgery was not feasible given her severe aortic stenosis. Following re-discussion with the patient, she agreed to undergo intervention. She agreed to the procedure this time. Her medical history included hypertension and permanent pacemaker implantation for sick sinus syndrome. On examination, her blood pressure was 131/70 mmHg with a heart rate of 62 b.p.m. On cardiac auscultation, a systolic ejection murmur was present and the intensity of second heart sound was reduced. The carotid pulse had a weak and delayed upstroke.

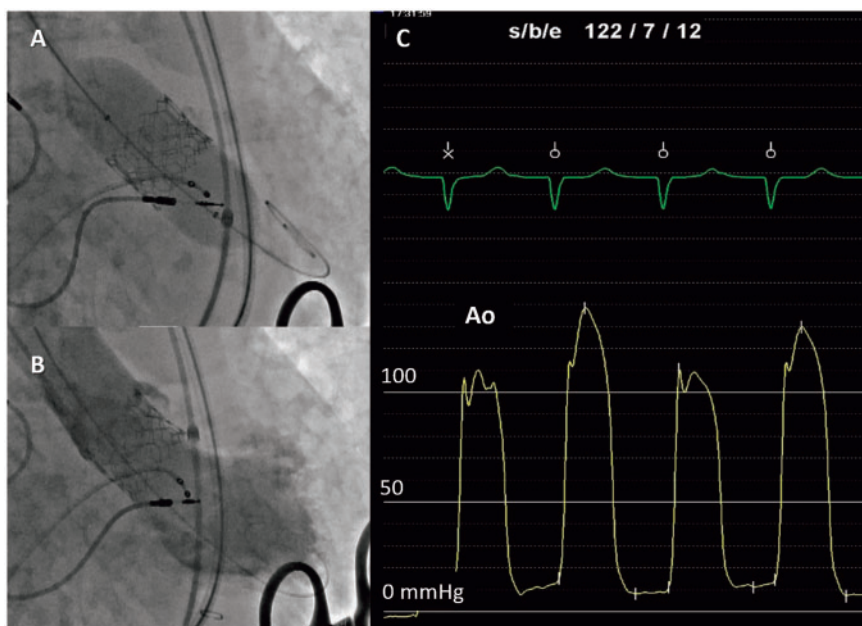
There were no significant findings on respiratory auscultation, but she had jugular vein distention indicating high-central venous pressure. Her cardiac symptom was shortness of breath classified as New York Heart Association II. Transthoracic echocardiography showed a preserved ejection fraction with severe aortic stenosis; aortic valve area of 0.4 cm<sup>2</sup>, peak velocity of 4.4 m/s, and mean gradient of 47.0 mmHg. The Society of Thoracic Surgeons score was 4.0% and the Logistic Euro Score was 32.1%. After multidisciplinary team discussions, the patient was deemed inoperable for heart surgery because of old age, and considered as a candidate for TAVI. Computed tomography showed no significant coronary artery disease. It revealed a 377 mm<sup>2</sup> annulus and compatible iliofemoral arteries; thus, transfemoral TAVI using a 23 mm Sapien 3 was performed. The procedure was under general anaesthesia because our institute was in early experience of TAVI and chose it as a routine method. After the pre-dilatation using a 20 mm balloon, the Sapien 3 was advanced. While crossing the stenotic native valve, we realized that the prosthetic valve and delivery balloon were out of alignment. The delivery system was pulled back to the ascending aorta and re-adjusted. The device crossed the aortic valve again and was deployed under rapid pacing. During the inflation, the delivery balloon slipped into the ventricle probably due to malalignment, and the valve top was not fully expanded (*Figure 1A*, *Supplementary Materials S1* and *S2*). Although the paravalvular leak was mild (*Figure 1B* and *Supplementary Material S3*), post-dilatation using a 23 mm balloon was decided to prevent recoiling and a small valve area caused by insufficient expansion (*Figure 2A* and *Supplementary Material S4*). Just after the post-dilatation, the patient developed shock and arrested. Cardiopulmonary resuscitation was commenced and venoarterial extracorporeal membrane oxygenation (ECMO) was provided. Aortography and haemodynamics indicated severe aortic regurgitation (*Figure 2B* and *C*). Transoesophageal echocardiography depicted the absence of leaflets inside the Sapien 3 with severe aortic regurgitation throughout the entire stent (*Figure 3*, *Supplementary Materials S5* and *S6*); thus, we confirmed that all three leaflets were stuck. A pigtail catheter was advanced and manipulated in the prosthetic valve stent, but the leaflets were not recovered. The valve-in-valve procedure was performed using the second 23 mm valve (*Figure 4A* and *Supplementary Material S7*). The second valve functioned well with a mild paravalvular leak (*Figure 4B*, *Supplementary Materials S8* and *S9*) and her haemodynamics dramatically improved. The ECMO was removed in the operating room and the patient was sent to the cardiac care unit under close observation. She was discharged 20 days later in a stable condition. Four months later, the patient was admitted again to the surgery department and underwent right inguinal hernia surgery. The patient was asymptomatic and stable in the 1 year follow-up period. Transthoracic echocardiography showed an effective orifice area of 1.32 cm<sup>2</sup>, peak velocity of 2.3 m/s, and mean gradient of 11.4 mmHg.

## Discussion

A stuck leaflet and frozen cusp are known complications following TAVI; to date, only four cases have been published.<sup>1–4</sup> Al-Attar et al.<sup>1</sup> reported the first case of severe intraprosthetic regurgitation triggered by an immobile leaflet after TAVI using a 23 mm Edwards-



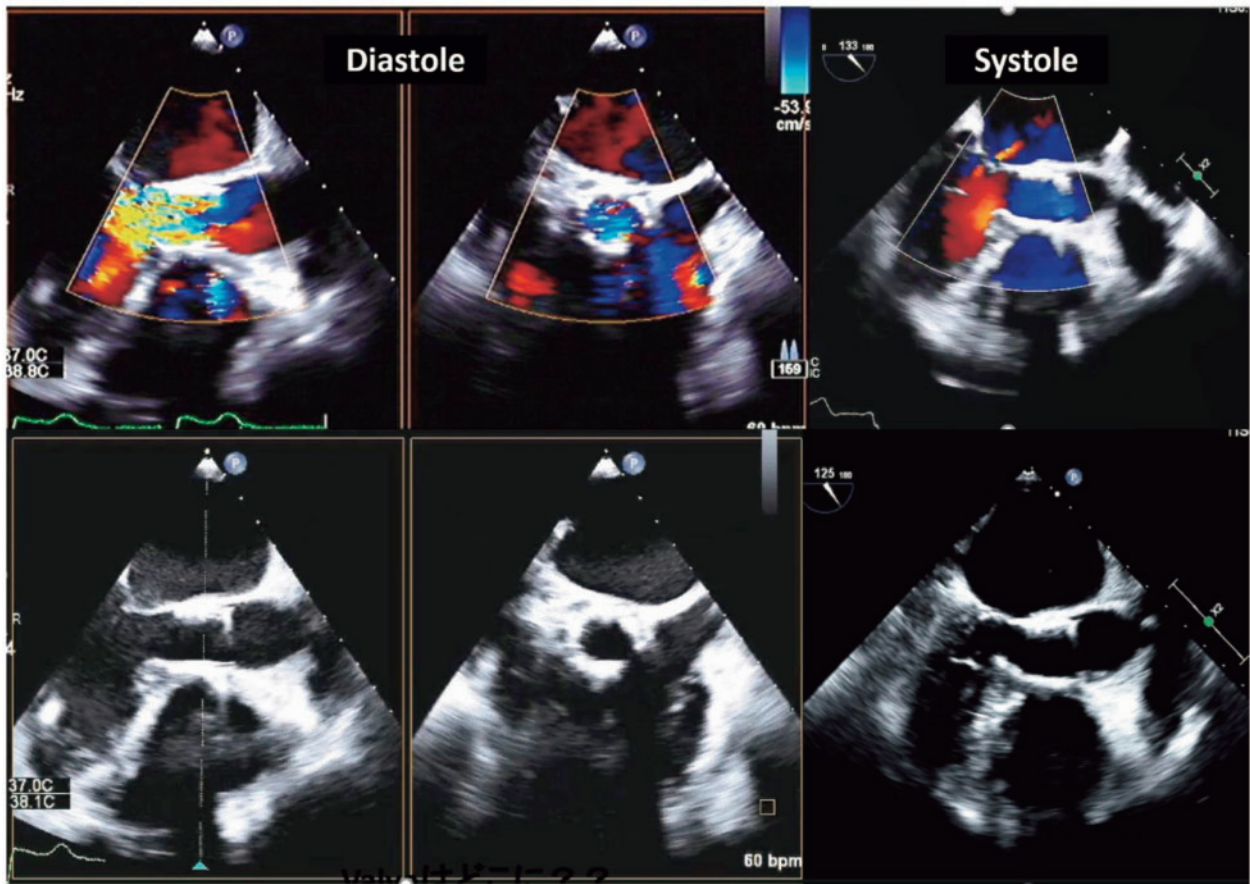
**Figure 1** (A) The delivery balloon slipped into the left ventricle and the valve top was not fully expanded. (B) Transoesophageal echocardiography showing a mild paravalvular leak and insufficient valve top expansion.



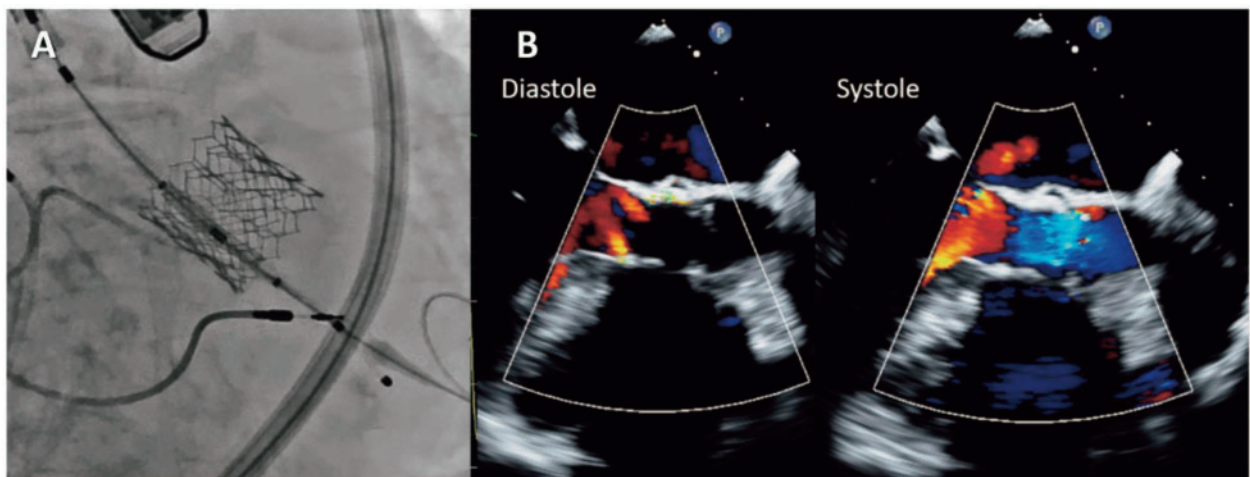
**Figure 2** (A) Post-dilatation using a 23 mm balloon. (B) Severe aortic regurgitation on the aortogram. (C) Low diastolic blood pressure in the ascending aorta suggesting aortic regurgitation.

SAPIEN valve. Although a new-generation valve, Sapien 3, was developed, a case of a stuck leaflet was again reported by Couture *et al.*<sup>4</sup> This complication can drastically change a patient's haemodynamics and be life-threatening. Ben-Dor *et al.*<sup>3</sup> discussed the bail-out method of this complication as follows: (i) haemodynamic support; (ii) gentle manipulation with a catheter; and (iii) favourable treatment for placing a second prosthesis within the first valve. In the present case, we tried catheter manipulation first; however, it did not restore the leaflet movement. Next, we performed the valve-in-valve procedure. As in our case, all earlier published cases also required the second valve.

The mechanisms of a stuck leaflet have been hypothesized as follows: (i) the native calcified valve leaflet trapped the device leaflet; and (ii) a result of damage to a valve leaflet during preparation.<sup>1,3</sup> A malfunctioning valve from the manufacturer is another possibility. Absence of movement of all three leaflets is unlikely to be explained by the previously mentioned mechanisms. Low blood pressure may explain the immobilization of all three leaflets because sufficient blood pressure is required to close the prosthetic leaflets; however, in our case, the leaflets remained stuck after the blood pressure was recovered by ECMO. The prosthesis slipped from its position over



**Figure 3** Transoesophageal echocardiography after the post-dilatation showing severe intravalvular aortic regurgitation caused by stuck leaflets in the long- (left) and short- (middle and right) axis views. The regurgitation jet is visible through the entire stent placed in the prosthetic valve.



**Figure 4** (A) Valve-in-valve procedure using a 23 mm Sapien 3. (B) Only a mild paravalvular leak was observed after the valve-in-valve procedure.

the balloon when it first crossed the native valve, requiring a second alignment procedure in the ascending aorta. This repeated movement may have damaged the leaflets.

The most probable mechanism is deformation of leaflet due to post-dilatation pressure. In this case, the stent top was not fully expanded secondary to slippage of the delivery balloon, but the prosthesis initially functioned well. The patient developed severe aortic regurgitation right after the post-dilatation procedure. Post-dilatation on an insufficiently-expanded and deformed stent might have resulted in crushing of the leaflets. Since the stent deformation was circumferential, post-dilatation caused the simultaneous failure of all leaflets.

The malalignment between the prosthesis and balloon caused stent deformation requiring post-dilatation. This case emphasizes importance of careful adjustment of alignment before balloon inflation. Furthermore, close attention should be paid to patient's haemodynamics after post-dilatation, particularly in cases with deformed stents.

Although the leaflet became stuck right after deployment in three of the four reported cases (using Edwards Lifesciences Sapien and XT valves), our case and the other reported by Couture *et al.*<sup>4</sup> (using the Sapien 3 valve) were comorbid following post-dilatation. In addition to rupture, a stuck leaflet should be considered as one of major

complications following post-dilatation even when a new-generation balloon-expandable valve is used.

## Supplementary material

Supplementary material is available at *European Heart Journal - Case Reports* online.

**Consent:** The author/s confirm that written consent for submission and publication of this case report including image(s) and associated text has been obtained from the patient in line with COPE guidance.

**Conflict of interest:** none declared.

## References

1. Al-Attar N, Himbert D, Vahanian A, Nataf P. Severe intraprosthetic regurgitation by immobile leaflet after trans-catheter aortic valve implantation. *Eur J Cardiothorac Surg* 2011;**39**:591–592.
2. Agostoni P, Buijsrogge MP, Stella PR. “Frozen” leaflet: a dreadful complication of transcatheter aortic valve implantation. *Circ Cardiovasc Interv* 2012;**5**:321–323.
3. Ben-Dor I, Satler LF, Pichard AD, Waksman R. Severe intraprosthetic regurgitation and valve embolization after transcatheter aortic valve implantation. *Catheter Cardiovasc Interv* 2013;**81**:392–396.
4. Couture EL, Labbé BM, DeLarochelière R, Rodés-Cabau J, Paradis J-M. Stuck leaflet after transcatheter aortic valve replacement with a SAPIEN-3 Valve: new valve, old complication. *JACC Cardiovasc Interv* 2016;**9**:e133–e135.