

# Laparoscopic-Assisted Transumbilical Ovarian Cystectomy in a Neonate

Sai Prasad TR, MBBS, MRCS, MCh, Chan Hon Chui, MBBS, FRCS, FAMS

## ABSTRACT

The occurrence of ovarian cysts in a neonate is common, but the management of the same is contentious. We present a case of a prenatally diagnosed complex ovarian cyst in a neonate, which was successfully treated by a novel laparoscopic technique. The literature was reviewed and the diagnosis, treatment options, and controversies in the management are discussed, highlighting the role of preservation of the ovary via the laparoscopic-assisted transumbilical ovarian cystectomy procedure.

**Key Words:** Ovarian cyst, Neonate, Complications, Laparoscopy, Treatment.

## INTRODUCTION

Although neonatal ovarian cysts (NOC) are increasingly diagnosed with routine antenatal ultrasound screening, their management is still controversial.<sup>1-5</sup> Preserving the ovary is the key aim in the management of these apparently benign lesions.<sup>1-5</sup> We describe a technique of 2-port laparoscopic-assisted transumbilical ovarian cystectomy performed successfully in a neonate with a complex ovarian cyst. This technique aids in the panoramic assessment of the abdomen and the pelvis in addition to accomplishing ovarian cystectomy with ease.

## CASE REPORT

A full-term female neonate with a birth weight of 3.08 kg was prenatally diagnosed at 35 weeks gestation as having an abdominal cystic lesion. Postnatally, the child was asymptomatic, and the abdominal cystic mass was not palpable. The ultrasound scan of the abdomen revealed a 2.0×2.6×3.0-cm cystic structure in the left hemipelvis, probably arising from the left ovary. The cyst contained a mobile hyperechoic nodule of 1.2×0.5×1 cm. The computed tomographic scan of the pelvis confirmed the same findings, and the diagnosis of possible left ovarian dermoid cyst was considered. The ultrasound examination performed 2 weeks later revealed that the size of the cyst had declined (2.2×1.4×0.9 cm) but still contained the solid nodule measuring 1.0×1.5×1.0 cm. In view of the persistent complex nature of the cyst, laparoscopic ovarian cystectomy was contemplated.

At surgery, after the insertion of a 5-mm umbilical camera port by the open Hasson's technique and creation of pneumoperitoneum up to 8 mm Hg pressures, a yellowish left ovarian cystic lesion measuring 2.5×2.0 cm was noticed. The right ovary was normal. A second port of 3 mm in size was inserted into the left lumbar region. The ovary with the cystic lesion was grasped with an atraumatic grasper passed through the working port. The umbilical incision was extended vertically in the umbilical cicatrix and joined to a periumbilical smiling incision 4 mm in length on the inferior aspect of the umbilicus. The left ovary was delivered through the umbilical incision under direct vision. The ovarian cystic lesion was decapsulated

Department of Pediatric Surgery, KK Women's and Children's Hospital, Singapore (all authors).

Address reprint requests to: Sai Prasad TR, Department of Pediatric Surgery, KK Women's and Children's Hospital, 100, Bukit Timah Road, Singapore 229899. Telephone: 65 63941113, Fax: 65 62910161, E-mail: trsai@rediffmail.com

© 2007 by JSLs, *Journal of the Society of Laparoendoscopic Surgeons*. Published by the Society of Laparoendoscopic Surgeons, Inc.

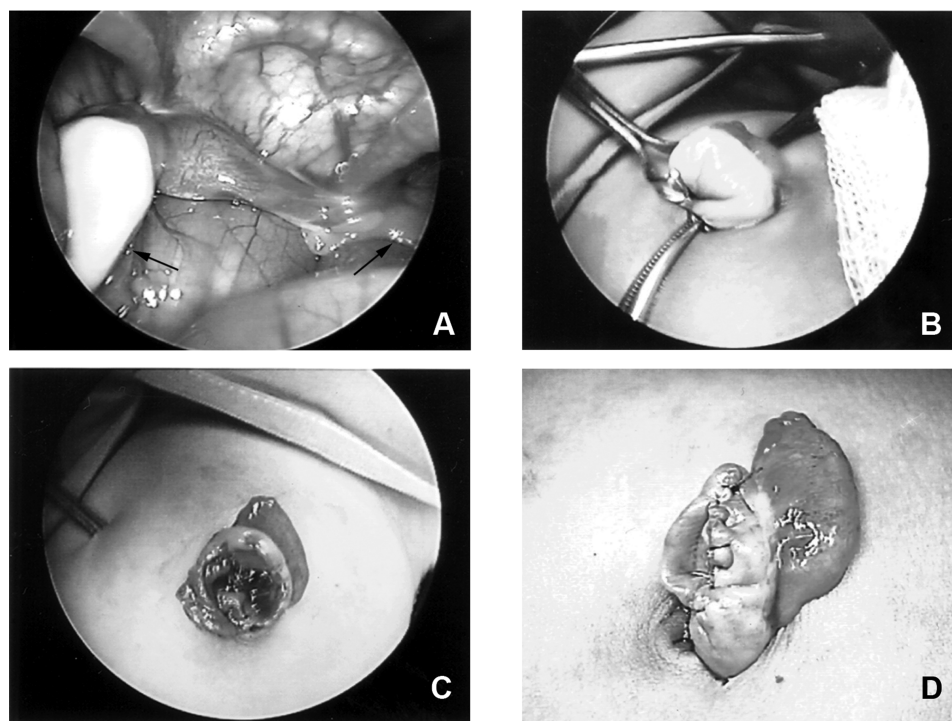
extracorporeally. The cyst contained chocolate colored fluid suggestive of a hematoma that resulted in a solid appearance on the computed tomographic (CT) scan and ultrasound examination. The ovary was reconstituted with continuous sutures of 6.0 polydioxanone and placed back into the pelvic cavity (**Figure 1**). The umbilical fascia was closed with 2 interrupted 3.0-polyglactin sutures. The histopathological examination revealed a benign ovarian cyst. The cyst wall contained fibrous and hemorrhagic tissue along with scattered hemosiderophages. The infant tolerated the procedure well and was discharged on the second postoperative day.

### DISCUSSION

Ovarian cysts are the rule, not the exception in the newborn infants. At birth, 98% of female neonates have ovarian cysts on ultrasound examination, about 20% of which measure more than 9 mm in diameter.<sup>1</sup> They occur either due to hormonal stimulation during the intrauterine or perinatal period, or abnormal development of the primitive gonad, probably because of disruption of its vascularization.<sup>1,3</sup> NOC are classified into simple or complicated cysts on ultrasound examination. A simple cyst is anechoic, with an imperceptible wall, no solid components,

and no fluid debris level. A complex or complicated cyst contains a fluid level, retracting clot, septa, or is completely filled with echoes producing a solid mass-like appearance.<sup>3</sup> Ultrasound is the cornerstone in the diagnosis and delineation of the nature of the NOC. Ultrasonogram and computed tomographic scans serve in differentiating other abdominal cystic lesions in a neonate, such as intestinal duplication cysts, hydronephrosis, lymphangioma, cystic meconium peritonitis, omental, mesenteric, omphalomesenteric, choledochal, hepatic, urachal, renal, or ureteral cysts, anterior myelomeningocele and hydrometrocolpos.<sup>3</sup>

The treatment of NOC is highly debated, and no universal consensus exists.<sup>1-5</sup> A conservative approach with a wait and see policy and serial ultrasonography is advocated because NOC is found to resolve with time, and the risk of malignancy is virtually nonexistent.<sup>1,3,4</sup> Surgical intervention is recommended in cases of complex cysts and simple cysts larger than 4 cm to 5 cm in diameter<sup>1-3,5</sup> to avoid the risk of ovarian torsion and other complications, such as compression on the bowel, ureter, or inferior vena cava; rupture and peritonitis with hemoperitoneum; or incarceration in the canal of Nuck.<sup>1,4,6,7</sup> Surgical intervention could theoretically reduce the risk of these complications along



**Figure 1.** **A:** Laparoscopic view of the left ovarian cyst and right normal ovary. **B:** Transumbilical extraction of the left ovary with the cyst. **C:** Completed ovarian cystectomy. **D:** Reconstituted ovary after cystectomy.

with the salvation of the ovary and also obviates long-term follow-up with serial ultrasonograms. The histopathological examination of the ovarian cyst in our neonate revealed hemorrhagic and fibrous tissue along with hemosiderophages, suggesting previous torsion and detorsion or hemorrhage into the cyst. These features may also suggest that although malignancy is virtually nonexistent in NOC, smaller cysts are also at risk for torsion and ovarian loss.

The management options of NOC vary from antenatal transuterine aspiration to postnatal intervention in the form of repeated ultrasound-guided needle aspiration, laparotomy, or laparoscopic oophorectomy or ovarian cystectomy.<sup>1-5</sup> Recent advances in laparoscopy and neonatal anesthesia has opened new avenues for minimally invasive management of NOC. Neonatal laparoscopy is tenable because neonates can sustain pneumoperitoneum up to the pressures of 8mm Hg.<sup>4,5,8,9</sup> Laparoscopy aids in the delineation of the lesion, evaluation of the contralateral ovary, and sometimes management of other cystic lesions that mimic ovarian cysts. Laparoscopic oophorectomy for ovarian torsion,<sup>10</sup> laparoscopic 2- or 3-port ovarian cystectomy,<sup>5</sup> laparoscopic-assisted aspiration, and ovarian cystectomy through a suprapubic incision have been described in the literature.<sup>5,8</sup> Minilaparotomy with an exteriorization-aspiration ("catch and suck") approach has also been described.<sup>7,11</sup> However, this technique has limitations, especially in cases of a mistaken diagnosis of abdominal cystic lesions in a neonate.

In our patient, we contemplated surgical exploration because the second ultrasound examination revealed the persistence of the solid component within the cyst. To our knowledge, this is the first case report of transumbilical ovary-preserving ovarian cystectomy in a neonate, although a similar technique has been described by Mahomed et al.<sup>9</sup> This technique is also an extrapolation of the procedure utilized for transumbilical extraction of the laparoscopically resected torted ovary.<sup>10,12</sup> The umbilicus is viewed as a window to the abdominal cavity that serves to safely execute minimal access procedures in children. Necessary access into the abdominal cavity can be safely obtained through a cosmetically acceptable and concealable incision. However, umbilical vessels in a neonate may be patent, and hence umbilical port insertions should be through an open Hasson's technique.<sup>4,5</sup> Our technique of vertical umbilical incision with extension to a small infraumbilical smiling incision, allows wide exposure for ligating the patent umbilical vessels and atraumatic extracorporeal delivery of the ovary with the cyst. The shallow

neonatal pelvis and long ovarian pedicle allows transumbilical extraction of the ovary with ease. Ovarian cystectomy and reconstitution of the ovarian anatomy with sutures can be accomplished extracorporeally. This obviates spilling of the contents, reduces operative time, in addition to achieving a safe, effective, aesthetic outcome. This procedure, which combines laparoscopy with conventional operative techniques, has the potential to be performed through a single umbilical incision with insertion of 2 coaxial ports or a single port with access for both the telescope and the grasper.

We also speculate that the procedure can be adopted for large ovarian cysts. The cyst could be drawn up to the umbilical incision and aspirated with a purse-string suture in situ, avoiding spillage and contamination. The decompressed ovary with the cyst wall can be delivered out of the umbilical incision, accomplishing extracorporeal cystectomy.

## CONCLUSION

NOC is common but the treatment options are arguable. Ovary-preserving ovarian cystectomy, although contentious, is indicated for complex cysts and simple cysts larger than 4cm to 5cm to avert the potential complications. Saving the ovary is the key, and this can be safely accomplished in neonates by laparoscopic-assisted transumbilical ovarian cystectomy.

## References:

1. Brandt ML, Helmrath MA. Ovarian cysts in infants and children. *Semin Pediatr Surg.* 2005;14:78-85.
2. Comparetto C, Giudici S, Coccia ME, Scarselli G, Borruto F. Fetal and neonatal ovarian cysts: what's their real meaning? *Clin Exp Obstet Gynecol.* 2005;32:123-125.
3. Enriquez G, Duran C, Toran N, et al. Conservative versus surgical treatment for complex neonatal ovarian cysts: outcomes study. *AJR Am J Roentgenol.* 2005;185:501-508.
4. Dobremez E, Moro A, Bondonny JM, Vergnes P. Laparoscopic treatment of ovarian cyst in the newborn. *Surg Endosc.* 2003;17:328-332.
5. Esposito C, Garipoli V, Di Matteo G, De Pasquale M. Laparoscopic management of ovarian cysts in newborns. *Surg Endosc.* 1998;12:1152-1154.
6. Brandt ML, Luks FI, Filiatrault D, Garel L, Desjardins JG, Youssef S. Surgical indications in antenatally diagnosed ovarian cysts. *J Pediatr Surg.* 1991;26:276-281.
7. Colby C, Brindle M, Moss RL. Minimally invasive laparotomy

for treatment of neonatal ovarian cysts. *J Pediatr Surg.* 2001;36: 868–869.

8. van der Zee DC, van Seumeren IG, Bax KM, Rovekamp MH, ter Gunne AJ. Laparoscopic approach to surgical management of ovarian cysts in the newborn. *J Pediatr Surg.* 1995;30:42–43.

9. Mahomed A, Jibril A, Youngson G. Laparoscopic management of a large ovarian cyst in the neonate. *Surg Endosc.* 1998; 12:1272–1274.

10. Tseng D, Curran TJ, Silen ML. Minimally invasive manage-

ment of the prenatally torsed ovarian cyst. *J Pediatr Surg.* 2002; 37:1467–1469.

11. Ferro F, Iacobelli BD, Zaccara A, Spagnoli A, Trucchi A, Bagolan P. Exteriorization-aspiration minilaparotomy for treatment of neonatal ovarian cysts. *J Pediatr Adolesc Gynecol.* 2002; 15:205–207.

12. Decker PA, Chammas J, Sato TT. Laparoscopic diagnosis and management of ovarian torsion in the newborn. *JLS.* 1999;3: 141–143.